



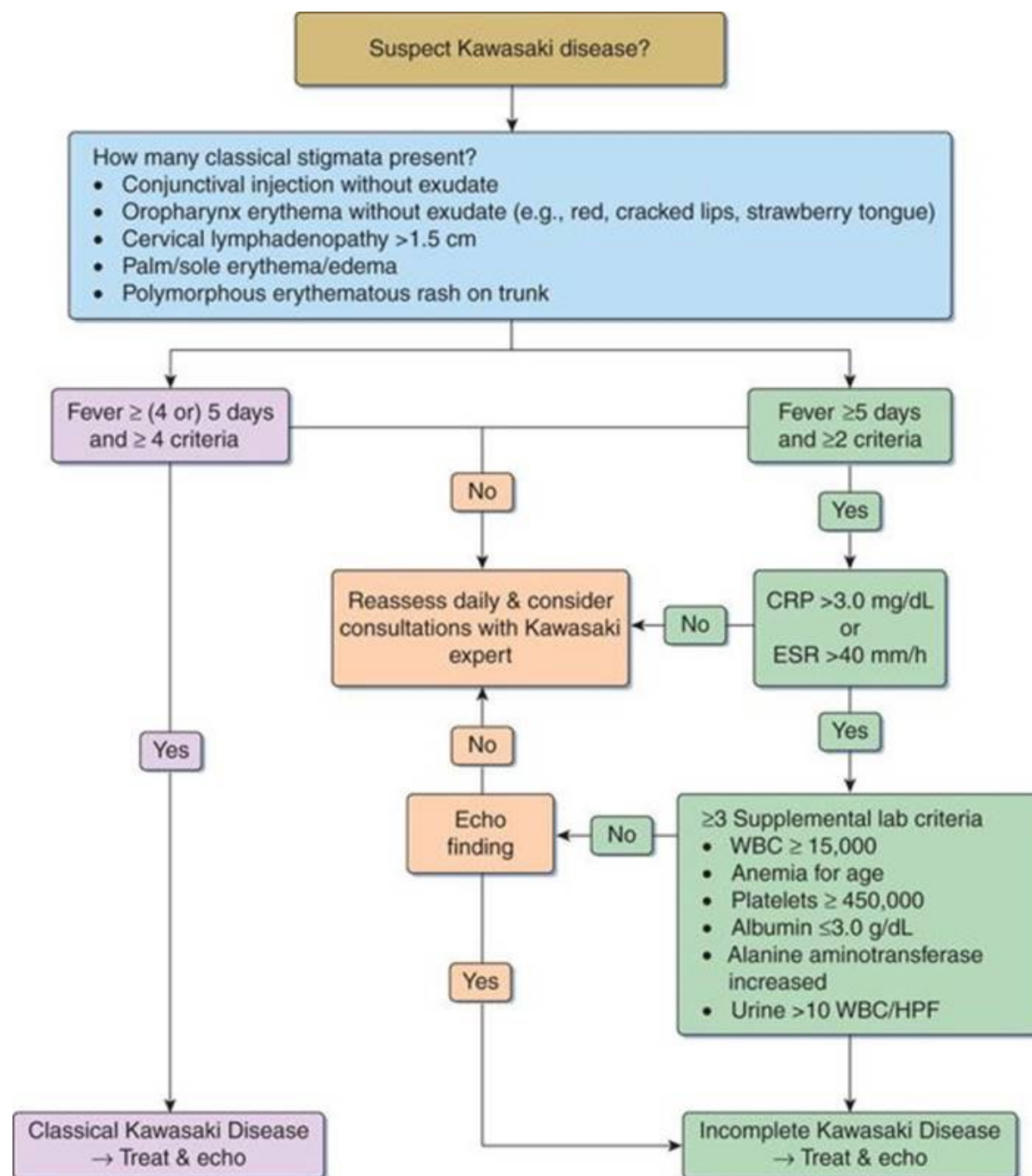
# Doctor, is it incomplete Kawasaki Disease? A case report

Taufiq Hidayat<sup>1,2</sup>, Sharifah Aishah<sup>1</sup>,  
and Muhammad Khairul Amri<sup>1</sup>

<sup>1</sup>Department of Paediatrics,  
International Islamic University  
Malaysia

<sup>2</sup>Mitra Delima Hospital, Malang,  
Indonesia

# Background



# AHA 2017

# Objective



To present a difficult case of incomplete KD with normal echo findings that give good response to IVIG and aspirin treatment



# Case

A 10-month-old girl

Fever for 6 days, 38-39°C, persistent despite 5 days of antibiotic

Generalized maculopapular rashes

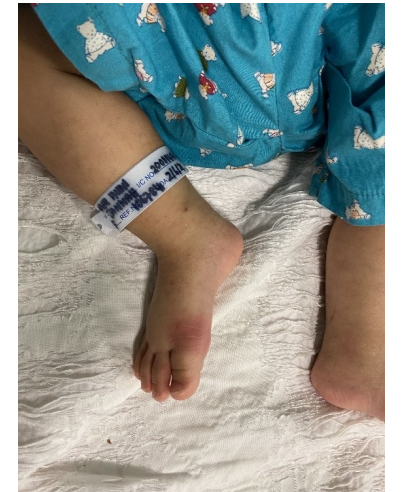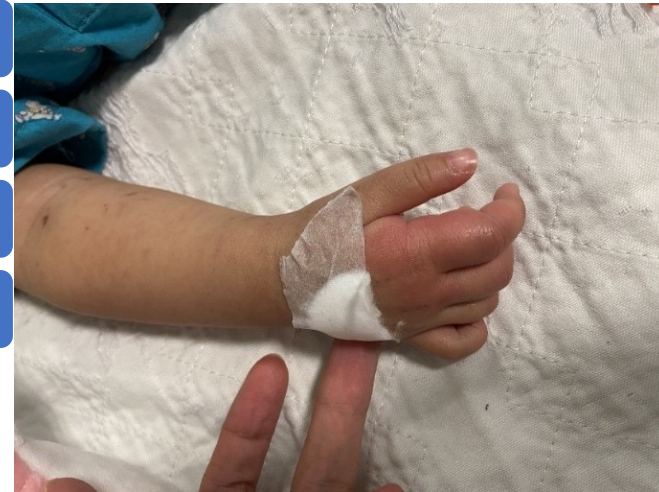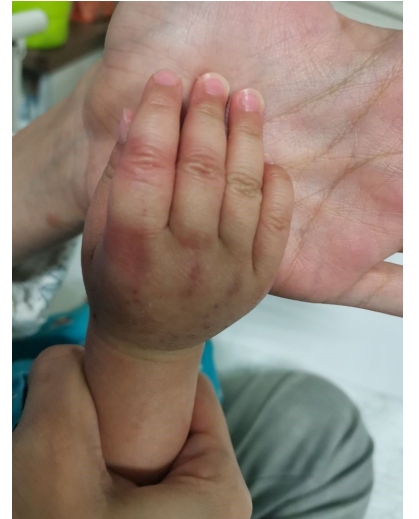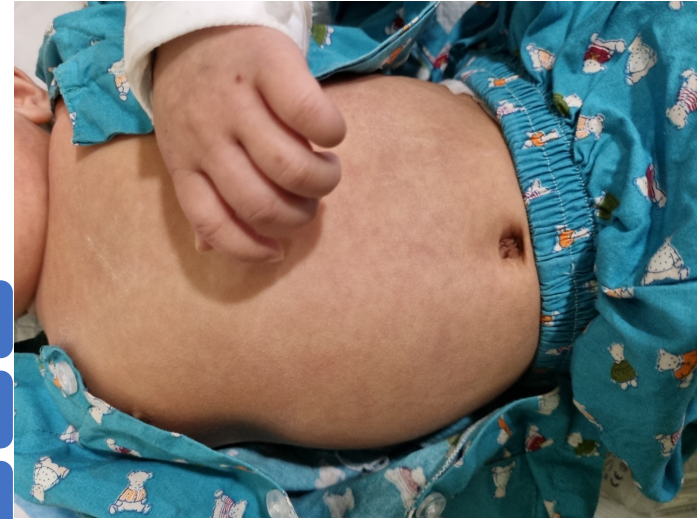Edema & erythema of hands & feet

Shotty cervical lymph nodes <0.5cm

No conjunctivitis

Mucosal changes: injected throat?

No BCG scar





# Case

- Echo:
  - RCA smooth, 2.0-2.3 mm
  - LCA smooth, 1.9-2.2 mm
- CRP 7.67 mg/dL
- ESR 120 mm/h
- Leukocytosis 16.500-30.900/mm<sup>3</sup>
- Anemia 7.1-8.6 g/dL
- Platelets 70.000-691.000/mm<sup>3</sup>
- Raised AST 401-918 and ALT 103-533
- Hypoalbuminemia 2.5-3.3 g/dL
- Urine clear
- Abdominal ultrasound: distended gallbladder with thickened wall

