

×

Search Radiopaedia.org

- [Articles](#)
- [Log In](#)
- [Cases](#)
- [Sign Up](#)
- [Courses](#)
- [Quiz](#)
- [Donate](#)
- [About](#)

×

Search Radiopaedia.org

[Menu](#)



[Search](#)

ADVERTISEMENT: Radiopaedia is free thanks to our supporters and advertisers. Become a Gold Supporter and see no ads.

[Articles](#)

[Cases](#)

[Courses](#)

[Log In](#)



- [Log in](#)
- [Sign up](#)

error

[Articles](#)[Cases](#)[Courses](#)[Quiz](#)

[About](#)[Recent Edits](#)[Go ad-free](#)

Search Radiopaedia.org

A promotional banner for a new X-ray course. The background is dark purple with two X-ray images of a knee joint on the left and right. The text in the center reads "NEW X-RAY COURSE! KNEE INJURIES BY ANDREW MURPHY". On the right side, there is a list of features: "4 hrs of content", "100+ annotated cases", and "completion certificate".

Left horizontal fissure

Case contributed by [Dr Mohd Radhwan Bin Abidin](#)

Diagnosis certain

Diagnosis certain

[Edit case](#) [Share](#) [Add to](#)

- [Report problem with Case](#)
- [Contact user](#)

Citation, DOI and case data

Citation:

Abidin, M. Left horizontal fissure. Case study, Radiopaedia.org. (accessed on 12 Nov 2021) <https://doi.org/10.53347/rID-88569>

DOI:

<https://doi.org/10.53347/rID-88569>

Permalink:

<https://radiopaedia.org/cases/88569>

rID:

88569

Revisions:

3 times by 2 users - [see full revision history](#).

Published:

14th Apr 2021

System:

[Chest](#)

Sections:

-

Tags:

-

Institution:

[International Islamic University Malaysia](#)

Inclusion in quiz mode:

Excluded

Case <https://radiopaedia.org/cases>

Full screen case <https://radiopaedia.org/cases>

Case with hidden diagnosis <https://radiopaedia.org/cases>

Full screen case with hidden diagnosis <https://radiopaedia.org/cases>

- [+ add to new playlist](#)

Presentation

Pleuritic chest pain with productive cough

Patient Data

Age: 20 years

Gender: Male

HRCT thorax

From the case: [Left horizontal fissure](#)

CT

Unable to load images

Please try reloading the page. If the problem continues [send us an email to let us know](#).

[Reload page](#)

Sagittal lung window

There is presence of left horizontal fissure. The lung fields are clear.

Case Discussion

Left horizontal or left minor fissure is an accessory fissure which is a normal variant. It separates the lingula from the rest of the left upper lobe.

References

0 public playlists include this case

Related Radiopaedia articles

Promoted articles (advertising)

Predicting Memories

Science, 2002

The Brain of LB1, Homo floresiensis

Dean Falk et al., Science, 2005

COVID-19 and its implications for thrombosis and anticoagulation

Jean M. Connors et al., Blood, 2020

Chest CT Severity Score: An Imaging Tool for Assessing Severe COVID-19

Ran Yang et al., Radiology: Cardiothoracic Imaging, 2020

Right-Left Asymmetries in the Brain

Albert M. Galaburda et al., Science, 1978

Pars triangularis asymmetry and language dominance.

A L Foundas et al., Proc Natl Acad Sci U S A, 1996

Powered by **TREND MD**

How to use cases

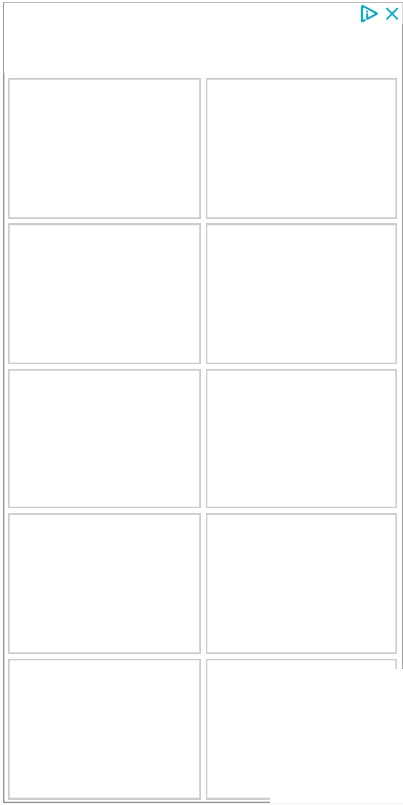
You can use Radiopaedia cases in a variety of ways to help you learn and teach.

- [Add cases to playlists](#)
- [Share cases with the diagnosis hidden](#)
- [Use images in presentations](#)
- [Use them in multiple choice question](#)

Creating your own cases is easy.

- [Case creation learning pathway.](#)

ADVERTISEMENT: Supporters see fewer/no ads



[Encyclopaedia](#)

By Section:

- [Anatomy](#)
- [Approach](#)
- [Artificial Intelligence](#)
- [Classifications](#)
- [Gamuts](#)
- [Imaging Technology](#)
- [Interventional Radiology](#)
- [Mnemonics](#)
- [Pathology](#)
- [Radiography](#)
- [Signs](#)
- [Staging](#)
- [Syndromes](#)

By System:

- [Breast](#)
- [Cardiac](#)
- [Central Nervous System](#)

- [Chest](#)
- [Forensic](#)
- [Gastrointestinal](#)
- [Gynaecology](#)
- [Haematology](#)
- [Head & Neck](#)
- [Hepatobiliary](#)

- [Interventional](#)
- [Musculoskeletal](#)
- [Obstetrics](#)
- [Oncology](#)
- [Paediatrics](#)
- [Spine](#)
- [Trauma](#)
- [Urogenital](#)
- [Vascular](#)

[Patient Cases](#)

- [Breast](#)
- [Cardiac](#)
- [Central Nervous System](#)
- [Chest](#)
- [Forensic](#)
- [Gastrointestinal](#)
- [Gynaecology](#)
- [Haematology](#)
- [Head & Neck](#)
- [Hepatobiliary](#)

- [Interventional](#)
- [Musculoskeletal](#)
- [Obstetrics](#)
- [Oncology](#)
- [Paediatrics](#)
- [Spine](#)
- [Trauma](#)
- [Urogenital](#)
- [Vascular](#)
- [Not Applicable](#)

[Radiopaedia.org](#)

- [About](#)
- [Blog](#)
- [Feature Sponsor](#)
- [Donate](#)
- [Editors](#)
- [Expert advisers](#)
- [Help](#)
- [Privacy Policy](#)



[Facebook](#)



[Twitter](#)



[Newsletter](#)

- Do not share my Personal Information.

[Contact Us](#)

[Terms of Use](#)

[Privacy Policy](#)

[Licensing](#)

[Sponsorship](#)

[Developers](#)

Updating... Please wait.



Unable to process the form. Check for errors and try again.



Thank you for updating your details.

© 2005–2021 Radiopaedia.org

This site is for use by [medical professionals](#). To continue you must accept our [use of cookies](#) and the site's [Terms of Use](#).