


From darkness, a light shall spring: Zero-fluoroscopic ablation of supraventricular tachycardia in a pregnant lady

Mohd Ridzuan Mohd Said¹  | Sathvinder Singh Gian Singh² | Kuo Ting Lee² |
Leet Ming Khor² | Chin Yung Chea² | Anand Raj Silveraju² | Mohd Al-Baqlish Mohd Firdaus¹ |
Dharmaraj Karthikesan² | Annamalar Muthu Muthuppalaniappan² |
Abdul Syukur Abdullah² | Omar Ismail² | Kantha Rao Narasamuloo² | Saravanan Krishinan²

¹Department of Medicine, International Islamic University of Malaysia, Pahang, Malaysia

²Department of Cardiology, Hospital Sultanah Bahiyah, Kedah, Malaysia

Correspondence

Mohd Ridzuan Mohd Said, Department of Medicine, Kulliyah of Medicine, Kuantan Campus, International Islamic University Malaysia, Jalan Sultan Ahmad Shah, 25200 Kuantan, Pahang, Malaysia.

Email: ridzuan.said85@gmail.com

Keywords: ablation, AVNRT, pregnancy, SVT, zero-fluoroscopic

1 | CASE

A 40 years old gravida 9 para 8 lady with underlying hypertension and recurrent supraventricular tachycardia (SVT) was referred to Cardiology clinic for further management. She had multiple admissions to district hospital throughout a year and subsequently referred to our center. She is currently pregnant at 28 weeks and presented with frequent palpitation episodes within a day, European Heart Rhythm Association III,¹ and managed with labetalol by an obstetrician. In view of frequent symptoms and not controlled by medication, decision for ablation was made and best mode of treatment will be zero-fluoroscopic ablation.

During symptom-free period, her electrocardiogram (ECG) recording showed sinus rhythm with heart rate of 73 beats per minute (bpm) and no preexcitation recorded. We managed to capture an ECG during tachycardia whereby the ECG revealed a narrow complex tachycardia², with heart rate of 195 bpm (Figure 1) and noted very short refractory period (RP) interval. Biochemistry wise was unremarkable and echocardiogram revealed structurally normal heart.

Thus, she was subjected to electrophysiological study (EPS) with zero-fluoroscopic ablation utilizing CARTO 3D system (Biosense Webster, Diamond Bar, CA) and planned for diagnostic three catheter study to unmask the diagnosis. First catheter, Smart Touch Thermo Cool D & F curve Ablation Catheter (Biosense Webster,

Diamond Bar, CA), was advanced gently to the right atrium (RA) until atrial signal seen via electrogram. The catheter movement was reflected through the CARTO system without any restriction of movement. A narrow complex tachycardia was induced spontaneously by premature atrial contraction (PAC) (Figure 2A) while preparing the patient for EPS with tachycardia cycle length (TCL) was measured at 283 milliseconds (ms) and Ventriculo-Atrial (VA) interval of 22 ms (< 70 ms) (Figure 2B)³. Hence, with a single catheter in mid RA, a diagnosis of AVNRT was made and decided for modification of slow pathway.

Therefore, 3D geometry of the RA was created while identifying HIS cloud, tricuspid annulus, coronary sinus, and slow pathway signal (Figure 3). Slow pathway was modified with 25 watts and noted junctional rhythms (Figure 2C). The pathway was further consolidated for 2 minutes. Then, a repeated EPS was performed and atrial effective refractory period (ERP) was achieved at an extrastimulus of 500/400/200 (Figure 2D). By achieving atrial ERP with double extrastimulus, we were able to conclude on the successful modification of slow pathway and confirmed the absence of other arrhythmia including atrial tachycardia.

Postablation, she remained well, asymptomatic, and this had eased the burden during delivery via spontaneous vaginal delivery. Later, she was reviewed during clinic follow-up and remained asymptomatic.

This is an open access article under the terms of the Creative Commons Attribution-NonCommercial License, which permits use, distribution and reproduction in any medium, provided the original work is properly cited and is not used for commercial purposes.

© 2020 The Authors. *Journal of Arrhythmia* published by John Wiley & Sons Australia, Ltd on behalf of the Japanese Heart Rhythm Society.

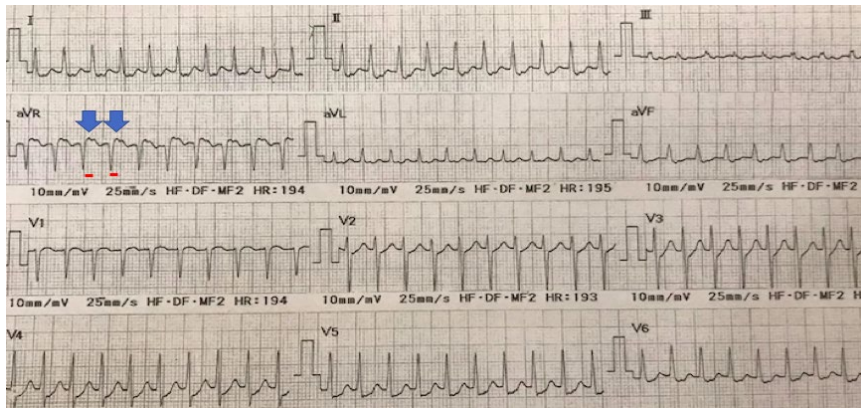


FIGURE 1 Electrocardiogram showing narrow complex tachycardia with heart rate of 195 bpm. Retrograde P wave is reflected with blue arrow and red line is tracing short refractory period interval

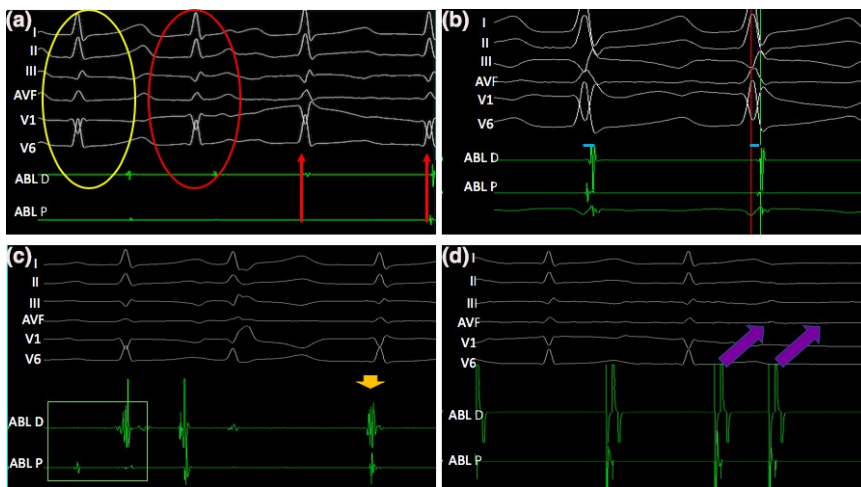


FIGURE 2 Electrogram (EGM) from ablation catheter in atrium. (A) Premature atrial contraction (red circle) induced the narrow complex tachycardia (red arrow), sinus rhythm in yellow circle. (B) Ventriculo-Atrial (VA) time was 22 s (outlined with blue line). (C) Slow pathway potential (green box) identified and junctional rhythm (orange arrow) observed during ablation. (D) Atrial ERP (magenta arrow) achieved during extrastimulus testing

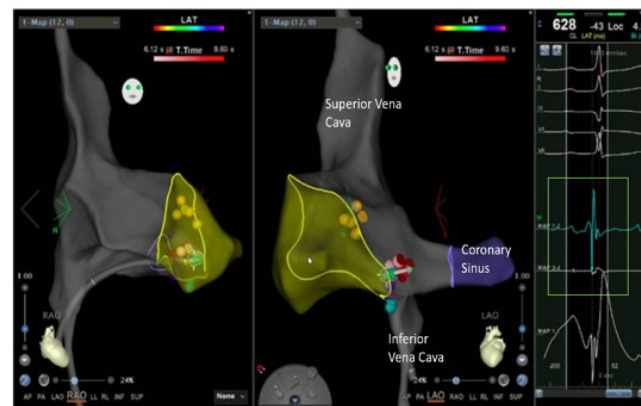


FIGURE 3 Image of 3D geometric of refractory period, superior vena cava, coronary sinus, inferior vena cava, and tricuspid annulus (outline by yellow line). HIS cloud was tagged with yellow spots and ablated lesions were tagged with red and pink spots. Tip of ablation catheter (green spot) at slow pathway potential (green box)

2 | DISCUSSION

Zero-fluoroscopic ablation is gaining favoritism among electrophysiologist with current advancement of 3D mapping system. Apart from no potential radiation hazard, 3D mapping system offers precise geometric

localization, hence hastier ablation procedure⁴. Furthermore, opportunity of avoiding heavy lead apron is intriguing to the practitioner especially during lengthy procedure⁴. Unfortunately, initial transition from conventional procedure to 3D mapping system is reflected with prolonged procedure and ablation time⁴. Nonetheless, previous literature did demonstrate on steep learning curve which lead to significant improvement with the procedure time once the technology is mastered⁴.

In addition, retrospective literatures had demonstrated on successful zero-fluoroscopic ablation of AVNRT with EnSite mapping system (Abbott, St Paul, Min), utilizing multiple diagnostic catheters⁵ and intracardiac echocardiography⁶. Multiple diagnostic catheters provided valuable evidence in establishing the diagnosis but in certain circumstance, prompt treatment is warranted, especially in our case. Our decision for a single ablation catheter as diagnostic and therapeutic was firstly centered on patient status who was in the third trimester with easily inducible arrhythmia. Secondly, we observed that her blood pressure reduced to 95/64 mmHg, particularly symptomatic, and concerned prolonged procedure may affect the well-being of the fetus and warranted for swift ablation. Thirdly, we were able to formulate the diagnosis by evaluating ECG (short RP tachycardia) and electrogram (VA < 70 ms), which suggests high likelihood of AVNRT³. Lastly, we do not deny a likelihood of septal atrial tachycardia; however, we were not able to induce any tachyarrhythmia postablation and hence suggestive of accurate diagnosis of AVNRT.

As conclusion, our case illustrated the practicability of zero-fluoroscopic ablation of SVT utilizing 3D mapping system in a pregnant lady which yielded desirable outcome. However, diagnosis of AVNRT is best formulated by multiple catheter evaluation as illustrated by previous literature,⁵ but in our patient, prompt treatment is desirable. In addition, we demonstrated a safer approach of zero-fluoroscopic ablation without intracardiac echocardiography⁶ by formulating the diagnosis from electrogram despite limited evidence.

CONFLICT OF INTEREST

Authors declare no conflict of interests for this article.

ORCID

Mohd Ridzuan Mohd Said  <https://orcid.org/0000-0001-8478-0849>

REFERENCES

1. Wynn GJ, Todd DM, Webber M, Bonnett L, McShane J, Kirchhof P, et al. The European Heart Rhythm Association symptom classification for atrial fibrillation: validation and improvement through a simple modification. *EP Europace*. 2014;16(7):965–72.

2. Colucci RA, Silver MJ, Shubrook J. Common types of supraventricular tachycardia: diagnosis and management. *Am Fam Physician*. 2010;82(8):942–52.
3. Veenhuyzen GD, Quinn FR, Wilton SB, Clegg R, Mitchell LR. Diagnostic pacing maneuvers for supraventricular tachycardia: part 1. *PACE*. 2011;34:767–82.
4. Cha MJ, Lee E, Oh S. Zero-fluoroscopy catheter ablation for atrial fibrillation: a transitional period experience. *J Arrhythmia*. 2020;36(6):1061–7.
5. Lahiri A, Srinath SC, Chase D, Roshan J. Zero fluoroscopy radiofrequency ablation for typical atrioventricular nodal reentrant tachycardia (AVNRT). *Indian Pacing Electrophysiol J*. 2017;17(6):180–2.
6. Bulava A, Hanis J, Eisenberger M. Catheter ablation of atrial fibrillation using zero-fluoroscopy technique: a randomized trial. *Pacing Clin Electrophysiol*. 2015;38(7):797–806.

How to cite this article: Mohd Said MR, Gian Singh SS, Lee KT, et al. From darkness, a light shall spring: Zero-fluoroscopic ablation of supraventricular tachycardia in a pregnant lady. *J Arrhythmia*. 2021;37:251–253. <https://doi.org/10.1002/joa3.12485>