



Anterior Abdominal Wall Abscess as a Complication of Appendicular Mass in Elderly

Ikhwan Sani Mohamad^{1*}, Shahidah Che Al Hadi², Norzila Abu Bakar³ and Zaidi Zakaria¹

¹Department of Surgery, Universiti Sains, Malaysia

²Department of Surgery, International Islamic University, Malaysia

³Department of Radiology, Universiti Sains, Malaysia

Abstract

Appendicitis in the elderly continues to be a challenging surgical problem. Patients usually present late with atypical presentations. The diagnosis of appendicitis is often difficult to establish and there are increased rate of perforation and mortality. Abscess formation with extension to anterior abdominal wall as reported in this case is rather rare. Older patients also tend to undergo more complicated operative procedures and higher rate of postoperative morbidity and mortality. We reported a case of atypical presentation of appendicitis as anterior abdominal abscess and postoperative challenges in geriatric surgery.

Keywords: Appendicular mass; Anterior abdominal wall abscess

Case Report

An 84-year-old Chinese man presented with painful right iliac fossa swelling for 4 days. It started initially as pain 3 days prior to the presence of swelling. The swelling progressively increased in size. He had no other symptoms apart from constipation few days before admission. He had no significant past medical history.

On general examination, his blood pressure was within normal range, slightly tachycardia 95 beat per minute and a febrile. Abdominal examination revealed a well-defined, firm 6×4 cm irreducible tender mass at right iliac fossa extending to the right inguinal region. Cough impulse was negative. The skin over the lump was normal. The rest of the abdominal examination was unremarkable with no signs of peritonitis or bowel obstruction.

His haematological investigations showed a white cell count of 14.46×10^9 g/dl. His renal profile was within normal limits. An urgent ultrasound abdomen was reported as right Spigelian hernia-able aperistaltic bowel loops herniated through a defect at the right paramedian rectus sheath. The attended subjected this patient for surgery since the findings by clinical and radiological evidences were toward strangulated hernia (Figure 1).

He underwent an emergency exploration of the mass under general anesthesia through a transverse incision placed directly over the swelling. 100 cc pus was found directly underneath the swelling. A diagnostic laparoscope was inserted at the subumbilical region, visualising a clump of omentum adhered to the anterior abdominal

wall underneath the abscess collection. Lower midline laparotomy was done due to difficult mobilization laparoscopically. It was found that an appendicular mass with omentum covering, eroded through the anterior abdominal wall forming abscess. There was also single perforation at the body of the atrophic appendix. The cecum was inflamed but healthy looking. Healthy appendicular base was ligated. The abdominal cavity was washed with saline and an abdominal drain was placed. Mass closure of the lower midline wound was done with 0-Ethilon and with clips to the skin. The transverse wound over the anterior abdominal wall abscess was left opened with the underlying muscle was closed interruptedly with Vicryl 0/0. Intravenous cefoperazone and metronidazole were administered intra- and post operatively. The abscess culture and sensitivity initially grew *E. coli*.

Postoperatively, he developed paralytic ileus and surgical wound breakdown at day 4. Repeated tissue and swab culture from the anterior abdominal wall abscess revealed *Proteus mirabilis*. Histopathologic report confirmed the diagnosis of appendicitis. The patient's condition further deteriorated when he developed hospital-acquired pneumonia at day 9 post operation. Unfortunately, he succumbed to death on day 15 post operation due to septicemic shock secondary to hospital-acquired pneumonia.

Discussion

Acute appendicitis still remains one of the commonest causes of acute abdomen requiring surgery. Appendicitis usually occurs in younger age group with a peak incidence in the second and third decades of life, and 5-10% of cases occurring in elderly [1]. However the incidence of acute appendicitis seems to be increasing in elderly with increase life expectancy [2]. Appendicitis in elderly patient is

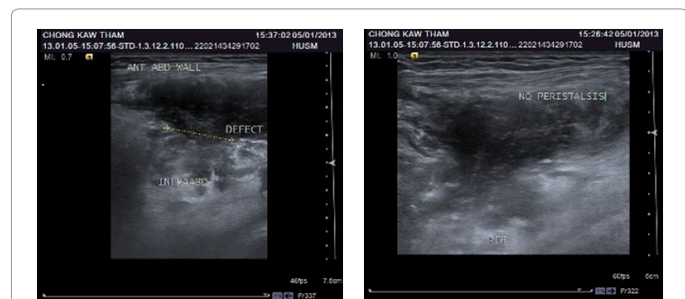


Figure 1: Ultrasound abdomen showed aperistaltic bowel loops herniated through a defect at the anterior abdominal wall.

*Corresponding author: Ikhwan Sani Mohamad, Department of Surgery, Universiti Sains, Malaysia, E-mail: ikhwansani@yahoo.com.my

Received July 09, 2013; Accepted August 24, 2013; Published August 31, 2013

Citation: Mohamad IS, Hadi SCA, Bakar NA, Zakaria Z (2013) Anterior Abdominal Wall Abscess as a Complication of Appendicular Mass in Elderly. Trop Med Surg 1: 137. doi:10.4172/2329-9088.1000137

Copyright: © 2013 Mohamad IS, et al. This is an open-access article distributed under the terms of the Creative Commons Attribution License, which permits unrestricted use, distribution, and reproduction in any medium, provided the original author and source are credited.

also associated with higher rate of morbidity and mortality. Common complications of appendicitis include perforation, peritonitis and abscess formation. However abscess formation with extension to anterior abdominal wall is rather rare. Other unusual complications being reported are thigh abscess, perirenal abscess, appendicocutaneous fistula and necrotising fasciitis.

Elderly patients' usually presented as appendicitis with complications. The rate of perforation is much higher in those over 65 years of age. Up to 40-70% of elderly patients have a perforated appendix at the time of surgery [3]. The high incidence of perforation among elderly may be due to late in seeking medical treatment, atypical presentation and delay in diagnosis. But some also speculated on the anatomic differences of the appendix in elderly which include a thinned, atrophic appendix with reduced blood supply and poorer inflammatory response to localize the infected appendix [2,3].

In the case reported, the patient was 84 year-old elderly presented with painful right iliac fossa mass. The differential diagnoses of this presentation in elderly were usually more towards unusual malignant conditions like ceacal cancer, lymphoma and ileocecal tuberculosis besides appendicitis. Based on the ultrasound findings, the diagnosis was more favourable of obstructed Spigelian hernia. However, the right iliac fossa mass was actually an anterior abdominal wall abscess discovered intraoperatively. Thus, exploratory laparotomy was done to find source of the abscess. The finding was perforated appendicitis which was embedded inside the anterior abdominal wall. Based on a similar case report published by Garipey and Henley, they postulated that such condition occur may be as a result of peritoneal reaction towards the inflamed appendix in which the reaction causing invasion of the adjacent abdominal wall for extension and rupture [4].

Patients with appendicitis, bacteriological cultures usually revealed colonic bacteria frequently polymicrobial. Common species isolated are *Escherichia coli*, *Klebsiella spp.*, *Proteus spp.* and *Bacterioides* [5]. In this case, the organisms cultured were *E. coli* and *Proteus mirabilis*.

The usage of ultrasound abdomen is indicated when the diagnosis is uncertain. It has a high sensitivity of 80% and specificity of more than 90% in diagnosing acute appendicitis [6]. However, it is user dependent and a normal appendix must be identified to exclude acute appendicitis [7]. The application of abdominal CT due to its high sensitivity and specificity of over 90% has improved the accuracy to diagnose appendicitis in elderly. CT findings may be subtle in early phase of appendicitis but more apparent if the appendix is perforated or the presence of appendicular mass or abscess [7].

Appendectomy is the first-line treatment for acute appendicitis. However, a period of non-operative management with antibiotics is indicated in those with appendicular mass who are otherwise clinically well and stable [5]. However, such patients who fail to respond and developed abscess should undergo abscess drainage either by ultrasound or CT-guided percutaneous abscess [8]. Failure to improve clinically means surgical intervention is needed [8]. However, a delayed operation would potentially experience more difficult appendectomy with possible laparotomy and bowel resection [9].

Mortality is often related to intra-abdominal sepsis and in most cases to septic complications from perforation augmented by associated

comorbidities [2]. Another important cause of morbidity and mortality is postoperative infections. Nosocomial pneumonia is a leading cause of postoperative mortality in elderly patients.

Conclusion

To be certain of the diagnosis based on right iliac fossa mass is sometimes quite difficult especially in elderly. Complicated appendicitis such as extension of appendicular abscess needs to be considered in the differential diagnosis of all patients with right iliac fossa mass. A high index of suspicion is necessary to avoid against misdiagnosis. Delays in presentation and diagnosis are associated with higher rates of perforation and hence higher morbidity and mortality. Early abdominal and pelvic ultrasound or CT is helpful in the diagnosis of appendicitis.

References

1. Chen CW, Hsiao CW, Wu CC, Jao SW, Lee TY, et al. (2010) Necrotizing fasciitis due to acute perforated appendicitis: case report. J Emerg Med 39: 178-180.
2. Ghannam M (2012) Elderly versus Young Patients with Appendicitis 3 Years Experience. Alexandria Journal of Medicine 48: 9-12.
3. (October 2005) Appendicitis. Current Problem Surgery.
4. GARIPEY LJ, KENLEY PG (1945) Acute suppurative appendicitis with abscess formation and subsequent perforation of the anterior abdominal wall. Am J Surg 70: 386-388.
5. Simpson J, Scholefield JH (2008) Acute Appendicitis. Emergency Surgery.
6. Maa J, Kirkwood KS (2007) The Appendix. Sabiston Textbook of Surgery, The Biological Basis of Modern Surgical Practice P Waschka, Saunders.
7. Schizas AMP, Williams AB (2010) Management of Complex Appendicitis. Emergency Surgery
8. Schein M (2005) Schein's Common Sense Emergency Abdominal Surgery, Springer.
9. Bahram MA (2011) Evaluation of early surgical management of complicated appendicitis by appendicular mass. Int J Surg 9: 101-103.

Citation: Mohamad IS, Hadi SCA, Bakar NA, Zakaria Z (2013) Anterior Abdominal Wall Abscess as a Complication of Appendicular Mass in Elderly. Trop Med Surg 1: 137. doi:10.4172/2329-9088.1000137

Submit your next manuscript and get advantages of OMICS Group submissions

Unique features:

- User friendly/feasible website-translation of your paper to 50 world's leading languages
- Audio Version of published paper
- Digital articles to share and explore

Special features:

- 250 Open Access Journals
- 20,000 editorial team
- 21 days rapid review process
- Quality and quick editorial, review and publication processing
- Indexing at PubMed (partial), Scopus, EBSCO, Index Copernicus and Google Scholar etc
- Sharing Option: Social Networking Enabled
- Authors, Reviewers and Editors rewarded with online Scientific Credits
- Better discount for your subsequent articles

Submit your manuscript at: <http://www.omicsonline.org/submission/>