

AVD

**Vol. 7
Supplement
September
2014**

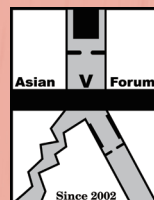
Annals of Vascular Diseases

<http://www.avd.umin.jp/>

Abstract Book



Asian Society
for Vascular Surgery



Asian Venous Forum

15th Congress of Asian Society for Vascular Surgery

9th Asian Venous Forum

September 5–7, 2014 Hong Kong

www.asvs2014.org

Asian Society for Vascular Surgery
Asian Venous Forum

*Published by the Editorial Committee of Annals of Vascular Diseases
c/o Medical Tribune Inc., 2-1-30 Kudan Minami, Chiyoda-ku 102-0074*

CONTENTS

| | |
|--|-------------|
| Committees | S2 |
| Program at Glance | S4 |
| Abstract | |
| Free Paper Presentations Time Table | S9 |
| Free Paper Presentation Abstracts | S20 |
| Poster Presentations Time Table | S63 |
| Poster Presentation Abstracts | S77 |
| Authors Index | S127 |

COMMITTEES

The 15th Congress of Asian Society for Vascular Surgery

Congress President

Stephen W.K. Cheng (Hong Kong)

Congress Organizing Committee

Stephen W.K. Cheng (President)

Yiu Che Chan

Jackie Ho

James Lau

Peter Robless

Albert Ting

Chad Tse

Malcolm Underwood

Alfred Wong

Asian Society for Vascular Surgery

President and Secretary General

Stephen W.K. Cheng

Treasurer

Yew Pung Leong

Councilors

Bangladesh – Niaz Ahmed Choudhury

China – Shenming Wang

Hong Kong – Stephen W.K. Cheng

India – Tarun Grover

Indonesia – Murnizal Dahlan

Japan – Tetsuro Miyata

Korea – Byung Jun So

Malaysia – Yew Pung Leong

The Philippines – Josefino I. Sanchez

Saudi Arabia – Mussaad Al-Salman

Singapore – Peter Robless

Taiwan – Chun-Che Shih

Thailand – Pramook Mutirangura

Turkey – Ahmet Kursat Bozkurt

Founders

John B. Chang (USA)
Yong Kak Lee (Korea)
Yoshio Mishima (Japan)
Zhong Gao Wang (China)

Past Presidents

| | |
|--|--------------------------------------|
| Yoshio Mishima (Japan) – 1994 | Yuqi Wang (China) – 2007 |
| Young Kak Lee (Korea) – 1996 | Sopon Jirasiritham (Thailand) – 2008 |
| Zhong Gao Wang (China) – 1998 | Yonung-Wook Kim (Korea) – 2009 |
| Avenilo P. Aventura (The Philippines) – 2000 | Hiroshi Shigematsu (Japan) – 2010 |
| Ming Keng Teoh (Singapore) – 2002 | Shoei-Shen Wang (Taiwan) – 2011 |
| S. A. Hussain (India) – 2004 | Hiroshi Shigematsu (Japan) – 2012 |
| Yew Pung Leong (Malaysia) – 2006 | A. Kursat Bozkurt (Turkey) – 2013 |

Council Members of Asian Venous Forum

President: Dong-Ik Kim (Korea)
Vice President: Shoaib F. Padaria (India)
General Secretary: Yew Pung Leong (Malaysia)
Treasurer: Tomohiro Ogawa (Japan)
Past President: Takehisa Iwai (Japan)

National Delegates

| | |
|---------------------------------------|--|
| Bangladesh – Niaz Ahmed Choudhury | Saudi Arabia – Mussaad Al-Salman |
| China – Yu-Qi Wang | Singapore – Peter Robless |
| China – Xin-Wei Han | Taiwan – Shoei-Shen Wang |
| Hong Kong – Stephen W.K. Cheng | Thailand – Kamphol Laohapensang |
| Indonesia – Murnizal Dahlan | Thailand – Pramook Mutirangura |
| Japan – Tetsuro Miyata | Turkey – Ahmet Kursat Bozkurt |
| The Philippines – Josefino I. Sanchez | United Arab Emirates – Ramesh Tripathi |

Program at Glance

Friday, Sept 5

| | Auditorium | Lecture Theatre | Function Room 1 | Function Room 2 | James Kung Meeting Room | Fung Ying Seen Koon Meeting Room 2 |
|-----------|--|---|--|--|---|------------------------------------|
| | G/F | G/F | 2/F | 2/F | 2/F | 2/F |
| 0930-1030 | Registration | | | | | |
| 1030-1200 | Session 1A Aorta: Endovascular Stent Grafts | Session 1B Aortic Dissection: Uncomplicated | Session 1C Asian Venous Forum: AV Access | Workshop (Supported by Lombard) | | |
| 1200-1330 | Lunch Symposium (Sponsored by Otsuka): The Optimal Treatment for the PAD Patients | | | | | |
| 1330-1500 | Session 2A Aorta: Thoracoabdominal Aorta | Session 2B Charing Cross Asia 1: TEVAR Controversies | Session 2C Asian Venous Forum: Novel Treatment Options for Venous Disease | Workshop (Supported by Covidien) | Workshop (Supported by Boston Scientific) | Workshop (Supported by KCI) |
| 1500-1530 | Refreshment Break / Poster Viewing / Exhibition (at Exhibition Hall) | | | | | |
| 1530-1700 | Session 3A Aorta: Infections and Inflammation | Session 3B Peripheral: Key Issues in Lower Limb Revascularization | FP3C: Best Paper Session | Workshop (Supported by Covidien) | Workshop (Supported by Boston Scientific) | |

Notes: Please refer to the program book for final scientific program

Saturday, Sept 6

| | Auditorium | Lecture Theatre | Function Room 1 | Function Room 2 | James Kung Meeting Room | Fung Ying Seen Koon Meeting Room 2 |
|-----------|--|--|--|---|--|--|
| | G/F | G/F | 2/F | 2/F | 2/F | 2/F |
| 0830-1000 | Session 4A Aorta: Fenestrated and Branch Solutions | Session 4B Peripheral: Critical Limb Ischemia and Limb Salvage | Session 4C Asian Venous Forum: Endovenous Therapy | FP4D: Asian Venous Forum Free Paper Presentation Venous Thromboembolism | FP4E: Free Paper Presentation Abdominal Aortic Aneurysms - 1 | |
| 1000-1030 | Refreshment Break / Poster Viewing / Exhibition (at Exhibition Hall) | | | | | |
| 1030-1100 | Opening Ceremony | | | | | |
| 1100-1230 | Session 5A Aorta: EVAR in Challenging Anatomy | Session 5B Peripheral: Endovascular Revascularization Techniques | FP5C: Free Paper Presentation Aortic Infections and Complicated Aortic Aneurysm Repair | Workshop (Supported by Jotec) | Workshop (Supported by Gore) | Workshop (Supported by Vascular Insights and Integmed Ltd) |
| 1230-1400 | Lunch Symposium (Sponsored by Gore) Advance Treatment Options for Endovascular Diseases | Lunch Symposium (Sponsored by Medtronic): Raising the Standard of Care for Endovascular Treatment in patients suffering of Aortic and Peripheral Disease – Applying Contemporary Outcomes to Clinical Practice | | | | |
| 1400-1530 | Session 6A Aorta: More on EVAR | Session 6B The Aortic Arch | FP6C: Free Paper Presentation Thoracic Aorta Disease 1 | Workshop (Supported by Terumo) | Workshop (Supported by Siemens) | |
| 1530-1600 | Refreshment Break / Poster Viewing / Exhibition (at Exhibition Hall) | | | | | |
| 1600-1730 | Session 7A Aorta: New Devices | Session 7B Aortic Syndromes: Early and Late Management | FP7C: Free Paper Presentation Thoracic Aorta Disease 2 | Workshop (Supported by Cook) | Workshop (Supported by Abbott) | |
| Evening | Gala Dinner | | | | | |

Notes: Please refer to the program book for final scientific program

Sunday, Sept 7

| | Auditorium | Lecture Theatre | Function Room 1 | Function Room 2 | James Kung Meeting Room | Fung Ying Seen Koon Meeting Room 2 |
|-----------|--|--|--|---|--|------------------------------------|
| | G/F | G/F | 2/F | 2/F | 2/F | 2/F |
| 0830-1000 | Session 8A Aortic Dissection: Complicated | Session 8B Peripheral: Recent Concepts and Developments | FP8C: Free Paper Presentation Abdominal Aortic Aneurysms-2 | FP8D: Asian Venous Forum Free Paper Presentation Varicose Vein | FP8E: Free Paper Presentation Lower Limb Arterial Occlusive Disease - 1 | |
| 1000-1030 | Refreshment Break / Poster Viewing / Exhibition (at Exhibition Hall) | | | | | |
| 1030-1200 | Session 9A Charing Cross Asia 2: EVAR Controversies | Session 9B Peripheral: New Technologies for Lower Limb Ischemia | | FP9D: Free Paper Presentation Carotid Disease | FP9E: Free Paper Presentation Lower Limb Arterial Occlusive Disease - 2 | |
| 1200-1330 | | | Lunch Symposium (Sponsored by Phillips): Clinical Excellence in the Hybrid OR | | | |
| 1330-1500 | Session 10A Carotid | Session 10B Peripheral and Visceral Diseases | | FP10D: Free Paper Presentation Access | FP10E: Free Paper Presentation Miscellaneous | |

Notes: Please refer to the program book for final scientific program

Free Paper Presentation

Best Paper Session

Session Code: FP3C
1530-1700, 5 September
Function Room 1, 2/F

- 0017 The Difference in the Methods and the Results of Subfascial Endoscopic Perforator Surgery, between Europa, North America, and Japan
Hitoshi Kusagawa¹, Yasuhisa Ozu¹, Kentaro Inoue¹, Takuya Komada¹, Yoshihiko Katayama¹, Naoki Haruta²
¹*Matsusaka Chuo General Hospital, Matsusaka, Mie, Japan*
²*Takano-Bashi Central Hospital, Hiroshima, Japan*
- 0082 Our Experience of Type II Endoleaks of Lumbar Artery after Endovascular Repair of Abdominal Aortic Aneurysm
Shintaro Shibutani¹, Hideaki Obara², Hirotohi Ohkubo¹, Shinobu Hayashi¹, Kentaro Matsubara², Yuko Kitagawa²
¹*Department of Vascular Surgery, Saiseikai Yokohamashi Tobu Hospital, Yokohama, Kanagawa, Japan*
²*Department of Surgery, Keio University School of Medicine, Shinjuku, Tokyo, Japan*
- 0152 Effectiveness and Durability of Open Repair of Abdominal Aortic Aneurysm in Octogenarians
Lee KF, Chan YC, Law Y, Yip HC, Ting AC, Cheng SW
Division of Vascular & Endovascular Surgery, Department of Surgery, University of Hong Kong Medical Centre, Pokfulam, Hong Kong, Hong Kong
- 0172 Impact of Selective Antegrade Cerebral Perfusion on Type A Dissection Repair
Randolph Wong, Rainbow Lau, Micky Kwok, Herman Chan, Eugene Yeung, Calvin Ng, Innes Wan, Song Wan, Malcolm Underwood
Division of Cardiothoracic Surgery, The Chinese University of Hong Kong, Shatin, Hong Kong, Hong Kong
- 0186 Ethnic Variation in the Anatomy of the Saphenous Fascia in South Asian Populations
Ming Yuan Tan¹, Yewfah Fong¹, Sriram Narayanan^{1,2}
¹*Tan Tock Seng Hospital, Singapore, Singapore*
²*National University of Singapore, Singapore, Singapore*
- 0193 Practical Design for Fenestrated Stent-Graft in Juxta-Renal Aortic Aneurysm in Korea: Based on Anatomical Analysis
Kihyuk Park
Daegu Catholic University Hospital, Daegu, Republic of Korea
- 0207 Impact of the Ischemic Heart Disease (IHD) on the Early Results of the Elective Abdominal Aortic Aneurysm (AAA) Repairs
Seoung-Wook Choi, Shin-Young Woo, Yang-Jin Park, Dong-Ik Kim, Duk-Kyung Kim, Young-Wook Kim
Division of Vascular Surgery, Department of Surgery, Department of Internal Medicine, Samsung Medical Center, Sungkyunkwan University School of Medicine, Seoul, Republic of Korea
- 0213 Iliac Vein Compression Syndrome in a Non-Vascular Related Symptomatic Patient Population
Fuxian Zhang
Beijing Shijitan Hospital Affiliated to Capital Medical University, Beijing, China
- 0250 The Outcome after Stenting of Ostial Lesions in Superficial Femoral Artery: a Discussion of Risk Factors and Reintervention
Jun-hao Jiang, Jia-ning Yue, Wei-guo Fu, Yu-qi Wang
Department of Vascular Surgery, Zhongshan Hospital, Fudan University, Shanghai, China

Asian Venous Forum: Venous Thromboembolism

Session Code: FP4D
0830-1000, 6 September
Function Room 2, 2/F

- 0070 Incidence of Acute Pulmonary Embolism in Patients with Acute Deep Venous Thrombosis
Piyanut Pootracool, Sapon Jirasiritham, Wiwat Tirapanich, Surasak Leela-Udomlipi,
Suthas Horsirimanont, Arkom Suesawatee
*Vascular and Transplant Division Department of Surgery, Ramathibodi Hospital, Faculty of Medicine,
Mahidol University, Bangkok, Thailand*
- 0081 Mean Platelet Volume as a Predictor of Venous Thromboembolism (VTE): A Systematic Review and Meta-Analysis
Chumpon Wilasrusmee^{1,3}, Boonying Siribumrungwong^{2,3}, Suthas Horsirimanont¹, Napaphat Poprom¹,
Chakrapan Jirasiritham¹, Jarim Wongserepipatana¹, Ammarin Thakkestian³
¹*Department of Surgery, Faculty of Medicine, Ramathibodi Hospital, Mahidol University, Bangkok, Thailand*
²*Department of Surgery, Faculty of Medicine, Thammasat University Hospital, Thammasat University, Pathumthani,
Thailand*
³*Section for Clinical Epidemiology and Biostatistics, Faculty of Medicine, Ramathibodi Hospital, Mahidol
University, Bangkok, Thailand*
- 0195 Mid- and Long-term Outcome of Patients with Permanent Inferior Vena Cava Filters
Felix Che-lok Chow, Yiu Che Chan, Grace Cheung, Stephen Wing-Keung Cheng
The University of Hong Kong, Hong Kong, Hong Kong
- 0211 The Vena Tech LP Permanent Caval Filter: Effectiveness and Safety in the Clinical Setting in Three Chinese Medical Centers
Fuxian Zhang
Beijing Shijitan Hospital Affiliated to Capital Medical University, Beijing, China
- 0242 Pre-dilatation techniques in Budd-Chiari syndrome with chronic inferior vena cava thrombus
Zhen Li, Pengxu Ding, Zhaohui Hua, Xinwei Han, Zhiwei Wang, Wenguang Zhang, Mingti Fu, Zhonggao Wang
Department of Endovascular, the First Affiliated Hospital of Zhengzhou University, Zhengzhou, China
- 0255 The Interventional Treatment for Shunt Stenosis or Occlusion after Mesocaval Shunts in Portal Hypertension
Zhi-wei Wang, Zhen Li, Sheng Guan, Xiu-Xian Ma
Department of Endovascular, the First Affiliated Hospital of Zhengzhou University, Zhengzhou, China
- 0271 Foam Sclerotherapy with Lauromacrogol for Varicose Veins: Analysis on 200 Cases
Sheng Guan, Xiao-hu Ge, Qing-bo Fang, Hao Ren, Li-Mujian A, Bin Zhu
Department of Vascular Center, People's Hospital of Xinjiang Uigur Autonomous Region, Urumchi, China
- 0273 Varicose Vein Surgery without Antibiotic Prophylaxis: Experiences with 664 Patients in a Single Center
Zhoupeng Wu, Jichun Zhao, Bin Huang, Ding Yuan, Yi Yang, Guojun Zeng, Xiyang Chen
Department of Vascular Surgery, West China Hospital, Sichuan University, Chengdu, China

Abdominal Aortic Aneurysms - 1

Session Code: FP4E
0830-1000, 6 September
James Kung Meeting Room, 2/F

- 0062 The Significance of Open Surgery of Abdominal Aortic Aneurysm in EVAR Era
Kiyohito Yamamoto, Kimihiro Komori, Hiroshi Narita, Hiroshi Banno, Akio Kodama, Masayuki Sugimoto
Nagoya University Graduate School of Medicine, Nagoya, Japan

- 0065 Persistent Type II Endoleak and Aneurysmal Sac Change after Endovascular Abdominal Aortic Aneurysm Repair
Takuro Shirasu, Katsuyuki Hoshina, Kunihiro Shigematsu, Toshiaki Watanabe
The University of Tokyo, Tokyo, Japan
- 0149 Mid- and Long-term Results for Patients with Proximal Palmaz Stents in Endovascular Aneurysm Repair (EVAR)
Yuk Law, Yiu Che Chan, Albert C Ting, Stephen WK Cheng
The University of Hong Kong Medical Center, Hong Kong, Hong Kong
- 0154 Long-term Outcome of Patients Who Underwent Open Abdominal Aortic Aneurysm Repair
Yuk Law, Yiu Che Chan, Kwok Fai Lee, Hon Chi Yip, Albert CW Ting, Stephen WK Cheng
The University of Hong Kong Medical Center, Hong Kong, Hong Kong
- 0205 A Prospective Screening of Popliteal Artery Aneurysm in Patients with Abdominal Aortic Aneurysm
Youn-Jung Kim, Shin-Young Woo, Yang-Jin Park, Dong-Ik Kim, Young-Wook Kim
Division of Vascular Surgery, Department of Surgery, Samsung Medical Center, Sungkyunkwan University School of Medicine, Seoul, Republic of Korea
- 0257 Comparison of Early and Mid-term Outcomes of Endovascular Repair versus Open Surgical Repair for Abdominal Aortic Aneurysm
Sheng Wang, Zhong Chen, Xiaobin Tang, Zhangmin Wu, Lei Kou, Hui Liu, Mengyao Zhai, Liao Yang, Qinghua Wu
Beijing an Zhen Hospital, Capital Medical University, Beijing, China
- 0262 Association of Polymorphisms on Chromosome 9p21.3 Region with Increased Susceptibility of Abdominal Aortic Aneurysm in a Chinese Hanpopulation
Yingqi Wei¹, Jiang Xiong², Shangwei Zuo², Feng Chen², Dafang Chen¹, Tao Wu¹, Wei Guo², Yonghua Hu¹
¹*Department of Epidemiology and Biostatistics, School of Public Health, Peking University Health Science Center, Beijing, China*
²*Department of Vascular and Endovascular Surgery, Chinese PLA General Hospital, Beijing, China*

Aortic Infections and Complicated Aortic Aneurysm Repair

Session Code: FP5C
1100-1230, 6 September
Function Room 1, 2/F

- 0064 Endovascular Stent Graft Repair of Infected Aorto-Iliac Pseudoaneurysm: Kuala Lumpur Hospital Experience
Nan Chuang Khang, Zainal Ariffin Azizi
Kuala Lumpur Hospital, Kuala Lumpur, Malaysia
- 0068 Early Experience with Fenestrated and Chimney Endografts for Short Neck Aortic Aneurysms Repair in Ramathibodi Hospital
Arkorn Suesawatee, Piyanut Pootracool, Suthas Horsirimanont, Wiwat Tirapanich, Surasak Leela-Udomlipi, Sapon Jirasiritham
Ramathibodi Hospital, Bangkok, Thailand
- 0071 Endovascular Repair of Ruptured Infectious Thoracoabdominal Aneurysm in a Patient with Previous Endovascular Aortic Aneurysm Repair
Hiroshi Mitsuoka, Takaaki Saito
Shizuoka Red Cross Hospital, Shizuoka City, Japan
- 0112 Case Report of Chimney Stent-Graft Repair for Concurrent Infra-Renal Abdominal Aortic Aneurysms and Inferior Mesenteric Artery Aneurysm
Zhen Wei Choo², Chun Hai Tan³, Punamiya Sundeep¹, Narayanan Sriram¹
¹*Tan Tock Seng Hospital, Singapore, Singapore*
²*Ministry of Health Holdings, Singapore, Singapore*
³*Khoo Teck Puat Hospital, Singapore, Singapore*

- 0133 Follow-up Results of Arterial Reconstructions with Cryopreserved Arterial Allografts: Risk Factors for Graft-Related Complications
Seung-Rim Han, Young-Wook Kim, Yang Jin Park, Shin-Young Woo, Yoong-Seok Park, Dong-Ik Kim
Samsung Medical Center, Seoul, Republic of Korea
- 0166 The Role of PET/CT for Diagnosis of Aortic Stent Graft Infection: Compared with Convention Computed Tomography and Single-photon Emission Computed Tomography (SPECT)
Chun-Che Shih
Taipei Veterans General Hospital, Taipei, Taiwan
- 0187 Aortoduodenal Fistula: A Lethal Codition with Multiple Treatment Options
Zia Ur Rehman, Ziad Sophie
The Aga Khan University Hospital, Karachi, Pakistan
- 0209 Lessons Learned from Stent-graft Placement for Ureteroarterial Fistula
Akhmadu Muradi^{1,2}, Masato Yamaguchi¹, Koji Idoguchi¹, Takuya Okada¹, Yoshikatsu Nomura³, Yutaka Okita³, Koji Sugimoto¹
¹*Center for Endovascular Therapy, Department of Radiology, Kobe University Hospital, Kobe, Japan*
²*Vascular and Endovascular Division, Ciptomangunkusumo Hospital. Faculty of Medicine, University of Indonesia, Jakarta, Indonesia*
³*Cardiovascular Division, Department of Surgery, Kobe University Hospital, Kobe, Japan*
- 0228 The Experience with Endovascular Repair of Complex Abdominal Aortic Aneurysm
Yongquan Gu, Lianrui Guo, Lixing Qi, Jian Zhang, Zhonggao Wang
Department of Vascular Surgery, of Xuanwu Hospital & Vascular Surgery Institute, Capital Medical University, Beijing, China

Thoracic Aorta Disease 1

Session Code: FP6C
 1400-1530, 6 September
 Function Room 1, 2/F

- 0025 Long Term Results of Aortic Root Reconstruction
Hitoshi Minami, Keitaro Nakagiri, Soihro Henmi, Atsushi Omura, Hirohisa Murakami, Hitoshi Matsuda, Masato Yoshida, Nobuhiko Mukohara
Hyogo Brain and Heart Center, Himeji, Hyogo, Japan
- 0086 Delayed Visceral Malperfusion after Bentall Procedure for Type A Acute Aortic Dissection
Satoshi Yamashiro, Yukio Kuniyoshi, Ryoko Arakaki, Yuya Kise, Hitoshi Inafuku
University of the Ryukyus, 207 Uehara, Nishihara, Nakagami, Okinawa, Japan
- 0087 Applicability of Endovascular Treatment for Descending Thoracic Aortic Syndromes: A Single Institution Experience
 Wilmo Orejola¹, David O'Connor¹, Yue Liu², Michael Wildermann¹, Massimo Napolitano¹, Gregory Simonian¹
¹*Hackensack University Medical Center, Hackensack, New Jersey, USA*
²*Stevens Institute of Technology, Hoboken, New Jersey, USA*
- 0148 Retrograde Type A Dissection following Hybrid Supra-Aortic Endovascular Surgery in High Risk Patients Unfit for Conventional Open Repair
Hon Chi Yip, Yiu Che Chan, Albert C Ting, Stephen WK Cheng
Division of Vascular & Endovascular Surgery, Department of Surgery, University of Hong Kong Medical Centre, Hong Kong, Hong Kong
- 0265 The Relationship between Plasma Homocysteine and Aortic Dissection
Jie Liu¹, Chen Duan^{1,2}, Xin Jia¹, Sen-Hao Jia¹, Yang-Yang Ge¹, Zhong-Yin Wu¹, Wei Guo¹
¹*Department of Vascular Surgery People's Liberation Army General Hospital, Beijing, China*
²*Medical College of Nan Kai University Tianjin, Tianjin, China*

- 0270 Novel Temporary Endovascular Shunt Technique to assist in situ Fenestration for Endovascular Reconstruction of the Distal Aortic Arch
Jiang Xiong, Wei Guo, Xiaoping Liu, Xin Jia, Xiaohui Ma, Lijun Wang
Department of Vascular Surgery, Vascular Center of Military, Chinese PLA General Hospital, Beijing, China
- 0277 Hybrid Treatment of Aortic Arch Disease with Ascending Aorta to Carotid Artery Revascularization and Subsequent Endovascular Repair
Mian Wang, Guang-Qi Chang, Shen-Ming Wang, Heng-Hui Yin, Chen Yao, Jin-Song Wang, Song-Qi Li
Department of Vascular Surgery, the First Affiliated Hospital, Sun Yat-Sen University, Guangzhou, China

Thoracic Aorta Disease 2

Session Code: FP7C
1600-1730, 6 September
Function Room 1, 2/F

- 0131 Influence of Operative Strategy for Acute Aortic Dissection Type A
Kouji Shimizu, Teiji Oda, Syouichi Suehiro
Shimane University, Izumo City, Shimane Prefecture, Japan
- 0173 Early and Mid-term Outcome of TEVAR in Complicated Type B Dissection
Randolph Wong¹, Simon Yu², YH Lam³, James Lau³, CM Chu², Innes Wan¹, Song Wan¹, Malcolm Underwood¹
¹*Division of Cardiothoracic Surgery, The Chinese University of Hong Kong, Shatin, Hong Kong, Hong Kong*
²*Department of Imaging and Interventional Radiology, Shatin, Hong Kong, Hong Kong*
³*Division of Vascular Surgery, Shatin, Hong Kong, Hong Kong*
- 0190 Long Term Results of Endovascular Treatment of Traumatic Thoracic Aortic Injuries. Single Center Experience
Abdelrahman Elkaiyal, Saud AlTurki, Hussin AlKohlani, Abdullah AlWahbi
King Fahd National Guard Hospital, Saud Bin Abdulaziz University for Health Sciences, Riyadh, Saudi Arabia
- 0208 Single-Stage Surgical Management for Complicated Thoracic Aortic Aneurysm Via Semi-Clamshell Approach
Hiroshi Furukawa, Takeshi Honda, Noriaki Kuwada, Hiroki Takiuchi, Takahiko Yamasawa, Yoshiko Watanabe, Yasuhiro Yunoki, Atsushi Tabuchi, Hisao Masaki, Kazuo Tanemoto
Kawasaki Medical School, Kurashiki, Japan
- 0230 Septal Defect Occluders Plus Bare Stents as Adjunctive Measure of TEVAR in the Treatment of Stanford B Aortic Dissections with Distal Tears at Visceral Branch Area
Jun Zhao¹, Qingsheng You², Jiakai Mei¹, Mingzhe Shao¹, Ye Pan¹, Jian Zhang¹, Haisheng Wu¹
¹*Vascular Surgery Division, General Surgery Department, 6th Affiliated People's Hospital of Shanghai Jiaotong University, Shanghai, China*
²*Cardiovascular Surgery Department, Affiliated Hospital of Nantong University, Nantong, China*
- 0245 Endovascular Repair of Malperfusion in Acute Type B Aortic Dissections
Weimin Zhou, Wei Zhou, Jiehua Qiu, Qingwen Chen, Feng Chen, Jixin Xiong
Department of Vascular Surgery, the Second Affiliated Hospital of Nanchang University, Nanchang, China

- 0268 The Misunderstanding and Comprehension of Hybrid Operation for Treating Aortic Dissection Involving Aortic Arch
Hao Ren, Hong-bo Ci, Sheng Guan, Qing-bo Fang, Sailimu, Xiao-hu Ge
Department of Vascular Surgery, The People's Hospital of Xinjiang Uigur Autonomous Region, Urumchi, China
- 0275 Occlusion of the True Lumen with the Stanford B Type Aortic Dissection
Hong-bo Ci, Guang-lei Tian, Jia Re Ke Tang, Hao Ren, Qing-bo Fang, Sheng Guan, Xiao-hu Ge
Division of Vascular Surgery, The People's Hospital of Xinjiang Uigur Autonomous Region, Urumchi, China

Abdominal Aortic Aneurysms 2

Session Code: FP8C
0830-1000, 7 September
Function Room 1, 2/F

- 0096 Stentgraft Limb Occlusion after EVAR
Naoki Hayashida, Souichi Asano, Nobuyuki Hirose, Takako Nishino, Masanao Ohba, Masashi Kabasawa, Tomonori Sueta, Hiroyuki Kito, Kouzou Matsuo, Hirokazu Murayama
Chiba Cerebral and Cardiovascular Center, Chiba, Japan
- 0171 Post EVAR Common Iliac Artery Enlargement after Flared Iliac Limb Stent-Graft
Wai Hong Chan¹, Yin Chun, Skyi Pang¹, Kin Leung, Edward Hui², Ling Chu, Renny Yien¹, Chung Ngai Tang¹
¹*Pamela Youde Nethersole Eastern Hospital, Hong Kong, Hong Kong*
²*Ruttonjee Hospital, Hong Kong, Hong Kong*
- 0179 Surgical Outcome of Aortic Aneurysm Repair: A Single Center Experience
Cristina Marie Lajom, Aries Garin, Pio Purino, Josefino Sanchez, Alexander Lat, Lara Lapena-Kare
University of Santo Tomas, Manila, Philippines, The Philippines
- 0206 Results of Small Abdominal Aortic Aneurysm Surveillance
Seoung-Wook Choi, Seon-Hee Heo, Yung-Seok Park, Yang-Jin Park, Dong-Ik Kim, Young-Wook Kim
Division of Vascular Surgery, Department of Surgery, Samsung Medical Center, Sungkyunkwan University School of Medicine, Seoul, Republic of Korea
- 0223 The Research on the Effect of Hyperhomocysteinemia on Abdominal Aortic Aneurysm
Jie Liu, Wei Guo, Xin Jia, Hongpeng Zhang, Senhao Jia, Minhong Zhang
Department of Vascular Surgery Chinese PLA General Hospital, Beijing, China
- 0246 Characters of complications in endovascular repair of abdominal aortic aneurysms in high-risk patients
Hejie Hu, Zhengdong Fang, Xiaotian Wang, Can Cheng, Xiaojie Sun
Department of vascular surgery, Anhui Provincial Hospital, Hefei Anhui province, China
- 0247 Open and endovascular management of isolated iliac artery aneurysms
Zhengdong Fang, Hejie Wu, Xiaotian Wang, Can Cheng, Xiaojie Sun
Department of vascular surgery, Anhui Provincial Hospital, Hefei Anhui province, China
- 0261 Open Repair of Abdominal Aortic Aneurysm: 10 Years Experience in a Single Center
Ding Yuan, Jichun Zhao, Yukui Ma, Bin Huang, Yi Yang, Fei Xiong, Guojun Zeng, Xiyang Chen
Division of Vascular Surgery, West China Hospital, Sichuan University, Sichuan University, Sichuan, China

Asian Venous Forum: Varicose Vein

Session Code: FP8D
0830-1000, 7 September
Function Room 2, 2/F

- 0031 Non-invasive Evaluation of Venous Flow Parameters in Normal Limbs and Limbs with Primary Varicose Veins in Malaysia
Sheau Wann Tong^{1,2}, Zainal Ariffin Azizi²
¹University Putra Malaysia, Selangor, Malaysia
²Hospital Kuala Lumpur, Kuala Lumpur, Malaysia
- 0069 Clarivein, A New Mechanochemical Endovenous Ablation Tools—Outcomes from 6 Months Cohort
Kwok Fai Cheung, Po Yan Wong, Wai Yin Lo, Kwong Man Chan, Leung Sing Ho
Princess Margaret Hospital, Hong Kong, Hong Kong
- 0077 Assessment of Great Saphenous Vein (GSV) Reflux during Temporary Interruption of Reflux to the Calf with Tourniquet Occlusion
Tomohiro Ogawa, Shunichi Hoshino
Fukushima Daiichi Hospital, Fukushima, Jersey
- 0102 The Effect and Complications of Femoral and Saphenous Nerve Blocks in Ambulatory Great Saphenous Vein Surgery
Koji Shinozaki, Tomohiro Katayama, Takaaki Ishii, Ken Tono, Yasuhito Kawasaki, Minoru Otsuru, Kensaku Mayumi, Ryosuke Fukuoka, Jyunji Nishiyama, Taku Mayahara, Seiji Yasuda
Kobe Ekisaikai Hospital, Kobe/Hyogo, Japan
- 0143 Factors of Venous Occlusion and Complications in Endovenous Laser Ablation for Varicose Veins
Dong-ik Kim, Yang-Jin Park, Young-Wook Kim, Yoong-Seok Park
Samsung Medical Center, Sungkyunkwan University, Seoul, Republic of Korea
- 0188 A Novel Technique for Sural Nerve Protection during Short Saphenous Vein Endothermal Ablation
Juefei Feng¹, Huimin Liu¹, Sriram Narayanan^{1,2}
¹Tan Tock Seng Hospital, Singapore, Singapore
²National University of Singapore, Singapore, Singapore
- 0189 Anterior Accessory Saphenous Vein—To Treat or Not to Treat
Huimin Liu¹, Yewfah Fong¹, Sriram Narayanan^{1,2}
¹Tan Tock Seng Hospital, Singapore, Singapore
²National University of Singapore, Singapore, Singapore
- 0216 Comparison of Clinical Results of Unilateral and Bilateral Ablations for Varicose Veins
Jin Hyun Joh, Ho-Chul Park, Jung-Hyun Choi
Kyung Hee University Hospital at Gangdong, Seoul, Republic of Korea

Lower Limb Arterial Occlusive Disease 1

Session Code: FP8E
0830-1000, 7 September
James Kung Meeting Room, 2/F

- 0024 Preoperative Evaluation and Revascularization of the Coronary Artery in Patients with Critical Limb Ischemia
Ryosuke Taniguchi, Kunihiro Shigematsu, Toshiaki Watanabe
Division of Vascular Surgery, The University of Tokyo, Tokyo, Japan

- 0105 Successful Limb Salvage Relating to Wound Location, Infection and Revascularization for Critical Limb Ischemia Patients
Arunesh Majumder^{1,2}, Jackie Ho Pei¹
¹National University Hospital, Singapore, Singapore
²Khoo Teck Puat Hospital, Singapore, Singapore
- 0111 Early Experience of Combined Maggot Debridement Therapy and Negative Pressure Wound Therapy to Heal Wounds in Critical Limb Ischemia Patients after Revascularization
Amritpal Singh, Jackie Pei Ho
 National University Hospital, Singapore, Singapore
- 0121 Mean Platelet Volume as a Predictor of Peripheral Arterial Disease (PAD): A Systematic Review and Meta-analysis
Chumpon Wilasrusmee^{1,3}, Boonying Siribumrungwong^{2,3}, Suthas Horsirimanont¹, Napaphat Poprom¹, Chakrapan Jirasiritham¹, Jarim Wongserepipatana¹, Ammarin Thakkestian³
¹Department of Surgery, Faculty of Medicine, Ramathibodi Hospital, Mahidol University, Bangkok, Thailand
²Department of Surgery, Faculty of Medicine, Thammasat University Hospital, Thammasat University, Pathumthani, Thailand
³Section for Clinical Epidemiology and Biostatistics, Faculty of Medicine, Ramathibodi Hospital, Mahidol University, Bangkok, Thailand
- 0128 Midterm Outcome of Femoral Artery Stenting for Chronic Atherosclerotic Occlusions
Hyun Jun Ahn¹, Keun-Myoung Park¹, Yong Sun Jeon², Soon Gu Cho², Tae Hyun Kong¹, Pil Ho Han¹, Jang Yong Kim³, Kee Chun Hong¹
¹Department of Surgery, Inha University Hospital, Incheon, Republic of Korea
²Department of Radiology, Inha University Hospital, Incheon, Republic of Korea
³Department of Surgery, College of Medicine, The Catholic University of Korea, Seoul, Republic of Korea
- 0232 Popliteal Artery Embolization in Superficial Femoral Artery Interventions: Incidence, Risk Factors, Treatment and Prognosis
Wei-wei Wu, Su-rong Hua, Chang-wei Liu, Yong-jun Li, Wei Ye, Bao Liu, Xiao-jun Song, Rong Zeng
 Department of Vascular Surgery, Peking Union Medical College Hospital, Chinese Academy of Medical Science, Beijing, China
- 0235 Factors Related to the Quality of Pedal Arch in Patients with Critical Limb Ischemia Suffering from Ischemic Ulcer
Hui Xie, Meng Ye, Jia-quan Chen, Lei LV, Kai Yuan, Ji-Wei Zhang, Lan Zhang
 Department of Vascular Surgery, Renji Hospital, Shanghai Jiao Tong University School of Medicine, Shanghai, China
- 0238 Primary Stenting for Symptomatic Patients with Superficial Femoral Atherosclerotic Lesions: A Multicenter Trial in the Mainland of China
 Danming Wu, Yubin Zhou, Haitao Tang
 Department of Vascular Surgery, the People's Hospital of Liaoning Province, Shenyang, China
- 0251 Imaging Diagnosis and Surgical Treatment of Popliteal Artery Entrapment Syndrome
Maohua Wang, Xing Jin, Xuejun Wu, Jingyong Zhang
 Department of Vascular Surgery, Shandong Provincial Hospital Affiliated to Shandong University, Jinan, China

Carotid Disease

Session Code: FP9D
 1030-1200, 7 September
 Function Room 2, 2/F

- 0085 Carotid Endarterectomy versus Carotid Artery Stenting for Patients with Carotid Restenosis after Carotid Endarterectomy: Systematic Review and Meta-analysis
Siwen Wang, Jian Tu, Zijun Huo, Ridong Wu, Chen Yao, Jingsong Wang, Henghui Yin, Guangqi Chang, Shenming Wang
 Department of Vascular and Thyroid Surgery, the First Affiliated Hospital of Sun Yat-sen University, Guangzhou, China

- 0204 Results of Carotid Endarterectomy (CEA): CEA Only Group vs. Combined CEA and Coronary Artery Bypass Grafting (CABG) Group
Youn-Jung Kim, Shin-Young Woo, Yang-Jin Park, Dong-Ik Kim, Young-Wook Kim
Division of Vascular Surgery, Department of Surgery, Samsung Medical Center, Sungkyunkwan University School of Medicine, Seoul, Republic of Korea
- 0234 Clinical Experience of Carotid Endarterectomy Combined Coronary Artery Bypass Grafting on Patients with Carotid and Coronary Artery Severe Stenosis
Peng Liu, Zhi-dong Ye, Xue-qiang Fan
Department of Cardiovascular, Chian-Japan Friendship Hospital, Beijing, China
- 0254 Treatment of Severe Cerebral Ischemia in Takayasu's Disease with Arterial reconstruction
Yongquan Gu, Jian Zhang, Zhonggao Wang
Department of Vascular Surgery, Xuanwu Hospital & Vascular Surgery Institute, Capital Medical University, Beijing, China
- 0267 Clinical Analysis of 60 Cases in Carotid Endarterectomy of Carotid Stenosis
Hong-bo Ci, Hao Ren, Guang-lei Tian, Jia Re Ke Tang, Feng Zhu, Bing Zhu, Sheng Guan, Xiao-hu Ge
Division of Vascular Surgery, the People's Hospital of Xinjiang Uigur Autonomous Region, Urumchi, China

Lower Limb Arterial Occlusive Disease 2

Session Code: FP9E

1030-1200, 7 September

James Kung Meeting Room, 2/F

- 0134 Carbon Dioxide as the Primary Contrast Media in Endovascular Therapy for Preventing Renal Complications
Tapish Sahu, Vivek Anand, Vishnu M, Sumanth Raj, K.R. Suresh
JIVAS, Bangalore, India
- 0142 Early Results of Stem Cell Therapy in Peripheral Arterial Occlusive Disease
Dong-ik Kim
Samsung Medical Center, Sungkyunkwan University, Seoul, Republic of Korea
- 0155 Autologous Bone Marrow Stem Cell Therapy in Peripheral Arterial Disease (ABMMSC)—Results From A Pilot Clinical Service in Singapore
Zhimin Lin², Siew Ping Chng¹, Jack Kian Ch'ng¹, Seck Guan Tan¹, Benjamin, Soo Yeng Chua¹
¹*Singapore General Hospital, Singapore, Singapore*
²*National University of Singapore, Yong Loo Lin School of Medicine, Singapore, Singapore*
- 0156 Clinical Outcome of Asian Severe Limb Ischemia Patients with Chronic Total Occlusion of the Lower Limb Arterial System
Kyi Zin Thant¹, Goh Chin Hock, Jason², Ho Pei, Jackie^{3,4}
¹*Department of Surgery, National University of Singapore, Singapore, Singapore*
²*Yong Loo Lin School of Medicine, National University of Singapore, Singapore, Singapore*
³*Department of Surgery, National University of Singapore, Singapore, Singapore*
⁴*Department of Cardiac, Thoracic and Vascular Surgery, National University Health System, Singapore, Singapore*
- 0159 Reduced Amputation Rate with Isovolemic Hemodilution in Critical Limb Ischemia Patients
Doosang Kim¹, Daniel Cho², Young I Cho³
¹*Veterans Health Service Medical Center, Seoul, Republic of Korea*
²*Rheovector LLC, Pennsauken, NJ, USA*
³*Drexel University, Philadelphia, PA, USA*

- 0191 Retrograde Tibial Surgical Approach Assisting Antegrade Approach for Recanalization of Peripheral Artery Complex Chronic Total Occlusions (CTOs)
Gangzhu Liang, Fuxian Zhang, Hui Zhao, Xiaoyun Luo, Changming Zhang, Lu Hu, Yaping Feng,
 Luyuan Niu, Huan Zhang, Long Cheng,
Beijing Shijitan Hospital, Capital Medical University, Peking, China
- 0212 Catheter-directed Thrombolysis assisted Angioplasty for Chronic Lower Limb Ischemia
Fuxian Zhang
Beijing Shijitan Hospital Affiliated to Capital Medical University, Beijing, China
- 0278 The Efficacy Analysis of Re-Intervention Treatment for SFA In-stent Restenosis
 Xue-qiang Fan, Zhi-dong Ye, Peng Liu, Jie Chen, Xia Zheng, Ya-nam Zhen, Bo Ma,
 Jiang-tao Liu, Yu-guang Yang, Song-yi Qian, Fei Wang, Fan Lin, Shi-yan Ren
Department of Cardiovascular, Chian-Japan Friendship Hospital, Beijing, China

Access

Session Code: FP10D
 1330-1500, 7 September
 Function Room 2, 2/F

-
- 0003 Brachial-jugular Prosthetic Vascular Access for Hemodialysis: Results from a Single-center Study
Sangchul Yun, Dan Song, Seok Han
Soonchunhyang University Seoul Hospital, Seoul, Republic of Korea
- 0005 Incidence and Risk Factors of Asymptomatic Central Vein or Proximal Vein Stenosis in Acute Arteriovenous Graft and Fistula Thrombosis in Dialysis Patients
Kwanchai Lawanwong, Wiwat Tirapanich, Sopon Jirasiritham, Surasak Leela-Udomlipi, Piyanut Pootrakool,
 Suthas Horsirimanont, Panuwat Lertsithichai
Vascular and Transplantation Division, Department of Surgery, Ramathibodi Hospital, Faculty of Medicine, Mahidol University, Bangkok, Thailand
- 0057 Transposed Basilic Vein Arteriovenous Fistula in Access Challenging Patients
BDK Leong, AA Zainal, H Hanif, MT Hafizan, SK Lee, G Naresh, P Kumaraguru,
 A Faidsal, M Ashraf, KL Tan
Kuala Lumpur Hospital, Kuala Lumpur, Malaysia
- 0080 On Postoperative Day Balloon Angioplasty for Salvage of Newly-placed, Flow-limiting Native Arteriovenous Fistula
Jae Young Park, Chang Hyun Yoo
Busan Vascular Clinic, Busan, Republic of Korea
- 0108 Evaluation of the Effect of Papaverine on the Hemodialysis Fistula Maturation Outcomes
Gholamhossein Kazemzadeh, Reza Manani, Emad Ebrahimi
Vascular and Endovascular Surgery Research Center, Imam Reza Hospital, Mashhad University of Medical Sciences, Iran
- 0144 Correlation between Preoperative Peak-to-Peak Pulsatility Index of Brachial Artery and Maturation of Native Brachio-Cephalic Fistula
Naresh Govindarajanthran, Mohd. Auri Jamaludin, Zainal Ariffin Azizi
Kuala Lumpur Hospital, Kuala Lumpur, Malaysia
- 0198 Banding for Access Related Ischaemia: Our Experience in Kuantan, Malaysia
Mohd Norhisham Azmi Abdul Rahman, Ahmad Faizal Othman
Vascular Unit, Department of Surgery, Kuliyah (Faculty) of Medicine, International Islamic University Malaysia, Kuantan, Pahang, Malaysia

Miscellaneous

Session Code: FP10E

1330-1500, 7 September

James Kung Meeting Room, 2/F

- 0016 Effects of Vacuum Therapy-vacumed on Skin Microcirculation in Patients Suffering from Diabetic Foot Ulcer in Context of TcPO₂ & Wound Healing
Sandeep Raj Pandey
Norvic Int'l Hospital, Kathmandu, Nepal
- 0041 Overview of Upper Limb Ischemia
Mi-ju Bae, Sung Woon Chung
Pusan National University Hospital, Department of Thoracic and Cardiovascular Surgery, Busan, Republic of Korea
- 0126 Clinical Study of Acute Limb Ischemia: Thrombectomy with Direct Thrombolysis Under the Mobile C-arm
Ji Ho Lee, Hyuk Jae Jung, Sang Su Lee
Pusan National University Yangsan Hospital, Yangsan, Gyeongnam, Republic of Korea
- 0127 Initial Experience of Rheolytic Thrombectomy with Solent Omni Peripheral Catheter
Jang Yong Kim, Kang-Woong Jun, Mi Hyoung Kim, Ji Il Kim, Sang Seob Yun,
In Sung Moon, Sang Dong Kim, Sang Hyun Ahn, Sun Chul Park
The Catholic University of Korea, Seoul, Republic of Korea
- 0136 Clinical Efficacy of Endovascular Therapy for Patients with Upper Limb Ischaemia
Tapish Sahu, Vivek Anand, Vishnu M, Sumanth Raj, KR Suresh
JIVAS, Bangalore, India
- 0145 Factors Affecting Outcome in Popliteal Artery Injuries
Alduz Cabasa, Leoncio Kaw, Jr.
University of the Philippines, Philippine General Hospital, Manila, The Philippines
- 0169 Results of Elective and Emergency Surgical Repair of Popliteal Artery Aneurysms
Mari Sakai, Atushi Omura, Hitoshi Minami, Hirohisa Murakami, Hitoshi Matsuda, Masato Yoshida,
Nobuhiko Mukohara
Hyogo Brain and Heart Center, Himeji/Hyogo, Japan
- 0185 Lower Extremity Arterial Injuries; How Functional are the Salvaged Limbs?
Zia Ur Rehman, Ziad Sophie, Lekhraj Mal
The Aga Khan University Hospital, Karachi, Pakistan
- 0241 Endovascular Therapy for Complication of Transplant Renal Artery
Zhaohui Hua, Zhen Li, Pengxu Ding, Zhiwei Wang, Wenguang Zhang, Peng Xu, Shirui Liu,
Zhiwei Wu, Zhonggao Wang
Department of Endovascular, the First Affiliated Hospital of Zhengzhou University, Zhengzhou, China
- 0260 Initial and Middle-term Outcome of Treatment for Isolated Dissection of Superior Mesenteric Artery
Zilun Li, Chen Yao, Henghui Yin, Jinsong Wang, Guangqi Chang, Shenming Wang
Division of Vascular Surgery, the First Affiliated Hospital, Sun Yat-sen University, Guangzhou, China
- 0276 Diagnosis and Treatment of Arterial Injuries in Extremities (An Analysis of 106 Cases)
Li-mu Sai, Hong-bo Ci, Guang-lei Tian, Hao Ren, Li-Mujian A, Bing Zhu, Sheng Guan,
Xiao-hu Ge
Division of Vascular Surgery, the People's Hospital of Xinjiang Uigur Autonomous Region, Urumchi, China

Best Paper Session

Session Code: FP3C

1530-1700, 5 September

Function Room 1, 2/F

0017

The Difference in the Methods and the Results of Subfascial Endoscopic Perforator Surgery, between Europa, North America, and Japan

Hitoshi Kusagawa¹, Yasuhisa Ozu¹, Kentaro Inoue¹, Takuya Komada¹, Yoshihiko Katayama¹, Naoki Haruta²

¹Matsusaka Chuo General Hospital, Matsusaka, Mie, Japan

²Takano-bashi Central Hospital, Hiroshima, Japan

Background: In Japan, Subfascial Endoscopic Perforator Surgery (SEPS) was accepted as a national advanced medical system by the Ministry of Health, Labor and Welfare in May 2009. Moreover, SEPS was accepted as a medical service under health insurance by the Ministry in April 2014, because more simple and easier method than classical SEPS in North America and Europa was developed and performed by the members of Japanese SEPS studying group (JSEPS).

Methods: The methods and the results of SEPS in Japan were evaluated, compared with those in North America and Europa. The importance of SEPS as an alternative therapy was discussed based on the Japanese medical system.

Results: In Japan, most of SEPSs were performed by two-port system using 6 mm sized screw-type ports introduced by Haruta. This method has never been tried in the other countries than Japan, and it is characterized by CO₂ not leaking out of the subfascial space without using a tourniquet. As a result, the visual field becomes much better with the lower CO₂ pressure than the classical SEPS, and the technic of SEPS became more simple and easier. More than 2500 of SEPS were performed in Japan, while 1140 in the other countries. According to the data which a part of the members of JSEPS performed or published in each so far in Japan, primary ulcer healing rate (PUHR) was 90–100%, ulcer recurrence rate (URR) was 2.5% (mean f/u; 18 months) to 8.3% (mean f/u; 59 months). In the other countries, PUHR was 88% and URR was 13% (mean f/u 21 months).

Conclusion: The methods and the results of SEPS in Japan were different from those in the other countries and SEPS was an important alternative therapy in Japan. JSEPS is now accumulating the whole data and is going to analyze the result in detail.

0082

Our Experience of Type II Endoleaks of Lumbar Artery after Endovascular Repair of Abdominal Aortic Aneurysm

Shintaro Shibutani¹, Hideaki Obara², Hirotoki Ohkubo¹, Shinobu Hayashi¹, Kentaro Matsubara², Yuko Kitagawa²

¹Department of Vascular Surgery, Saiseikai Yokohamashi Tobu Hospital, Yokohama, Kanagawa, Japan

²Department of Surgery, Keio University School of Medicine, Shinjuku, Tokyo, Japan

Background and Objectives: Endovascular aneurysm repair (EVAR) has been widely used as abdominal aortic aneurysms (AAAs) treatment. Endoleaks remain among the most common complications of EVAR. Many type II endoleaks will seal spontaneously over time and conservative management is justified in most cases. Indications for intervention for type II endoleaks remain controversial. The purpose of our investigation was to access the outcome of type II endoleaks of lumbar artery in our patients.

Methods: From February 2008 to July 2013, 762 patients underwent EVAR in our institutions.

Results: There were 167 type II endoleaks (21.9%) with a median follow-up of 30 months. Of 167 patients, 27 (16.2%) had expansion of the aneurysm of 5 mm or more. Three patients (11.1%) with expansion of the aneurysm of 5 mm or more due to type II endoleak of lumbar artery had ruptured AAA. The sizes of their aneurysm sac were 90 mm or more. One of these had ruptured despite underwent coil embolization for lumbar artery and had conversion to open surgical repair. The other cases were still alive despite no treatment for ruptured AAA. There was no death due to type II endoleak of lumbar artery.

Conclusions: Ruptured aneurysm after EVAR with expansion of the aneurysm of 5 mm or more due to type II endoleak of lumbar artery appears to be not so rare. But the patient with ruptured aneurysm due to lumbar type II endoleak would not die. The management of type II endoleak of lumbar artery remains controversial.

0152

Effectiveness and Durability of Open Repair of Abdominal Aortic Aneurysm in Octogenarians

Lee KF, Chan YC, Law Y, Yip HC, Ting AC, Cheng SW

Division of Vascular & Endovascular Surgery, Department of Surgery, University of Hong Kong Medical Centre, Pokfulam, Hong Kong, Hong Kong

Background and Objectives: Open repair of abdominal aortic aneurysm in patients more than 80 years of age may be associated with higher peri-operative risks. The aim of this study is to present the short and long term outcomes of open repair of aortic aneurysm in octogenarians at our institution.

Methods: Consecutive patients aged between 80 and 89 who underwent elective or emergency open repair of aortic aneurysm in a tertiary referral centre were identified from a prospectively collected departmental database. Patient demographics, pre-morbid conditions, peri-operative outcomes and long term survival were analysed. Logistic regression was used to identify predictors for surgical mortality.

Results: From a cohort of 512 patients who underwent open repair of abdominal aortic aneurysm from July 1990 until June 2012, 78 (15%; 54 males) were aged between 80 and 89 (1 suprarenal, 3 pararenal, 4 juxtarenal, 70 infrarenal) of whom 45 and 33 were elective and emergency procedures respectively. For elective procedures, the 30-day mortality was 4.4%, whilst emergency procedures had a 30-day mortality of 45.5% (χ^2 test: $p < 0.001$). Upon multivariate analysis, rupture of aneurysm (OR 7.2, 95% confidence interval 1.5–34.2, $p = 0.012$) was the only independent predictive factors of surgical mortality. The 3-year overall survival with Kaplan-Meier analysis were 62.8% and 30.3% for elective and emergency procedures respectively (Log rank test: $p < 0.001$). On long-term follow-up, only one patient had re-intervention 23 months later, which resulted in our only aneurysm-related late mortality.

Conclusions: Our study shows that open repair of aortic aneurysms in octogenarians is safe and effective, with a low 30-day elective mortality of 4.4%. Only one patient had aneurysm-related late mortality.

0172

Impact of Selective Antegrade Cerebral Perfusion on Type A Dissection Repair

Randolph Wong, Rainbow Lau, Micky Kwok, Herman Chan, Eugene Yeung, Calvin Ng, Innes Wan, Song Wan, Malcolm Underwood

Division of Cardiothoracic Surgery, The Chinese University of Hong Kong, Shatin, Hong Kong, Hong Kong

Objective: To evaluate the impact of intra-operative selective antegrade cerebral perfusion (ACP) on the outcome of surgical repair of type A aortic dissection.

Method: Demographic data of patients undergoing emergency and urgent surgical repair for type A aortic dissection from Jan 2009 to Apr 2014 were prospectively collected by a research assistant. Intra-operative ACP usage was at the discretion of the operating surgeon and it was adopted only after year 2010. Outcomes including mortality, ICU and hospital stay were records and compared between the ACP group and no ACP (NACP) group.

Results: A total of 102 patients were included during the study period. The median age of our patients is 59 (37–84) year-old. There were 12 aortic root replacement, 70 ascending aortic replacement, 12 hemiarch replacement and 8 total arch replacement. ACP were carried out in 37 patients (36.3%) and they included 8 (100%) of arch replacement, 8 (66.7%) of hemiarch, 18 (25.7%) ascending and 3 (25%) root replacement patients. 50% of arch surgeries were re-operation. There were 2 (5.4%) patients developed stroke in

ACP group and 9 (13.9%) developed stroke in NACP group, $p = 0.32$. There were total 15 (14.7%) in-hospital mortality within our cohort, these included 3 (8.1%) in ACP group and 12 (18.5%) in no ACP group, however, the difference did not reach statistical significance. The difference between ACP and NACP groups in median operative duration, ICU stay, time to extubation and post-operative stay were 410 min vs 382.5 min, 3 days vs 4 days, 39.2 hours vs 39.1 hours and 14.5 days and 16 days respectively.

Conclusion: The overall mortality of type A dissection repair is in par with international standard and patients with selective antegrade perfusion is associated with lower risk of stroke and less mortality although not reaching statistical significance.

0186

Ethnic Variation in the Anatomy of the Saphenous Fascia in South Asian Populations

Ming Yuan Tan¹, Yewfah Fong¹, Sriram Narayanan^{1,2}

¹Tan Tock Seng Hospital, Singapore, Singapore

²National University of Singapore, Singapore, Singapore

Background: Endothermal ablation of the great saphenous vein (GSV) is a common procedure. The GSV is enveloped within the saphenous fascia that is described variously as extending from the inguinal venous confluence to the ankle. We describe our observations regarding ethnic variations in saphenous fascia anatomy on ultrasound scanning.

Methods: The extent of the fascia around the GSV on ultrasound scanning (USS) was recorded during 442 consecutive endovenous radiofrequency procedures for GSV incompetence. The fascia was mapped from the groin to the medial malleolus and adjudged as complete if seen to be fully formed from the groin to the ankle, incomplete if present only in the above knee segment and absent if not identified at all. Patients were classified into Chinese, Indian, Malay, Caucasian and Mixed ethnicity.

Results: Fascial anatomy was recorded in 161 patients bilaterally (322 legs) and 120 unilaterally. The ethnic distribution of patients is shown in the table below. The figures in brackets indicate the number in whom the fascia was incomplete.

| Ethnicity | Bilateral | Unilateral |
|-----------|------------------------|------------|
| Chinese | 82 (left 76, right 78) | 56 (54) |
| Indian | 38 (left 26, right 25) | 41 (28) |
| Malay | 23 (left 11, right 11) | 13 (7) |
| Caucasian | 14 (left 2, right 1) | 7 (1) |
| Mixed | 4 (left 1, right 1) | 3 (1) |

95% of Chinese, 68% of Indian and 49% of Malay patients had a formed saphenous fascia only above the knee, compared to only 11% of Caucasian and 27% of patients of mixed ethnicity. A high degree of concordance was observed between the right and left sides in the anatomy of fascial distribution in all races. No patient was found to have absent saphenous fascia.

Conclusions: The saphenous fascia shows significant ethnic variations among Asian races compared to Caucasian patients. This has implications in the technique of administration of tumescent anaesthesia and prevention of peri-venous thermal injury during endothermal ablation.

0193

Practical Design for Fenestrated Stent-graft in Juxta-renal Aortic Aneurysm in Korea: Based on Anatomical Analysis

Kihyuk Park

Daegu Catholic University Hospital, Daegu, Republic of Korea

Endovascular repair for the juxta aortic aneurysm, fenestrated or scallop designed stent-graft could offer solution than regular devices. In Europe and US government approved fenestrated stent-graft is available now with standard shape. The purpose of this study is find out the anatomy around visceral arteries in abdominal aortic aneurysm (AAA) patients to be used basic data of asian version of fenestrated stent-graft design. We have evaluated 133 AAA patients by measuring anatomical characteristics using Aquarius (iNtution (version 4.4.6 Terarecon, Inc) workstation. We measured distance, diameter and orientation of celiac artery (CA), superior mesenteric artery (SMA), both renal arteries (RA). The distance between two renal arteries was 7.11 ± 5.9 mm, over 15 mm was found in 14 patients (10.6%). Between SMA and upper RA, mean distance was 12.6 ± 7.9 mm and over 15 mm was found in 16 (12.2%) patients. The diameter at the orifice was 6.0 ± 1.3 mm for SMA, 4.8 ± 1.2 mm for Right RA, 5.1 ± 1.4 mm for left RA. The distance between SMA-CA 15.1 ± 5.6 mm (Max 36.8 mm) and in 6 patient both arteries originated as common channel (4.5%). The orientation of branches at axial foot view, CA (23.1 degree), SMA (13.7), right RA (66.1), left RA (91.4). Considering 15 mm proximal neck over fenestration for sealing, one fenestration design for one renal artery, 89.4% of patients need additive procedure such as chimney technique to save opposite renal artery. Also 88% of patients need salvaging procedure for SMA, if two fenestration stent-graft was used of both RA such as scallop design of snorkel. 4.5% patients needs common channel design for SMA and CA common origin. The fenestration size for renal artery would be better in 5 mm for asian than 6 mm as US design. Finally if planning two renal chimney technique, 83.4% of Korean patients would be also required SMA salvaging procedure such as 3rd snorkel stent or scallop. This study has limitation because the patient were infrarenal AAA not juxta AAA but still could be used as basic data for further study.

0207

Impact of the Ischemic Heart Disease (IHD) on the Early Results of the Elective Abdominal Aortic Aneurysm (AAA) Repairs

Seoung-Wook Choi, Shin-Young Woo, Yang-Jin Park, Dong-Ik Kim, Duk-kyung Kim, Young-Wook Kim

Division of Vascular Surgery, Department of Surgery, Department of Internal Medicine, Samsung Medical Center, Sungkyunkwan University School of Medicine, Seoul, Republic of Korea

Purposes: The prevalence of ischemic heart disease (IHD) in the general population varies between the races or countries. We attempted to determine impacts of the IHD on the early results of the elective-treatment of abdominal-aortic-aneurysm (AAA).

Method: We reviewed database of AAA patients who underwent elective-open-surgical-repair (OSR) or endovascular-repair (EVAR) of AAA in a single-institute during the past-10-years. Ruptured-AAA ($n = 57$), AAA caused by other than degenerative etiology ($n = 48$) and redo-aortic-surgery ($n = 13$) were excluded from the study. Preoperative cardiac-risk-evaluation before elective-AAA-repair was performed using predetermined protocol. AAA patients were classified into 3 groups based on IHD: Control-group, asymptomatic-patients with no evidence of IHD on preoperative-evaluation: Group I, patients with past history of IHD who have been conservatively-treated without any coronary-intervention; Group II, patients who underwent coronary-intervention (PCI or CABG) and receiving subsequent-drug-therapy. The frequencies of IHD, early-postoperative (<30 days) acute-myocardial-infarction (AMI) and operative-mortality were investigated according to the groups and treatment type (OSR vs EVAR).

Results: Among 712 AAA repairs, 583 patients (median age, 70 years (41–91), male 87%, open repair ($n = 385$, 66%), EVAR ($n = 198$, 34%) were included for this study. IHD was detected in 203 (35%)-patients while 380 (65%)-patients do not have any evidence of IHD on preoperative-evaluations. Among IHD patients, 71 (12%)-patients were group I and 132 (23%)-patients were classified into group II. Postoperative-AMI developed in 6 (8.5%) in group I, 8 (6.1%) in group II and 10 (2.6%) in control-group ($p = 0.025$). Postoperative-AMI developed in 22 (5.7%) and 2 (1%) after OSR and EVAR respectively ($p = 0.007$). When considering IHD and treatment mode of AAA together, OSR in patient with group I showed significantly higher frequency of postoperative AMI compared to EVAR in control group (11.8% vs 1.4%, $p = 0.022$).

Conclusion: We found that 35% of Korean AAA patients who are undergoing elective-AAA-repair were accompanied with IHD. Risk of postoperative-AMI was significantly higher in patients with past history IHD who have been conservatively-treated without any coronary-intervention. But occurrence of postoperative-AMI was not necessarily correlated with operative-mortality.

Iliac Vein Compression Syndrome in a Non-vascular Related Symptomatic Patient Population

Fuxian Zhang

Beijing Shijitan Hospital Affiliated to Capital Medical University,
Beijing, China

Background: Iliac vein compression syndrome (IVCS) is characterized by left common iliac vein obstruction secondary to compression of the left iliac vein (LCIV) by the right iliac artery (RIA) against the fifth lumbar vertebra. This anatomic variant results in an increased incidence of left-sided deep vein thrombosis (DVT). However, the natural frequency of compression of the left iliac vein and its clinical significance in asymptomatic patients has not been established. The purpose of this study was to determine the incidence of IVCS in a non-vascular related symptomatic population.

Methods and Results: A total of 500 patients with non-vascular symptoms were evaluated in our study (228 women and 272 men; mean age 55.36 ± 14.67 years). A Brilliance iCT scanner was used in all cases, and the mean and minimum diameter of the LCIV was measured. Medical records were reviewed to judge whether patients had vascular related symptoms. The mean compression degree of the LCIV in the entire population was $21.5\% \pm 19.4\%$, and 37.8% of patients had a compression degree greater than 25% while 9.8% had greater than 50%. However, women had a greater mean compression degree of the LCIV and there was a significant difference between men and women ($17.82\% \pm 18.19\%$ vs. $25.9\% \pm 19.9\%$, $P < 0.01$). Meanwhile, the LCIV compression degree of the young female group had a statistically significant difference when compared with the middle-aged female group ($41.51\% \pm 16.51\%$ vs. $22.87\% \pm 19.10\%$, $P < 0.001$).

Conclusions: Left iliac vein compression is a frequent anatomic variant in asymptomatic individuals, especially in young women with a greater LCIV compression degree. This should have been brought to our attention in our clinical positions.

0250

The Outcome after Stenting of Ostial Lesions in Superficial Femoral Artery: A Discussion of Risk Factors and Reintervention

Jun-Hao Jiang, Jia-Ning Yue, Wei-Guo Fu, Yu-Qi Wang

Department of Vascular Surgery, Zhongshan Hospital, Fudan University, Shanghai, China

Background: For the ostial lesions of the superficial femoral artery (SFA), crossover stenting across the origin of the profound femoral artery (PFA) is commonly adopted. However, the outcome is uncertain. In this study, we observe the primary outcome after stenting of the SFA ostial lesions in a single center and also reported the reintervention results.

Methods: In the last 2 years, SFA stenting involving the bifurcation was proposed to 42 patients. Bifurcation patency, survival free from reintervention, and survival free from amputation rates were determined. Possible causes of stent occlusion in terms of lesion characteristics, stent placement pattern and stent sizing were analyzed based on imaging studies and interventional or surgical findings.

Results: The mean follow-up was 15 months (range, 3–22). At 1 year, primary and secondary bifurcation patency were 76% and 90%, target lesion revascularization free cumulative survival was 81%. In 8 reintervention cases, endovascular approach failed in all of the 4 cases, and technical success was obtained in all of the 6 patients undergoing surgical bypass. One major amputation was noted.

Conclusion: Stenting of the SFA ostial lesions seems to be a safe technique with acceptable clinical outcome at 1 year. Significant CFA and PFA occlusive lesions, jailed ostial SFA stenting and stent undersizing are possible factors contributing to loss of bifurcation patency after ostial stenting. Surgical repair has more favorable outcome than endovascular approach for the cases required reintervention for limb salvage.

Asian Venous Forum: Venous Thromboembolism

Session Code: FP4D

0830-1000, 6 September

Function Room 2, 2/F

0070

Incidence of Acute Pulmonary Embolism in Patients with Acute Deep Venous Thrombosis

Piyanut Pootracool, Sopon Jirasiritham, Wiwat Tirapanich, Surasak Leela-Udomlipi, Suthas Horsirimanont, Arkom Suesawatee

Vascular and Transplant Division Department of Surgery, Ramathibodi Hospital, Faculty of Medicine, Mahidol University, Bangkok, Thailand

Objective: To evaluate the incidence of acute pulmonary embolism (PE) in patients who had acute deep venous thrombosis (DVT). All of DVT patients was send for evaluate acute pulmonary embolism by pulmonary computed tomography angiography (CTPA) or lung perfusion scan if the patients had impairment of renal function.

Methods: Prospective study between June 2011 and December 2013, 79 patients with acute symptomatic lower limbs DVT were studied for incidence of acute pulmonary embolism. All patients were send for CTPA or lung perfusion scan for investigation of acute pulmonary embolism.

Results: Seventy – nine DVT patients, mean age 64.4 year-old developed acute PE 25. 9%. The incidence of PE in patients with femoral vein DVT is 19.7% ($p < 0.01$), incidence of PE in popliteal vein DVT is 15.3% ($p < 0.01$), incidence of PE in cancer patient is 9.1% ($p < 0.01$). The incidence of PE in femoropopliteal vein DVT is 22.3% ($p < 0.01$). No patients develop fatal PE.

Conclusions: The incidence of acute PE in symptomatic DVT is high. In femoral vein, popliteal vein DVT, and cancer patients are significant risk factor for develop acute PE ($p < 0.01$). From this result supports that the importance of venousthromboembolism prophylaxis should be considered especially in cancer patients. In the patients with femoropopliteal vein DVT should receive adequate treatment for prevent PE.

0081

Mean Platelet Volume as a Predictor of Venous Thromboembolism (VTE): A Systematic Review and Meta-Analysis

Chumpon Wilasrusmee^{1,3}, Boonying Siribumrungwong^{2,3}, Suthas Horsirimanont¹, Napaphat Poprom¹, Chakrapan Jirasiritham¹, Jarim Wongserpipatana¹, Ammarin Thakkinstian³

¹Department of Surgery, Faculty of Medicine, Ramathibodi Hospital, Mahidol University, Bangkok, Thailand

²Department of Surgery, Faculty of Medicine, Thammasat University Hospital, Thammasat University, Pathumthani, Thailand

³Section for Clinical Epidemiology and Biostatistics, Faculty of Medicine, Ramathibodi Hospital, Mahidol University, Bangkok, Thailand

Background: Platelet activity is a major devilish in atherothrombotic events. Mean platelet volume (MPV), which is widely available as a routine parameter of the complete blood count, is a potentially useful biomarker of platelet activity in the setting of venous thrombosis.

Aim: To determine whether an association exists between MPV and VTE.

Methods: A literature search of the MEDLINE and Scopus was performed to identify the association between MPV and VTE. Two reviewers independently extracted data. Differences in MPV were expressed as unstandardized mean difference.

Results: Among 403 articles identified, 10 studies (5 retrospective cohorts and 5 case controls) comprising 2,265 patients were eligible for pooling. MPV was significantly higher in those with VTE than those without VTE (mean difference 0.61 fL, 95% confidence interval (CI) 0.34–0.88, $P < 0.001$). Elevated MPV increased the relative risk of VTE as compared as normal MPV (RR1.319, CI 1.061–1.641, $I^2 = 82.5\%$).

Conclusions: The available evidence suggests that elevated MPV is associated with VTE. An updated meta-analysis and further elucidated mechanistic study are required in order to use in practice or guide therapy.

0195

Mid- and Long-term Outcome of Patients with Permanent Inferior Vena Cava Filters

Felix Che-lok Chow, Yiu Che Chan, Grace Cheung, Stephen Wing-Keung Cheng

The University of Hong Kong, Hong Kong, Hong Kong

Background: IVC filters are used to prevent pulmonary embolism (PE), especially in patients have active contraindication to anticoagulation. We aimed to investigate the outcomes of patients who received IVC filters in our institution.

Methods: Retrospective review of prospectively collected database on patients who had IVC filter was conducted. Patient demographics, indications of filter placement, post-procedure clinical outcome, as well as use of anticoagulant therapy were documented. Chi-square test was used to test for statistically significant differences, while survival was calculated using Kaplan-Meier survival curves analysis.

Results: Between February 1998 and December 2013, a total of 109 patients with a median age of 65 years had IVC filters inserted. All of them had documented venous thrombo-embolism (VTE) before filter placement: 90.8% had lower extremity DVT, 8.3% had massive PE without evidence of DVT and 0.9% had isolated IVC thrombosis. There were two serious procedure-related complications: one assess site thrombosis and one right ventricular perforation. With a mean follow-up of 36 ± 35 months, no patient had further symptomatic PE or paradoxical embolism. There were a total of 54 (49.5%) deaths, with a thirty-day mortality of 8.3%; none of them was device or procedure-related. Among the 92 patients followed up, twenty seven (29.3%) had further VTE – including 20 DVT and 14 filter/IVC thrombosis. Forty-one (44.6%) patients reported post-thrombotic syndrome (PTS) symptoms. Anticoagulant therapy was given to 39 (42.4%) and 55 (59.8%) patients in the peri-procedural period and at any time during the study period respectively. It did not reduce the rate of post-filter VTE or PTS in both instances.

Conclusion: This cohort study showed that patients who received permanent IVC filters have high mortality on follow-up, although none were procedure- or device-related. Although IVC filters were effective in the prevention of PE, persistent symptomatic VTE was common.

The Vena Tech LP Permanent Caval Filter: Effectiveness and Safety in the Clinical Setting in Three Chinese Medical Centers

Fuxian Zhang

Beijing Shijitan Hospital Affiliated to Capital Medical University, Beijing, China

Objective: The effectiveness, safety, and patient outcomes after Vena Tech LP caval filter placement were evaluated retrospectively in China.

Methods and Results: From January 2002 to January 2013, 1,200 patients received Tech LP caval filters to prevent PE at three Beijing University medical centers. The patients' general condition, reasons for DVT formation, filter placement method, indication for filter placement, complications, safety of the filter, treatment post-filter, and follow-up were recorded. The patients' mean age was 65 (range, 19–87) years, and 840 were males. Before filter placement, all had ultrasonic-diagnosed DVT, 84% (1008/1200) were assessed for PE, and 73% (736/1008) had PE. Filters were placed via the femoral or jugular vein, with 62 placements at the SVC and 1,138 at the IVC. Filter placement via various venous access routes was 100% successful. Anticoagulation therapy was continued in 88% patients (n = 1056) for ≥6 months after filter placement. Follow-up was accomplished in 80% (n = 960) of patients for an average of 6 years (range, 3 months to 10 years). The patency rate of the vena cava was 90% at 5 years. The morbidity was 2% and the mortality was 0.5% during 30 days post-filter placement. After 30 days, the mortality rate was 2.4%, no PE reoccurred, and there were no other clinical adverse events.

Conclusion: Vena Tech LP caval filter placement was effective and safe, with demonstrated stability and a good long-term patency rate at the IVC and SVC in China.

0242

Pre-dilatation techniques in Budd-Chiari syndrome with chronic inferior vena cava thrombus

Zhen Li, Pengxu Ding, Zhaohui Hua, Xinwei Han, Zhiwei Wang, *Wenguang Zhang*, Mingti Fu, Zhonggao Wang

Department of Endovascular, the First Affiliated Hospital of Zhengzhou University, Zhengzhou, China

The Interventional Treatment for Shunt Stenosis or Occlusion after Mesocaval Shunts in Portal Hypertension

Zhi-wei Wang, Zhen Li, Sheng Guan, Xiu-xian Ma

Department of Endovascular, the First Affiliated Hospital of Zhengzhou University, Zhengzhou, China

Objective: To explore the cause of artificial vessel stenosis or occlusion after mesocaval shunts, and analysis the feasibility and efficacy of percutaneous interventional therapy.

Methods: The clinical data of 19 cases of artificial vessel stenosis or occlusion after mesocaval shunts for portal hypertension in our department from March 2009 to March 2012 were retrospectively analyzed.

Results: In the 19 cases with artificial vessels stenosis or occlusion treated by mesocaval shunts for portal hypertension, 5 cases who got acute thrombosis within a week after the surgery were treated by catheter directed thrombolysis; 6 cases who got shunts stenosis for anastomotic stenosis of artificial vessel—superior mesenteric vein from 1 to 8 years after surgery, were cured by balloon dilatation or stent angioplasty. The shunts artificial vascular occlusion occurred in 8 cases from 1 to 4 years after surgery, 6 of which succeed to be patent by balloon dilatation or stent angioplasty, and 2 were failed for the guide wire can't go through the anastomotic site of artificial vessel—superior mesenteric vein. And 11 cases were associated with embolism of esophagogastric varices for postoperative standard anticoagulation. During the 3 month to 3 years follow-up period, one case had a recurrence 1 year later after balloon dilatation, with the shunt stenosis conformed by ultrasound, accepted stent angioplasty, and felt good in the next 5 month. And all the other cases had no recurrence.

Conclusions: Interventional radiological techniques by percutaneous puncture through “femoral vein-inferior vena cava-artificial vessel-portal vein” (including catheter directed thrombolysis, balloon dilatation, stent placement, etc.) are little trauma, highly successful and have a remarkable effect in the treatment of shunt stenosis or occlusion after mesocaval shunts in portal hypertension.

0271

Foam Sclerotherapy with Lauromacrogol for Varicose Veins: Analysis on 200 Cases

Sheng Guan, *Xiao-hu Ge*, Qing-bo Fang, Hao Ren, Li-Mujian A, Bin Zhu

Department of Vascular Center, People's Hospital of Xinjiang Uigur Autonomous Region, Urumchi, China

Objective: To investigate the efficacy of foam sclerotherapy by using lauromacrogol for varicose veins in the lower limbs.

Methods: During October 2012 to April 2014, we performed foam sclerotherapy on 200 patients (298 limbs) with lower limb varicos-

ity by using lauromacrogol. Lauromacrogol foam was made by extracting 10 ml of room air into 10 ml lauromacrogol with a 20-ml syringe and repeated aspiration to form small uniform foam. The efficacy of the therapy was followed up after the procedure.

Results: Re-examination in one week by palpation showed that all the varicose veins were sclerosed. Cure was defined as no complaints of obvious varicosity in three months.

Conclusion: Non-ultrasound-guided foam sclerotherapy is simple, effective, minimally invasive and safe.

0273

Varicose Vein Surgery without Antibiotic Prophylaxis: Experiences with 664 Patients in a Single Center

Zhoupeng Wu, Jichun Zhao, Bin Huang, Ding Yuan, Yi Yang, Guojun Zeng, Xiyang Chen

Department of Vascular Surgery, West China Hospital, Sichuan University, Chengdu, China

Objective: Our objective was to evaluate the outcome of varicose vein surgery without the use of prophylactic antibiotics. This study was held from January 2011 to August 2013 in our hospital.

Methods: A total of 664 varicose vein surgery patients were retrospectively reviewed and basic data were recorded, including age, sex, peri-operative antibiotic use, classification of the varicose, and post-operative complications. All the patients were underwent the the great saphenous vein for high ligation and varicose vein stripping. The drain was not routinely placed. Any complications were analyzed.

Results: A total of 392 (59%) females and 272 (41%) males were included, giving ratio of 1.44:1. The average age was 50.68 years. The mean operation time was 85.3 min. Classification including II 267 (40.2%), III 331 (49.8%), IV 47 (7.1%), V 17 (2.6%), VI 2 (0.3%). 106 had temporally nerve paralysis. 68 had subcutaneous induration, and only eight had wound infection (1.2%).

Conclusion: Antibiotic prophylaxis in varicose vein surgery is not an essential pre-operation preparation for all patients, if guidelines for antibiotic prophylaxis in clean surgery are adhered to and surgeons have sophisticated skills in the procedure.

Abdominal Aortic Aneurysms – 1

Session Code: FP4E

0830-1000, 6 September

James Kung Meeting Room, 2/F

0062

The Significance of Open Surgery of Abdominal Aortic Aneurysm in EVAR Era

Kiyohito Yamamoto, Kimihiro Komori, Hiroshi Narita, Hiroshi Banno, Akio Kodama, Masayuki Sugimoto

Nagoya University Graduate School of Medicine, Naogoa, Japan

Objectives: The principle for EVAR in our institution, patients more than 75 years old or with higher operative risk are candidates for EVAR. Patients less than 74 years old or unsuitable anatomy for EVAR are candidates for open repair (OR). The aim of this study was to compare the early and mid-term outcomes of EVAR versus open repair (OR) for AAA after EVAR was introduced to our institution.

Methods: Consecutive AAA patients treated with EVAR (n = 377) or OR (n = 321) from June 2007 to July 2013 were retrospectively examined.

Results: Thirty two (10.0%) patients in OR group received supra-renal aortic cross-clamping. The mean age, and respiratory function had significant difference (77.7 ± 6.5 vs 70.9 ± 7.1 years old, 103.3 ± 22.2 vs $106.6 \pm 20.8\%$: EVAR vs OR). The operation time, the amount of bleeding, and the duration of hospital stay were higher in the OR group than EVAR group. More patients with OR developed delirium, ischemic colitis, and intestinal obstruction perioperatively than EVAR group. Operative mortality was higher in OR than in EVAR (1.2 vs 0%). Postoperative complications in the EVAR group included graft occlusion (1.3%), type I endoleak (2.6%), aneurysm rupture (0.8%), graft infection (0.6%) that required further interventions. There were 11% with incisional hernia, 0.9% with anastomotic aneurysm in OR group. Kaplan-Meier analysis at 3 years indicated that cumulative re-intervention free rate (89 vs 93%), accumulated survival rate (90.4% vs 94%) and accumulated re-intervention free survival rate (98.4 vs 99%) had not shown significant difference between EVAR and OR.

Conclusions: EVAR was less invasive procedure than OR in the short term and patients with EVAR have similar re-intervention free survival rate with OR in the midterm. These results indicate that our patient selection and criteria for EVAR and OR was appropriate.

Persistent Type II Endoleak and Aneurysmal Sac Change after Endovascular Abdominal Aortic Aneurysm Repair

Takuro Shirasu, Katsuyuki Hoshina, Kunihiro Shigematsu, Toshiaki Watanabe

The University of Tokyo, Tokyo, Japan

Background: Aneurysmal sac shrinkage and enlargement following type II endoleak is one of the concerns after endovascular aneurysm repair (EVAR).

Method: All patients who received EVAR for abdominal aortic aneurysm in our hospital between February 2009 and September 2013 were retrospectively reviewed. Patients who were followed up with contrast-enhanced computed tomography (CT) for more than 6 months were included. One patient with type Ia endoleak was excluded. Univariate analysis was performed for analysis.

Result: Fifty one patients were included in the analysis. There were 28 patients (55%) who took antithrombotic agents such as aspirin, thienopyridine, cilostazol and warfarin. The number of patent lumbar arteries detected by the preoperative enhanced CT was 5.1 ± 2.0 . In the follow-up period of 26 ± 15 months, persistent type II endoleak (PT2, present after 6 months from EVAR) was confirmed in 23 patients (45%). Among the patients' characteristics, there were statistically significant differences in chronic obstructive pulmonary disease (COPD) and the number of patent lumbar arteries. Patients with PT2 had more patent lumbar arteries (5.7 ± 2.0 versus 4.6 ± 1.9 , $p = 0.04$) and less COPD (3, 13% versus 14, 50%; $p = 0.007$). In addition, patients taking antithrombotic agents and more than 6 patent lumbar arteries were revealed to have the significant risk for PT2 ($p = 0.002$). An absence of aneurysmal sac shrinkage (more than 4 mm reduction compared with a preoperative study) was associated with prior history of coronary artery disease ($p = 0.02$), intake of antithrombotic agents ($p = 0.0002$) and more number of patent lumbar arteries ($p = 0.046$). On the other hand, aneurysmal sac enlargement (more than 4 mm expansion) with PT2 was confirmed in 6 patients, which was significantly related to patent lumbar arteries more than 6 ($p = 0.02$).

Conclusion: The number of patent lumbar arteries and intake of antithrombotic agents were associated with adverse outcomes following PT2 after EVAR.

Mid- and Long-term Results for Patients with Proximal Palmaz Stents in Endovascular Aneurysm Repair (EVAR)

Yuk Law, Yiu Che Chan, Albert C Ting, Stephen WK Cheng

The University of Hong Kong Medical Center, Hong Kong, Hong Kong

Background: The use of a proximal giant Palmaz stent is a well-recognized technique treating endoleaks. The aim of this study is to report follow-up data on patients who received proximal Palmaz stents in EVAR.

Methods: Retrospective review of prospectively collected computerized departmental database from July 1999 to May 2014. Pre-operative aortic anatomy analysed, and clinical and radiological follow results reviewed.

Results: In a cohort of 481 infrarenal EVAR patients, six (1.2%) patients received preoperative proximal Palmaz stents for Type 1a endoleaks. The mean \pm SEM of neck length (distance from lowest renal to beginning of aneurysm) and neck angulation, was 25.2 ± 1.82 mm and $58 \pm 6.12^\circ$ respectively. Four patients had conical neck, and one patient had reversed conical neck (defined as 20% area increase in neck area between level of renal artery and 2 cm below this). All the patients received Cook Zenith stentgrafts. No Type 1a endoleaks were seen at completion angiogram. With a median follow up period was 11 (range 2–86) months, none of the patients had type 1a endoleaks. One patient required left iliac extension at day 10 for occluded limb. Two patient have since died (24 and 59 post-operative months) from non-aneurysm related deaths.

Conclusions: In our experience, Palmaz stenting was effective, but we emphasize the importance of proper patient selection, pre-EVAR planning, and diligent follow up surveillance.

Long-term Outcome of Patients Who Underwent Open Abdominal Aortic Aneurysm Repair

Yuk Law, Yiu Che Chan, Kwok Fai Lee, Hon Chi Yip, Albert CW Ting, Stephen WK Cheng

The University of Hong Kong Medical Center, Hong Kong, Hong Kong

Introduction: The aim of the study was to evaluate the short and long-term outcomes in patients who underwent open infrarenal abdominal aortic aneurysm repair.

Methods: Consecutive patients with open repair of infrarenal aortic aneurysm at our institution from 1 July 1990 till 30 June 2012 were reviewed from a prospective collected departmental database. Short-term outcomes included 30 days mortality and peri-operative complications. Long-term survival and secondary intervention were also reported.

Results: 383 patients (317 males, Median age 72 with range 15–90) underwent open infrarenal aortic aneurysm repair during the period,

of whom 266 (69.5%) were elective, 18 (4.7%) were urgent for symptomatic but non-ruptured cases, and 99 (25.8%) were emergency procedures for ruptured aneurysms. Mean aneurysm size was 6.5 cm (range 2.5–15.0). All patients were followed up for at least 24 months with mean follow up period 163 months. Overall 30 days mortality was 11.0% (36.4% for ruptured; 11.1% for symptomatic, 1.5% for elective, $p < 0.001$). Systemic complications included 50 cardiac events, 52 respiratory events, 6 renal events, 3 cerebral vascular accidents and 1 deep vein thrombosis/pulmonary embolisms. Local complications included 1 anastomotic/graft hemorrhage, 10 distal thrombosis/embolism, 5 bowel ischemia, 1 spinal cord ischemia, 17 wound complications. The ruptured group presented survival of 53.5%, 50.5%, 47.5%, 42.3%, 38.0%, 23.7% at 12, 24, 36, 48, 60 and 120 months respectively; while non-ruptured ones were 91.5%, 88.0%, 83.7%, 78.3%, 73.0%, 43.0% (Log rank $p < 0.001$). For those who died after 30 days of operation, only 4 patients died of aneurysm related mortality. A total of 3 (0.8%) patients underwent secondary interventions were recorded: 1 for late aorto-enteric fistulae and 2 for anastomotic pseudoaneurysms.

Conclusion: In the current era of endovascular repair, open infrarenal aneurysm repair is safe and effective, and has low secondary interventions rates.

0205

A Prospective Screening of Popliteal Artery Aneurysm in Patients with Abdominal Aortic Aneurysm

Youn-Jung Kim, Shin-Young Woo, Yang-Jin Park, Dong-Ik Kim, Young-Wook Kim

Division of Vascular Surgery, Department of Surgery, Samsung Medical Center, Sungkyunkwan University School of Medicine, Seoul, Republic of Korea

Background: According to western reports, reported prevalence of popliteal artery aneurysm (PAA) in patients with abdominal aortic aneurysm (AAA) varies from 3%–12% (8%) whereas prevalence of AAA in PAA patients is 40%–70%.

Purpose: We attempted to determine prevalence of PAA in AAA patients and factors associated with PAA in Korean AAA patients. **Method:** We conducted prospective screening ultrasound examinations of popliteal artery (PA) in all AAA patients who are undergoing surgical or endovascular AAA repair during the past 3 years. US examination of the PA was performed in supine position at both legs with L9 with 4 MHz linear array transducer measuring outer-to-outer diameter (mm) of PA. PAA was diagnosed when largest diameter of the PA $\geq 150\%$ of the normal proximal segment of PA. To find factors associated with concurrent PAA in AAA patients, we analyzed by entering various variables including gender, age, concomitant aneurysm, coexisting disease or smoking, family history of aortic aneurysm, clinical features of AAA, and blood levels of ESR, CRP and total cholesterol.

Results: Among 280 patients with AAA (176 open surgical repairs and 117 EVARs), 18 PAA was detected in 12(4.3%) patients. Bilateral PAAs were detected in 6 patients (50%). Mean diameter of PAA was 15.7 mm (10.3–46.1 mm). PAAs were distributed in above the knee ($n = 11, 61\%$) and both above and below the knee ($n = 8, 39\%$). On a risk factor analysis for the PAA, there was no factors associated with concomitant PAA in AAA patients except presence of concomitant other arterial aneurysm such as splanchnic or intracranial artery aneurysm (3/12, 25% vs 1/268, 0.4%, $p < 0.001$). Among PAAs detected by screening in AAA patients, treatment-requiring PAA due to symptomatic or greater than 20 mm in diameter was 0.4%.

Conclusion: In Korean patients with AAA requiring treatment, PAA was found in 4.3% of patients. Among them, treatment-requiring PAA was very rare. As a factor associated with PAA, coexistence of other aneurysm such as splanchnic artery aneurysm was an only factor to predict presence of PAA in AAA patients.

0257

Comparison of Early and Mid-term Outcomes of Endovascular Repair versus Open Surgical Repair for Abdominal Aortic Aneurysm

Sheng Wang, Zhong Chen, Xiaobin Tang, Zhangmin Wu, Lei Kou, Hui Liu, Mengyao Zhai, Liao Yang, Qinghua Wu
Beijing An Zhen Hospital, Capital Medical University, Beijing, China

Objectives: To compare the early and mid-term outcomes of endovascular repair (EVAR) versus open repair (OR) for abdominal aortic aneurysm (AAA).

Methods: The trial compared the early and mid-term outcomes after EVAR and OR in patients with AAA anatomically suitable for both EVAR and OR. A total of 150 patients were performed EVAR or OR. Patients were monitored for 2 years after treatment. Statistical analysis was by intention to treat.

Results: The 30-day systemic complication rates in OR group were significantly higher than those in EVAR group (OR: 19/65, 29.2% vs EVAR: 8/85, 9.4%, $\chi^2 = 9.802$, $p = 0.002$). Operation-related complication rates in EVAR group were higher than those in OR group (EVAR: 14/85, 16.5% vs OR: 4/65, 6.2%), but there was no significant difference in both groups ($\chi^2 = 3.712$, $p = 0.054$). Patients in open repair group required longer operation time ($p = 0.000$) and hospital stay ($p = 0.022$), while more hospitalization cost was required in EVAR group ($p = 0.023$). The volume of intraoperative blood transfusion was more than 5 times in the open group over EVAR group. Patients in OR group had a trend toward systemic complications after surgery than in EVAR group. During a follow-up of 24 months, the systemic complication rates in OR group (6/62, 9.6%) were higher than those in EVAR group (3/83, 3.6%), but there was no significant difference in both groups ($\chi^2 = 2.241$, $p = 0.1342$). Operation-related complication rates in EVAR group were significantly higher than those in OR group (EVAR: 18/83, 16.5% vs OR: 3/62, 6.2%, $\chi^2 = 8.134$, $p = 0.004$).

Conclusions: Endovascular repair of abdominal aortic aneurysm caused less trauma in patients with AAAs than open repair in the short term, while required more hospital costs than open repair. Total complication rates at 24 months after operation were similar in both groups, while operation-related complications were more common in EVAR group.

0262

Association of Polymorphisms on Chromosome 9p21.3 Region with Increased Susceptibility of Abdominal Aortic Aneurysm in a Chinese Han Population

Yingqi Wei¹, Jiang Xiong², Shangwei Zuo², Feng Chen², Dafang Chen¹, Tao Wu¹, Wei Guo², **Yonghua Hu¹**

¹Department of Epidemiology and Biostatistics, School of Public Health, Peking University Health Science Center, Beijing, China

²Department of Vascular and Endovascular Surgery, Chinese PLA General Hospital, Beijing, China

Objective: Several studies have reported that polymorphisms on chromosome 9p21.3, near the CDKN2A/2B gene, are strongly associated with increased susceptibility to abdominal aortic aneurysm (AAA). However, no convincing data has been reported on a relationship between AAA and these variants in the Chinese Han population. The aim of this study was to evaluate the role of rs10757278 and rs1333049 in determining genetic susceptibility to AAA.

Methods: A total of 155 AAA patients and 310 controls, comparable in age and gender, were enrolled in this study. DNA samples were genotyped for rs10757278 and rs1333049 using the Mass Array system. The association between these two single nucleotide polymorphisms and AAAs was tested using multivariate logistic regression. Stratified analysis was also performed by clinical and laboratory features.

Results: Single nucleotide polymorphisms rs10757278 and rs1333049 were significantly associated with increased risk of AAA. The frequencies of rs10757278-G and rs1333049-C in AAA patients were significantly higher than in control subjects (odds ratio [OR], 1.53; 95% confidence interval [CI], 1.11–2.11; $P = .01$, and OR, 1.48; 95% CI, 1.07–2.05; $P = .02$). Multiple logistic regression analysis indicated that, after adjusting for smoking habits, drinking habits, and histories of other chronic diseases, homozygosity of the risk allele for rs10757278-G and rs1333049-C also increased the likelihood of AAA (OR, 2.31; 95% CI, 1.22–4.36, and OR, 2.14; 95% CI, 1.13–4.05). The frequency of the GC haplo type was significantly higher in AAA patients than in control subjects (OR, 1.44; $P = .038$). Stratification analysis of clinical and laboratory features revealed no association between polymorphisms and aortic diameters in AAA patients. There was a significantly high frequency of the rs10757278 GG genotype in AAA patients with high serum total homocysteine compared with those control subjects with high serum total homocysteine (OR,

2.71; 95% CI, 1.12–6.58; $P = .03$) indicating that the genotype GG of rs10757278 might interact with the homocysteine biological pathway to stimulate the presence of AAA.

Conclusions: Present data demonstrate that rs10757278 and rs1333049 on chromosome 9p21.3 are significantly associated with increased risk of AAA in the Chinese population and emphasize the need to further study the role of these markers in AAA. (J Vasc Surg 2013; 1-7.)

Aortic Infections and Complicated Aortic Aneurysm Repair

Session Code: FP5C

1100-1230, 6 September

Function Room 1, 2/F

0064

Endovascular Stent Graft Repair of Infected Aorto-Iliac Pseudoaneurysm: Kuala Lumpur Hospital Experience

Nan Chuang Khang, Zainal Ariffin Azizi

Kuala Lumpur Hospital, Kuala Lumpur, Malaysia

Background: This is a single institutional review of all infected aorto-iliac pseudoaneurysm managed with endovascular stent graft repair.

Methods: From 2009 to 2014, 16 patients had endovascular stent graft inserted for infected pseudoaneurysm of the thoracic aorta (1), abdominal aorta (8) and iliac arteries (7) in Kuala Lumpur Hospital. Co-morbidity, causative agents, in-hospital mortality, complications and outcomes were examined.

Results: The average age was 59.1 years (range 36–77). Comorbidities include hypertension, diabetes mellitus, tuberculosis, prior infection and previous open aneurysmal repair. 75% of patients had abdominal/back pain while 50% had fever. All patients had raised WBC ($>10.0 \times 10^9/L$), ESR or C-reactive protein on admission. Blood cultures were positive in 4 patients: 2 *Klebsiella* spp, 1 *Enterobacter* spp, and 1 *Salmonella* spp. The sites of pseudoaneurysm were descending thoracic aorta (1), abdominal aorta (8), common iliac artery (5) and internal iliac artery (2). Aorto-uni-iliac stent grafts with occlusive device on contralateral common iliac artery were inserted in 8 patients followed by femoro-femoral crossover bypass. 8 other patients had tube aortic or iliac graft inserted. All in-patients were given intravenous antibiotics followed by oral antibiotics upon discharge. Only one in-hospital mortality at day-47 post-procedure. 2 patients died of aorto-enteric fistula at district hospital 8 & 16 months later. One patient died of chronic graft infection 2 years later. One died of unrelated cause. One patient developed type IB endoleak from internal iliac artery 2 years later and surgical ligation was performed. The average follow up was 15.8 months. Significant reduction of inflammatory markers, aneurysm size and patients' symptoms were noted after the procedure.

Conclusion: Endovascular stent graft repair for infected pseudoaneurysm is a viable option compared to open surgery. It is less invasive, has lower operative morbidity and good outcomes. However, long-term follow up is needed to ensure early recognition of complications.

0068

Early Experience with Fenestrated and Chimney Endografts for Short Neck Aortic Aneurysms Repair in Ramathibodi Hospital

*Arkorn Suesawatee, Piyanut Pootracool,
Suthas Horsirimanont, Wiwat Tirapanich,
Surasak Leela-Udomlapi, Sopon Jirasiritham*
Ramathibodi Hospital, Bangkok, Thailand

Objective: To present our early experience for the use of fenestrated and chimney endograft techniques in the endovascular management for short neck of descending thoracic aortic aneurysm (DTAA) and abdominal aortic aneurysm (AAA) in Ramathibodi hospital.

Methods: Retrospective reviewed fenestrated and chimney endograft techniques for short neck DTAA and AAA performed from January 2012 to January 2014. The aneurysms included; DTAA neck <2 cm to the left subclavian artery and AAA neck <1.5 cm to the lowest renal artery. The advanced endovascular techniques included; chimney technique for thoracic endovascular aneurysm repair (chTEVAR), chimney technique for endovascular abdominal aneurysm repair (chEVAR), and fenestrated-endovascular aneurysm repair (FEVAR).

Results: In total 19 patients (16 men and 3 women), median age 77 years. DTAA 3 cases and juxtarenal AAA 16 cases, median aneurysm diameter 60 mm and mean neck length 2.16 mm. The procedure included; chTEVAR 3 cases, chEVAR 11 cases, and FEVAR 5 cases. Technical success for exclude aneurysm from circulation 89.4%. Technical success for target vessels preservation 97.6%. No procedure conversion to open repair. Endoleak type Ia were found in 2 cases (1 case spontaneous thrombosis at 1 month after operation). Perioperative complications within 30 days included; NSTEMI 1 case, ARF 4 cases, pseudoaneurysm at right brachial artery 1 case. Median hospital stay 8 days and median ICU stay 2 days. In mean follow-up period (7.07 months) found that aneurysm sac completely thrombosis 94.7%. Death 1 case and develop new type Ia endoleak 1 case, all target vessels were patent.

Conclusions: Advanced endovascular aneurysm repair in short neck or inadequate proximal landing zone in high-risk patients by using technique of fenestrated endograft, chimney technique can reduced perioperative morbidity, mortality and favorable outcome.

0071

Endovascular Repair of Ruptured Infectious Thoracoabdominal Aneurysm in a Patient with Previous Endovascular Aortic Aneurysm Repair

Hiroshi Mitsuoka, Takaaki Saito

Shizuoka Red Cross Hospital, Shizuoka City, Japan

Objectives: To share our emergent endovascular experience using a “surgeon modified fenestrated stent graft” for a rupture of infectious thoracoabdominal aneurysm.

Case Report: The patient was a 71-year-old male. Previously, he had undergone elective EVAR using a stent-graft with a supra-renal stent (Endurant, Medtronic, USA), and surgical repair of deep femoral artery aneurysm at the same time. He was presented to our hospital at the status of septic shock, due to infection of the prosthesis in the groin. The infected graft was surgically removed, but post-operatively, he became totally dependent on hemodialysis due to renal failure. Bacteriological tests detected MRSA (VCM highly sensitive) in the prosthesis and his blood. The patient had been suffering from high fever, chronic heart failure (presented as pleural effusion and hypoxia), the end-stage renal function, and low nutrition, in spite of three weeks of strictly controlled anti-biotic therapy. On the 24th post-operative day, he complained of severe back pain. Computed tomography angiography found a rupture of aneurysmal aortic segment around the supra-renal stent. Type IA endoleak was also detected. The aneurysmal segment was covered with a modified (fenestrated based upon patients anatomy) stent-graft using a different bifurcated stent graft (Zenith, Cook, USA). For the celiac and superior mesenteric arteries, two covered stents (Fluency, BARD, USA) were used. The renal arteries were not revascularized due to the end-stage renal failure. Postoperatively, the patient had no neurological problems. Although he had an extraordinarily extended hospital stay, he could be discharged from hospital on foot, 5 months after the endovascular procedure.

Conclusions: Rupture of supra-renal aortic segment after previous EVAR was rare. The infection seemed to be the main cause of rupture. The technique was feasible to deal with such an acute status of a high-risk patient. Needless to say, long term follow-up is necessary.

Case Report of Chimney Stent-graft Repair for Concurrent Infra-renal Abdominal Aortic Aneurysms and Inferior Mesenteric Artery Aneurysm

Zhen Wei Choo², **Chun Hai Tan**³, **Punamiya Sundeep**¹,
Narayanan Sriram¹

¹Tan Tock Seng Hospital, Singapore, Singapore

²Ministry of Health Holdings, Singapore, Singapore

³Khoo Teck Puat Hospital, Singapore, Singapore

Background and Objectives: This case report describes the technical aspect of chimney stent grafting (CG) for an 82 years old man with an asymptomatic concurrent 4.4-cm infra-renal abdominal aortic aneurysm (AAA) and 3.6-cm inferior mesenteric artery (IMA) aneurysm. This report aims to demonstrate the technical feasibility and safety of adding CG to endovascular aneurysm repair (EVAR) technique for concurrent AAA and IMA aneurysm in a patient with background multiple co-morbidities.

Methods: The procedure was performed by a vascular surgeon together with an interventional radiologist in the angiographic suite in the radiology department under general anesthesia. The IMA aneurysm was initially stented and subsequent IMA chimney and main body stent-graft were deployed sequentially. All the landing zones and joints were molded using a compliant reliant balloon and check aortogram was performed. A repeat CT angiogram was performed 3 days later.

Results: Immediately after the procedure, patient developed persistent type 2 and type 4 endoleak. However, repeat CT angiogram 3 days later showed good preservation of blood flow through IMA and bilateral internal iliac arteries with no endoleak. The main body graft, IMA chimney graft, iliac limbs and IMA stent remains in good position and caliber, with satisfactory iliac runoff and mesenteric circulation seen. Patient was discharged well on post-op day 16.

Conclusion: This technique is a safe and feasible option in high surgical risk patients with concurrent AAA and IMA aneurysm.

0133

Follow-up Results of Arterial Reconstructions with Cryopreserved Arterial Allografts: Risk Factors for Graft-related Complications

Seung-Rim Han, **Young-Wook Kim**, **Yang Jin Park**,
Shin-Young Woo, **Yoong-Seok Park**, **Dong-Ik Kim**
Samsung Medical Center, Seoul, Republic of Korea

Background and Objectives: Advantages of cryopreserved arterial allograft (CAA) are availability of long time preservation, lowered antigenicity and resistance to bacterial infection. However, graft-related complications (GRC) such as an early postoper-

ative graft rupture and late degenerative change of the implanted CAA are reported. Previously reported results of the CAA were heterogeneous. We attempted to determine factors associated with GRC by reviewing our case series of CAAs.

Method: Prospectively maintained database of patients who underwent arterial reconstruction with CAA were reviewed. We investigated surgical indications, allograft properties, and follow-up results including GRCs and causes of death if patients are dead. To determine risk factors for GRCs, we analyzed variables of the duration of cryopreservation, donor age, gross purulence, pediatric patient and immunosuppression.

Results: During the past 10 years, 31 patients (median age, 68 years, 1–90 years) underwent arterial reconstructions using CAAs for patients with infective aneurysm or prosthetic graft infections (n = 24), arterial reconstructions in immunocompromised patients (n = 5), and in cases of no alternative graft material in pediatric patients (n = 2). Arterial reconstruction were performed at 19 aorto-iliac, 6 femoral, 3 iliac, 2 brachial and 1 carotid arteries. Sources of allografts were 13 composite aorta-iliac/femoral, 7 abdominal aortas, 6 iliac, 2 femoral, 1 internal mammary and 1 radial arteries. Mean duration of cryopreservation was 17 mo (1–79 mo) after harvest. During the follow-up period of median 24 mo (1–85 mo), 6 deaths, 6 GRCs including anastomotic narrowing (2), graft occlusions (2) and aneurysmal dilatation (1) and graft rupture (1) resulting in graft-enteric fistula occurred while 2 patients were lost to follow up. On an analysis to determine risk factors for GRC, we couldn't find any significant risk factor except small-caliber CAA in pediatric patients.

Conclusion: Most of the late mortality attributed to underlying diseases not to GRCs. Though small-caliber CAAs resulted in early graft occlusion, factors associated with GRC should be further investigated.

0166

The Role of PET/CT for Diagnosis of Aortic Stent Graft Infection: Compared with Convention Computed Tomography and Single-photon Emission Computed Tomography (SPECT)

Chun-Che Shih

Taipei Veterans General Hospital, Taipei, Taiwan

Aim: To investigate the diagnostic accuracy of fluoro-2-deoxy-D-glucose positron emission tomography combine with computed tomography (FDG-PET/CT) in diagnosing aortic stent graft infection, and compare with conventional computed tomography and inflammation scan.

Materials and Methods: During Aug 2011 to Oct 2013, 21 patients, suspected having aortic stent graft infection after EVAR/TEVAR with or without hybrid procedure, received CT scan, inflammation scan/SPECT and PET/CT to determine stent graft infection.

Results: 8 of the 21 patients were diagnosed as aortic stent graft infection or infected aortic aneurysm. FDG-PET/CT had perfect specificity and accuracy (sensitivity 100%, specificity 100%, positive predictive value 100% and negative predictive value 100%, accuracy 100%). For CT, these values were 75%, 84.6%, 75% and 84.6%, 80.95%, respectively. For inflammation scan/SPECT, the values were 75%, 92.3%, 85.7%, 85.7% and 85.7%.

Conclusion: FDG-PET scanning showed excellent diagnostic accuracy for the aortic stent graft infection and the perfect specificity in our cases. This study suggests that FDG-PET provides a useful tool in differential diagnosis for those clinically suspected aortic stent graft infection.

0187

Aortoduodenal Fistula: A Lethal Condition with Multiple Treatment Options

Zia Ur Rehman, Ziad Sophie

The Aga Khan University Hospital, Karachi, Pakistan

Aortoenteric fistula is one of the most challenging diagnostic and therapeutic entities in vascular surgery. It has multiple presentations and also multiple treatment options which have to be individualized. We share our experience of managing five patients with aortoenteric fistula over three years (2011–2014). Out of them four patients had secondary, while one patient had primary aortoenteric fistula. Three patients had previous abdominal aortic aneurysm repair and one patient of Takayasu disease had aorto-aortic bypass for aortic stenosis. Patient with primary aortoenteric fistula had Hodgkin Lymphoma and abdominal tuberculosis. Most of the patients (3) presented with massive upper gastrointestinal bleeding and were haemodynamically unstable. While the rest presented with sepsis. Three patients were managed surgically solely, one with endovascular means and one had both options used for management. Out of the surgically treated patients, one had axillobifemoral bypass, one had neo aorta reconstruction with femoral vein graft. Survival rate in this series was 80%. One patient who died presented with haemodynamic instability due to massive upper GI bleeding and died due to multiorgan failure. High clinical suspicion and versatility to all available options and rapid intervention can give satisfactory results in this lethal condition.

0209

Lessons Learned from Stent-graft Placement for Ureteroarterial Fistula

Akhmadu Muradi^{1,2}, Masato Yamaguchi¹, Koji Idoguchi¹, Takuya Okada¹, Yoshikatsu Nomura³, Yutaka Okita³, Koji Sugimoto¹

¹Center for Endovascular Therapy, Department of Radiology, Kobe University Hospital, Kobe, Japan

²Vascular and Endovascular Division, Ciptomangunkusumo Hospital, Faculty of Medicine, University of Indonesia, Jakarta, Indonesia

³Cardiovascular Division, Department of Surgery, Kobe University Hospital, Kobe, Japan

Ureteroarterial fistula (UAF) is a rare but potentially life-threatening entity. Surgery would be formidable due to hostile field, patient risk factors, and comorbidities. Therefore, stent graft placement for UAF is now the preferred treatment. We report a 76-year-old female with history of radical hysterectomy, left ureteral stenting, and pelvic radiation for cervix cancer who had intermittent hematuria followed by massive hematuria. Contrast-enhanced CT and multidirectional angiography could not depict evidence of fistula. Considering the risk factors, UAF was clinically diagnosed and stent-graft placement was planned. However, some pitfalls occurred during the procedure. Chronic inflammation process might induce longer adhesion area between artery and ureter, which resulted in unusual fistula site (the middle portion of external iliac artery), and rigid iliac arteries. This further led to difficulty in advancing the 16-F endograft delivery system, even the access route was large enough. Multiple attempts to pass the iliac artery resulted in “incidental” mechanical provocative angiography with subsequent massive bleeding. The usage of smaller and more flexible stent-graft delivery system profile (9F) resolved the problem. These suggested us not only to be careful and prepared but also to consider that angiography after inserting the delivery system could give additional information on the exact fistula site. At 22 months follow up, there were no hematuria and stent graft related complication.

0228

The Experience with Endovascular Repair of Complex Abdominal Aortic Aneurysm

Yongquan Gu, Lianrui Guo, Lixing Qi, Jian Zhang, Zhonggao Wang

Department of Vascular Surgery, Xuanwu Hospital & Vascular Surgery Institute, Capital Medical University, Beijing, China

Purposes: To explore the results of endovascular repair of complex infrarenal abdominal aortic aneurysm (EVAR).

Methods: Data of endovascular treatment of 65 cases with complex infrarenal abdominal aortic aneurysm were retrospectively analyzed. Complexity of abdominal aortic aneurysm included: short neck (15 cases, 23.1%), severe angulated neck (28 cases,

43.1%), bilateral involvement of common iliac arteries (5 cases, 7.7%), difficulty in sending the delivery system because of stenosis or occlusion in arterial access (5 cases, 7.7%) and other complicated types of aneurysm (2 cases, 3%). All the cases underwent EVAR. Imported stent-grafts were used in 29 cases (44.6%), domestic stent-grafts were used in 36 cases (55.4%). The short neck was overcome by relatively proximal deployment of the stent with reference to the distal renal artery; The severe angulation of the aneurysm neck was relatively straightened to guarantee safe stent deployment; Unilateral internal iliac artery was kept patent with either stenting or bypass grafting in case of iliac aneurysm; One patient had the bilateral internal iliac arteries covered by graft stents in two stages to avoid intrapelvic ischemia from EVAR.

Results: Procedure success rate was 100%. 23 cases (35.4%) suffered from immediate endoleak, including type I in 6 cases (26.1%), type II in 14 cases (60.9%), type III in 3 cases (13.0%). No procedure-related death occurred. Mean postoperative hospital stay was 8.2 days. Follow-up was made in 60 cases (92.3%), mean follow-up period was 3.5 years. 5 (8.3%) cases died of diseases other than aneurysm. One case had stent migration in 6 months after operation and underwent further endovascular treatment because of endoleak. Up to 22 months' follow-up revealed no stent migration or new endoleak for this patient. All other endoleaks recovered in other cases. Lower limb ischemia was found in 3 cases. One suffered from graft migration and ischemia was alleviated by femorofemoral bypass; The other 2 cases suffered from stent folding, and treated with bare stent implantation.

Conclusions: As the improvement of endovascular technology and equipments, many complex abdominal aortic aneurysm can also be treated, and the endovascular procedure were safe and efficient.

Thoracic Aorta Disease 1

Session Code: FP6C
1400-1530, 6 September
Function Room 1, 2/F

0025

Long Term Results of Aortic Root Reconstruction

Hitoshi Minami, Keitaro Nakagiri, Soihiro Henmi, Atsushi Omura, Hirohisa Murakami, Hitoshi Matsuda, Masato Yoshida, Nobuhiko Mukohara

Hyogo Brain and Heart Center, Himeji, Hyogo, Japan

Background: This study is to evaluate early and late outcomes of aortic root replacement including valve sparing operation.

Methods: From January 2001 to December 2013, 87 patients underwent aortic root replacement using modified Bentall operation in 60 patients and the David reimplantation technique in 14 patients. Twenty-four patients underwent combined hemi arch or total arch replacement for aortic regurgitation (AR) with extended aortic aneurysm from aortic root to arch. Etiologies included acute

type A aortic dissection in 16, chronic aortic dissection in 12, non-dissection, true aneurysm in 45. There were 7 patients with Marfan syndrome.

Results: One hospital death was observed (1.3%). Postoperative complications were prolonged mechanical ventilation (>48 hours) in 2 and reoperation for bleeding in 4. The other complications such as neurological dysfunction or low cardiac output syndrome were not observed. During follow-up, all valve sparing operation group had less than trace AR. The mean follow-up period was 46.8 ± 40.4 months. Overall survival at 10 years was 78.1%. Thromboembolic complication occurred in 2 patients during follow-up. Freedom from reoperation at 5 and 10 years was 93.4% and 84.2%, respectively.

Conclusions: Early outcomes of valve sparing operation are feasible and provides excellent freedom from thromboembolic complication. Freedom from reoperation at long term follow-up is acceptable. Late results of Bentall op is stable. Further follow-up is required to evaluate this procedure.

0086

Delayed Visceral Malperfusion after Bentall Procedure for Type A Acute Aortic Dissection

Satoshi Yamashiro, Yukio Kuniyoshi, Ryoko Arakaki, Yuya Kise, Hitoshi Inafuku

University of the Ryukyus, 207 Uehara, Nishihara, Nakagami, Okinawa, Japan

Rapid restoration of flow into the true lumen and obliteration of a false lumen is considered the optimal approach to treating malperfusion syndrome due to acute aortic dissection. However, organ malperfusion can occasionally persist after proximal aortic graft replacement despite redirecting blood flow into the true lumen. A 35-year-old man underwent the modified Bentall procedure for Stanford type A acute aortic dissection without organ malperfusion. The postoperative course was initially uneventful, but abdominal fullness and bilateral leg pain developed together with a significantly weakened femoral arterial pulse on postoperative day 8. Enhanced CT revealed thrombus in the false lumen interfering with the true lumen above the celiac trunk with left renal arterial occlusion. Since malperfusion had apparently progressed to include the visceral and lower extremities, we performed an immediate left axillary-to-bilateral femoral artery bypass. The patient recovered uneventfully from this procedure although acute renal failure required continuous hemodialysis for one week. The true lumen expanded after these procedures and visceral malperfusion disappeared. Postoperative follow-up CT revealed a well-preserved, expanded true lumen and extra-anatomical bypass flow. The patient was free of organic dysfunction at the time of discharge on postoperative day 28. Although organ malperfusion persisting after proximal aortic graft replacement despite redirecting blood flow into the true lumen is rare, various mechanisms of malperfusion should be carefully considered. Adverse outcomes are mainly associated with a delayed diagnosis and irreversible organ ischemia. Early

diagnosis and immediate intervention are imperative for patients with organ ischemia due to aortic dissection, but reliable diagnostic markers or findings to predict the condition have not yet been identified. Close observation remains imperative after central repair of type A dissection.

0087

Applicability of Endovascular Treatment for Descending Thoracic Aortic Syndromes: A Single Institution Experience

Wilmo Orejola¹, *David O'Connor¹*, Yue Liu², Michael Wildermann¹, Massimo Napolitano¹, Gregory Simonian¹

¹Hackensack University Medical Center, Hackensack, New Jersey, USA

²Stevens Institute of Technology, Hoboken, New Jersey, USA

Background: Descending thoracic aortic aneurysms (DTAA), traumatic aortic injuries and aortic dissections are life-threatening pathologies in which thoracic endovascular aortic repair (TEVAR) has become a therapeutic option. We provide the mortality and morbidity results of these descending thoracic aortic syndromes from our institution.

Methods: We reviewed data from all patients treated with TEVAR in our institution from 1/13/2006 to 2/4/2014, including demographics, diagnosis, endograft usage, complications and 30-day and late mortalities.

Results: Seventy-five TEVAR procedures were done in 70 patients, with a sex ratio of 1:1, mean age 74 years (range 22–98 years). TEVAR was done in 52 DTAAAs (74.2%); 14 Type B dissection (20.0%); 4 traumatic aortic injuries (5.7%). Five TEVARs were performed in the same patients to correct type 1 endoleaks. One stent graft was used for superior mesenteric artery occlusion.

Most common device-related complications was type-1 endoleak 6 (8.0%); while procedure-related complications included 2 ischemic bowel/colitis (2.6%), 1 Paraplegia (1.3%); 1 Stroke (1.3%); 1 heart failure (1.3%); 1 type 2 endoleak (1.3%). Average length of stay was 7.5 days.

Four patients died within 30 days (5.3%), while 8 died later or a late mortality of 10.6%.

Conclusions: Our results confirm that TEVAR is a therapeutic option for both elective and emergency descending thoracic aortic syndromes. Mortality tends to be higher in aortic ruptures and dissections, which are done more emergently.

0148

Retrograde Type A Dissection following Hybrid Supra-Aortic Endovascular Surgery in High Risk Patients Unfit for Conventional Open Repair

Hon Chi Yip, Yiu Che Chan, Albert C Ting, Stephen WK Cheng

Division of Vascular & Endovascular Surgery, Department of Surgery, University of Hong Kong Medical Centre, Hong Kong, Hong Kong

Introduction: Hybrid procedures with combined open extra-anatomical supra-aortic bypasses and endovascular surgery are less invasive for patients with complex aortic arch pathology. The aim of this paper is to report patients who developed retrograde Type A aortic dissection following initially successful hybrid endovascular treatment.

Methods: Retrospective review of prospectively collected computerised departmental database. All patients with supra-aortic hybrid endovascular surgery and post-procedure retrograde Type A dissection were identified. Patient demographics, comorbid conditions, perioperative parameters, procedural details and post-operative complications were collected.

Results: From May 2005 to March 2014, 163 patients underwent thoracic aortic endovascular procedures at our institution, of which 46 of them had supra-aortic hybrid endovascular repair. Six patients (6/163 (3.6% of all thoracic stentgrafts cases); 6/46 (13% of all supra-aortic hybrid cases), 3 males) developed retrograde Type A aortic dissection. All were elective cases, with 3 chronic dissecting aneurysms and 3 atherosclerotic aneurysms. All had one stage hybrid procedures: 2 patients had carotid-carotid bypass grafts, 1 had carotid-carotid-left subclavian bypass graft, and 3 had bypass grafts from ascending aorta to innominate artery and left carotid artery. Five patients had Cook Zenith thoracic stentgrafts (Cook®, Bloomington, USA), and 1 had Medtronic® Valiant stentgrafts (Medtronic Vascular Inc, Santa Rosa, USA). The retrograde Type A dissection occurred with sudden symptoms at day 5, 6, 10, 20, 105 and 128 respectively. There were 3 immediate fatalities and 2 patients treated conservatively deemed unfit for reintervention (one died at 9 month of pneumonia, and one remained alive at 7 months post-complication). One patient underwent successful emergency open surgery and survived.

Conclusion: Supra-aortic hybrid procedures in treating aortic arch pathology are not protective of retrograde Type A dissection, and patients with this post-operative complication inevitably have poor outcome, even with early diagnosis or treatment is delayed.

The Relationship between Plasma Homocysteine and Aortic Dissection

Jie Liu¹, Chen Duan^{1,2}, Xin Jia¹, Sen-hao Jia¹,
Yang-yang Ge¹, Zhong-yin Wu¹, Wei Guo¹

¹Department of Vascular Surgery, People's Liberation Army General Hospital, Beijing, China

²Medical College of Nan Kai University Tianjin, Tianjin, China

Objective: To study the relationship between plasma homocysteine and aortic dissection.

Method: From October 2011 to January 2013, a total of 111 participants met the inclusion criteria including 45 acute aortic dissection patients (group A, mean age 57.62 ± 9.74 years, 35 males), 16 non-acute aortic dissection patients (group B, mean age 53.88 ± 8.12 years, 12 males) and 50 healthy controls (group C, mean age 55.62 ± 4.07 years, 41 males). Fasting homocysteine were determined in serum separated within 1 h of blood collection using a fluorescence polarization immunoassay technique.

Results: The mean homocysteine level was 17.85 ± 8.65 $\mu\text{mol/L}$, 22.15 ± 10.45 $\mu\text{mol/L}$ in group A and group B, and in the healthy control group was 12.74 ± 3.32 $\mu\text{mol/L}$ ($p < 0.001$). Twenty-six (57.8%) patients of the group A and eleven (68.8%) patients of the group B had hyperhomocysteinemia compared to 15 (30%) in the healthy control group. Univariate logistic regression showed that a 4.78-fold greater risk of AD in subjects who have the HHcy, as compared with those having normal hcy level. (OR = 4.78; 95% CI = 1.21, 18.92; $p < 0.05$).

Conclusion: This study shows significantly higher levels of plasma homocysteine in aortic dissection patients. Hyperhomocysteinemia is suggested to be an independent risk factor for aortic dissection. More clinical studies in this direction are warranted.

0270

Novel Temporary Endovascular Shunt Technique to Assist In Situ Fenestration for Endovascular Reconstruction of the Distal Aortic Arch

Jiang Xiong, Wei Guo, Xiaoping Liu, Xin Jia,
Xiaohui Ma, Lijun Wang

Department of Vascular Surgery, Vascular Center of Military, Chinese PLA General Hospital, Beijing, China

Thoracic endovascular aortic repair (TEVAR) of arch pathology presents special challenges for revascularization. To obtain an anatomic reconstruction of the arch arteries, in situ fenestration with extra-anatomic bypass has been increasingly used in TEVAR. We report a case involving TEVAR for a pseudoaneurysm at zone 2 of the thoracic aorta in a 37-year-old man with the use of in situ fenestration assisted by a temporary endovascular shunt technique. (J Vasc Surg 2014; 1-4.)

0277

Hybrid Treatment of Aortic Arch Disease with Ascending Aorta to Carotid Artery Revascularization and Subsequent Endovascular Repair

Mian Wang, Guang-Qi Chang, Shen-Ming Wang,
Heng-Hui Yin, Chen Yao, Jin-Song Wang, Song-Qi Li

Department of Vascular Surgery, the First Affiliated Hospital, Sun Yat-sen University, Guangzhou, China

Objective: To summarize the experience of treating aortic arch disease with ascending aorta to carotid artery revascularization and subsequent endovascular repair.

Method: From January 2002 to July 2014, 14 high risk patients with aortic arch disease were treated with ascending aorta to carotid artery revascularization with subsequent endovascular repair in our center. Of the 14 patients (male 13), with a mean age of 54.9 ± 13.1 (34–71) years old, 8 were Stanford B aortic dissection, 3 were Stanford A aortic dissection and 3 were aortic arch aneurysm. All aortic arch debranching was performed with mid-sternotomy, including 8 Ascending Aorta (AO) to Innominate Artery (IA) and Left Common Carotid Artery (LCCA) bypass, 2 AO to IA-LCCA and Left Subclavian Artery (LSA) bypass, 3 AO to LCCA-LSA bypass, and 1 AO to IA bypass. Subsequently, simultaneous ($n = 6$) and staged ($n = 8$, mean interval = 8.5 ± 4.1 days) endovascular repair was performed via femoral artery.

Results: Technical success rate was 100% (14/14). The 30 day-mortality was 28.6% (4/14), including 1 brain stem infarction, 1 circulatory failure, 1 intracranial hemorrhage and 1 aorto-tracheal fistula. Complication included 1 minor type I endoleak and 1 type II endoleak. The time of follow-up was 45.3 ± 42.5 (2–146) months. CT scanning was performed at 1, 3 months after surgery and annually thereafter. There was no death and no occlusion of bypass during follow up. No complication occurred except 1 existing minor type II endoleak.

Conclusions: Ascending aorta to carotid artery revascularization with subsequent endovascular repair is safe and effective in treating aortic arch pathology, and is suitable for high risk patients of poor general condition with little tolerance to aortic arch replacement.

Thoracic Aorta Disease 2

Session Code: FP7C

1600-1730, 6 September

Function Room 1, 2/F

0131

Influence of Operative Strategy for Acute Aortic Dissection Type A

Kouji Shimizu, Teiji Oda, Syouichi Suehiro

Shimane University, Izumo City, Shimane Prefecture, Japan

Objective: In acute DeBakey type I aortic dissection, it is still controversial whether to perform extended aortic replacement to improve long term outcome or to use a conservative strategy with ascending aortic and hemiarch replacement with entry tear exclusion to palliate a life-threatening condition.

Methods: Between 2002 and 2013, 73 consecutive patients (37 women; mean age, 72.4 ± 11.0 years) with acute DeBakey type I aortic dissection underwent hemiarch (Hemiarch group; $n = 56$), and total arch replacement (Total arch group; $n = 17$) in conjunction with ascending aorta replacement. We performed hemiarch or total arch replacement, according to the location of the primary entry tear. Clinical outcomes were compared.

Results: Mean follow up was 40.9 months (range 0–138 months) and was 94.6% ($n = 69$) complete. Five year survival and permanent-neurologic-injury-free survival were $79.9 \pm 5.2\%$ and $70.5 \pm 5.8\%$ in the Hemiarch group, and $69.2 \pm 12.8\%$ and $46.2 \pm 13.8\%$ in the Total arch group, respectively ($p = 0.35$ and 0.08). There were no differences between the two groups. The risks of the re-operation for aortic pathology or distal aortic dilatation (>55 mm) were similar for both groups (3.6% in the Hemiarch group, and 5.9% in the Total arch group; $p = 0.78$).

Conclusions: Rates of five year-survival and permanent-neurologic-injury free survival, and that of aortic reoperation or aortic dilatation were not significantly different between the two surgical strategies. These findings support hemiarch replacement with entry tear exclusion to circumvent this life-threatening situation.

0173

Early and Mid-term Outcome of TEVAR in Complicated Type B Dissection

Randolph Wong¹, Simon Yu², YH Lam³, James Lau³, CM Chu², Innes Wan¹, Song Wan¹, Malcolm Underwood¹

¹Division of Cardiothoracic Surgery, The Chinese University of Hong Kong, Shatin, Hong Kong, Hong Kong

²Department of Imaging and Interventional Radiology, Shatin, Hong Kong, Hong Kong

³Division of Vascular Surgery, Shatin, Hong Kong, Hong Kong

We aimed to assess the safety and mid- to long-term clinical and radiological outcome of Thoracic Aortic Endovascular Stenting

(TEVAR) for complicated aortic dissection with descending tear.

Methods: We conducted a retrospective study of all complicated aortic dissections with intimal tear in descending aorta treated with TEVAR from January 2008 to April 2014 in a tertiary referral center. The composite primary end-point was technical success and procedural safety defined as procedure-related death or complication within 30 days. The secondary end-points were clinical and radiological outcome defined as incidence of death, procedure-related complications and radiological evidence of aortic remodeling during the follow up period.

Results: A total of 92 consecutive patients with complicated thoracic aortic dissection were treated with TEVAR. There were three aortic related deaths (1 acute retrograde aortic dissection, 1 ruptured false lumen, 1 rebleeding from concealed rupture). There were 6 30-days mortality (1 acute retrograde aortic rupture, 1 ruptured false lumen, 1 rebleeding from concealed rupture, 2 pneumonia, 1 acute myocardial infarction). There were 8 total debranching, 41 extra-anatomical bypass of head and neck vessels and 43 cases of simple TEVAR. Two patients required re-exploration for bleeding. Three patients with transient paraparesis that settled with lumbar drainage, 4 minor strokes, and one intimal tear at femoral artery entry site. There was 1 aortic related death, i.e. aorto-esophageal fistula after 30 days. In the latest follow up CT (median: 50 months, range: 1 week–72 months), complete and partial thromboses of the false lumen of thoracic aorta were achieved in 70% and 25% of patients respectively. Four type I and seven type II endoleaks were detected. The overall survival rates were 86% (1-year), 83% (2-year) and 81% (5-year).

Conclusion: TEVAR is probably a safe and effective treatment for patients with complicated type B aortic dissection.

0190

Long Term Results of Endovascular Treatment of Traumatic Thoracic Aortic Injuries. Single Center Experience

Abdelrahman Elkaialy, Saud AlTurki, Hussin AlKohlani, Abdullah AlWahbi

King Fahd National Guard Hospital, Saud Bin Abdulaziz University for Health Sciences, Riyadh, Saudi Arabia

Introduction: Successful thoracic endovascular aortic repair (TEVAR) with low rates of complications has been referred to in the treatment of traumatic thoracic aortic injuries; however, we still do not know the long-term behavior.

Aim: In this series, we report the long-term follow up after TEVAR of traumatic thoracic aortic injuries.

Material and Methods: Retrospective review of patients who underwent stent graft repair for traumatic thoracic aortic transection from April 2007 to April 2014 was undertaken. Outcome measures includes procedure related mortality, neurological complication (paraplegia-stroke), CT scan follow up for immediate

and long term coverage of thoracic false aneurysm and absence of stent graft complications.

Results: The clinical charts and courses of 46 patients with traumatic thoracic aortic injuries treated with TEVAR were retrospectively reviewed. Technically successful stent graft deployment was achieved in all patients. There was no procedure-related mortality or paraplegia. Postoperative complications were; proximal stent graft collapse (1), stroke (1), endoleak (3), left upper limb ischemia (2), external iliac artery dissection (2) and lower limb ischemia (3). Mean follow up of 36.2 months has shown no endoleak and no stent graft migration or collapse.

Conclusion: In our series, the good results of short and long term follow up of TEVAR prove its durability in treatment of traumatic thoracic aortic injury. Our follow up of CT scan did not show any stent graft complications. We suggest that the long term follow up of CT scan may not be needed.

0208

Single-stage Surgical Management for Complicated Thoracic Aortic Aneurysm via Semi-clamshell Approach

Hiroshi Furukawa, Takeshi Honda, Noriaki Kuwada, Hiroki Takiuchi, Takahiko Yamasawa, Yoshiko Watanabe, Yasuhiro Yunoki, Atsushi Tabuchi, Hisao Masaki, Kazuo Tanemoto

Kawasaki Medical School, Kurashiki, Japan

Background: We retrospectively evaluated the initial surgical experience and early clinical outcomes of surgical management for extensive complicated thoracic aortic aneurysm (CTAA) via semi-clamshell approach (SCSA).

Methods: Thirty-three patients (6 women and 27 men, mean age 69 ± 11 years) who underwent elective surgical intervention for CTAA by SCSA in our institute from 2004 to 2013 participated in this study. The indications leading to this approach were extensive true thoracic aortic aneurysm (TAA) in 20, complex extensive dissecting TAA in 9, recurrent distal arch aneurysm following central repair for type A acute aortic dissection in 3, and complicated mycotic TAA in 1. Left thoracotomy with a transverse sternotomy was made in the fourth intercostal space following the incision from the right sternal borderline to the anterior axillary line on the left. Subsequently, cardiopulmonary bypass was established and extensive graft replacement (GR) was conducted with hypothermia.

Results: Total arch replacement (TAR) was carried out in 22, descending with or without distal hemi-arch replacement in 6, TAR with descending aorta in 4, and extensive GR from ascending to descending aorta in 1. There were 3 hospital deaths (9.1%). Two patients required tracheotomy due to respiratory failure and new-onset cerebrovascular infarction was shown in 3. No mediastinitis was recognized. Over a median follow-up period of 36.0 ± 29.0 (1~88) months, the 1- and 3-year survival rates were 90.9% and 81.8% by Kaplan-Meier analysis.

Conclusions: Single-stage surgical management for extensive CTAA via SCSA may contribute to acceptable early clinical outcomes in high-risk patients.

0230

Septal Defect Occluders Plus Bare Stents as Adjunctive Measure of TEVAR in the Treatment of Stanford B Aortic Dissections with Distal Tears at Visceral Branch Area

Jun Zhao¹, Qingsheng You², Jiakai Mei¹, Mingzhe Shao¹, Ye Pan¹, Jian Zhang¹, Haisheng Wu¹

¹Vascular Surgery Division, General Surgery Department, 6th Affiliated People's Hospital of Shanghai Jiaotong University, Shanghai, China

²Cardiovascular Surgery Department, Affiliated Hospital of Nantong University, Nantong, China

Objective: To evaluate the strategy of septal defect occluders plus bare stents as an adjunctive measurement of typical thoracic endovascular aortic repair (TEVAR) in the treatment of aortic dissections with tears at the segment of visceral branches.

Methods: Patients of Stanford Type B aortic dissections revealed by CTA received the typical TEVAR treatment as the first step to seal the main tears. Then the tears at the visceral branch area were evaluated by aortography. Atrium or ventricular septal defect occluders were deployed at the tears, followed with bare stents placement over the occluders, as the adjunctive procedures of TEVARs.

Results: There were seven patients underwent the method. The occluders were successfully implanted in six cases, while failure of anchoring in one case. The alternative method of coil embolization was applied in this case. The completion aortography revealed good anchoring of the occluders, and false lumen were sealed immediately in five cases. The true lumens were expanded by the bare stents, while the visceral branches maintained patent. No paraplegia, lesion of visceral organs or other complications occurred.

Conclusions: The strategy of septal defect occluders plus bare stents as an adjunctive measure of thoracic endovascular aortic repair (TEVAR) in the treatment of aortic dissections with tears at the segment of visceral branches is a summation of the application of two simple techniques, which functioned as a rational approach. Acting as the adjunctive treatment as the tears in challenging anatomic situations, the method might accomplish a goal of "radical treatment" that a sole stent-grafting procedure incapable of achieving.

Endovascular Repair of Malperfusion in Acute Type B Aortic Dissections

Weimin Zhou, Wei Zhou, Jiehua Qiu, Qingwen Chen, Feng Chen, Jixin Xiong

Department of Vascular Surgery, the Second Affiliated Hospital of Nanchang University, Nanchang, China

Objective: To examine the feasibility, efficacy, and short to mid-term results of endovascular management of acute type B aortic dissection complicated by visceral or lower limb malperfusion.

Methods: A retrospective review was conducted to identify 23 consecutive patients with acute type B dissection complicated by visceral or lower limb malperfusion which treated endovascularly at a single center between July 2001 to December 2012. Of the 23 patients identified (20 men, 3 women; mean age, 52.5 ± 8.6 years; range, 42–75 years) presented with clinical and imaging evidence of end-organ malperfusion: 5 (21.7%) renal, 9 (39.1%) superior mesenteric artery, 3 (13%) celiac trunk and 6 (20.1%) lower limb; 2 renal and lower limb.

Results: All patients had stent-graft coverage of the proximal entry tear; 11 (47.8%) patients required additional branch vessel stenting. Successful correction of malperfusion was achieved in all the patients and the successful rate of operation and technology was 100%. In 1 patient, ischemia in the lower limb was resolved but not one week later, and a stent was implanted to the right iliac artery, then the lower limb ischemia resolved again. In another patient, complicated with lower limb ischemic necrosis, amputation was performed after stent-graft placement one stage. The duration of follow-up was 6 months to 72 months, mean 21.4 ± 11 months. No migration of stent-graft and end-organ ischemia. No paraplegic patients in the group.

Conclusion: Endovascular coverage of the proximal entry tear in acute type B aortic dissections complicated by end-organ malperfusion is a reasonable first line of treatment. But some cases should combine with branch vessel stenting or other procedures.

0268

The Misunderstanding and Comprehension of Hybrid Operation for Treating Aortic Dissection Involving Aortic Arch

Hao Ren, Hong-bo Ci, Sheng Guan, Qing-bo Fang, Sailimu, Xiao-hu Ge

Department of Vascular Surgery, The People's Hospital of Xinjiang Uigur Autonomous Region, Urumchi, China

Objective: To evaluate the misunderstanding and comprehension of hybrid operation for treating aortic dissection involving aortic arch.

Methods: From March 2009 to November 2013, a total of 13 patients received hybrid operation for aortic dissection involving

aortic arch in the People's Hospital of Xinjiang Uigur Autonomous Region were enrolled, male 11, female 2, aged 36–60 years old, mean age ($44 + 6.8$) years old. All patients were type-B aortic dissection. All of them were not suitable to be treated with endovascular exclusion monotherapy. The ascending aorta-brachiocephalic artery bypass and left carotid artery bypass was established with median sternotomy approach and neck incision in 13 patients, and 2 patients did left subclavian artery bypass additionally, then retrograde endovascular stent graft implantation was used. CTA scanning at 3-month, 9-month, 1-year and every-year after operation showed no stent grafts translocation and bypass graft obstruction.

Results: The surgical operation and stent grafts implantation were completely successful. Angiography showed 1 case had end leakage and other cases no obvious displacement or end leakage of stent grafts in operation. Blood flow in true lumen of aortic dissection was recovered and all of bypass grafts were unobstructed. No death and severe complications occurred. All patients were followed-up with 3 to 56 months [(29.0 ± 10.2) months], and all patients resumed normal life. Enhanced CT scanning after operation showed 1 case had endoleak and other cases no endoleak, stent grafts translocation and bypass graft obstruction. No signs of brain and limb ischemia were observed.

Conclusions: To summarize misunderstanding and experience by continuous explore feature of hybrid operation for treating disease involving aortic arch. We developed a more reasonable surgical treatment options that can improve the success rate of complex aortic dissection surgery, and ultimately achieve better surgical results.

0275

Occlusion of the True Lumen with the Stanford B Type Aortic Dissection

Hong-bo Ci, Guang-lei Tian, Jia Re Ke Tang, Hao Ren, Qing-bo Fang, Sheng Guan, Xiao-hu Ge

Division of Vascular Surgery, The people's Hospital of Xinjiang Uigur Autonomous Region, Urumchi, China

Objective: To review the endovascular treatment about resolving the difficulties of entering into the Stanford B type aortic dissection of true lumen in endovascular graft exclusion.

Method: From January 2006 to December 2013, 151 cases of Stanford B type aortic dissection were analyzed retrospectively. The operations performed under DSA monitor. The wire was difficult to enter into the true lumen of aortic dissection in 8 cases. The methods were used to resolve these problems including catheter smoking technique, guide wire transfixion between proximal and distal, left brachial artery puncture to test a low-pass up, different position projection and other methods to ensure that the guide wire into the true lumen.

Result: 8 cases of occlusion of the true lumen, the guide wire were difficulties into the true lumen, 7 cases were sham occlusion of the true lumen. 1 case of the guide wire can't into the true lumen and proved to be true lumen occlusion to give up operation and conservative treatment instead.

Conclusion: The preoperative and intraoperative should evaluate vascular conditions, the use of a variety of endovascular techniques to ensure that the wire enter into the true lumen. To avoid wire enter into the false lumen and causing disastrous consequences.

Abdominal Aortic Aneurysms 2

Session Code: FP8C
0830-1000, 7 September
Function Room 1, 2/F

0096

Stentgraft Limb Occlusion after EVAR

Naoki Hayashida, Souichi Asano, Nobuyuki Hirose, Takako Nishino, Masanao Ohba, Masashi Kabasawa, Tomonori Sueta, Hiroyuki Kito, Kouzou Matsuo, Hirokazu Murayama

Chiba Cerebral and Cardiovascular Center, Chiba, Japan

Objectives: We studied whether deployment of a stentgraft limb in the external iliac artery (EIA) increases the ratio of limb occlusion following endovascular aneurysm repair (EVAR).

Subjects: One hundred and thirty eight patients (128 male; mean age of 77 years) with abdominal aortic aneurysm underwent EVAR in our center between 2007 and 2013. The device comprises Excluder in 51 cases, Zeinth in 44 cases, Endurnat in 40 cases and others in 3 cases. Thirty five patients underwent stentgraft limb deployment in the EIA. Two out of 35 patients had bilateral deployment in the EIA.

Results: There were 6 limb occlusions (6/276 limbs 2.2%). The patients with limb occlusion are all male and a mean age of 83 years. The onset was between 10 days and 2.3 years after EVAR. All patients had symptoms such as limb pain or intermittent claudication. The device comprises Endurant in 3 cases, Zenith in 2 cases, and Excluder in one case. They were treated by thrombectomy and stent placement in 4 cases, femoro-femoral crossover bypass in 2 cases. Three limb occlusions were found in the stentgraft limb deployment in the EIA (3/37; 8.1%). On the other hand, three limb occlusions were found in the stentgraft limb deployment in the common iliac artery (CIA) (3/236; 1.3%). The rate of limb occlusion was significantly higher than in the EIA landing group than in the CIA landing group ($p < 0.05$).

Conclusions: This study demonstrates the significantly higher occlusion rate for stentgraft limbs deployed in the EIA compared to limbs placed in the CIA. We should be careful for the limb occlusion in the EVAR cases which deploys limb in the external iliac artery.

0171

Post EVAR Common Iliac Artery Enlargement after Flared Iliac Limb Stent-graft

Wai Hong Chan¹, Yin Chun, Skyi Pang¹, Kin Leung, Edward Hui², Ling Chu, Renny Yien¹, Chung Ngai Tang¹

¹Pamela Youde Nethersole Eastern Hospital, Hong Kong, Hong Kong

²Ruttonjee Hospital, Hong Kong, Hong Kong

Background and Objectives: Endovascular aortic repair (EVAR) becomes the first line treatment for majority of infra-renal abdominal aortic aneurysms. Re-intervention remains one of the disadvantages for EVAR.

Flared iliac limb is commonly used when common iliac artery (CIA) diameter ranges from 15 to 25 mm. Post-stenting follow up imaging is usually recommended to look for further aneurysmal changes especially over CIA, which may results in type Ib endoleak.

We would like to know the chance of post-operative CIA dilatation in this group of patients.

Methods: Patients underwent EVAR with simple bifurcated graft in Hong Kong East Cluster between 2009 and 2013 were recruited. Diameters of bilateral CIAs were measured in the pre-op and latest computerized tomography.

Results: 112 patients with a total of 224 CIAs were included. 92 (41.1%) of the CIA diameters were between 15 mm and 25 mm. The mean age of patients was 77 ± 8 . Flared iliac limb was used in 59 cases (64.1%). There were 63 CIAs with diameter greater than 25 mm. All were managed by coil embolization of internal iliac artery with distal stent landing on external iliac artery.

16 out of 59 (27.1%) flared iliac limb stent-graft used with CIA dilatation of more than 3 mm. Only 14 out of 103 (13.6%) non-flared iliac limb stent-graft used with more than 3 mm CIA dilatation. The difference between two groups is statistically significant ($p = 0.018$). 4 patients (6.8%) with flared iliac limb stent developed type Ib endoleak in follow up imaging require re-intervention.

Conclusions: Flared iliac limb stent-graft in CIA greater than 15 mm is associated with post-operative CIA dilatation, which may result in type Ib endoleak. If technically feasible, other measures like iliac bifurcated device, sandwich technique, or coil embolization of internal iliac artery with distal landing at external iliac artery should be considered especially for young patients.

0179

Surgical Outcome of Aortic Aneurysm Repair: A Single Center Experience

Cristina Marie Lajom, Aries Garin, Pio Purino, Josefino Sanchez, Alexander Lat, Lara Lapena-Kare

University of Santo Tomas, Manila, Philippines, The Philippines

Abdominal aortic aneurysm (AAA) is a relatively common and often fatal vascular condition that mostly affects older patients. Since its first description by Vesalius in the 16th century, remarkable progress

has been made in the field of vascular surgery. Elective repair of abdominal aortic aneurysm is one of the most frequent vascular surgery. Endovascular aortic repair (EVAR) has gained a majority of the cases especially in the elderly.

This retrospective study aims to describe the surgical outcome of patients with aortic aneurysms who underwent endovascular and open repair from the year 2010 to 2013 at the university hospital. A total of 11 patients were included in the study with a mean age of 69 years. The aneurysm size ranged from 4.2 cm to 10 cm in its widest diameter. Eight patients underwent open repair and 3 underwent EVAR. The mean hospital stay post-op is 8.9 days. Eight of 11 patients were admitted in the ICU with a mean duration of 5.87 days. The mean operative time for EVAR is 109 minutes compared to open repair with 273 mins. The EVAR group had negligible blood loss compared to the open group that has an average blood loss of 754 ml.

EVAR offers a minimally invasive procedure for patients with aortic aneurysms which offers shorter hospital stay as well as ICU admission, operative time, and blood loss. It offers a better post-operative quality of life with early mobilization and aesthetically acceptable post-operative sites.

Based on the data gathered, despite the current population who underwent EVAR, this yields a positive immediate post-operative outcome and offering this procedure to patients with aneurysm could be beneficial.

0206

Results of Small Abdominal Aortic Aneurysm Surveillance

Seoung-Wook Choi, Seon-Hee Heo, Yung-Seok Park, Yang-Jin Park, Dong-Ik Kim, Young-Wook Kim

Division of Vascular Surgery, Department of Surgery, Samsung Medical Center, Sungkyunkwan University School of Medicine, Seoul, Republic of Korea

Purpose: To observe the natural course of small abdominal aortic aneurysm (SAAA) in Korean patients and to determine factors associated with higher growth rate of the SAAA.

Method: With defining SAAA as an AAA with diameter between 3 cm–5 cm, we analyzed database of SAAA patients who were prospectively observed in a single institution during the past 10 years. Among all SAAA, we excluded patients with short duration (<12 months) of surveillance and SAAA related with connective tissue disease, aortic dissection, infection or vasculitis. We measured maximal outer-to-outer aortic diameter with electric caliper perpendicular to the long axis of aorta on CT scan. Surveillance interval was 1 year and 6 months for patient with 3 mm–3.9 mm SAAA group and 4 mm–4.9 mm SAAA group, respectively. With the calculated AAA growth rate (mm/year) and variables and we conducted multivariate analysis to determine factors related with higher growth rate of SAAA.

Results: Among 400 SAAAs, 168 SAAA was included for the analysis. Mean age was 72.3 ± 8.3 years and 86% of the patients

were male. Mean initial diameter of SAAA was 37.5 mm and it became to mean 44.9 mm on the last follow-up CT image showing AAA growth rate 2.4 mm/year. During the follow-up period of 34.6 months (median), 4 AAA ruptures, death including 2 AAA related death developed and AAA repair was required in 59 (35%) patients. On a risk factor analysis for higher growth rate of SAAA, initial diameter was the only significant factor related with higher growth rate ($P = 0.024$, by simple linear regression).

Conclusion: Though growth rate was slow in most SAAAs, we found that 35% of SAAA patients required treatment due to various causes and 4(2.4%) AAA ruptures developed from the SAAA patient pool. Initial diameter was an only significant factor associated with faster growth of the SAAA.

0223

The Research on the Effect of Hyperhomocysteinemia on Abdominal Aortic Aneurysm

Jie Liu, Wei Guo, Xin Jia, Hongpeng Zhang, Senhao Jia, Minhong Zhang

Department of Vascular Surgery Chinese PLA General Hospital, Beijing, China

Background and Objectives: To study the relationship between HHcy and AAA and the effect of HHcy on AAA.

Methods: Firstly, a total of 121 participants met the inclusion criteria including 58 AAA patients and 63 controls in our case-control study. Secondly, Pubmed and Embase were searched for case-control studies for meta-analysis before December 2013, with the text terms homocysteine, hyperhomocysteinemia, aneurysm. Thirdly, fifty adult SD rats were randomly divided into four groups. Group A and Group B were infiltrated abdominal aorta with 0.9% saline, Group C and group D were infiltrated abdominal aorta with 0.5 mol/L calcium chloride.

Results: Firstly, thirty-eight (65.5%) of the AAA patients had elevated levels of homocysteine compared to 17 (27%) in the case control group. Univariate logistic regression showed that a 3.35-fold greater risk of AAA in subjects who have the HHcy, as compared with those having normal hcy level. (OR = 3.35; 95% CI = 1.14–9.80; $P = 0.03$). The diameter of aneurysm was 5.66 ± 1.49 cm and 5.11 ± 0.98 cm ($P = 0.18$) and no correlation between plasma homocysteine level and the diameter of aneurysm was found ($r = 0.09$, $P = 0.48$). Secondly, 11 studies with 7050 participants were identified and analyzed. Overall, HHcy was associated with an increased risk of AAA (OR = 4.33; 95% CI 2.40–7.80). Thirdly, HHcy greatly increased the incidence of CaCl_2 -induced AAA in SD rats (group C versus group D: 38.5% versus 92.3%; $P < 0.05$). HHcy aggravated the severity of abdominal aortic aneurysm in rats, due to augmenting the degradation of elastin, which was caused by the increased levels of interleukin-6, interleukin-1 β , and SOD in the AAA tissue.

Conclusions: HHcy is a risk factor of AAA. HHcy significantly increased the incidence of CaCl₂-induced AAA in SD rats. Clinical trials in this direction are warranted.

0246

Characters of complications in endovascular repair of abdominal aortic aneurysms in high-risk patients

Hejie Wu, Zhengdong Fang, Xiaotian Wang, Can Cheng, Xiaojie Sun

Department of vascular surgery, Anhui Provincial Hospital, Hefei Anhui province, China

Objective: To review the characters and treatment strategies of complications after endovascular aneurysm repair (EVAR) of high-risk abdominal aortic aneurysms in our medical center.

Methods: Fifty eight elective EVAR cases in high-risk patients from January 2008 to December 2013 were analyzed retrospectively, including perioperative period and mid-term results.

Results: The technical success rate was 96.6 percent (56 of 58 patients). The overall complication rate in perioperation period was 32.8 percent (19/58). Eleven systemic complications (19.0 percent), 16 primary endoleaks (27.6 percent), 7 access site complications (12.1 percent) were observed. The follow-up rate was 86.2% (51/58). During the follow up period, the mortality was 7.8 percent (4 cases of 51 patients), the re-intervention rate was 7.8 percent (4 cases of 51 patients). The overall complication rate was 29.4 percent (15/51), including systemic complications 3.9 percent (2/51), secondary endoleak 9.8 percent and graft-related complications 11.8 percent (6/51).

Conclusions: Endoleak, graft-related complications continue to be the major causes of re-intervention of high-risk aneurysm patients, Long-term follow-up is extremely important.

0247

Open and endovascular management of isolated iliac artery aneurysms

Zhengdong Fang, Hejie Hu, Xiaotian Wang, Can Cheng, Xiaojie Sun

Department of vascular surgery, Anhui Provincial Hospital, Hefei Anhui province, China

Objective: Isolated iliac artery aneurysms (IAAs) are rare but associated with significant morbidity and mortality when ruptured. This study assess our experience with open and endovascular repairs of isolated IAAs.

Methods: We retrospectively reviewed the charts of all patients who underwent repair of isolated IAAs from October 2006 to February 2014. Baseline characteristics, procedure-related variables, and follow-up data were retrospectively reviewed.

Results: A total of 17 patients were treated with isolated IAAs. There were 5 open and 12 endovascular repairs. In the open group, patients were treated with unilateral iliac prosthetic graft interposition, aorto-biiliac or aorto-bifemoral arterial bypass graft, ligation of the internal iliac artery. In the endovascular group, patients were treated with unilateral iliac stent-grafts, bifurcated aortic stent-grafts, or coil embolization alone. Preoperative comorbidities were similar between the two groups, there was no aneurysm-related mortality in either group. During the follow up period, there were no postoperative ruptures or aneurysm-related death.

Conclusion: In appropriately selected patients, endovascular repair of isolated IAAs is safe and an effective alternative to open repair. But in special situation, technical controllability of open repair may be better than endovascular repair, treatment should be made according to the patient's general condition and anatomy of the aneurysm.

0261

Open Repair of Abdominal Aortic Aneurysm: 10 Years Experience in a Single Center

Ding Yuan, Jichun Zhao, Yukui Ma, Bin Huang, Yi Yang, Fei Xiong, Guojun Zeng, Xiyang Chen

Division of Vascular Surgery, West China Hospital, Sichuan University, China, Sichuan University, Sichuan, China

Aim: Open repair of abdominal aortic aneurysm (AAA) produced superior durability has been challenged by advocates of EVAR. However, open repair treatment may not be substituted for EVAR because of the similar long-term survival and the lower cost. This study will analyze the short-term and long-term outcome of AAA with open repair among 10 years.

Material and Methods: From January 2003 to April 2013, 206 patients underwent elective open repair in the vascular center of the West China Hospital. Patients were followed for perioperative mortality and complications, long-term survival, graft-related complications until the end of July 2013. Predictive factors of the mortality were determined by multivariate analysis.

Results: There were 116 males and 90 females, with a mean age of 57.8 ± 13.4 years. The 47.8% of patients were less than 60 years. The mean follow-up of patients was 50.2 months. The aortic cross-clamp and operation duration was 60.5 ± 27.0 min and 206.3 ± 61.6 min, respectively. The median length of hospital stay was 10 days and the median of hospitalization expenses was RMB 46 ± 7 thousands. Perioperative mortality (30 days) was 7.3%, and 5-years survival was 86.8%. Six cases (2.9%) with graft-related complications were reinterventions in long-term follow-up. Forty-nine patients with rupture AAA were emergency operation, in which the perioperative survival rate was 79.6%. Rupture of aneurysm wall was the independent risk factor of perioperative mortality (OR = 11.1, P = 0.000). Furthermore, the intramural thrombus was the protective factor for RAAA (OR = 4.2, P = 0.001).

Conclusion: Open repair remains a safe and durable option for the management of AAA. Specially, the advantage of the lower expenses and the long-term survival will be more durable in Chinese patients. In addition, the graft-related reintervention is superior to that of EVAR. Finally, open repair is still the effective treatment for rupture AAA before the identified outcome of EVAR for rupture AAA.

Asian Venous Forum: Varicose Vein

Session Code: FP8D
0830-1000, 7 September
Function Room 2, 2/F

0031

Non-invasive Evaluation of Venous Flow Parameters in Normal Limbs and Limbs with Primary Varicose Veins in Malaysia

Sheau Wann Tong^{1,2}, Zainal Ariffin Azizi²

¹University Putra Malaysia, Selangor, Malaysia

²Hospital Kuala Lumpur, Kuala Lumpur, Malaysia

Introduction: The role of air-plethysmography in evaluating normal limbs and limbs with primary varicose veins is yet to be defined in Malaysia.

Objectives: Our study was aimed to determine the values of venous flow parameters in normal subjects and in patients with primary varicose veins; and to compare local findings with previous published works.

Methods: This hospital-based cross-sectional study compared normal limbs to limbs with primary varicose veins (clinical class 2). Venous flow parameters i.e. venous filling index (VFI), ejection fraction (EF), and residual volume fraction (RVF), were measured using air-plethysmograph APG® Model 1000C (ACI Medical).

Results: One hundred and fifty-one (151) subjects, with mean age of 46.8 years were enrolled. Of 290 limbs assessed independently, 190 limbs had primary varicose veins, and 100 were normal limbs with no varicose veins and served as control limbs. Normal limbs had mean VFI of 0.79 ± 0.78 ml/s, EF $69.11 \pm 17.46\%$ and RVF $45.90 \pm 23.97\%$. Limbs with primary varicose veins had VFI of 3.09 ± 2.22 ml/s, EF $48.24 \pm 17.66\%$ and RVF $61.00 \pm 19.23\%$. Statistical significance was observed in VFI, EF and RVF ($p < 0.005$).

Conclusion: There is a significant difference in the measured venous parameters between normal subjects and patients with primary varicose veins as measured by air-plethysmography. Air-plethysmography is useful in evaluating venous diseases of lower limbs in view of its reproducibility and non-invasiveness.

0069

Clarivein, A New Mechanochemical Endovenous Ablation Tools- Outcomes from 6 Months Cohort

Kwok Fai Cheung, Po Yan Wong, Wai Yin Lo, Kwong Man Chan, Leung Sing Ho

Princess Margaret Hospital, Hong Kong, Hong Kong

Introduction: Varicose vein is a common surgical disease with a wide spectrum. Treatment modality depends on the severity. Clarivein, a new mechanochemical endovenous ablation of great saphenous vein (GSV) is chosen as a new tools to treat patients at our ambulatory vein center.

Method: It is a perspective cohort study. Patients treated with Clarivein at the center started from July 2013 were included. Besides demographic informations, staging of varicose vein and symptoms were charted. Regular follow up with doppler ultrasound study of treated limb at post operative 1,4,12 and 26 weeks given.

Results: During July 2013 to March 2014, 28 patients treated with Clarivein. All patient found symptomatic relief. Neither deep vein thrombosis nor wound complication was detected. 2 cases found early recannulation of GSV during first week postoperative follow up. 4 cases of staining along course of GSV were found.

Conclusion: In selected patient, Clarivein is an effective treatment modality of varicose vein. Short term results were encouraging.

0077

Assessment of Great Saphenous Vein (GSV) Reflux during Temporary Interruption of Reflux to the Calf with Tourniquet Occlusion

Tomohiro Ogawa, Shunichi Hoshino

Fukushima Daiichi Hospital, Fukushima, Jersey

Background and Objective: The current treatment of GSV reflux with primary varicose veins is the ablation of GSV using laser, RF or sclerotherapy. However, Pittaluga reported that phlebectomy with preservation of GSV (ASVAL) is effective for the treatment of mild varicose veins with the abolishment rate of saphenous reflux is 70%. We set up an experimental model for temporary interruption of reflux to the calf with tourniquet occlusion and assessed GSV reflux in the patients with primary varicose due to GSV reflux.

Methods: 50 cases (60 legs) with varicose veins in their calf and reflux of great saphenous vein participated in this study. They underwent the examination for venous reflux using duplex ultrasound. The GSV reflux and diameter at 2 cm below sapheno-femoral junction was measured with and without tourniquet occlusion below and above knee under sitting position using pneumatic cuffs. Venous reflux was defined as venous reflux time more than 0.5 sec.

Results: The average of saphenous venous diameter without tourniquet, with below and above knee tourniquet occlusion was 5.8, 5.4, and 5.1 mm respectively a significant difference. The average

of venous reflux time without tourniquet, with below and above knee tourniquet occlusion was 3.8, 3.6 and 2.1 sec respectively. The average of venous reflux time with above knee tourniquet occlusion became significantly shorter than that without tourniquet and with below knee tourniquet occlusion. Disappearance of venous reflux with below and above knee tourniquet occlusion was found in 5% and 17% legs respectively.

Conclusions: The results of decreased GSV diameter and reflux time with tourniquet occlusion showed calf venous reflux makes thigh saphenous venous reflux worse and some cases can preserve competent saphenous vein above knee.

0102

The Effect and Complications of Femoral and Saphenous Nerve Blocks in Ambulatory Great Saphenous vein Surgery

Koji Shinozaki, Tomohiro Katayama, Takaaki Ishii, Ken Tono, Yasuhito Kawasaki, Minoru Otsuru, Kensaku Mayumi, Ryosuke Fukuoka, Jyunji Nishiyama, Taku Mayahara, Seiji Yasuda

Kobe Ekisaikai Hospital, Kobe/Hyogo, Japan

Purpose: To evaluate the effect and safety of the Femoral and Saphenous Nerve Blocks for Great Sphenous Vein Stripping in day surgery.

Methods: The outcome was compared retrospectively between Femoral Nerve Blocks plus TLA (Tumescent Local Anesthesia) and Femoral and Saphenous Nerve Blocks plus TLA in the GSV operation. Seventy-seven patients underwent GSV stripping under Femoral Nerve blocks (1% Lidocaine, 10 ml) plus TLA. Thirty-four patients underwent Femoral Nerve Block (Lidocaine, 2 ml) and Saphenous Nerve Blocks (Lidocaine, 10 ml) plus TLA. Nerve blocks were injected under ultrasound guide. When patients complained for a pain, additional anesthesia was used intravenously. Patients were tested after 4 hours of bed rest.

Results: Two patients out of 77 patients with Femoral Nerve Block had paralysis of quadriceps femoris muscles and required overnight stay. One had complication of falling down. No paralysis after Femoral and Saphenous Nerve Blocks was observed.

Conclusion: The Femoral and Saphenous Nerve Blocks plus TLA is safe and effective anesthesia in ambulatory GSV surgery.

0143

Factors of Venous Occlusion and Complications in Endovenous LASER Ablation for Varicose Veins

Dong-ik Kim, Yang-Jin Park, Young-Wook Kim, Yoong-Seok Park

Samsung Medical Center, Sungkyunkwan University, Seoul, Republic of Korea

Purpose: This study was designed to analyze the factors of post-operative saphenous vein occlusion and complications in endovenous LASER ablation (EVLA) for great saphenous varicose veins.

Method: We retrospectively analyzed 169 limbs of 146 patients who were treated with the EVLA (30 J/cm) for primary varicose vein associated with great saphenous vein (GSV) reflux. The diameter and depth of GSV were checked with duplex scan preoperatively. The complications and status of saphenous vein were analysis after 1 month postoperatively.

Results: There were 141 limbs (83%) with complete occlusion and 28 limbs (17%) with partial occlusion of saphenous vein after 1 month postoperatively. The preoperative median size of GSV were 55 mm in complete occlusion group and 66 mm in partial occlusion group ($p = 0.04$). There were 3 (1.8%) deep vein thrombosis (DVT) after surgery. All of the DVT were localized in the vicinity of saphenofemoral junction. But 2 of DVT resolved completely within 1 month postoperatively. 29 limbs (17.2%) complained cord feeling on thigh. But the preoperative diameter of GSV was not affected to cord feeling ($p = 0.182$). 44 limbs (26%) showed numbness on ankle area. But there was no significant factors affecting ankle numbness. There was no significant complication besides DVT, cord feeling and ankle numbness related with EVLA.

Conclusion: This study showed that EVLA had lower rates of complications and high rate of occlusion of saphenous vein.

0188

A Novel Technique for Sural Nerve Protection during Short Saphenous Vein Endothermal Ablation

Juefei Feng¹, Huimin Liu¹, Sriram Narayanan^{1,2}

¹Tan Tock Seng Hospital, Singapore, Singapore

²National University of Singapore, Singapore, Singapore

Background: The sural nerve (SN) comes to lie close to the short saphenous vein (SSV) somewhere half-way down the leg, and is at risk of injury during endovenous thermal ablation from this point distally. We describe a novel technique to identify this 'at risk' point.

Methods: The results of 42 consecutive SSV radiofrequency ablations performed under local anaesthesia using the VNUS Closurfast catheter were analysed. The SSV was mapped by ultrasound

(US) from the sapheno-popliteal junction (SPJ) to the lower 1/3 of leg using transverse scanning and a careful attempt made first to identify the SN as a hyperechoic spot within the SSV fascial envelope. 1% Lignocaine (2–3 ml) was then injected in a radiate fashion at a point 8 cm distal to the SPJ along the SSV course. The lower 1/3 of leg distal to this injection point was then tested for sensory loss along the course of the SSV. Loss of sensation meant that the SN had come to lie close to the SSV more proximally and hence could not be safely ablated.

Results: The ‘at-risk’ point of the SSV was identified in 26 patients on US, 37 by local anesthetic guided localisation and in 40 of 42 patients by a combination of the two methods. It could not be definitely identified in 2 patients who were then converted to open SPJ ligation.

Technical success of the primary SSV ablation was 100%, with one early recurrence at 6 months. There was no sural nerve damage on sensory testing in any of the 42 patients at 6 weeks post-operatively.

Conclusions: The technique described allows the operator to safely proceed with SSV endovenous thermal ablation in almost all cases, or to convert to an open SPJ ligation when the ‘at-risk point’ cannot be reliably determined.

A short video of the technique will be shown.

0189

Anterior Accessory Saphenous Vein—To Treat or Not to Treat

Huimin Liu¹, Yewfah Fong¹, Sriram Narayanan^{1,2}

¹Tan Tock Seng Hospital, Singapore, Singapore

²National University of Singapore, Singapore, Singapore

Background: The indications to treat the anterior accessory saphenous vein (AASV) during endothermal ablation of the great saphenous vein (GSV) are as yet unclear. We analysed the role of AASV reflux in recurrence after endovenous laser therapy (EVLT) of the GSV in a historical cohort of patients.

Methods: A retrospective analysis of consecutive EVLT (Dornier 940 nm Laser) procedures performed at a single centre between 2006 and 2011 for GSV reflux was done. All cases were traced for recurrence using the National Electronic Health record and paired duplex scans from the time of the operation and at recurrence were compared for rates patterns of recurrence in the AASV and GSV.

Results: Of the 326 EVLT procedures performed in the said time period, duplex data on 307 patients was traced for analysis. 206 of these had isolated GSV reflux with no AASV seen on duplex. 101 patients (33%) had an AASV on the original duplex of which 56 were incompetent (55%).

Recurrence patterns showed that 32 patients (10.3%) had a recurrence with a median time to recurrence of 11.3 months. However, the recurrence rate for original GSV reflux only patients was 3% (6/206), GSV reflux but competent AASV was 9% (4/45) and for those with AASV reflux was 39% (22/56). The median time to recurrence was 13.6 months for GSV reflux only, 9.3 months for

those with competent AASV and 6.2 months if the AASV was incompetent.

Conclusion: AASV reflux if not treated leads to an over ten-fold increase in the recurrence rate after GSV ablation. The time to recurrence is also much shorter. Patients with competent AASV but planned treatment for GSV reflux should at least be counselled that their rates of recurrence are slightly higher than those with no AASV present, and that such a recurrence could occur earlier than usual.

0216

Comparison of Clinical Results of Unilateral and Bilateral Ablations for Varicose Veins

Jin Hyun Joh, Ho-Chul Park, Jung-Hyun Choi

Kyung Hee University Hospital at Gangdong, Seoul, Republic of Korea

Background: Radiofrequency ablation (RFA) is commonly used modality for the treatment of varicose veins. Approximately 20% of varicose vein involves bilaterally. Patients would prefer a simultaneous bilateral procedure instead of two separate unilateral procedure. There is currently little evidence comparing bilateral and unilateral varicose vein surgery. The purpose of our study is to report clinical outcomes of unilateral and bilateral RFA for varicose vein.

Methods: RFA using ClosureFast catheter was done according to the manufacturer's instructions for use. We retrospectively collected data of the patients demographics, risk factors, and clinical outcome after RFA from March 2009 to May 2014. We investigated CEAP score, venous clinical severity score (VCSS), and quality of life (QoL) score. The paired t-test and bivariate correlation analysis using SPSS Ver. 19.0 (Armonk, NY) were used for statistical analysis.

Results: RFA was done in total 657 limbs in 484 patients. The female patients were 57.6%. The mean age was 52.7 ± 12.3 years (range 19–84). RFA of unilateral limb was done in 311 (64.3%) patients and bilateral limbs in 173 (35.7%) patients. The demographic characteristics showed the baseline characteristics were similar. Preoperative mean diameter of saphenous vein was 6.7 ± 1.8 mm (3.5–11.2 mm). Occlusion rate after 2 years was 94.5%. Clinical outcomes of clinical class, VCSS, QoL score were improved significantly, 2.33 ± 0.78 to 1.29 ± 0.96 , 3.48 ± 0.98 to 0.63 ± 1.16 , 6.91 ± 6.69 to 3.38 ± 4.74 , respectively. The preoperative and postoperative differences of QoL score for unilateral and bilateral RFA were 3.25 ± 2.34 to 4.01 ± 2.93 , respectively ($P = 0.343$).

Conclusions: RFA showed the good clinical outcomes in terms of clinical class, VCSS, and QoL score. The QoL score is similar for unilateral and bilateral RFA for varicose veins.

0024

Preoperative Evaluation and Revascularization of the Coronary Artery in Patients with Critical Limb Ischemia

Ryosuke Taniguchi, Kunihiro Shigematsu, Toshiaki Watanabe

Division of Vascular Surgery, The University of Tokyo, Tokyo, Japan

Background and Objectives: Patients with critical limb ischemia (CLI) who are candidates for revascularization are consulted in advance to a cardiologist at our division, normally resulting in a coronary angiography (CAG) and if necessary, a coronary revascularization (CR). In this study, we sought to elucidate the efficacy of treating coronary artery disease (CAD) together with CLI.

Methods: CLI inpatients between 2004 and 2010 were included in this retrospective study. CAD was termed as a history of AMI or a >50% stenosis in ≥ 1 coronary artery. Overall survival (OS); amputation free survival (AFS); major adverse limb event (MALE) and 30 day perioperative death (POD) was used as an objective performance goal.

Results: A total of 245 patients (mean age, 69; 71% male; 80% ASO, 60% DM, 35% dialysis dependent, 46% CAD) with a median follow up of 29 months were included in the analysis. Of the 289 limbs, 58% underwent revascularization. Preoperative CAG was performed in 43% of patients (106/245, 123 limbs) and 25% (27/106, 31 limbs) underwent CR.

CAD patients had significantly low OS, AFS and MALE + POD (47% vs 71% ($p < 0.01$), 47% vs 63% ($p < 0.05$) and 61% vs 71% ($p < 0.05$), respectively, at 5 years). There were no significant differences in AFS or MALE + POD between those with and without preoperative CAG. There was also no significant difference in OS, AFS or MALE + POD between CAD patients with or without preoperative CR.

Conclusions: CAD comorbidity resulted in worse results for the limb as well as a poor prognosis. Preoperative CR may contribute to a better prognosis considering the selection bias of their electives being high risk patients. Evaluation of the coronary artery did not have apparent adverse effects to the limb and should be considered in preoperative cases.

Successful Limb Salvage Relating to Wound Location, Infection and Revascularization for Critical Limb Ischemia Patients

Arunesh Majumder^{1,2}, Jackie Ho Pei¹

¹National University Hospital, Singapore, Singapore

²Khoo Teck Puat Hospital, Singapore, Singapore

Introduction: Current peripheral arterial disease (PAD) classifications have low predictive power on limb salvage in critical limb ischemia (CLI) patients presenting with tissue loss. A new stratification system using Wound, Ischemia and Foot Infection has been proposed. We aim to examine the association of wound, infection & revascularization with limb salvage rate of our CLI patients.

Materials and Methods: A retrospective analysis of consecutive CLI patients with tissue loss treated by a single surgeon, between January 2012 & December 2013 was performed. "Endovascular first" approach for revascularization was adopted for all patients. The same surgical team was responsible for treatment and healing of all the wound(s). Data was collected from a prospectively maintained database regarding co-morbidities, initial wound location (toe, forefoot, heel or ankle), status of revascularization (direct, indirect or failed), & presence of infection. The primary endpoint of this study was major amputation and PAD related mortality. All factors were analyzed in both univariate & multivariate model. Kaplan Meyer curve was used to estimate limb salvage rate & amputation free survival. p value < 0.05 was taken as significant.

Result: 74 patients with 82 affected limbs were treated. Limb salvage rate & amputation free survival were 83.4% & 73.2% at 6 months. Heel wound was associated with poor outcome in univariate analysis. Successful revascularization, whether direct or indirect, was associated with reduced risk of major amputation and PAD related death in both univariate and multivariate analysis. Among patients with heel lesion, 37.5% with direct revascularization & 50% with indirect revascularization eventually had a major amputation or PAD related mortality. 60% patients with toe lesion and failed revascularization had a similar outcome. Infection in the wound at the initial presentation did not appear as a statistically significant determinant of the adverse outcome.

Conclusion: Location of wound and successful revascularisation are important determinants of successful limb salvage in CLI patients.

Early Experience of Combined Maggot Debridement Therapy and Negative Pressure Wound Therapy to Heal Wounds in Critical Limb Ischemia Patients after Revascularization

Amritpal Singh, Jackie Pei Ho

National University Hospital, Singapore, Singapore

Background and Objectives: Wound healing is the ultimate step to salvage the threatened limb of critical limb ischemia (CLI) patients with tissue loss after revascularization. Difficulties are encountered in patients with multiple medical co-morbidities and in situations with extensive tissue loss on presentation. We here report the early experience of providing maggot debridement (MDT) followed by negative pressure wound therapy (NPWT) in wound healing for CLI patients after limb revascularization.

Methods: A retrospective review of CLI patients who presented to our unit (January 2012 to December 2013) with advanced tissue loss underwent MDT and NPWT after successful revascularization was performed.

All the patients had revascularization of their ischemic limbs done. MDT was commenced after initial minor amputation or debridement of non-viable tissue. NPWT was then followed when non-viable tissue was considered minimal. Success was defined as complete wound healing while failure was defined as the need for major amputation.

Results: A total of 14 patients (11 males and 3 females) with 15 limbs underwent combined MDT and NPWT after successful revascularization during the study period. Twelve (85.7%) patients had diabetes, 10 (71.4%) had ischemic heart disease and 9 (64.3%) had dialysis dependent renal failure. The location of tissue loss involved base of toe(s) in 8, heel in 5, and lateral aspect of the foot in 2 limbs. Direct revascularization was achieved in 14 (93.3%) of the limbs. One (6.7%) patient died of cerebrovascular accident before the wound healed. Complete wound healing was achieved in 11 (73.3%) limbs. The wound deteriorated further in two (13.3%) limbs resulting in major amputation. One (6.7%) patient with wound shrinking in size is still under management.

Conclusion: Our early experience showed reasonable wound healing rate can be achieved using combined MDT and NPWT for CLI patient with advanced tissue loss after successful revascularization.

Mean Platelet Volume as A Predictor of Peripheral Arterial Disease (Pad): A Systematic Review and Meta-analysis

Chumpon Wilasrusmee^{1,3}, Boonying Siribumrungwong^{2,3}, Suthas Horsirimanont¹, Napaphat Poprom¹, Chakrapan Jirasiritham¹, Jarim Wongserepipatana¹, Ammarin Thakkinstian³

¹Department of Surgery, Faculty of Medicine, Ramathibodi Hospital, Mahidol University, Bangkok, Thailand

²Department of Surgery, Faculty of Medicine, Thammasat University Hospital, Thammasat University, Pathumthani, Thailand

³Section for Clinical Epidemiology and Biostatistics, Faculty of Medicine, Ramathibodi Hospital, Mahidol University, Bangkok, Thailand

Background: Platelets play a major role in the pathogenesis of atherosclerosis and PAD. Increased mean platelet volume (MPV) is an early marker of platelet activation, which is widely available in clinical practice. In this study, we sought to determine the association between MPV and PAD.

Methods: A literature search of the MEDLINE and Scopus was performed to identify the association between MPV and PAD. Two reviewers independently extracted data. Differences in MPV were expressed as unstandardized mean difference.

Results: Among 272 articles identified, 5 studies (3 cohorts, 1 case control, and 1 cross sectional study) comprising 6,852 patients were eligible for pooling. MPV was higher in those with PAD than those without PAD, however no statistical significant was found (mean difference 1.307 fL, 95% confidence interval (CI) -0.219 to 2.833, P <0.093).

Conclusions: The available evidence suggests that elevated MPV may associated with PAD. An updated meta-analysis and further elucidated mechanistic study are required in order to use in practice or guide therapy.

Midterm Outcome of Femoral Artery Stenting for Chronic Atherosclerotic Occlusions

Hyun Jun Ahn¹, Keun-Myoung Park¹, Yong Sun Jeon², Soon Gu Cho², Tae Hyun Kong¹, Pil Ho Han¹, Jang Yong Kim³, Kee Chun Hong¹

¹Department of Surgery, Inha University Hospital, Incheon, Republic of Korea

²Department of Radiology, Inha University Hospital, Incheon, Republic of Korea

³Department of Surgery, College of Medicine, The Catholic University of Korea, Seoul, Republic of Korea

Purposes: The purpose of this study is to evaluate early and midterm results of superficial femoral artery stenting with self-expanding

nitinol stents for chronic atherosclerotic occlusions and to identify factors affecting to continuing success.

Methods: Stenting on the superficial femoral artery (SFA) were performed in 165 limbs of 117 patients at Inha University Hospital, Incheon, Korea, from Jan 2009 to Dec 2013. Patients were followed up for first occurrence of in-stent restenosis, defined as a reduction of lumen diameter over 50%, by color-coded duplex sonographic and/or angiographic confirmation.

Results: During the follow-up (mean: 15.3 ± 3.2 months), no early thrombotic occlusion occurred within 30 days, but 78 limbs developed an in-stent restenosis. Cumulative primary patency rate at 6, 12, and 18 months were 78, 66 and 42%, and secondary patency rate, 85, 72 and 58%, respectively. Diabetes mellitus was affecting factor to restenosis. (adjusted hazard ratio 3.2, $p = 0.01$).

Conclusions: Midterm restenosis after femoropopliteal stenting using self-expanding nitinol stents remains a major problem, particularly in patients with diabetes mellitus.

0232

Popliteal Artery Embolization in Superficial Femoral Artery Interventions: Incidence, Risk Factors, Treatment and Prognosis

Wei-wei Wu, Su-rong Hua, Chang-wei Liu, Yong-jun Li, Wei Ye, Bao Liu, Xiao-jun Song, Rong Zeng

Department of Vascular Surgery, Peking Union Medical College Hospital, Chinese Academy of Medical Science, Beijing, China

Purpose: Endovascular therapy has gained acceptance as a primary treatment modality for superficial femoral artery (SFA) diseases. Popliteal artery embolization (PAE) is a severe complication in SFA interventions. The purpose of this study was to evaluate the incidence, risk factors, treatment and prognosis of PAE in primary SFA percutaneous transluminal angioplasty and stenting (PTA+S). **Methods:** Chronic SFA arteriosclerosis cases that underwent primary PTA+S were reviewed from a prospectively maintained database. Runoff vessels were evaluated in all cases before and after interventions for detection of PAE. The primary patency, secondary patency and limb salvage rates were calculated using Kaplan-Meier analysis and compared using log-rank analysis.

Results: There were 436 lesions treated in 388 patients with 10 PAE events (2.3%) in total. PAE rate was significantly higher in Transatlantic Inter-Society Consensus (TASC) C/D group compared with TASC A/B group (OR = 8.91, $P = 0.002$), in chronic total occlusion (CTO) lesions compared with stenotic lesions ($P < 0.0001$), and in group with history of cerebral ischemic stroke (OR = 6.11, $P = 0.007$). PAE rates were not significantly affected by age, sex, smoking, hypertension, diabetes, hyperlipidemia and runoff status. The 12-month and 24-month primary patency, secondary patency and limb salvage rates in PAE group showed no significant differences comparing with non-PAE group.

Conclusions: PAE is a rare event in primary SFA PTA+S. TASC C/D lesion, CTO and cerebral ischemic stroke history are risk factors for PAE. PAE can be treated by comprehensive techniques.

If the popliteal flow is restored in time, PAE has no significant effect on long-term patency and limb salvage rates.

0235

Factors Related to the Quality of Pedal Arch in Patients with Critical Limb Ischemia Suffering from Ischemic Ulcer

Hui Xie, Meng Ye, Jia-quan Chen, Lei LV, Kai Yuan, Ji-Wei Zhang, Lan Zhang

Department of Vascular Surgery, Renji Hospital, Shanghai Jiao Tong University School of Medicine, Shanghai, China

Objective: To explore the factors related to the quality of pedal arch in patients with critical limb ischemia suffering from ischemic ulcer.

Method: The clinical data of 152 patients with critical limb ischemia suffering from ischemic ulcer were retrospectively analyzed. According to the pedal arch quality by angiography patients were divided into two groups: good pedal arch group ($n = 37$), poor pedal arch group ($n = 115$). Clinic data including age, gender, smoking, hypertension, fasting blood glucose (FBG), diabetes duration, body weight, blood lipid, creatinine, mean platelet volume (MPV), platelet distribution width (PWD), platelet count were documented. Multivariate logistic regression model was performed to detect the possible factors related to the quality of pedal arch.

Results: (1) FBG and MPV was significantly higher in poor pedal arch group than in good pedal arch group ($P = 0.008$, $P = 0.005$), in poor pedal arch group the number of patients with diabetes duration ≥ 10 years was significantly higher than that in good pedal arch group ($P < 0.001$). (2) After adjusting for age, gender, smoking, hypertension and dyslipidemia, FBG (OR = 3.194, $P < 0.05$), MPV (OR = 7.195, $P < 0.05$), diabetes duration ≥ 10 years (OR = 20.247, $P < 0.05$) remained as independent risk factors for impaired pedal arch. (3) The ROC curve showed the optimal cut-off point for FBG and MPV to predict poor pedal arch was 6.6 mmol/L and 11.7 fl, the area under the ROC curve was 0.805 ($P < 0.05$) and 0.907 ($P < 0.05$). (4) According to the critical point of FBG, MPV and diabetes duration ≥ 10 years the data was divided into two groups and taken into the logistic regression model as the mode of classification variables, after adjusting factors of age, gender, history of smoking, hypertension, blood lipid level, the risk of poor pedal arch in group of FBG ≥ 6.6 mmol/L, MPV ≥ 11.7 fl and diabetes duration ≥ 10 years was 8.684 (95% CI = 3.496~21.571, $P < 0.05$), 12.737 (95% CI = 5.358~30.232, $P < 0.05$), and 7.75 (95% CI = 2.996~20.048, $P < 0.05$) times higher than FBG < 5.8 mmol/L, MPV < 11.7 fl, and diabetes duration ≥ 10 years.

Conclusion: Higher level of FBG, diabetes duration ≥ 10 years and MPV are independent predictors of poor pedal arch in patients with critical limb ischemia suffering from ischemic ulcer.

Primary Stenting for Symptomatic Patients with Superficial Femoral Atherosclerotic Lesions: A Multicenter Trial in the Mainland of China

Danming Wu, Yubin Zhou, Haitao Tang

Department of Vascular Surgery, the People's Hospital of Liaoning Province, Shenyang, China

The investigators of the other 12 research centers²

² Zhongshan Hospital of Fudan University, Chinese PLA General Hospital, Beijing Anzhen Hospital, Capital Medical University, the First Affiliated Hospital of Sun Yat-sen University, First Affiliated Hospital of Chongqing Medical University, Changhai Hospital, First Affiliated Hospital, the First Affiliated Hospital of Zhejiang University, the First Affiliated Hospital of Fujian Medical University, the First Affiliated Hospital of Harbin Medical University, the Second Affiliated Hospital of Harbin Medical University, Renji Hospital, Shanghai Jiaotong University, the 9th Hospital, Shanghai Jiaotong University.

Purpose: The aim of this multicenter trial is to assess the clinical efficacy of primary stenting for symptomatic patients with superficial femoral atherosclerotic lesions in the Mainland of China.

Materials and Methods: All symptomatic patients enrolled in this prospective, multicenter study underwent primary stenting for de novo superficial femoral atherosclerotic lesions. They were followed up at 1, 3, 6, and 12 months with clinical, duplex, or CTA assessments. Baseline and Results A total of 508 patients (351 males), mean age of 72 years (range, 43–94 years) were included. The 1,3,6-month primary patency rates were: 84.6% (423 patients were followed up), 73.7% (377 patients were followed up) and 60.9% (304 patients were followed up).

Conclusion: It is the first multicenter trial to assess the clinical efficacy of primary stenting for symptomatic patients with superficial femoral atherosclerotic lesions in the Mainland of China. It shows that the clinical efficacy of primary stenting for symptomatic patients with superficial femoral atherosclerotic lesions in the Mainland of China is disappoint and unpromising. The other new technologies, such as drug-eluting stents, drug-eluting balloons, need to be examined in the future.

0251

Imaging Diagnosis and Surgical Treatment of Popliteal Artery Entrapment Syndrome

Maohua Wang, Xing Jin, Xuejun Wu, Jingyong Zhang

Department of Vascular Surgery, Shandong Provincial Hospital Affiliated to Shandong University, Jinan, China

Objective: To summarize the experience of imaging diagnosis and surgical treatment for popliteal artery entrapment syndrome (PAES).

Methods: From year 2004 to 2010, 11 patients with PAES underwent CTA or MR (A). 13 limbs were diagnosed to be PAES, 12 limbs underwent surgery, the Ankle/Brachial Index (ABI) of 12 limbs was measured before the operation, the mean ABI was 0.47 ± 0.27 .

Results: There were 11 patients with a mean age of (28 ± 190) years, eight patients were male, three patients were female. Two patients were found to have bilateral involvement. Intermittent claudication was the most frequent presenting symptom. Six limbs were type I, three limbs were type II, three limbs were type III, one limb was type V. One limb of a bilateral patient was rejected to underwent surgery. Popliteal artery exploration surgery or popliteal artery release surgery was performed in all 12 limbs, and this procedure was combined with a great saphenous vein bypass graft in seven limb because of arterial occlusion or aneurysm. After a median follow-up of (19 ± 20) months (0 month to 6 years), the mean ABI was 0.81 ± 0.30 after operation, the ABI was significant higher than preoperation ($P < 0.05$), one patient died of pulmonary embolism one day after operation, one patient (one limb) had popliteal artery thrombosis after operation, all other patients were cured of their intermittent claudication symptoms.

Conclusions: Exactly early imaging diagnosis and timely surgical intervention is very important for PAES.

Carotid Disease

Session Code: FP9D
1030-1200, 7 September
Function Room 2, 2/F

0085

Carotid Endarterectomy versus Carotid Artery Stenting for Patients with Carotid Restenosis after Carotid Endarterectomy: Systematic Review and Meta-analysis

Siwen Wang, Jian Tu, Zijun Huo, Ridong Wu, Chen Yao, Jingsong Wang, Henghui Yin, Guangqi Chang, Shenming Wang

Department of Vascular and Thyroid Surgery, the First Affiliated Hospital of Sun Yat-sen University, Guangzhou, China

Background: Carotid restenosis (CRS) after carotid endarterectomy (CEA) is an issue that can't be ignored nowadays. This study was to compare outcomes of redo CEA and CAS for CRS after CEA.

Methods: We performed a systematic analysis with searching terms CEA restenosis or carotid restenosis or CEA recurrent stenosis on MEDLINE, EMBASE, PubMed and Cochrane Library. 50 articles (9 comparing studies and 41 non-comparative studies), involving 4399 patients, were included.

Results: Pooled analysis showed no significant differences in the 30-day perioperative mortality, stroke and transient ischemic attack (TIA) rate in comparing studies ($P > 0.05$ respectively) and non-comparative studies ($P > 0.05$ respectively). Patients undergoing

redo CEA suffered more cranial nerve injury (CNI) than those undergoing CAS ($p = 0.02$ in comparing studies and $p < 0.01$ in non-comparative studies), but most of them were reversible. The late outcomes demonstrated the disease related mortality and stroke rate were lower after CAS ($p < 0.01$ and $p = 0.04$ respectively) in non-comparative studies. However, non-significant difference was noted in freedom from stroke at 36 months in comparing studies ($p = 0.47$) and freedom from stroke at 12 months in non-comparative studies ($p = 0.89$). The risk of restenosis was higher in CAS patients compared with redo CEA patients ($p = 0.02$ in comparing studies and $P < 0.01$ in non-comparative studies).

Conclusion: Both redo CEA and CAS were safe and feasible for CRS after CEA. Although the incidence of CNI was higher in redo CEA group, most of CNI were reversible. Patients treated with CAS were easier to develop restenosis than those treated with redo CEA during long term follow up.

0204

Results of Carotid Endarterectomy (CEA): CEA Only Group vs. Combined CEA and Coronary Artery Bypass Grafting (CABG) Group

Youn-Jung Kim, Shin-Young Woo, Yang-Jin Park,
Dong-Ik Kim, Young-Wook Kim

Division of Vascular Surgery, Department of Surgery, Samsung
Medical Center, Sungkyunkwan University School of Medicine,
Seoul, Republic of Korea

Background: According to the updated SVS guidelines in 2011 for management of extracranial-carotid-disease, patients with symptomatic carotid stenosis will benefit from carotid endarterectomy (CEA) prior to or concomitant with coronary artery bypass graft (CABG). The timing of the intervention depends on clinical presentation and institutional experience. Patients with severe bilateral-asymptomatic-carotid-stenosis, critical stenosis and contralateral occlusion should be considered for CEA prior to or concomitant with CABG.

Purpose: To compare our results of CEAs between CEA only group and combined CEA and CABG group.

Method: During the past 10 years, 662 CEAs were performed in a single institution. Among them, 382(58%) CEAs underwent patch angioplasty using processed bovine pericardial patch (Vascu-Guard; Synnovis-Surgical-Innovations, St. Paul, MN). To avoid bias arising from CEA procedure, 381 CEAs with patch angioplasty were included for this study excluding primary closure ($n = 280$, 42%) and patient underwent other concomitant aortic procedure ($n = 1$, CEA-with-CABG-and-aortic-arch-replacement). Among enrolled patients, 348(91%) was CEA only group and 33(9%) patients were combined CEA and CABG group. All CEAs were performed under the general anesthesia routinely using carotid shunt (Pruitt-Inahara®-Carotid-Shunts, LeMaitre®-Vascular, Burlington, MA) and 91% of CABG were performed as off the pump procedure. After comparison of preoperative neurologic and

cardiac status, we compared early postoperative neurologic complications between 2 groups.

Results: There was no significant difference between CEA only group and combined CEA and CABG group in mean age (69-years vs 69-years) and gender (male-87% vs female-82%). In pre-operative neurologic symptom, symptomatic carotid disease was more common in combined CEA and CABG group (60% vs 85%, $p = 0.005$). Although mean dosage of intravenous heparin was significantly higher in combined surgery group (4,000-units vs 14,000-units, $p < 0.001$), there was no significant difference in early postoperative neurologic complication rate (7/348, 2% vs. 2/33, 6%, $p = 0.179$) and bleeding complications (1.1% vs 0%, $p = 1.000$). Major stroke developed in 2 patient (0.6%) in CEA only group but there was no operative mortality in both groups.

Conclusion: Combined CEA and CABG is an acceptable treatment strategy in selected patient group having concomitant symptomatic carotid stenosis and CAD.

0234

Clinical Experience of Carotid Endarterectomy Combined Coronary Artery Bypass Grafting on Patients with Carotid and Coronary Artery Severe Stenosis

Peng Liu, Zhi-dong Ye, Xue-qiang Fan

Department of Cardiovascular, Chian-Japan Friendship Hospital,
Beijing, China

Objective: To evaluate clinical safety and efficiency of simultaneous carotid endarterectomy (CEA) and coronary artery bypass grafting (CABG) on patients with combined carotid and coronary artery stenosis.

Methods: From January 2000 to October 2013, 34 patients [21 males, 13 females, aged (70 ± 6) years in average] underwent combined CEA and CABG in our department. Preoperative coronary and carotid artery angiography revealed that left main trunk stenosis occurred in 6 cases, triple-vessel disease in 17 cases, double-vessel disease in 11 cases. 33 patients were given unilateral CEA firstly and then CABG. Only 1 case was given CABG firstly and then unilateral CEA. 26 cases received Off-Pump CABG and 8 cases underwent CABG with CPB support. An intraluminal carotid shunt and patch repair were used in all CEA procedure.

Results: There were no operative mortality and perioperative cardio-cerebral vascular accidents in our study. 1 case received right femo-popliteal artificial graft bypass for lower extremity atherosclerotic occlusive disease 1 month after the simultaneous CEA and CABG. No cardiovascular events were observed during the 6 to 84-month follow-up.

Conclusions: Simultaneous CEA and CABG is effective and safety for patients combined carotid and coronary artery severe stenosis. It can effectively prevent postoperative cardio-cerebral vascular complications with satisfactory mid-term result.

Treatment of Severe Cerebral Ischemia in Takayasu's Disease with Arterial reconstruction

Yongquan Gu, Jian Zhang, Zhonggao Wang

Department of Vascular Surgery, of Xuanwu Hospital & Vascular Surgery Institute, Capital Medical University, Beijing, China

Objective: To evaluate the effect of surgical bypass and to explore the role of Transcranial Doppler (TCD) during the bypass operation.

Methods: From January 2003 to June 2013, Forty-one patients, eight males and thirty-three females, with a male to female ratio of 1:4.1, with cerebral ischaemia caused by cervical arterial lesions due to TA were treated at our institute. The average age was 30.5 years, and the mean course of the illness was 8.5 years. Group A (22 cases) received TCD monitoring during the bypass operation, and group B (19 cases) didn't. Examination including angiography and color Doppler sonography confirm that patients with all the four cervical artery (bilateral carotid and vertebral artery) suffered from TA in group A and B are 12 cases and 10 cases; patients with three suffered arteries are 6 cases and 4 cases; and patients with two suffered arteries are 4 case and 5 cases respectively. Major surgical procedure: Ascending aorta - bilateral axillary (brachial) / subclavian artery artificial graft bypass - unilateral internal carotid artery autologous great saphenous vein bypass were performed on 10 and 8 patients in group A and B respectively; Ascending aorta (aortic arch) - bilateral axillary (brachial) / subclavian artery artificial graft bypass were performed on 7 and 9 patients respectively. On the basis of beforehand ascending aorta - bilateral axillary artery artificial graft bypass, graft - unilateral internal carotid artery autologous great saphenous vein bypass were performed on both 5 patients in group A and B respectively.

Result: The success rate of surgery is 100 percent, while the Mortality rate is 0 percent. All the vascular grafts were patent at discharge. Symptoms of cerebral ischemia reduced in all the 41 cases. The surgical efficiency is 100% in both groups with no significant difference ($P>0.05$). The main surgery complications in group A and B include tongue skew (5 cases V.S. 4 cases, $P>0.05$), dizziness (2 cases V.S. 9 cases, $P<0.05$), headache and eye swelling (2 cases V.S. 7 cases, $P>0.05$), cerebral hemorrhage (0 case V.S. 2 cases, $P>0.05$). All the 41 patients were successfully followed up, with a mean of 4.5 years. Symptoms recurred in 2 and 1 cases respectively in each group, with no significant difference ($P>0.05$).

Conclusion: Arterial reconstruction is safe and effective to treat cerebral ischemia in Takayasu's disease. Intraoperation TCD monitoring can significantly reduce postoperative complications caused by hyperperfusion.

Clinical Analysis of 60 Cases in Carotid Endarterectomy of Carotid Stenosis

Hong-bo Ci, Hao Ren, Guang-lei Tian, Jia Re Ke Tang, Feng Zhu, Bing Zhu, Sheng Guan, Xiao-hu Ge

Division of Vascular Surgery, the People's Hospital of Xinjiang Uigur Autonomous Region, Urumchi, China

Objective: To discuss the efficacy and safety of carotid endarterectomy (CEA) for carotid stenosis.

Methods: The data of 60 cases of carotid stenosis were treated by CEA at Division of Vascular Surgery, the people's Hospital of Xinjiang Uigur Autonomous Region were analyzed retrospectively.

Results: All procedures were successful. There was no one dead in this study. The postoperative complications included cerebral hemorrhage in one case, cerebral infarction in 2 cases, and mild tongue deviation in 2 cases.

Conclusion: CEA is a safe and effective procedure for patients with carotid stenosis. We found that the key of CEA including ensure inclusion criteria for carotid revascularization, improve the operation skills and reduce the possibilities of complications.

Lower Limb Arterial Occlusive Disease 2

Session Code: FP9E

1030-1200, 7 September

James Kung Meeting Room, 2/F

0134

Carbon Dioxide as the Primary Contrast Media in Endovascular Therapy for Preventing Renal Complications

Tapish Sahu, Vivek Anand, Vishnu M, Sumanth Raj, K.R. Suresh

JIVAS, Bangalore, India

Introduction: Contrast-induced nephropathy (CIN) is a significant source of iatrogenic morbidity and mortality with the ever-increasing use of iodinated contrast media (ICM) during Endovascular Therapy (EVT) and is known to be related to ICM volume used. We sometimes experience CIN regardless of renal function and ICM volume; thus, it is advisable to reduce the ICM volume as low as possible for all EVTs. The carbon dioxide (CO₂) is used as the alternative contrast medium and contributes to the reduction of ICM volume. Therefore, we evaluated the effects on renal function and reduction of ICM volume by using CO₂ contrast in treating complex lesions.

Material and Methods: From January 2013 to January 2014, EVT was performed in 50 consecutive patients with iliofemoral artery disease at our centre. We divided them into two groups of 25 patients each, group A (CO₂ group) comprised of patients undergoing EVT

with CO₂ as the primary contrast agent with only small amount of ICM. Group B(ICM group) comprised of patients undergoing EVT with only ICM as the contrast media. CO₂ was injected by using AngioSet device (Optimed Corp., GmbH), lesions were classified according to TASC II document and the effects on renal function and ICM volume between the two groups were recorded.

Results: The overall technical success rate was 100% in both groups without any major complications. CO₂ contrast group had significantly lesser worsening of estimated glomerular filtration rates (eGFR) pre and post procedure (Δ eGFR: ml/min/1.73 m²: -7 vs -25, $P = 0.035$). In addition, we could significantly reduce the ICM volume by using CO₂, especially for the treatment of TASC C&D lesions (ICM group: 99.38 ml \pm 50.89 vs CO₂ group: 45.25 ml \pm 30.59, $P = 0.033$).

Conclusion: In conclusion, this study shows that ICM in EVT can be significantly reduced by using CO₂ regardless of renal function, which will have minimal change in eGFR, especially to treat complex lesions. We suggest that CO₂ contrast can be used as the primary contrast agent in all EVTs.

0142

Early Results of Stem Cell Therapy in Peripheral Arterial Occlusive Disease

Dong-ik Kim

Samsung Medical Center, Sungkyunkwan University, Seoul, Republic of Korea

Background: Autologous whole bone marrow stem cell therapy in patients with peripheral arterial occlusive disease (PAOD) was accepted as a new health technology on 2013 in Korea. Here, we reported our early results of autologous whole bone marrow stem cell therapy in patients with PAOD.

Methods: From March to October 2013, 45 limbs of 30 patients with symptomatic arterial occlusion were treated. Under the spinal anesthesia, about 30–40 ml of autologous whole bone marrow stem cell were aspirated from iliac bone and divided into 30 number of 1 ml volume and injected into the area of vicinity of tibio-peroneal arteries by intramuscular injections. Recombinant human granulocyte-colony stimulating factor was injected intravenously from 4 days before stem cells injection.

Results: There were 25(83%) Buerger's patients and 3(10%) atherosclerotic occlusive patients. 19(63%) patients were current smoker. The numbers of injected total mononuclear cells were $1.65 \times 10^7 \pm 0.98 \times 10^7$, and CD34⁺ cells were $1.63 \times 10^5 \pm 1.47 \times 10^5$. The mean pain score was decreased from 5.75 ± 2.5 in pre-treatment to 3.3 ± 2.8 in 1 month and 1.85 ± 2.6 in 3 month post-treatment ($p < 0.001$). Scales for clinical status showed improvement of severity. There was no major side effect related with procedure.

Conclusions: Our results suggested that autologous whole bone marrow stem cell therapy might be used widely to the PAOD as an single or adjunctive treatment in the future.

0155

Autologous Bone Marrow Stem Cell Therapy in Peripheral Arterial Disease (ABMMSC)—Results from a Pilot Clinical Service in Singapore

Zhimin Lin², Siew Ping Chng¹, Jack Kian Ch'ng¹, Seck Guan Tan¹, Benjamin, Soo Yeng Chua¹

¹Singapore General Hospital, Singapore, Singapore

²National University of Singapore, Yong Loo Lin School of Medicine, Singapore, Singapore

Background: Critical limb ischemia (CLI) is a severe form of peripheral arterial disease (PAD) that is associated with limb loss in 30% of patients and mortality in 25% within a year. Up to 30% of such patients are unsuitable or are refractory to standard therapy such as angioplasty/surgical bypass. Autologous bone marrow mesenchymal stem cell (ABMMSC) therapy for PAD has been studied in recent years for refractory PVD patients with the aim of encouraging therapeutic angiogenesis through the differentiation and proliferation of progenitor cells obtained from adult bone marrow. We present our results from a pilot clinical service in Singapore.

Methods: This is a pilot prospective study of the efficacy of ABMMSC therapy for CLI. Patients are selected according to the inclusion criteria of PAD with severe critical ischaemia with Ankle Brachial Pressure Index (ABPI) < 0.5 , rest pain or tissue loss, including gangrene or a non-healing ulcer, who are poor candidates or high risk for peripheral angioplasty or surgical bypass. Patients who have failed surgical bypass or angioplasty are also included.

Outcomes studied include ABPI, Doppler flow, improvement of rest pain symptoms, pain-free walking distance, ulcer healing and limb salvage. Patients undergoing this procedure had a 1-staged procedure of bone marrow aspiration from the iliac crest, and then injecting the centrifuged stem cells intramuscularly into the affected limb. They were followed up fortnightly for these outcomes. We present the results from our initial cohort of patients.

Conclusion: Our results show that ABMMSC may be a new therapeutic option for patients with refractory PVD with CLI. More studies are needed to assess its long-term viability as first line treatment.

0156

Clinical Outcome of Asian Severe Limb Ischemia Patients with Chronic Total Occlusion of the Lower Limb Arterial System

Kyi Zin Thant¹, Goh Chin Hock, Jason², Ho Pei, Jackie^{3,4}

¹Department of Surgery, National University of Singapore, Singapore, Singapore

²Yong Loo Lin School of Medicine, National University of Singapore, Singapore, Singapore

³Department of Surgery, National University of Singapore, Singapore, Singapore

⁴Department of Cardiac, Thoracic and Vascular Surgery, National University Health System, Singapore, Singapore

Background: Peripheral arterial disease shows a growing incidence in Singapore. Those with chronic total occlusion (CTO) of their lower limb arterial system post a challenge to revascularization. In this study, we aim to review the characteristic and clinical outcome of severe limb ischemia (SLI) patients with CTO lesions after endovascular intervention.

Methods and Materials: Demographics and clinical parameters of the SLI patients with CTO lesions underwent endovascular revascularization between January 2010 and December 2013 were collected and analyzed. The clinical outcomes of the patients were recorded. Comparison of the Kaplan-Meier limb salvage rate, overall survival and amputation free survival, was performed between the successful and unsuccessful CTO revascularization patients.

Results: In total, 116 severe ischemia limbs of 100 patients with CTO lesions were treated during the study period. The mean age of patients was 66 ± 11 (40–90) years. 63.8% of the studied patients were Chinese, 18.1% were Malay and 13.8% were Indian. 84.5% of the patients were diabetic. 11.2% of patients had impaired renal failure, and 30.2% suffered end stage renal failure. 77.6% of the SLI patients had tissue loss at presentation. Successful CTO lesion revascularization rate improved from 44.4% in 2010 to 90.47% in 2013. Overall CTO revascularization success rate was 74.1%. Throughout the study period, 21 major amputations were performed. SLI patients with successful CTO lesion revascularization had a significantly better Kaplan-Meier limb salvage rate, overall and amputation free survival (1 year 84.2%, 85.4%, 72.6% respectively) compared to those with unsuccessful CTO revascularization (1 year 67.8%, 71.5%, 51.2%).

Conclusion: Asian SLI patients with CTO lesions are medically ill. Successful CTO lesion revascularization is associated with better limb salvage, overall and amputation free survival.

0159

Reduced Amputation Rate with Isovolemic Hemodilution in Critical Limb Ischemia Patients

Doosang Kim¹, Daniel Cho², Young I. Cho³

¹Veterans Health Service Medical Center, Seoul, Republic of Korea

²Rheovector LLC, Pennsauken, NJ, USA

³Drexel University, Philadelphia, PA, USA

Objectives: Critical limb ischemia (CLI) patients are characterized by intractable pain in spite of medication, non-healing ulcers, and gangrene. The objective of this study was to investigate whether or not isovolemic hemodilution treatment can reduce the rate of major amputations in CLI.

Methods: 28 patients were studied who had tissue loss on Rutherford Grade III, Category 5 or 6. The subjects were divided into two arms: standard of care or conventional therapy (CT) (n = 15) as a

control group and hemodilution therapy (HT) (n = 13) as a study group. For the HT group, weekly isovolemic hemodilution was performed over 4 consecutive weeks, removing 250 ml of whole blood with the infusion of hydroxyl-ethyl starch solution. Blood viscosity, hematocrit, hemoglobin, ankle-brachial index, VA pain scale, time-to-amputation from admission, and survival time were measured.

Results: The mean Hct gradually decreased over 4 weeks from 36.3 to 33.0, whereas the WBV at a shear rate of 1 s^{-1} significantly decreased from 25.2 to 14.1 during the same period. Subsequently, tissue oxygen delivery index, defined as the ratio of Hct to WBV at a shear rate of 1 s^{-1} , increased from 15.7 to 23.4 by 48.7%, improving the oxygen delivery to the tissue in the patients. The average rate of lower limb major amputation in control group was 93% (14/15), whereas that in study group was 31% (4/13) ($p = .001$). Amputation-free median survival time and amputation-free 5-year survival rate in control group were 1.2 months and 7%, while that in study group were 30.2 months and 44% ($p = .001$). There are no adverse effects from repetitive hemodilution in study group.

Conclusions: Isovolemic hemodilution treatment of CLI patients was found to be well-tolerated and reduced the rate of major amputation resulting from deterioration of CLI.

0191

Retrograde Tibial Surgical Approach Assisting Antegrade Approach for Recanalization of Peripheral Artery Complex Chronic Total Occlusions (CTOs)

Gangzhu Liang, Fuxian Zhang, Hui Zhao, Xiaoyun Luo, Changming Zhang, Lu Hu, Yaping Feng, Luyuan Niu, Huan Zhang, Long Cheng

Beijing Shijitan Hospital, Capital Medical University, Peking, China

Background and Objectives: We aimed to describe the technical aspects and clinical outcomes of the retrograde tibial surgical approach assisting antegrade approach for recanalization of peripheral artery complex chronic total occlusions (CTOs).

Methods: Between May 2011 and June 2013, antegrade revascularization failed in 12 limbs with complex total occlusions. For each of these antegrade failure cases in 12 patients (9 males, 3 females), a retrograde tibial surgery approach had been adopted to recanalize the CTOs. The mean age of the patients was 71.3 years (range, 50–83 years). There were 3 patients with severe claudication (Rutherford Category 3) and 9 patients with critical limb ischemia (Rutherford Category 4–5).

Results: Access from the tibial artery was successfully obtained for 11 patients (91.7%). One patient failed to obtain the access because the dorsalis pedis artery was occluded and the guidewire was hard to enter the vessel. Of the 11 patients, retrograde access was performed from the anterior dorsalis pedis artery in 6 patients and posterior tibial artery in 5 patients. Two minor complications

were documented (perforation of little artery during procedure). All the patients were followed up. Two patients encountered restenosis and released by reintervention. One patient died of a heart attack 3 months after operation.

Conclusions: Retrograde tibial surgical approach assisting antegrade approach for recanalization of peripheral artery complex chronic total occlusions (CTOs) safely increases the success rates of percutaneous recanalization in the failed traditional approach and is a feasible endovascular option to avoid more X-ray exposure time and contrast medium loads compared to retrograde tibial puncture approach.

0212

Catheter-Directed Thrombolysis Assisted Angioplasty for Chronic Lower Limb Ischemia

Fuxian Zhang

Beijing Shijitan Hospital Affiliated to Capital Medical University, Beijing, China

Background: Thrombolysis is an appropriate treatment for acute arterial occlusion. There remains controversy as to whether thrombolysis before angioplasty helps to identify the underlying lesion and improve results for chronic ischemia of the lower extremity. We sought to investigate the feasibility of catheter-directed thrombolysis assisted angioplasty for chronic lower limb ischemia.

Methods: Between July 2008 and December 2009, the data of patients with chronic lower limb ischemia undergoing catheter-directed thrombolysis assisted angioplasty were retrospectively analyzed.

Results: Twenty consecutive patients (18 men with a mean age of 56.35 ± 8.5 years) underwent thrombolysis-assisted angioplasty for occlusion of a native artery (n 1/4 18) or bypass graft (n 1/4 2). The median duration of symptoms was 19 months (range: 3–48 months). Symptoms included disabling claudication in 12 patients, rest pain in 5 patients, and gangrene of the toes in 3 patients. Urokinase or recombinant tissue plasminogen activator as a thrombolytic agent was used before angioplasty. The mean length of occlusive lesions decreased significantly from 150 mm to 30 mm after thrombolysis ($P < 0.01$). Four patients had no change in their lesions. Improvement of Inter-Society Consensus for the Management of Peripheral Arterial Disease (TASC II) classification was achieved in 16 patients, with 14 TASC IIA lesions and 2 TASC IIB lesions after thrombolysis. Subsequent stenting was successfully performed in all patients. The anklebrachial index increased significantly from 0.33 to 0.63 ($P < 0.01$). No perioperative deaths occurred. Morbidity included access site bleeding in 1 patient and distal embolization in 2 patients without further intervention. The primary patency rate at 1 year was 95%, with a median follow-up time of 19 months.

Conclusions: Catheter-directed thrombolysis assisted angioplasty is a safe and effective treatment in some patients with chronic lower limb ischemia. It may reduce the magnitude of the lesion and simplify the expected intervention procedures.

0278

The Efficacy Analysis of Re-intervention Treatment for SFA In-stent Restenosis

Xue-qiang Fan, Zhi-dong Ye, Peng Liu, Jie Chen, Xia Zheng, Ya-nam Zhen, Bo Ma, Jiang-tao Liu, Yu-guang Yang, Song-yi Qian, Fei Wang, Fan Lin, Shi-yan Ren

Department of Cardiovascular, Chian-Japan Friendship Hospital, Beijing, China

Objective: To evaluate the efficacy and medium-term outcomes of reintervention in the treatment of in-stent restenosis on superficial-femoral arteries (SFA).

Methods: Clinical, angiographic, and procedural data were collected on 20 patients who suffer from SFA in-stent restenosis at a single center from December 2011 to January 2013. We present a retrospective analysis for symptoms improvement and restenosis after re-intervention treatment.

Results: Among all the patients, 14 were admitted because of intermittent claudication, 3 presented with acute lower limb ischemia, 3 suffer from rest pain. The preoperative average ABI was 0.43, claudication distance was (238.5 ± 76.8) m. 65% (13/20) of the patients coexisted with 2 diabetes, 70% (14/20) of them were categorized to TASC II grade C/D. We selected PTA (3 cases), PTAS (9 cases), Bypass (3 cases), SilverHawk (4 cases) as re-intervention therapy methods. At 6 months, a complete follow-up was obtained in 14 patients. Postoperative ABI was 0.69 ($P < 0.05$), claudication distance was (835.0 ± 217.8) m ($P < 0.01$), no amputation occurred when after six months follow-up. There were six cases (42.86% 6/20) occurred in-stent restenosis again.

Conclusions: Re-intervention can significantly improve the short and medium-term outcomes for patients with SFA in-stent restenosis, but there is still a high rate of restenosis after treatment.

Access

Session Code: FP10D
1330-1500, 7 September
Function Room 2, 2/F

0003

Brachial-jugular Prosthetic Vascular Access for Hemodialysis: Results from a Single-center Study

Sangchul Yun, Dan Song, Seok Han

Soonchunhyang University Seoul Hospital, Seoul, Republic of Korea

Background: Central vein stenoses are frequently found in patients who undergo a large number of central venous catheterization. In patients with central vein stenosis, creating vascular access in the ipsilateral arm vein could induce venous hypertension in the ipsilateral upper extremity, which causes arm swelling

and eventually leads to the closure of fistulas. In such patients, one could consider using ipsilateral internal jugular vein for arteriovenous fistula outflow vein. The authors present arteriovenous graft creation using the internal jugular vein in patients with subclavian vein stenosis.

Methods: From 2001 to 2011, 32 patients were analyzed retrospectively who had arteriovenous hemodialysis access created with brachial artery and ipsilateral internal jugular vein. All patients had ipsilateral subclavian or axillary vein stenosis. The preserved internal jugular vein and innominate vein were preoperatively confirmed with Doppler echocardiography and contrast venography.

Results: The mean age of the patients was 57.6 ± 12.3 years, and the mean follow-up period was 3.1 ± 2.3 years. All patients had the ipsilateral axillary vein or subclavian vein stenosis. The primary patency was 54%, 32%, 15% and 5% at 6 months, 1, 2, and 3 years, respectively. The secondary patency was 93%, 93%, 89%, 79%, 72% at 1, 2, 3, 4, 5 years, respectively. In the analysis of complications, 1 steal syndrome, 2 seroma, 1 hematoma, 3 arm swelling, 2 infection, 1 pseudoaneurysm, 1 puncture site bleeding, 8 stenosis, and 13 thrombosis cases were noted.

Conclusions: Brachial-jugular arteriovenous graft showed satisfactory results in terms of patency and complication. It could be a good outflow vein for arteriovenous fistula for chronic renal failure patients who have subclavian or axillary vein stenosis or occlusion, if the internal jugular vein is preserved.

0005

Incidence and Risk Factors of Asymptomatic Central Vein or Proximal Vein Stenosis in Acute Arteriovenous Graft and Fistula Thrombosis in Dialysis Patients

Kwanchai Lawanwong, Wiwat Tirapanich, Sapon Jirasiritham, Surasak Leela-Udomlipi, Piyanut Pootrakool, Suthas Horsirimanont, Panuwat Lertsithichai

Vascular and Transplantation Division, Department of Surgery, Ramathibodi Hospital, Faculty of Medicine, Mahidol University, Bangkok, Thailand

Background: Incidence and risk factor of proximal vein or central vein stenosis in Thailand has not been documented.

Objective: To evaluate incidence and risk factor of asymptomatic central vein or proximal vein stenosis in acute vascular access thrombosis in dialysis patients in Ramathibodi Hospital.

Methodology: Prospective cohort study between April 2013 to December 2013. Intraoperative venogram were performed in all patients who underwent AV graft or fistula revision to detected proximal vein or central vein stenosis. In this group additional treatment is balloon angioplasty. Demographics data, timing of access and dialysis, previous central catheter and rethrombosis rate after revision were analyzed.

Results: From 62 Pts., 1 Pts. was excluded due to contrast allergy, 18 patients have central or proximal vein stenosis (30%); 11 (61%) patients have proximal vein stenosis and 7 (39%) patients have central vein stenosis. Those patients were treated by balloon angioplasty; technical success rate 83% (15/18). Follow up period for a median time of 2.3 months (range 0.38 month to 11 months), rethrombosis rate 37.7% (23/61). Independent risk factors for rethrombosis consist of presence of central vein or proximal vein stenosis (hazard ratio 3.74), DM (hazard ratio 3.07).

Conclusion: The incidence of asymptomatic central vein or proximal vein stenosis in acute arteriovenous graft and fistula is high. In this study, there is no significant risk factor for development of central vein or proximal vein stenosis. After revision, early rethrombosis is associated with DM and central vein or proximal vein stenosis.

0057

Transposed Basilic Vein Arteriovenous Fistula in Access Challenging Patients

BDK Leong, AA Zainal, H Hanif, MT Hafizan, SK Lee, G Nares, P Kumaraguru, A Faidzal, M Ashraf, KL Tan

Kuala Lumpur Hospital, Kuala Lumpur, Malaysia

Background and Objectives: End-Stage Renal Disease (ESRD) is a significant health problem worldwide and its prevalence is on the rise. Native fistula creation for haemodialysis in patients who have exhausted all their superficial veins presents a challenge to vascular practice. We review our experience in transposed basilic vein fistula (BVT) creation and its usage for haemodialysis. To the best of our knowledge, this represents the largest series to be reported in the literature to date.

Methods: We analysed the hospital operative registry from January 2009 till June 2012 to identify the total number of BVT created in our centre. Medical record of each patient was traced and patients were interviewed using a standard proforma. In our centre, BVT is performed as a 2-stage procedure for patients with the presence of suitable arm basilic vein of at least 2.5 mm and with no other suitable superficial veins. All patients were routinely assessed with duplex scan pre- and post-operatively.

Results: 239 patients were recruited in the study. 50.6% of patients were male and 49.4%, female. Mean age was 53.1 years old. 81.2% of patients had history of other previous fistula creation. Risk factor profile includes diabetes mellitus in 59.8%, hypertension in 86.2% and smoking in 13.0%. Mean size of basilic vein was 7.3 mm with mean flow rate of 1034.1 ml/min before second stage transposition. 84.5% of patients had no operative complication. Commonest complication was wound infection, 6.3%, followed by haemorrhage or haematoma required surgical intervention, 5.9%, and pseudoaneurysm, 1.3%. Primary patency was at 86.1% at 1 year and 70.5% at 3 years.

Conclusions: BVT is a credible option for challenging patients with absence of superficial veins for native fistula creation with

good patency and low operative complication rate. Pre-operative ultrasound assessment improves patient selection and outcome of BVT.

0080

On Postoperative Day Balloon Angioplasty for Salvage of Newly-placed, Flow-limiting Native Arteriovenous Fistula

Jae Young Park, Chang Hyun Yoo

Busan Vascular Clinic, Busan, Republic of Korea

Background and Objectives: To report result and usefulness of immediate postoperative balloon angioplasty of de novo arteriovenous fistula (AVF) which shows no flow after creation.

Methods: From January 1, 2012 to March 31, 2014, 1,270 patients received de novo AVF creations in single vascular clinic. In twenty-four patients (1.9% of total AVF creation), immediate postoperative balloon angioplasty was performed because of flow-limiting on palpation (only pulsation or no thrill) just after AVF creation. Medical records were reviewed retrospectively; technical success (restoration of AVF flow)/clinical success (growing as functional AVF) rate, maturation time, primary patency rate and fistula survival outcome were analyzed during mean 10.8 months of follow-up period.

Results: Technical/clinical success rate was 100%; in all twenty-four patients, AVF flow was restored after balloon angioplasty, and all AVFs were growing as functional AVFs with mean 4.5 (\pm 1.5, standard deviation) weeks of maturation time. Seven (29.2%) patients needed another balloon angioplasty for maturation. The overall primary patency after immediate postoperative balloon angioplasty was 70.8% at 1 and 6 months and 59.0% at 12 months. Only one complication (4.2%, operation site hematoma) was occurred.

Conclusion: Immediate postoperative balloon angioplasty for salvage of newly-placed, flow-limiting native arteriovenous fistula is a useful, effective and safe procedure.

0108

Evaluation of the Effect of Papaverine on the Hemodialysis Fistula Maturation Outcomes

Gholamhossein Kazemzadeh, Reza Manani, Emad Ebrahimi

Vascular and Endovascular Surgery Research Center, Imam Reza Hospital, Mashhad University of Medical Sciences, Iran

Background: The prevalence of patients with end-stage renal disease requiring kidney replacement therapy is increased progressively. According to guidelines, preferred vascular access for hemodialysis is a native arteriovenous fistula. By using standard method of surgery it might take up to three month for fistula maturation. The

aim of this work was to assess the effect of papaverine on the hemodialysis fistula maturation outcomes.

Participants: 110 patients suffering from chronic renal failure, who had been admitted for creating an AVF, in Imam Reza Hospital, Mashhad, Iran.

Methods: The patients were randomly divided into two groups after having filled out consent forms. Groups had similar baseline characteristics. The control group went under standard method fistula surgery. In the interventional group, Papaverine was injected subadventitial of arterial during surgery. Both groups underwent post-operative Color Doppler Sonography of both upper limbs, 48 hours after surgery, evaluating flow and the diameter of arterial and the patients were followed for rate of maturation, complications, failure rate and rate of fistula blood flow on days 7, 14, 30, 60, 90.

Results: The interventional strategy showed a significant reduction in maturing time ($p = 0.004$) and increase in diameter of arterial ($p = 0.005$) and blood flow of AVF ($p = 0.001$). No complication were detected related to injection of papaverine.

Conclusion: This randomized study indicates the benefit of using local subadventitial injection of papaverine was accompanied by an increase in the proportion of AVFs that were suitable for dialysis.

0144

Correlation between Preoperative Peak-to-Peak Pulsatility Index of Brachial Artery and Maturation of Native Brachio-cephalic Fistula

Naresh Govindarajanathan, Mohd. Auri Jamaludin, Zainal Ariffin Azizi

Kuala Lumpur Hospital, Kuala Lumpur, Malaysia

Background: The compliance of the artery has been identified as one of the factors affecting maturity of the fistula, which is often overlooked in the preoperative work-up for fistula creation. The use of the pulsatility index (PI) which is derived from measurements during an ultrasound; has been shown to correlate with the compliance of the artery. Reactive hyperaemia from temporary ischaemia causes reduction in peripheral resistance, thus reducing the PI. This stimulates the changes seen in an artery after creation of a fistula. The change in the PI is then used to correlate with maturation of the BCF.

Methods: This is a cross-sectional study carried out over a period of 4 months from January 2012 until April 2012. The study population includes 60 consecutive patients undergoing brachio-cephalic fistula procedures in the Vascular Unit who fit the inclusion criteria. The measurement of the preoperative PI of the brachial artery is performed using a duplex ultrasound. Compression with a sphygmomanometer cuff for 3 minutes is used to induce the reactive hyperemia and the PI measurement is repeated post compression. The patient then underwent a brachio-cephalic fistula creation and the maturity is assessed.

Results: The maturity rate of BCF for this study population is 90%. The reduction in pulsatility index of brachial artery (PI) after

compression correlate well with maturity ($p < 0.001$). The mean percentage in reduction of PI that significantly correlate with maturity is 19.8% ($p < 0.001$). Among the patients who had BCFs which failed to mature, the PI increased by 10.1%.

Conclusion: Reduction in the pulsatility index of the brachial artery after induction of reactive hyperemia significantly correlates with maturation of BCFs. This is a relatively simple test which measures a parameter which is often overlooked. This method may be used to assist in case selection for BCF creation.

0198

Banding for Access Related Ischaemia: Our Experience in Kuantan, Malaysia

Mohd Norhisham Azmi Abdul Rahman,

Ahmad Faizal Othman

Vascular Unit, Department of Surgery, Kuliyah (Faculty) of Medicine, International Islamic University Malaysia, Kuantan, Pahang, Malaysia

Introduction and Objectives: Since it was first recognized in 1969 by Storey, access related ischaemia has been a significant problem. Reported incidence is between 2–20%. The treatment goals are to reverse the ischaemia and salvage the access. One of the recognized treatment strategies is banding of the fistula. We would like to present our result for the past year in employing this strategy in our local community in Kuantan, Malaysia.

Materials and Methods: All banding procedures identified from theatre lists and cross referenced with the theatre log book. (We performed our banding using PTFE graft, placed around the access and sutured in a tapered manner using a non-absorbable material). Resolution of symptoms and salvation of access reviewed using medical notes supplemented with a phone call to the patient. Statistical analysis performed using SPSS® v15.

Results: We performed 8 banding procedures in 8 patients, between June 2012 and April 2014. All presented with grade II–III steal syndrome. Complete symptoms resolution and salvage access occurred in all cases except in 1 patient.

Conclusion: In our experience, employing banding as a flow limiting procedure has been a success in dealing with access related ischaemia.

Miscellaneous

Session Code: FP10E

1330-1500, 7 September

James Kung Meeting Room, 2/F

0016

Effects of Vacuum Therapy-vacumed on Skin Microcirculation in Patients Suffering from Diabetic Foot Ulcer in Context of TcPO₂ & Wound Healing

Sandeep Raj Pandey

Norvic Int'l Hospital, Kathmandu, Nepal

Background: We investigated the short-term effect of impinging vacuum therapy by vacuumed (VC) P6 or P7 on skin microcirculatory perfusion in the foot of patients suffering diabetic foot ulcer in context of TcPO₂ & wound healing.

Patients and Methods: Nineteen patients with diabetic foot ulcer underwent vacuum therapy by vacuumed P6 or P7 for 40 minutes for several days (3 to 10 days). The leg was positioned in an air-tight plexiglass cylinder in which hypobaric (–110 mm Hg) and hyperbaric (70 mm Hg) pressure could be generated alternately, in order to improve peripheral circulation and suck infected & necrotic tissues. The effect on skin microcirculation was investigated using transcutaneous oxygen tension measurements (TcPO₂) and photos observing wound healing.

Results: Three of the patients experienced ischaemic symptoms during VC, probably because the leg was pinched off through inflation of the cuff. Patients capillary microscopic parameters changed slightly at first vacuum. After several vacuum, TcPO₂ parameters improved significantly (3 to 19 mm Hg) along with better wound healing.

Conclusion: Vacuum therapy significantly improves total skin perfusion and oxygenate on being an essential factor in the occurrence of ischaemic symptoms with context of TcPO₂ & wound healing. We therefore conclude that this instrument in its present form is an aid in the treatment of diabetic foot management.

0041

Overview of Upper Limb Ischemia

Mi-ju Bae, Sung Woon Chung

Pusan National University Hospital, Department of Thoracic and Cardiovascular Surgery, Busan, Republic of Korea

Background: In comparison to lower limb ischemia, upper limb ischemia is rare and only a few cases have been reported. This paper reviews the epidemiology, etiology and clinical characteristics of upper limb ischemia and analyzes factors affecting its mortality and functional sequelae after treatment.

Method: From January 2007 to December 2012, 35 patients with acute and chronic upper limb ischemia were reviewed retrospectively.

Result: Median age was 55.03 years. The number of male patients was 24 (68.6%). Median follow-up duration was 706.23 days (range 4–2458 days). The most common etiology was embolism with heart origin secondary to thrombosis followed by trauma, and the brachial artery was the most common lesion with obstruction. CT angiography was the first line diagnostic tool in our center. Twenty-eight operations and 7 conservative therapies were performed. There were 5 deaths (14.3%) during follow-up, among them there was 1 hospital death. Twenty patients (57.1%) complained functional sequelae after treatment. Functional sequelae and mortality was increased with longer symptomatic duration ($p < 0.001$, $p = 0.007$) and higher LDH level (each $p = 0.001$). Lower serum total cholesterol level was related with high mortality ($p = 0.01$).

Conclusion: The prognosis of upper limb ischemia is associated with prompt and proper treatment and could also be predicted by initial serum LDH and total cholesterol level.

0126

Clinical Study of Acute Limb Ischemia: Thrombectomy with Direct Thrombolysis Under the Mobile C-arm

Ji Ho Lee, Hyuk Jae Jung, Sang Su Lee

Pusan National University Yangsan Hospital, Yangsan, Gyeongnam, Republic of Korea

Purpose: Acute limb ischemia (ALI) is any sudden decrease in limb perfusion causing a potential threat to limb viability. Even with optimal surgical management, ALI resulting from thromboembolic disease continues to cause significant morbidity and mortality. The management of ALI still remains a major surgical challenge.

Method: 52 limbs in 46 patients surgically treated at the Pusan National University Yangsan Hospital from April 2011 to February 2014 were studied retrospectively. We analyzed amputation free survival rate and re-intervention rate as well as clinical characteristics of patients and treatment modalities. Intraoperative arteriography was used during arterial thrombectomy as a guide for extension of procedure to ensure complete clearance of the arterial tree and distal patency. Also, direct thrombolysis under the mobile C-arm was used after thrombectomy for resolution of residual thrombosis.

Result: The analyzed data includes 30 males and 16 females (1.8:1). The mean follow-up was 10.7 months (range: 0–34 months). The mean age was 74.9 years old (range: 40–87 years). The highest incidence occurred among people in 70s and 80s. The severity of ALI according to SVS/ISCVS classification were category IIa in 3 (5.8%), category IIb in 43 (82.7%) and category III in 6 (11.5%). For the treatment, 43 thrombectomies, 6 thrombectomies following surgical bypasses and 3 surgical bypasses only were performed. All cases treated with intraoperative direct thrombolytic therapy under

the mobile C-arm. There were 11 major amputations and 6 mortalities at 6 months. 6 months amputation free survival rate of all survival patients was 93.2% with re-intervention rate of 1.9%.

Conclusion: ALI treated with thrombectomy and direct thrombolysis under the mobile C-arm results in favorable limb salvage and survival rate. This data shows the benefits in amputation free survival and low re-intervention rate.

0127

Initial Experience of Rheolytic Thrombectomy with Solent Omni Peripheral Catheter

Jang Yong Kim, Kang-Woong Jun, Mi Hyoung Kim, Ji Il Kim, Sang Seob Yun, In Sung Moon, Sang Dong Kim, Sang Hyun Ahn, Sun Chul Park

The Catholic University of Korea, Seoul, Republic of Korea

Introduction: Acute thrombosis in arterial system and venous system requires emergent treatment. Mechanical thrombectomy of peripheral artery and vein became available in Korea and have advantage over thrombolysis. Authors Experienced successful serial 10 cases of AngioJet with Solent Omni catheter for peripheral vascular artery and vein.

Methods: This is a retrospective study of Seoul St. Mary's hospital in 2013. Procedures of AngioJet was following: Vascular access, Diagnostic angiogram, Wire was passed through occlusion site, Power Pulse Mode: 100cc N/S + UK 105 Unit, Maximum time for mechanical thrombectomy: 5 minutes, Adjunctive procedure for residual lesion, Completion angiogram.

Results: There were 4 acute limb ischemia (acute embolization from atrial fibrillation, acute ischemia from underlying chronic claudication, acute thrombosis of stent with in-stent restenosis, distal embolization from traumatic vascular injury), 5 acute DVT in lower legs, and 1 acute venous mesenteric ischemia. There was no mortality (0/10). Technical success rate was 90% (9/10). There were occlusion of venous stent (1), distal embolization (1) and hemoglobinuria (3) as a complications.

Conclusion: Mechanical thrombectomy with AngioJet and Solent Omni peripheral catheter showed 90% success rate. This can be used as an alternative option to traditional open thrombectomy or thrombolysis.

0136

Clinical Efficacy of Endovascular Therapy for Patients with Upper Limb Ischaemia

Tapish Sahu, Vivek Anand, Vishnu M, Sumanth Raj, K.R. Suresh

JIVAS, Bangalore, India

Introduction: Symptomatic occlusive disease of the upper extremities is much less common than the lower extremities, accounting for limb ischemia in approximately 5% of the patients. Few authors

have focused on the long-term durability of endovascular therapy for subclavian artery (SCA) lesions. This study attempts to document long-term durability of this kind of PTA during a 5-year period at a single-center.

Methods: We did a retrospective analysis of our prospectively maintained database. From July 2008 to June 2013, out of 144 patients who presented with upper limb ischemia, 20 patients (12 men; 8 women, mean age: 52 years) had an identifiable underlying lesion, rest of which were treated by embolectomy or required intra operative angiogram only. All patients presented with critical ischemia (left:right:11:9), 5 patients required thrombectomy, approached through open brachial approach while 6 patients had percutaneous transfemoral access, 9 had percutaneous brachial access. PTA alone was done in 6 patients, in 14 patients, stent was placed.

Results: Angioplasty was successful in all the patients, 3 patients (15%) had minor wound related problems all without permanent sequelae while 3 patients with percutaneous brachial approach had thrombosis of the brachial artery, which required no intervention, as the patients were asymptomatic. Follow-up ranged from 3 months to 5 years (mean, 34 months). Primary patency at 5 years was 89%, with a median recurrent obstruction-free period of 23 months. There was no major amputation in any patient, those treated by PTA alone had radiologically evident restenosis in 2 patients (33%) while in patients who had stents, the stenosis was evident in 2 (14%) patients however, none had symptoms.

Conclusion: PTA of the proximal SCA is not only an effective initial treatment, but is also successful over short-term and long-term. We could not prove positive or negative influence of placement of stents; however, the number of recurrent stenoses might be too small in this retrospective study to draw firm conclusions. Adverse events of any kind are not greater than with invasive surgical procedures thus making PTA far less morbid and must be considered in patients with localized obstruction of the proximal SCA.

0145

Factors Affecting Outcome in Popliteal Artery Injuries

Alduz Cabasa, Leoncio Kaw, Jr.

University of the Philippines, Philippine General Hospital, Manila, The Philippines

Background and Objectives: Injuries to the popliteal artery, albeit relatively uncommon, has been shown to be associated with poor outcome. Previous studies have cited prolonged ischemia time, blunt mechanism, concomitant venous injury and associated orthopedic procedures as factors associated with high amputation rates. This study aims to present a single institution experience of popliteal artery injuries.

Methodology: We performed a retrospective analysis on 22 patients who underwent surgery for popliteal artery injuries. Clinical characteristics and interventions done were analyzed for predictors of poor outcome.

Results: Twenty-two patients were included in the study. Majority of the subjects were males and gunshot wounds accounted for 40% of cases. Seven patients (31.8%) had associated venous injuries, 12 (54.5%) patients had associated fractures and eight patients (36.3%) had concomitant tibial nerve injuries.

Four patients (18%) underwent amputation. There were 3 deaths, all due to sepsis. Factors associated with amputations were blunt mechanism ($p = 0.009$), long segment arterial thrombosis ($p = 0.046$), and preoperative limb ischemia ($p = 0.046$). Delay in surgical revascularization, concomitant venous, nerve & orthopaedic injuries, need for ancillary fasciotomy and thrombectomy were not shown to be associated with poor outcome.

Conclusion: In patients with popliteal artery injuries, blunt trauma, presence of long segment arterial thrombosis and preoperative limb ischemia were associated with high amputation rates.

0169

Results of Elective and Emergency Surgical Repair of Popliteal Artery Aneurysms

Mari Sakai, Atushi Omura, Hitoshi Minami, Hirohisa Murakami, Hitoshi Matsuda, Masato Yoshida, Nobuhiko Mukohara

Hyogo Brain and Heart Center, Himeji/Hyogo, Japan

Background and Objective: Popliteal artery aneurysms (PAAs) are the most common peripheral arterial aneurysms. And there are rare and present with important clinical problems including rest pain, calf claudication, and tissue loss etc. It is difficult to study with a scientific approach, therefore there is no established operative indication.

Methods: From May 2002 to April 2014, 19 patients (22 limbs) underwent surgical repair of PAAs in our institute. We assessed the freedom from adverse events. Long term patency of graft were evaluated by Kaplan-Meier method.

Results: The mean age was 66.3 ± 8.1 years old, ranging from 54–82 years old. Male were 18 patients. The mean diameter of the aneurysms was 36.0 ± 15.5 mm. Most patients showed symptoms of acute arterial occlusion. 7 cases (31.8%) were treated with aneurysmectomy and graft interposition (in 1 case with prosthetic graft and 7 cases with autologous saphenous vein). In 15 cases (68.2%), proximal and distal ligation of the aneurysm with bypass grafting was performed. All grafts were autologous saphenous veins. 13 cases underwent above-below knee bypass and distal bypass was carried out for 2 cases. There were no perioperative deaths, 2 patients need revascularization because of bypass occlusion or anastomotic stenosis and 1 amputation occurred for the infection. Mean duration of follow-up was 50 ± 54 months. The freedom from adverse events in 5 years was $95.7 \pm 4.25\%$.

Conclusion: The results of surgical repair of popliteal artery aneurysms were acceptable. As soon as we diagnose, as peripheral arterial aneurysms. Surgical repair should be considered because even small aneurysms cause acute arterial occlusion.

Lower Extremity Arterial Injuries; How Functional Are the Salvaged Limbs?

Zia Ur Rehman, Ziad Sophie, Lekhraj Mal

The Aga Khan University Hospital, Karachi, Pakistan

Functional status is as important as to salvage a limb with major arterial injuries. A functionless limb is worse than artificial lower leg prosthesis. In the literature, most of the studies focused on the salvage rate of the injured limbs quite well but have ignored the post operated functional status of these patients. The purpose of this study is to measure limb salvage rate and functional of those patients who have undergone lower extremity arterial repair at The Aga Khan University Hospital, Karachi (Pakistan). Patient undergone revascularization for the lower extremity arterial injuries between 2008–2013 were included in this study and contacted by telephone to explore their functional status. Out of 110, fifty patients fulfilled the inclusion and exclusion criteria. Mean age of patients were 33.1 \pm 12.3 years. All patients were male. Most of the patients had penetrating injuries (76%). Twenty two (44%) patients had associated fracture. Sixteen (32%) patient had superficial femoral artery injury while 14 (28%) patients had popliteal artery injured. Out of patients who had successful repair, 3 (6%) patients had MESS score greater than 7. Limb salvage rate in our study was 96%. Two patients had secondary amputation. Lower extremity functional score which was recorded via telephonic communication was on average 72 (Good). The patients who had associated fracture, underwent fasciotomy and blunt trauma had relatively lower functional status postoperatively.

0241

Endovascular Therapy for Complication of Transplant Renal Artery

Zhaohui Hua, Zhen Li, Pengxu Ding, Zhiwei Wang, Wenguang Zhang, Peng Xu, Shirui Liu, Zhiwei Wu, Zhonggao Wang

Department of Endovascular, the First Affiliated Hospital of Zhengzhou University, Zhengzhou, China

Initial and Middle-term Outcome of Treatment for Isolated Dissection of Superior Mesenteric Artery

Zilun Li, Chen Yao, Henghui Yin, Jinsong Wang, Guangqi Chang, Shenming Wang

Division of Vascular Surgery, the First Affiliated Hospital, Sun Yat-sen University, Guangzhou, China

Objective: Symptomatic isolated dissection of the superior mesenteric artery (SIDSMA) represents an extremely rare condition. Although various treatments including conservative treatment (CT), endovascular stenting (ES), and surgical repair are currently available, consensus treatment guideline is absent due to scarce of SIDSMA cases. Thus, we present our experience in the treatment of SIDSMA at our single center.

Methods: Fourteen cases of SIDSMA was treated with CT, catheter directed thrombolysis (CDT), endovascular stenting (ES), or surgical repair in our center between January 2008 and December 2013. Demographics, clinical manifestations, coexisting medical conditions, imaging feature, treatments and follow-up of these patients were retrospectively collected and analyzed.

Results: For 13 patients without peritonitis, conservative treatment was given for 4–6 days initially. After the first observation cycle, symptoms and signs were alleviated in 8 patients, and conservative treatments were continued. The remaining 5 patients received technically and clinically successful ES (in 4) or CDT (in 1) due to worsening symptoms and signs during CT. One patient with peritonitis underwent emergent surgery, with the necrotic small intestine resected and reconstructed. However, the abdominal pain was not alleviated 17 days postoperatively, ES was thus performed and symptoms relieved immediately. Two weeks after ES, a new aneurysm and partial thrombosis in the distal part of the stent were found by CTA in this patient. No intestinal infarction or mortality developed during hospitalization. Follow-up was accomplished in 11 cases, ranging from 4–74 months (23.5 ± 21.3). Except that one complained with mild abdominal pain, the other 10 achieved complete remission. All patients were free from new aneurysmal formation of SMA and all stents remained patent.

Conclusions: For SIDSMA without peritonitis, CT can be provided with reasonable success rate, while ES may serve as an effective alternative once CT fails. For SIDSMA with peritonitis, open surgery remains the treatment of choice for resecting necrotic intestine and revascularization.

Diagnosis and Treatment of Arterial Injuries in Extremities (An Analysis of 106 Cases)

*Li-mu Sai, Hong-bo Ci, Guang-lei Tian, Hao Ren,
Li-Mujian A, Bing Zhu, Sheng Guan, Xiao-hu Ge*

Division of Vascular Surgery, The People's Hospital of Xinjiang Uigur
Autonomous Region, Urumchi, China

Objective: To evaluate our experiences with patients who had arterial injuries in extremities in this study.

Patients and Methods: A retrospective analysis was carried out in which 106 patients with arterial injuries in extremities from Jan 2004 to Oct 2013. The management was according to the type of arterial injuries in extremities.

Results: There was no one dead in this study, but 9 cases received amputation.

Conclusions: Results from vascular repairs are encouraging. Limb loss may be decreased by vascular repairs. The availability of experienced vascular surgical teams and effective emergency care are vital for decreasing the amputation rate and mortality due to arterial injuries in extremities.

Poster Presentation

(A) Abdominal Aorta Disease

Venue: Foyer Area, 1/F

- 0010 Endovascular Abdominal Aortic Repair Application in Patients With Complex Iliac Pathology
Fundu Yildirim, Alper Ozbakaloglu, Ozlem Karaaslanyuksel, Taner Kurdal, Mustafa Cerrahoglu, Ihsan Iskesen, Omer Tetik
Celal Bayar University, School of Medicine, Department of Cardiovascular Surgery, Manisa, Turkey
- 0015 Secondary Aortoenteric Fistula (AEF) —Review of a Case
Sandeep Raj Pandey
Norvic Int'l Hospital, Kathamndu, Nepal
- 0042 The Factors of Recurrence in Leriche's Syndrome
Sung Woon Chung, Mi-ju Bae, Min Su Kim
Pusan National University Hospital, Department of Thoracic and Cardiovascular Surgery, Busan, Republic of Korea
- 0045 The Effect of Adjunctive Iliac Stent during Endovascular Aneurysm Repair to Prevent Iliac Limb Occlusion
Jae Hoon Lee, Ki Hyuk Park
Daegu-Catholic Univ. Medical Center, Daegu, Republic of Korea
- 0047 Successful EVAR for an Abdominal Aortic Aneurysm with Horseshoe Kidney
Norimasa Koike¹, Toru Takahashi¹, Jun Mohara¹, Kei Shibuya², Takao Miki¹, Izumi Takeyoshi¹
¹*Department of Thoracic and Visceral Organ Surgery, Gunma University Graduate School of Medicine, Maebashi, Japan*
²*Department of Diagnostic Radiology and Nuclear Medicine, Gunma University Graduate School of Medicine, Maebashi, Japan*
- 0048 A Case of Delayed Graft Leg Proximal Migration after Endovascular Repair for the Aneurysms of Abdominal Aorta and Bilateral Common Iliac Arteries
Shinji Yamazoe, Yasuhito Sekimoto, Hirohisa Harada
Tokyo Dental College, Ichikawa General Hospital, Ichikawa City, Chiba, Japan
- 0056 Delayed Abdominal Closure Prevent Abdominal Compartment Syndrome for a Ruptured Abdominal Aortic Aneurysm—Report of a Case
Yutaka Hasegawa, Masahiko Ezure, Noritsugu Naito, Syuichi Okada, Chieri Kimura, Shuichi Okonogi, Hitomi Takihara, Tatsuo Kaneko
Division of Cardiovascular Surgery, Gunma Prefectural Cardiovascular Center, Maebashi, Japan
- 0060 Crossover Chimney Technique to Preserve the Internal Iliac Artery in Common Iliac Artery Aneurysms
Ho Kyun Lee¹, Oh Hyun Park¹, Jae Kyu Kim², Soo Jin Na Choi¹, Sang Young Chung¹
¹*Department of Surgery, Chonnam National University Medical School, Gwangju, Republic of Korea*
²*Department of Radiology, Chonnam National University Medical School, Gwangju, Republic of Korea*
- 0061 Endovascular Exclusion of Abdominal Aortic Aneurysm in Patients with Concomitant Abdominal Malignancy
Ho Kyun Lee¹, Oh Hyun Park¹, Jae Kyu Kim², Soo Jin Na Choi¹, Sang Young Chung¹
¹*Department of Surgery, Chonnam National University Medical School, Gwangju, Republic of Korea*
²*Department of Radiology, Chonnam National University Medical School, Gwangju, Republic of Korea*
- 0073 The Effect of Steroid Therapy on Postoperative Inflammatory Response after Endovascular Abdominal Aortic Aneurysm Repair
Kazuto Maruta, Atsushi Aoki, Tadashi Omoto, Hirofumi Iizuka, Hiroyuki Kawaura
Showa University School of Medicine Cardiovascular Surgery, Tokyo, Japan

- 0098 Successful Fenestrated EVAR to a Left Common Iliac Artery Aneurysm for a Living Kidney Transplantation Donor
Takao Miki¹, Norimasa Koike¹, Toru Takahashi¹, Jun Mohara¹, Kei Shibuya², Takashi Hachiya³, Izumi Takeyoshi¹
¹*Department of Thoracic and Visceral Organ Surgery, Gunma University Graduate School of Medicine, Maebashi City, Japan*
²*Department of Diagnostic Radiology and Nuclear Medicine, Gunma University Graduate School of Medicine, Maebashi City, Japan*
³*Department of Cardiovascular Surgery, Saitama Cardiovascular and Respiratory Center, Saitama City, Japan*
- 0099 The Experience of In Situ Antibiotic-soaked Graft Replacement with Omentral Wrapping in Patients with Asymptomatic Aortic Graft Enteric Erosion.
 Shin-Seok Yang, Moonsang Ahn
Chungnam National University Hospital, Daejeon, Republic of Korea
- 0104 Impact of Graft Composition on the Systemic Inflammatory Response after an Elective Repair of an Abdominal Aortic Aneurysm
Ju Yeon Lee¹, Jong Kwan Baek¹, Hyunwook Kwon¹, Gi-Young Ko¹, Youngjin Han¹, Young Soo Chung¹, Tae-Won Kwon¹, Yong-Pil Cho¹
¹*University of Ulsan College of Medicine and Asan Medical Center, Seoul, Republic of Korea*
²*Pusan National University School of Medicine and Medical Research Institute, Pusan, Republic of Korea*
³*Ulsan University Hospital, Ulsan, Republic of Korea*
- 0106 One Case that was Diagnosed with Aortic Aneurysm of IgG4-related Disease 17 Years after the Pancreaticoduodenectomy.
Hirokuni Ono, Syouta Kita, Hirotoshi Suzuki, Masahiro Sagane, Yuka Sakurai, Tokuchirou Nagata, Daijyun Ro, Kiyoshi Chiba, Makoto Ono, Yosuke Kitanaka, Masahide Chikada, Hiroshi Nishimaki, Takeshi Miyairi
St. Marianna University of Medicine, Kanagawa, Kawasaki, Japan
- 0107 An Idiopathic Congenital Abdominal Aortic Aneurysm with Impending Rupture in a 23-Month-Old Boy: Two Years Follow-up
Hyunwook Kwon, Yong-Pil Cho, Seong Chul Kim, Tae-Won Kwon
Asan Medical Center, Seoul, Republic of Korea
- 0110 Risk Factors on Acute Kidney Injury (AKI) after Endovascular Aortic Aneurysm Repair (EVAR)
Koki Tabata, Kimihiro Komori, Kiyohito Yamamoto, Hiroshi Narita, Hiroshi Banno, Akio Kodama, Masayuki Sugimoto
Nagoya University Graduate School of Medicine, Nagoya, Japan
- 0114 Retrospective Review of the Treatment Results of Middle Aortic Syndrome (MAS)
Seoung-Wook Choi, Young-Wook Kim, KI Sung, DI Kim, YS Do, DK Kim
Samsung Medical Center, Seoul, Republic of Korea
- 0118 Abdominal Aortic Aneurysm in Giant Cell Aortitis: Case Report
Hyunwook Kwon, Youngjin Han, Yong-Pil Cho, Tae-Won Kwon
Asan Medical Center, Seoul, Republic of Korea
- 0120 Midterm Outcome after Endovascular Abdominal Aortic Aneurysm Repair on Endurant® Stentgraft System
Kiyoshi Chiba¹, Hiroshi Nishimaki¹, Yukihiisa Ogawa², Hirotoshi Suzuki¹, Yuka Sakurai¹, Masanori Sagane¹, Ro Daijyun¹, Hirokuni Ono¹, Makoto Oono¹, Yousuke Kitanaka¹, Masahide Chikada¹, Hiroyuki Abe¹, Takeshi Miyairi¹
¹*Department of Cardiovascular Surgery St. Marianna University School of Medicine, Kawasaki, Kanagawa, Japan*
²*Department of Radiology St. Marianna University School of Medicine, Kawasaki, Kanagawa, Japan*
- 0122 One Year Experience of Iliac Bifurcated Device for Aortoiliac Aneurysm in Korean Single Center
Kee Chun Hong¹, Hyun Jun Ahn¹, Keun-Myoung Park¹, Yong Sun Jeon², Soon Gu Cho², Tae Hyun Kong¹, Jung Taek Kim³, Pil Ho Han¹
¹*Department of Surgery, Inha University Hospital, Incheon, Republic of Korea*
²*Department of Radiology, Inha University Hospital, Incheon, Republic of Korea*
³*Department of Cardiothoracic Surgery, Inha University Hospital, Incheon, Republic of Korea*

- 0132 Endovascular Relining of Pergraft Seroma after Open Surgical Repair of AAA
Jang Yong Kim, Kang-Woong Jun, Mi Hyoung Kim, Ji Il Kim, Sang Seob Yun, In Sung Moon,
 Sang Dong Kim, Sang Hyun Ahn, Sun Chul Park
The Catholic University of Korea, Seoul, Republic of Korea
- 0137 Successful Endovascular Repair in a Case of Infected Aortic Aneurysm
Won Yong Sung, Nam Woo Seok, Kim Mi Hyeong, Jun Kang Woong, Ahn Sang Hyun, Hwang Jeong Kye,
 Kim Sang Dong, Park Sun Cheol, Kim Jang Yong, Yun Sang Seob
Division of Vascular and Transplantation Surgery, Department of Surgery, The Catholic University of Korea School of Medicine, Seoul, Republic of Korea
- 0158 The Outcomes of Sac Dimensions after EVAR and its Predisposing Factors—A Single Center Retrospective Study
Min-Hyun Kim, Tae-Seung Lee, Hong-Kyoung Shin, Sae-Lee Kim, In-Hye Moon, Hyung-Sup Park
Seoul National University Bundang Hospital, Seong-Nam, Gyeonggi-Do, Republic of Korea
- 0162 Successful endovascular repair for retrograde type A aortic dissection and abdominal aortic aneurysm with proximal neck dissection
Kenji Aoki, Takeshi Okamoto, Hiroki Sato, Yosuke Horii, Osamu Namura, Kazuhiko Hanzawa, Masanori Tsuchida
Niigata University, Niigata, Japan
- 0181 Conservative Treatment of Spontaneous Abdominal Aortic Dissection
Byung Jun So, Dae Yong Kim, Jeong Byeong Kwon
Wonkwang University Hospital, Iksan, Jeonbuk, Republic of Korea
- 0210 Management of Type II Endoleak after Endovascular Repair of Arterio caval Fistula Complicating Aortoiliac Aneurysm: Case Report and Literature Review
Akhmadu Muradi^{1,2}, Masato Yamaguchi¹, Eisuke Ueshima¹, Takuya Okada¹, Koji Idoguchi¹, Yoshikatsu Nomura³,
 Yutaka Okita³, Koji Sugimoto¹
¹Center for Endovascular Therapy, Department of Radiology, Kobe University Hospital, Kobe, Japan
²Vascular and Endovascular Division, Department of Surgery, Ciptomangunkusumo Hospital, Faculty of Medicine University of Indonesia, Jakarta, Indonesia
³Cardiovascular Division, Department of Surgery, Kobe University, Hospital, Kobe, Japan

(B) Carotid Disease

- 0078 Endovascular Repair of Giant Iatrogenic Common Carotid Artery Pseudoaneurysm
Yuk Law, Yiu Che Chan, Stephen Wing Keung Cheng
Queen Mary Hospital, The University of Hong Kong, Hong Kong, Hong Kong
- 0095 Clinical Features and Outcomes of Carotid Endarterectomy after Carotid Artery Stenting
Ju Yeon Lee, Jae Hyun Kwon, Young Jin Han, Ji-Yun Choi, Yong-Pil Cho, Tae-Won Kwon
University of Ulsan College of Medicine and Asan Medical Center, Seoul, Republic of Korea
- 0163 Iatrogenic Giant Pseudoaneurysm of Right Common Carotid Artery in a Case with Multiple Co-morbidities
Ali Gurbuz, Orhan Gokalp, Ismail Yurekli, Ufuk Yetkin, Nagihan Karahan, Filiz Kiliccioglu
Izmir Katip Celebi University Ataturk Training and Research Hospital, Department of Cardiovascular Surgery, Izmir, Turkey
- 0168 Is Digital Subtraction Angiography of Carotid Artery a Gold Standard Examination Technique in Patients with Serious Left Main Coronary Artery Lesion?
 Ufuk Yetkin, Koksall Donmez, Ali Gurbuz
Department of Cardiovascular Surgery, Katip Celebi University Izmir Ataturk Training and Research Hospital, Izmir, Turkey

- 0224 Management of Hemodialysis Associated Left Innominate Vein Compression Syndrome
Ya-Xue Shi¹, Wei Liang¹, Hao Zhang¹, Yi-Ping Zhou¹, Meng Ye¹, Jie-Jun Cheng², Xiang-Jiang Guo¹, Ji-Wei Zhang¹
¹*Department of Vascular Surgery, Ren Ji Hospital, School of Medicine, Shanghai Jiao Tong University, Shanghai, China*
²*Department of Radiology, Ren Ji Hospital, School of Medicine, Shanghai Jiao Tong University, Shanghai, China*
- 0226 The Short and Mid-term Results of Self-expanding Nitinol Stents for Treatment of Popliteal Arteries Following Suboptimal Balloon Angioplasty
Wei Liang, Peng Wang
Dept. Vascular Surgery, Renji Hospital, School of Medicine, Shanghai Jiaotong University, Shanghai, China
- 0233 Crossover Chimney Technique to Preserve the Internal Iliac Artery in a Ruptured Aortic Dissection Aneurysm with Bilateral Iliac Entry Tears 10 years After TEVAR
Wei-wei Wu, Wei Ye, Su-rong Hua, Chang-wei Liu
Department of Vascular Surgery, Peking Union Medical College Hospital, Beijing, China
- 0239 Endovascular Treatment for Extrahepatic Portal Vein Bifurcation Stenosis after a Whipple Procedure Using the Kissing Stents Technique
Wen-Guang Zhang, Zhen Li, Zhong-Gao Wang
Department of Endovascular, the First Affiliated Hospital of Zhengzhou University, Zhengzhou, China
- 0240 Endovascular Treatment of an Unusual Primary Arterioportal Fistula Complicated by Cavernous Transformation of the Portal Vein Caused by Portal Thrombosis
Wen-Guang Zhang, Zhen Li, Zhong-Gao Wang
Department of Endovascular, the First Affiliated Hospital of Zhengzhou University, Zhengzhou, China
- 0249 Inhibition of Experimental Neointimal Hyperplasia by Novel Helical Stent in Procine Model
Jia-ning Yue, Jin-sheng Li, Wei-guo Fu, Yu-qi Wang
Department of Vascular Surgery, Zhongshan Hospital, Fudan University, Shanghai, China
- 0252 Percutaneous Transluminal Angioplasty for Atypical Thromboangiitis Obliterans in Arteries Above the Knee
Lianxi Yuan, Junmin Bao
Vascular Surgery Department, Shanghai Changhai Hospital, Shanghai, China
- 0253 Endovascular Therapy for Long-segment Atherosclerotic Aortoiliac Occlusion
Lianxi Yuan, Junmin Bao
Vascular Surgery Department, Shanghai Changhai Hospital, Shanghai, China
- 0256 Differential Expressions of microRNA between Young and Senescent Endothelial Cells
Henghui Yin, Junbin Zhang, Peng Chen, XiaoNan Zhu, JinSong Wang
Department of Vascular Surgery, The First Affiliated Hospital of Sun Yat-sen University, Guangzhou, China
- 0258 Drug Impact on In-stent Restenosis after Percutaneous Transluminal Angioplasty in Peripheral Arterial Disease
Dan Liu, Zhong Chen, Xiao-bin Tang
Beijing Anzhen Hospital Affiliated to Capital Medical University, Beijing, China
- 0259 EPCs Relieve Lower Extremity Ischemia by Paracrine Factors Through VEGF Pathway
Yaoguo Yang, Zhong Chen, lei Kou, Tengfei Zhang, Sheng Wang, Yanwen Qin
The Department of Vascular Surgery, Beijing Anzhen Hospital, Capital Medical University, Beijing, China
- 0263 Endovascular Treatment of Long Femoro-popliteal Arterial Occlusions Disease of Lower Extremities
Sheng Guan, Xiao-hu Ge, Qing-bo Fang, Hao Ren, Li-Mujian A
Department of Vascular Center, People's Hospital of Xinjiang Uigur Autonomous Region, Urumchi, China
- 0264 Noninvasive pressure monitoring systems in EVAR surgery
Jie Liu, Xin Jia, Wei Guo
Department of Vascular Surgery, Chinese PLA General Hospital, Beijing, China

- 0266 The Experience of Diagnosis and Treatment of Traumatic Popliteal Artery Injury
Hong-bo Ci, Hao Ren, Qing-bo Fang, Jia Re Ke Tang, Bing Zhu, Guang-lei Tian, Sheng Guan, Xiao-hu Ge
Division of Vascular Surgery, The People's Hospital of Xinjiang Uigur Autonomous Region, Urumchi, China
- 0269 In-hospital Efficacy of Endovascular Aortic Repair in Patients with Impending Rupture versus Contained Rupture of Abdominal Aortic Aneurysms
 Jiang Xiong, Wei Guo, Xiaoping Liu, Lijun Wang, Xin Jia, Xiaohui Ma, Hongpeng Zhang, Tao Zhang
Department of Vascular Surgery, Clinical Division of Surgery, Chinese PLA General Hospital and Postgraduate Medical School, Beijing, China
- 0272 Experience of surgical treatment in 58 patients with complicated carotid body tumor (CBT)
 Guojun Zeng, Jichu Zhao, Yukui Ma, Bin Huang, Ding Yuan, Yi Yang, Fei Xiong, Xiyang Chen, Tiehao Wang, Zhoupeng Wu, Yiren Liu, Hailong Luo, Han Luo
Division of Vascular Surgery, West China Hospital, Sichuan University, Sichuan, China
- 0274 Advancement of Researches on Correlation between Dyslipidemia and Aortic Aneurysm
 Ren Wei^{1,2}, Wei Guo¹
¹*Department of Vascular Surgery, General Hospital of People's Liberation Army, Beijing, China*
²*Medical College of Nankai University, Tianjin, China*
- 0279 A New Type of Endoleak after EVAR Induced by Stanford B Aortic Dissection and its Treatment
Jie Liu, Xin Jia, Wei Guo
Department of Vascular Surgery Chinese PLA General Hospital, Beijing, China
- 0280 The Efficacy of Intermittent Pneumatic Compression to Prevent Venous Thromboembolism: a Meta-analysis
Kalifu Baheti, Xiaohu Ge, Sheng Guan
Department of Vascular Surgery, People's Hospital of Xinjiang Uyghur Autonomous Region, Urumchi, China

(D) Miscellaneous

- 0030 Gunshot Wound of Thigh
 Baris Akca¹, Koksai Donmez², Didem Avci Donmez³, Ufuk Yetkin²
¹*Department of Cardiovascular Surgery, Kilis State Hospital, Kilis, Turkey*
²*Department of Cardiovascular Surgery, Katip Celebi University Izmir Atatürk Training and Research Hospital, Izmir, Turkey*
³*Department of Emergency, Izmir Tepecik Training and Research Hospital, Izmir, Turkey*
- 0038 Multiple Trauma Due to Bombing
 Baris Akca¹, Koksai Donmez², Didem Avci Donmez³, Ufuk Yetkin²
¹*Kilis State Hospital, Kilis, Turkey*
²*Katip Celebi University Izmir Atatürk Training and Research Hospital, Izmir, Turkey*
³*Izmir Tepecik Training and Research Hospital, Izmir, Turkey*
- 0051 Lower Extremity Gunshot Wound
 Baris Akca¹, Koksai Donmez², Didem Avci Donmez³, Ufuk Yetkin²
¹*Department of Cardiovascular Surgery, Kilis State Hospital, Kilis, Turkey*
²*Department of Cardiovascular Surgery, Katip Celebi University Izmir Atatürk Training and Research Hospital, Izmir, Turkey*
³*Department of Emergency, Izmir Tepecik Training and Research Hospital, Izmir, Turkey*
- 0059 Renal Vein Stent Insertion for Nutcracker Syndrome
Ho Kyun Lee¹, Oh Hyun Park¹, Sang Young Chung¹, Jae Kyu Kim², Soo Jin Na Choi¹
¹*Department of Surgery, Chonnam National University Medical School, Gwangju, Republic of Korea*
²*Department of Radiology, Chonnam National University Medical School, Gwangju, Republic of Korea*

- 0088 Rapid Growth of Infectious Iliac Artery Aneurysm Due to Infectious Embolus after an Operation for Infectious Endocarditis
Yasuhito Sekimoto, Hirohisa Harada
Tokyo Dental College Ichikawa General Hospital, Ichikawa, Chiba, Japan
- 0090 Popliteal Vein Repair with Posterior Approach in a Patient with Stab Wound
 Koksai Donmez, Kazim Ergunes, Ihsan Peker, Bortecin Eygi, Habib Cakir, Banu Lafci, Levent Yilik, Ali Gurbuz
Katip Celebi University Izmir Ataturk Training and Research Hospital, Department of Cardiovascular Surgery, Department of Cardiovascular Surgery, Izmir, Turkey
- 0100 Effects of Simultaneous Iliac Artery Angioplasty on Graft and Patient Survival after Living-donor Kidney Transplantation
 Duck Jong Han¹, Young Hoon Kim¹, Young Soo Chung², Youngjin Han¹, Heungman Jun³, Tae-Won Kwon¹, Yong-Pil Cho¹
¹*University of Ulsan College of Medicine and Asan Medical Center, Seoul, Republic of Korea*
²*Pusan National University Hospital, Pusan, Republic of Korea*
³*Korea University Anam Hospital, Seoul, Republic of Korea*
- 0101 Renal Vein Extension during Living-donor Kidney Transplantation in the Era of Laparoscopic Donor Nephrectomy
 Duck Jong Han¹, Youngjin Han¹, Young Hoon Kim¹, Ki Byung Song¹, Young Soo Chung², Tae-Won Kwon¹, Yong-Pil Cho¹
¹*University of Ulsan College of Medicine and Asan Medical Center, Seoul, Republic of Korea*
²*Pusan National University School of Medicine and Medical Research Institute, Pusan, Republic of Korea*
- 0113 Comparison of Characteristic between Splenic Artery Aneurysm & Other Splanchnic Artery Aneurysm
Youn-jung Kim, Young-wook Kim, Young-Soo Do, Dong-Ik Kim, Yang-Jin Park, Kwang-Bo Park, Hong-Seok Park
Samsung Medical Center, 81 Irwon-Ro, Gangnam-gu, Seoul, Republic of Korea
- 0124 Successful Closure of Inadvertent Subclavian Artery Cannulation during Central Venous Catheter Placement Using a Percutaneous Closure Device
Jun Jie Ng, Jackie Ho
National University Health System, Singapore, Singapore
- 0151 Endovascular Aortic Aneurysm Repair (EVAR) Using Bifurcated Device in a Patient With Femoro-Femoral Bypass
Woo-Sung Yun, Bo-Yang Suh
Division of Transplantation and Vascular Surgery, Department of Surgery, Yeungnam University Medical Center, Yeungnam University College of Medicine, Daegu, Republic of Korea
- 0153 Percutaneous Angioplasty Balloon Assisted Thrombin Injection for Pseudoaneurysms
Sujith Wijerathne, Jackie Ho
National University Health System, Singapore, Singapore
- 0197 Our Cost-effective Repair Strategy of Innominate vein Injury Due to Spreading in Open Heart Surgery
 Ufuk Yetkin, Habib Cakir, Ihsan Peker, Koksai Donmez, Ali Gurbuz
Department of Cardiovascular Surgery, Katip Celebi University Izmir Ataturk Training and Research Hospital, Izmir, Turkey

- 0201 A Review of Factors Affecting Limb Salvage in Traumatic Arterial Injury: Kuantan, Malaysia Experience
Ismail Ali¹, Mohd Norhisham Azmi Abdul Rahman¹, Mohamad Sallehudin Che Zan², Hasmali Mohamad²,
 Izatt Syafieq Abd Rashad², Nazri Mohd Yusof³, Ahmad Faizal Othman¹
¹*Vascular Unit, Department of Surgery, Kuliyah (Faculty) of Medicine, International Islamic University Malaysia, Kuantan, Pahang, Malaysia*
²*Department of Surgery, Hospital Tengku Ampuan Afzan, Kuantan, Pahang, Malaysia*
³*Department of Orthopaedic and Traumatology, Kuliyah (Faculty) of Medicine, International Islamic University Malaysia, Kuantan, Pahang, Malaysia*
- 0215 Combined Endovascular and Surgical Approach for a Ruptured Extended Thoracic Aortic Aneurysm Patient Presented with Massive Hemoptysis
Yoshihito Irie¹, Shunichi Kondo¹, Eitoichi Tsuboi¹, Kyu Rokkaku¹, Hitoshi Yokoyama²
¹*Cardiovascular Surgery, Iwaki Kyouritsu General Hospital, Iwaki, Fukushima, Japan*
²*Cardiovascular Surgery, Fukushima Medical University, Fukushima, Japan*
- 0217 Novel Surgeon-modified Iliac Branched Device for Preserving Pelvic Flow
 Jin Hyun Joh, Bomina Baek
Kyung Hee University Hospital at Gangdong, Seoul, Republic of Korea

(E) Peripheral Arterial Disease

- 0002 Algorithm Proposed for the Management of Spontaneous Isolated Dissection of the Superior Mesenteric Artery and New Classification
Baku Takahashi¹, Shinyu Shiroma², Koki Ido², Yoshihiro Nakayama¹, Tomohiro Taguchi², Sumio Okuda²,
 Yosuke Mukae¹
¹*Department of Cardiovascular Surgery, Oosumikanoya Hospital, Kanoya-shi, Kagoshima, Japan*
²*Department of General Surgery, Oosumikanoya Hospital, Kanoya-shi, Kagoshima, Japan*
- 0006 Characteristics of Ankle-brachial and Toe-brachial Indexes and Pulse Volume Waveforms in Healthy Young Adults: Influences of Age and Gender
Yoshiko Watanabe, Hisao Masaki, Atushi Tabuchi, Yasuhiro Yunoki, Hiroshi Furukawa, Takahiko Yamasawa,
 Hiroki Takiuchi, Takeshi Honda, Noriaki Kuwada, Kazuo Tanemoto
Kawasaki Medical School, Kurashiki, Okayama, Japan
- 0022 Management of Acute Right and Left Brachial Artery Thrombosis after Catheterization
Kazim Ergunes, Banu Lafcı, Orhan Gokalp, Yuksel Besir, Koksall Donmez, Serkan Yazman,
 Levent Yılık, Ali Gurbuz
Izmir Katip Celebi University Atatürk Training and Research Hospital, Izmir, Turkey
- 0026 Significance of Infragenicular Bypass for Intermittent Claudication in the Era of Endovascular Treatment
Shinsuke Mii¹, Kiyoshi Tanaka¹, Ryoichi Kyuragi¹, Sosei Kuma²
¹*Steel Memorial Yawata Hospital, Kitakyushu-city, Japan*
²*Kokura Memorial Hospital, Kitakyushu-city, Japan*
- 0033 Excellent Long Time Patency of Femoro (ilio) Femoro Bypass Graft for Intermittent Claudicants
Hironobu Fujimura
Toyonaka Municipal Hospital, Toyonaka/Osaka, Japan
- 0053 Treatment Results for Spontaneous Isolated Superior Mesenteric Artery Dissection According to Our Previous Guidelines and Collective Literature Review
Byung Sun Cho¹, Hye Young Ahn²
¹*Eulji University Hospital, Daejeon, Republic of Korea*
²*Eulji University College of Nursing, Daejeon, Republic of Korea*

- 0055 A Case of Surgical Treatment for Leriche's Syndrome with Severe Carotid and Coronary Artery Diseases
Shinichiro Taniguchi¹, Seizaburo Sakamoto², Koichiro Takemoto², Hiromasa Kobayashi²,
 Masaki Takahara², Shun Nakaji¹, Ryuichiro Shibata¹
¹Sasebo Chuo Hospital, Cardiovascular Surgery, Sasebo, Nagasaki, Japan
²Sasebo Chuo Hospital, Neurological Surgery, Sasebo, Nagasaki, Japan
- 0063 PAD Hidden in Lower Limbs with Normal ABI
Yasuhiro Ozeki¹, Kazuo Tsuyuki¹, Shinichi Watanabe², Kenji Kohno¹, Kyoko Takashima¹, Mayumi Hamada¹,
 Yuki Tominaga¹, Hiroyoshi Yano¹, Kunio Ebine¹, Susumu Tamura¹, Masashi Yokomuro¹, Toshifumi Murase¹,
 Kenji Ninomiya¹, Naoya Moriki¹, Kenta Kumagai¹, Itaru Yokouchi¹, Satoru Toi¹
¹Odawara Cardiovascular Hospital, Odawara, Kanagawa, Japan
²Development Center to Support Health and Welfare, Kanagawa Institute of Technology, Atsugi,
 Kanagawa, Japan
- 0076 Long Term Result of Kissing Stent in Aortoiliac Bifurcation: A Single Center Experience
Hong Pil Hwang^{1,2}, Jae Do Yang^{1,2}, Sang In Bae^{1,2}, Young Min Han^{1,2}, Hee Chul Yu¹
¹Chonbuk National University Hospital, Jeonju, Chonbuk, Republic of Korea
²Research Institute of Clinical Medicine, Jeonju, Chonbuk, Republic of Korea
- 0083 Surgical Experience with Thoracic Outlet Syndrome
Hirotoki Ohkubo, Keita Hayashi, Naotsugu Yamashiro, Shintaro Shibutani, Shinobu Hayashi
 Department of Vascular Surgery, Saiseikai Yokohamashi Tobu Hospital, Yokohama/Kanagawa, Japan
- 0116 A Case of Persistent Sciatic Artery Occlusion with Blue Toe Syndrome
Naotsugu Yamashiro, Hirotoki Ohkubo, Shintaro Shibutani, Keita Hayashi, Shinobu Hayashi,
 Atsushi Nagashima
 Saiseikai Yokohamashi Tobu Hospital, Yokohama/Kanagawa, Japan
- 0123 Surgical Revascularization in Chronic Mesenteric Ischemia and Abdominal Aortic Aneurysm
Hyuk Jae Jung, Ji Ho Lee, Sang Su Lee
 Pusan National University Yangsan Hospital, Yangsan, Gyeongnam, Republic of Korea
- 0125 Hybrid Treatment in Buerger's Disease
Hyuk Jae Jung, Ji Ho Lee, Sang Su Lee
 Pusan National University Yangsan Hospital, Yangsan, Gyeongnam, Republic of Korea
- 0129 Thoracoabdominal Approach for Visceral Artery Aneurysm with a Common Celiomesenteric Trunk, Caused by Median
 Arcuate Ligament Syndrome
Hitoshi Inafuku¹, Yukio Kuniyoshi¹, Satoshi Yamashiro¹, Yuichi Totsuka¹, Katsuya Arakaki², Yuji Morishima²
¹University of the Ryukyus, Okinawa, Uehara, Nishihara, Japan
²Urasoe General Hospital, Okinawa, Urasoe, Japan
- 0146 Traumatic Tearing of Common Femoral Artery and External Iliac Vein Treated by Hybrid Operation
Hyuk Jae Jung, Ji Ho Lee, Sang Su Lee
 Pusan National University Yangsan Hospital, Yangsan, Gyeongnam, Republic of Korea
- 0150 Endovascular Treatment for Infrainguinal Chronic Total Occlusions and Severe Stenoses Using the High-frequency
 Vibrational Energy Device
Masahiro Nakamura, Toshifumi Kudo, Yohei Yamamoto, Sotaro Katsui, Masato Nishizawa, Kimihiro Igari,
 Shinya Koizumi, Takahiro Toyohuku, Yoshinori Inoue
 Tokyo Medical and Dental University, Tokyo, Japan
- 0165 Case Report on Treatment of a True Axillary Artery Aneurysm Associated with Distal Thrombosis in a Professional
 Basketball Player
Kwok Fai Cheung, Hon Cheung Hui, Wai Yin Lo, Kwong Man Chan, Leung Sing Ho
 Princess Margaret Hospital, Hong Kong, Hong Kong

- 0180 Management of Mycotic Femoral Pseudoaneurysm in Intravenous Drug Abuser—Single Institute Experience
Zhimin Lin¹, Jack Kian Ch'ng², Benjamin, Soo Yeng Chua²
¹National University of Singapore, Yong Loo Lin School of Medicine, Singapore, Singapore
²Singapore General Hospital, Singapore, Singapore
- 0199 Blue Toe Syndrome: A Rare Presentation of Atrial Myxoma
Norhafiza Abdul Rahman¹, Ahmad Faizal Othman¹, Ahmad Khadri Awang²
¹Vascular Unit, Department of Surgery, International Islamic University Malaysia, Kuantan, Pahang, Malaysia
²Cardiothoracic Unit, Department of Surgery, International Islamic University Malaysia, Kuantan, Pahang, Malaysia
- 0221 Comparison between Surgical Bypass and Percutaneous Transluminal Angioplasty for the Treatment of Peripheral Arterial Disease of Lower Limbs in a Locoregional Hospital in Hong Kong
Lok Ping Si, Kin Leung Hui, Wai Tat Chan
Department of Surgery, Ruttonjee Hospital, Hong Kong, Hong Kong
- 0222 Percutaneous Transluminal Angioplasty for the Treatment of Lower Limb Peripheral Arterial Disease: A Six-year Experience in a Locoregional Hospital in Hong Kong
Lok Ping Si, Kin Leung Hui, Wai Tat Chan
Department of Surgery, Ruttonjee Hospital, Hong Kong, Hong Kong
- 0237 STAT4 is Required for Homocysteine-induced Proliferation and Migration of Human Aorta Smooth Muscle Cell via MCP-1 Secretion
Weibin Huang, Lei Lu, Hui Xie, Meng Ye, Ji-wei Zhang, Lan Zhang
Department of Vascular Surgery, Renji Hospital, School of Medicine, Shanghai Jiaotong University, Shanghai, China
- 0244 Successful Treatment of Aberrant Splenic Artery Aneurysm with a Combination of Coils Embolization and Covered Stents: A Report of Three Consecutive Cases and Review of the Literature
Weimin Zhou, Jiehua Qiu, Qingwen Yuan, Jixin Xiong
Department of Vascular Surgery, the Second Affiliated Hospital of Nanchang University, Nanchang, China
- 0281 Endovascular retrograde recanalization in critical limb ischaemia using the “SAFARI” technique: a single-centre experience
Jia Sheng Tay, Sulaiman Bin Yusof, Siok Siong Ching, Yin Kai Tan, Wei Cheong Kum
Department of Surgery, Changi General Hospital, Singapore

(F) Thoracic Aorta Disease

- 0007 Aortic Coarctation Treated with Self Expandable Stent Graft
Fundu Yildirim, Alper Ozbakaloglu, Ozlem Karaaslanyuksel, Taner Kurdal, Mustafa Cerrahoglu, Ihsan Iskesen, Omer Tetik
Celal Bayar University, School of Medicine, Department of Cardiovascular Surgery, Manisa, Turkey
- 0028 Gigantic Chronic Mega-aneurysm of Aorta with Type 1 Dissection
Cengiz Ozbek², Ufuk Yetkin¹, Koksal Donmez¹, Kazım Ergunes¹, Nagehan Karahan³, Ali Gurbuz¹
¹Department of Cardiovascular Surgery, Katip Celebi University Izmir Atatürk Training and Research Hospital, Izmir, Turkey
²Department of Cardiovascular Surgery, Tepecik Training and Research Hospital, Izmir, Turkey
³Department of Clinical Anesthesiology, Katip Celebi University Izmir Atatürk Training and Research Hospital, Izmir, Turkey

- 0029 Our Successful Combined Surgical Strategy with our Modified Cerebral Perfusion Method in a Patient with Incidentally Found Type 2 Aortic Dissection at Coronary Artery Bypass Surgery
 Ufuk Yetkin¹, Habib Cakir¹, Nagehan Karahan², Ersin Celik¹, Koksai Donmez¹, Ali Gurbuz¹
¹*Department of Cardiovascular Surgery, Katip Celebi University Izmir Atatürk Training and Research Hospital, Izmir, Turkey*
²*Department of Anesthesiology, Katip Celebi University Izmir Atatürk Training and Research Hospital, Izmir, Turkey*
- 0032 Surgical Treatment of Right-sided Aortic Arch Aneurysm Arising from a Kommerell's Diverticulum with an Aberrant Left Subclavian Artery
Koki Yokawa, Takuo Nomura, Mitsuru Asano
Seirei Mikatahara Hospital, Hamamatsu/Shizuoka, Japan
- 0044 Surgery for Acute Type A Aortic Dissection in Octogenarians
Hideyuki Kunishige, Yoshimitsu Ishibashi, Masakazu Kawasaki, Nozomu Inoue
National Hospital Organization Hokkaido Medical Center, Sapporo, Hokkaido, Japan
- 0046 The Timing of Thoracic Endovascular Aortic Repair for Aortic Dissection
Takashi Hashimoto, Noriyuki Kato, Takatoshi Higashigawa, Shuji Chino
Mie University Hospital, Tsu, Japan
- 0054 Total Endovascular Repair of Aberrant Left Subclavian Artery with Kommerell's Diverticulum Using a Fenestrated Stent Graft
Takeshi Okamoto¹, Yoshihiko Yokoi², Kazuhiko Hanzawa¹, Hiroki Satou¹, Kenji Aoki¹, Osamu Namura¹, Masanori Tsuchida¹
¹*Niigata University Graduate School of Medical and Dental Sciences, Niigata, Japan*
²*Tokyo Women's Medical University Hospital, Tokyo, Japan*
- 0074 Total Debranching TEVAR for Distal Aortic Arch Aneurysm with No Access Routes from the Femoral Artery
Hiroaki Yusa, Imun Tei, Shou Tatebe, Makoto Taoka, Tomoaki Tanabe, Eiichi Tei
Ayase Heart Hospital, Tokyo, Japan
- 0089 A Case Report of Stanford Type-A Acute Aortic Dissection Resuscitated by Percutaneous Cardiopulmonary Support from Cardiopulmonary Arrest Due to Cardiac Tamponade Caused by Aortic Rupture
Yoshio Mori, Yukihiro Matsuno, Yukio Umeda, Hiroshi Takiya
Gifu Prefectural General Medical Center, Gifu, Japan
- 0091 The Early and Late Results of Surgery for Acute Type A Aortic Dissection in Octogenarians
Atsushi Omura, Mukohara Nobuhiko, Masato Yoshida, Hitoshi Matsuda, Hirohisa Murakami, Hitoshi Minami, Tasuku Honda
Hyogo Brain and Heart Center at Himeji, Hyogo, Japan
- 0092 Prevention of Postoperative Spinal Cord Ischemia in Surgical Treatment of Thoracoabdominal Aortic Aneurysm
Mizuki Ando, Yuichi Totsuka, Ryoko Arakaki, Tatsuya Maeda, Yuya Kise, Hitoshi Inahuku, Moriyasu Nakaema, Takaaki Nagano, Satoshi Yamashiro, Yukio Kuniyoshi
Ryukyu University Hospital, Nishihara, Nakagami/Okinawa, Japan
- 0093 Current Result of Patch Repair for Saccular Aneurysms of the Aortic Arch
Yutaka Kobayashi, Haruo Suzuki, Atsushi Kawakami
Uji-Tokushukai Medical Center, Kyoto, Japan
- 0094 Endovascular Treatment of Descending Aorta Stenosis in Takayasu's Arteritis
Sang Jun Park¹, Hojong Park¹, Jae Chol Hwang², Young Woo Seo², Ji Sun Oh³, Hong Rae Cho¹
¹*Department of Surgery, University of Ulsan College of Medicine, Ulsan, Republic of Korea*
²*Department of Radiology, University of Ulsan College of Medicine, Ulsan, Republic of Korea*
³*Department of Internal Medicine, University of Ulsan College of Medicine, Ulsan, Republic of Korea*

- 0119 Aneurysms of the Innominate Artery: Our Early and Midterm Results of 7 Series of Patients
Yojiro Koda, Atsushi Omura, Hirohisa Murakami, Hitoshi Matsuda, Masato Yoshida, Nobuhiko Mukohara
Hyogo Brain and Heart Center at Himeji, Hyogo, Japan
- 0157 Thoracic Periaortic Hydatid Fluid Collection Mimic Contained Hematoma of Acute Aortic Syndrome
Abdelrahman Elkaialy, Abdeulmohsen Alzakari
King Fahd National Guard Hospital/King Saud Bin Abdulaziz University for Health Sciences, Riyadh, Saudi Arabia
- 0170 Cardiac Arrest Due to Dynamic Obstruction of Aorta during Course of the Acute Type B Aortic Dissection: Case Report
Kimimasa Sakata, Akio Yamashita, Katsunori Takeuchi, Koji Seki, Tatsuro Matsuo, Masaya Aoki, Kanetsugu Nagao, Naoki Yoshimura
Department of Thoracic and Cardiovascular Surgery, University of Toyama, Toyama, Japan
- 0176 Two Stage Operations for Chronic Type B Dissecting Aortic Aneurysm with Aberrant Right Subclavian Artery and Kommerell Diverticulum: A Case Report
Katsunori Takeuchi, Akio Yamashita, Tatsuro Matsuo, Koji Seki, Masaya Aoki, Kimimasa Sakata, Kanetsugu Nagao, Naoki Yoshimura
Department of Thoracic and Cardiovascular Surgery, University of Toyama, Toyama, Japan

(G) Vascular Access

- 0004 Superficialization of the Deep-seated Cephalic Vein with Native Arteriovenous Fistula for Effective Hemodialysis Access Construction
Dan Song, Sangchul Yun, Seok Han
Soonchunhyang University Seoul Hospital, Seoul, Republic of Korea
- 0008 Role of Prophylactic Antibiotic in the Placement of Totally Implanted Central Venous Access Port
Chong-Chi Chiu, Tsung-Chih Tsai
Department of General Surgery, Chi Mei Medical Center, Tainan and Liouying, Taiwan
- 0037 Intra-operative Cephalic Vein Distensibility Can Predict Nonmaturation of Radiocephalic Arteriovenous Fistula
Mihyeong Kim¹, Youngkyun Kim², Insung Moon¹, Jiil Kim¹
¹*Seoul St. Mary's Hospital, Seoul, Republic of Korea*
²*Daejeon Sun Hospital, Daejeon, Republic of Korea*
- 0039 Stentgraft Insertions for Thrombosed Arteriovenous Grafts Outflow Stenosis
Petr Bachleda¹, Petr Utíkal², Martin Köcher¹, Marie Cerna², Jana Fialová²
¹*LF UP, Olomouc, Czech Republic*
²*Fakultní Nemocnice, Olomouc, Czech Republic*
- 0049 Early Detection of Infection of Arteriovenous Graft for Hemodialysis; The Significance of Radionuclide Methods
Petr Bachleda¹, Petr Utíkal², Jana Fialová², Lucie Kalinova¹, Miroslav Mysliveček²
¹*LF UP, Olomouc, Czech Republic*
²*Fakultní Nemocnice, Olomouc, Czech Republic*
- 0050 Inferior Vena Cava as a “Run-of Conduit” for Arteriovenous Grafts in Selected Hemodialysis Patients: Is it still Relevant?
Igor Rabin¹, Leonid Feldman², Laurian Copel³, Jonathan Lorber¹, Arie Bass¹
¹*Vascular Surgery Department, Assaf Harofeh Medical Center, Affiliated to Sackler Faculty of Medicine, Tel-Aviv University, Zerifin, Israel*
²*Nephrology Department, Assaf Harofeh Medical Center, Affiliated to Sackler Faculty of Medicine, Tel-Aviv University, Zerifin, Israel*
³*Department of Radiology, Assaf Harofeh Medical Center, Affiliated to Sackler Faculty of Medicine, Tel-Aviv University, Zerifin, Israel*

- 0052 Percutaneous Access for Endovascular Stenting—The Pioneer Experience in a Local Center
TLD Fung¹, KF Cheung, KM Chan, WY Lo, LF Cheng, LS Ho
Princess Margaret Hospital, Hong Kong, Hong Kong
- 0103 Comparison of Surgical and Endovascular Salvage Procedures for Juxta-anastomotic Stenosis in Autogenous Wrist Radiocephalic Arteriovenous Fistula
Hyunwook Kwon, Ji Yoon Choi, Youngjin Han, Tae-Won Kwon, Yong-Pil Cho
Asan Medical Center, Seoul, Republic of Korea
- 0138 Hemodynamic Simulation of Arteriovenous Fistulas Having Different Anastomosis Angles—reverse Anastomosis
Sun Cheol Park¹, Jinkee Lee²
¹*The Catholic University of Korea, School of Medicine, Seoul, Republic of Korea*
²*Sungkyunkwan University, School of Mechanical Engineering, Suwon, Republic of Korea*
- 0182 Lipectomy as an Salvage Option for Deeply Located Arteriovenous Fistula
Hyoun Tae Kim, Seulgi Hyun, Uijun Park, Won Hyun Cho
Keimyung University Dongsan Medical Center, Daegu, Republic of Korea
- 0200 Successful Limb Salvage after an Iatrogenic Femoral Atrio-venous Fistula: A Case Report
Mohd Abdul Rauf Paharudin, Mohd Norhisham Azmi Abdul Rahman, Ahmad Faizdal Othman
Vascular Unit, Department of Surgery, International Islamic University Malaysia, Kuantan, Pahang, Malaysia
- 0220 The Mid-sternal Length, a Practical Anatomical Landmark for Optimal Positioning of Long-term Central Venous Catheters
Fereshteh Salimi, Amir Keshavarzian, Navab Ghasemi, Mohammad Imani
Isfahan University of Medical Sciences, Isfahan, Iran

(H) Venous Disease

- 0018 Preliminary Report: Study of Inflammatory Responses in Varicose Veins Surgery, A Comparison between Conventional Venous Stripping and Endo-venous Radio-frequency Ablation (EV-RFA)
Pisake Boontham, Norraporn Chairaroon, Nunthapol Pongrattananan, Anucha Panoi, Tamrongroj Temudom, Chaiwat Kunanuson
Division of Vascular Surgery, Department of Surgery, Phramongkutklao Hospital, Bangkok, Thailand
- 0020 Catheter-directed Thrombolysis with rt-PA in a Patient with Lower Extremity Deep Venous Thrombosis Developing after Medical Abortion
Ismail Yurekli, Kazim Ergunes, Levent Yilik, Yuksel Besir, Ufuk Yetkin, Serkan Yazman, Tayfun Goktogan, Ali Gurbuz
Izmir Katip Celebi University Atatürk Training and Research Hospital, Izmir, Turkey
- 0036 The Clinical Importance of Anomaly on Inferior Vena Cava in the Graft Donation Surgery from a Deceased Donor
Mihyeong Kim, Kangwoong Jun, Insung Moon, Jiil Kim
Seoul St. Mary's Hospital, Seoul, Republic of Korea
- 0075 Prevalence of Lower Limb Varix in Hemodialysis Patients
Yasuhiro Ozeki¹, Kazuo Tsuyuki¹, Shinichi Watanabe², Kunio Ebine¹, Susumu Tamura¹, Masashi Yokomuro¹, Toshifumi Murase¹, Kenji Ninomiya¹, Naoya Moriki¹, Kenta Kumagai¹, Itaru Yokouchi¹, Satoru Toi¹, Kenji Kohno¹, Kyoko Takashima¹, Mayumi Hamada¹, Yuki Tominaga¹, Hiroyoshi Yano¹
¹*Odawara Cardiovascular Hospital, Odawara, Kanagawa, Japan*
²*Development Center to Support Health and Welfare, Kanagawa Institute of Technology, Atsugi, Kanagawa, Japan*
- 0109 Use of meso-Rex Shunt with Transposition of the Coronary Vein for the Management of Extrahepatic Portal Vein Obstruction
Hyunwook Kwon, Yong-Pil Cho, Tae-Yong Ha, Gi-Young Ko, Kyung-Mo Kim, Sung-Gyu Lee
Asan Medical Center, Seoul, Republic of Korea

- 0135 Study of 5 Cases that Required PCPS for Acute Pulmonary Embolism
Sakurai Yuka¹, Abe Hiroyuki², Suzuki Hirotoshi¹, Sagane Masatoshi¹, Ro Daijyun¹, Chiba Kiyoshi¹,
 Ono Hirokuni¹, Oono Makoto¹, Kitanaka Yousuke¹, Masahide Chikada¹, Nishimaki Hiroshi¹, Miyairi Takeshi¹
¹*St. Marianna University of Medicine Cardiovascular Surgery, Kanagawa, Japan*
²*Keiai Hospital, Kanagawa, Japan*
- 0141 Simultaneous Percutaneous Treatment of Bilateral (B/L) Varicocele and B/L Lower Limbs Varicose Veins in an Infertile Male in Era of Hybrid Operating Room
Sandeep Raj Pandey
Norvic Int'l Hospital, Kathmandu, Nepal
- 0147 Deep Vein Thrombosis of Unusual Etiology as a Hip Joint Ganglion Cyst
In Mok Jung, Jung Kee Chung, Young Ho Soh
Snu-Smg Boramae Medical Center, Seoul, Republic of Korea
- 0160 Surgical Treatment of Inferior Vena Cava (IVC) Malignant Thrombus with Cardiac Extension Secondary to Pelvic Tumor
Abdelrahman Elkaialy, Faisal Alsafi, Haney Najm
King Fahd National Guard Hospital/King Saud Bin Abdulaziz University of Health Sciences, Riyadh, Saudi Arabia
- 0164 Our Approach to Right Lower Extremity Deep Vein Thrombosis in a Patient with Complicated Takayasu's Arteritis
 Ufuk Yetkin, Ihsan Peker, Koksall Donmez, Ali Gurbuz
Department of Cardiovascular Surgery, Katip Celebi University Izmir Ataturk Training and Research Hospital, Izmir, Turkey
- 0167 Five Years Experience of Conventional Venous Stripping for Varicose Veins at Lampang Hospital, Thailand: It's Still Working
Boonsap Sakboon¹, Nuttapon Arayawudhikul²
¹*Lampang hospital, Lampang, Thailand*
²*Chiangmai University, Chiangmai, Thailand*
- 0177 Short-term Catheter-directed Thrombolysis with Low-dose Urokinase Followed by Aspiration Thrombectomy for Treatment of Symptomatic Acute Lower Extremity Deep Venous Thrombosis
Soo Jin Na Choi¹, Hag Zu Kim², Ho Kyun Lee¹, Sang Young Chung¹
¹*Chonnam National University Hospital, Gwangju, Republic of Korea*
²*Health Insurance Review & Assessment Service, Seoul, Republic of Korea*
- 0178 Endovenous Therapy for Venous Insufficiency: A Review of 79 Consecutive Cases
Chun Ling Patricia Yih, Yin Chun Skyi Pang, Chung Ngai Tang
Department of Surgery, Pamela Youde Nethersole Eastern Hospital, 3 Lok Man Road, Chai Wan, Hong Kong
- 0184 Splenic Vein Aneurysm Associated with Splenic Arteriovenous Fistula—A Case Report
Dae Yong Kim, Byeong Kwon Jeong, Byung Jun So
Wonkwang Uni Hosp., Iksan, Jeonbuk, Republic of Korea
- 0192 Successful Medical Treatment of a Patient with Chronologically Discordant Superficial and Deep Combined Thrombophlebitis that is Complicated with Cellulitis
 Ufuk Yetkin, Koksall Donmez, Hasan Iner, Ihsan Peker, Ali Gurbuz
Department of Cardiovascular Surgery, Katip Celebi University Izmir Ataturk Training and Research Hospital, Izmir, Turkey
- 0194 Popeye Syndrome: Hemodialysis Catheter Related Central Vein Occlusion
Patrick Louie Maglaya, Leoncio Kaw
Philippine General Hospital, National Capital Region, The Philippines

0236 PROC Mutations Causing Inherited Venous Thrombosis in Chinese Population

Haoyu Deng^{1,4}, Jun Xie², Wei Shen³, Yi Gu³, Biqin Fang¹, Jiaquan Chen¹, Hui Xie¹, Weibin Huang¹,
Meng Ye¹, Lei LV¹, Jiwei Zhang¹, Lan Zhang¹

¹*Department of Vascular Surgery, Renji Hospital, School of Medicine, Shanghai JiaoTong University, Shanghai, China*

²*The State Key Lab of Genetic Engineering, School of Life Sciences, FuDan University, Shanghai, China*

³*Department of Clinical Laboratory, Renji Hospital, School of Medicine, Shanghai JiaoTong University, Shanghai, China*

⁴*Department of Pathology and Laboratory Medicine, Faculty of Medicine, University of British Columbia, Vancouver, Canada*

⁵*Centre for Heart Lung Innovation, St. Paul's Hospital, Vancouver, Canada*

(A) Abdominal Aorta Disease

0010

Endovascular Abdominal Aortic Repair Application in Patients with Complex Iliac Pathology

Funda Yildirim, Alper Ozbakaloglu, Ozlem Karaaslanyuksel, Taner Kurdal, Mustafa Cerrahoglu, Ihsan Iskesen, Omer Tetik

Celal Bayar University, School of Medicine, Department of Cardiovascular Surgery, Manisa, Turkey

Endovascular abdominal aortic repair for aortic aneurysm is more preferred nowadays. Anatomical characteristics of abdominal aortic aneurysms are the most important factors in order to determine the success of endovascular aortic repair (EVAR). Some of them are severe proximal aortic neck angulation, iliac arterial tortuosity, angulation and aneurysmal dilatation. Neck angulation may be main place for fixation failure, a situation that may lead to complications, including endoleak and late rupture.

We present 15 patients with abdominal aort aneurysm associated with iliac pathology and comorbidity. Most of the patients were over 70 years old. They had comorbidities like coronary artery disease, obesity, diabetes mellitus, previous abdominal surgery and chronic obstructive pulmonary disease with increased risk of general anesthesia. As most of the world does we preferred EVAR in order to avoid risks of open surgery. All of our patients had iliac artery involvement. We exposed both femoral arteries with small incisions. After the placement of the main body we used extension stent grafts for both iliac systems. All of the patients were discharged on post operative 3rd day without any problem. Control CT angiograms showed no endoleak or patent aneurysm formation.

We strongly recommend the use of EVAR technique with extantion stent grafts when there is both iliac artery involvement to avoid endoleaks.

0015

Secondary Aortoenteric Fistula (AEF)—Review of a Case

Sandeep Raj Pandey

Norvic Int'l Hospital, Kathamndu, Nepal

Objective: To assess early diagnosis and management of hematemesis in patients who have a history of aortic reconstructive surgery.

Material and Methods: A 70-year-old man presented with complains of active hematemesis and melena for 2 days at the

Emergency Room. He gave a history of aortic reconstructive surgery 9 years ago. Urgent Computed Tomography(CT) angiography was done suggestive of large aortic anastomotic pseudoaneurysm with aortoenteric fistula. Urgent Endovascular repair of pseudo-aneurysm with Right femoral artery to Left femoral artery crossover with ligation of Left femoral artery, Left common iliac artery and Left graft limb was done.

Results: The patient did well after the surgical management. Routine follow-up was done. Repeat CT-angio was done. No any major complication was encountered.

Conclusion: Secondary aortoenteric fistula is a life-threatening complication of abdominal aortic reconstruction. The clinical manifestation of the aortoenteric fistula is always hematemesis. Treatment of the disease is urgent hybrid surgical intervention.

0042

The Factors of Recurrence in Leriche's Syndrome

Sung Woon Chung, Mi-ju Bae, Min su Kim

Pusan National University Hospital, Department of thoracic and cardiovascular surgery, Busan, Republic of Korea

Background: Leriche's syndrome has several symptoms such as the ulcers of lower extremities, rest pain, claudication, and erectile dysfunction. The author of this study has reviewed the observations and treatment experiences of Leriche's syndrome for 5 years, retrospectively.

Methods: A total of 20 patients with Leriche's syndrome who had underwent surgical treatment through February 2007 to November 2011 were reviewed retrospectively.

Results: The observation period lasted from 59 days to 2167 days, with the average of 1001.45 days. A total of 19 patients underwent aorto-biiliac bypass (2 out of 20), aorto-bifemoral bypass (11 out of 20), and axillo-bifemoral bypass surgery (6 out of 20), and one patient was treated by percutaneous endovascular biiliac kissing stenting. The incidence rate of postoperative thrombosis in aorto-bifemoral bypass surgery was 36.36% (4 out of 11), and that of the axillo-bifemoral bypass surgery was 50% (3 out of 6). No patient presented postoperative thrombosis in aorto-biiliac bypass surgery (0 out of 2). The postoperative mortality rate was 10% (2 out of 20). Smoking ($P = 0.017$) and the number of smoking pack years ($P = 0.029$) were linked with postoperative thrombosis, statistically.

Conclusion: The postoperative thrombosis of artificial graft is related to the constant smoking and the amount of tobacco smoked. This study did not provide statistical significance, but the extra anatomical bypass surgery could certainly increase postoperative thrombosis. Therefore, it is important to prevent postoperative thrombosis in the patients by providing them with the anti-smoking education, and the extra-anatomical bypass surgery must also be performed at limited situations.

The Effect of Adjunctive Iliac Stent during Endovascular Aneurysm Repair to Prevent Iliac Limb Occlusion

Jae Hoon Lee, Ki Hyuk Park

Daegu-Catholic Univ. Medical Center, Daegu, Republic of Korea

Purposes: Endovascular aneurysm repair (EVAR) involving the common iliac artery aneurysm (CIAA) requires extension of the stent-graft limb into the external iliac artery (EIA). Deployment of endograft limbs into the EIA led to a higher rate of occlusion. In Korea, there was no report about the relationship between adjunctive stents and limb occlusion. This study reports our experience with adjunctive bare metal stents and investigates limb thrombosis as a complication.

Methods: We performed a retrospective review of 98 patients who underwent EVAR between 2010 and 2013 at our institution.

Results: The mean follow-up duration was 288 days. We underwent EVAR involving with CIAA in 38 (39%) patients and 58 (30%) limbs. In patients with CIAA, 33 (87%) patients were male sex and mean diameter of CIA was 29.97 ± 7.96 mm. We identified 38 (66%) limbs which had been extended of the stent-graft limb into EIA. In all cases of extension limb into the EIA, adjunctive bare metal stents (SMART; Cordis, a Johnson & Johnson company, Miami, FL, USA) were deployed. No limb occlusions occurred in the presence of adjunctive bare metal stents.

Conclusions: Adjunctive stenting reduced the risk of postoperative stent-graft limb occlusion without complication. Nitinol SMART stent which is showed excellent results may be considered as standard procedure to EVAR. Studies about the experience of other researchers using the balloon expandable stent for comparison are needed. Further large study and long-term follow-up is mandatory.

0047

Successful EVAR for an Abdominal Aortic Aneurysm with Horseshoe Kidney

Norimasa Koike¹, Toru Takahashi¹, Jun Mohara¹, Kei Shibuya², Takao Miki¹, Izumi Takeyoshi¹

¹Department of Thoracic and Visceral Organ Surgery, Gunma University Graduate School of Medicine, Maebashi, Japan

²Department of Diagnostic Radiology and Nuclear Medicine, Gunma University Graduate School of Medicine, Maebashi, Japan

There is still controversy as to which surgical method is the most suitable for repair of an abdominal aortic aneurysm (AAA) with concomitant horseshoe kidney. Here we report a case of an AAA with horseshoe kidney, which was successfully treated with endovascular aneurysm repair (EVAR). A 65-year-old male was referred to our hospital. Computed tomography (CT) revealed AAA

measuring 49 mm in diameter and right common iliac aneurysm (RCIA) measuring 23 mm in diameter with a horseshoe kidney. In this case, two normal renal arteries arose from the aortic neck, and one accessory renal artery measuring 5 mm in diameter arose from the abdominal aortic aneurysm and another accessory renal artery measuring 2 mm in diameter arose from the right common iliac artery. EVAR was performed simultaneously, followed by coil embolization to the right internal iliac artery, one accessory renal artery arose from the abdominal aortic aneurysm and inferior mesenteric artery in order to prevent type II endoleak. On the fourth postoperative day, enhanced CT showed no endoleak. The postoperative course was uneventful, and the patient was discharged on the seven postoperative day with normal renal function. If the blood supply to the kidney is taken into consideration, EVAR is preferred surgical method for repair of AAA with a horseshoe kidney when anatomic conditions are suitable for stent-graft application and kidney function is normal.

0048

A Case of Delayed Graft Leg Proximal Migration after Endovascular Repair for the Aneurysms of Abdominal Aorta and Bilateral Common Iliac Arteries

Shinji Yamazoe, Yasuhito Sekimoto, Hirohisa Harada

Tokyo Dental College, Ichikawa General Hospital, Ichikawa City, Chiba, Japan

Background: Migration is one of complications of endovascular aortic repair (EVAR) for abdominal aortic aneurysm (AAA). Migration occurs at frequency of 3.6–16.6% after EVAR. Most migrations are reported to occur at proximal side and there are few reports of migration of leg. We present a successful case in that we treated delayed expansion of common iliac arterial aneurysm (CIAA) caused by leg proximal migration after EVAR for AAA and CIAA by using the additional leg device.

Case: Patient was an about-70-year-old man. He visited to vascular surgery in our hospital because of abdominal pulsatile mass and lower back pain. He was diagnosed as infra-renal AAA (63 mm in diameter) and bilateral CIAAs by CT angiogram (CTA), and EVAR was chosen for the treatment. We performed coil embolization in bilateral internal iliac artery in advance, and EVAR at a later date. We chose Excluder device and deployed leg grafts to the bilateral external iliac arteries. No intraoperative endoleaks was found finally but we noticed that landing length of the right graft leg was slightly shorter than expected. The postoperative course was uneventful and the patient was determined to be in follow-up. One year after EVAR, he was developed a type Ib endoleak caused by the right leg proximal migration without right CIAA expansion by CTA. Six months later we performed re-operation because of progress of the leg migration and expansion of the right CIAA. We deployed an additional leg device from right inguinal approach, and the endoleak was disappeared.

Conclusion: There are few reports of expansion or rupture of aneurysm caused by migration of legs after EVAR, but it is necessary to consider leg migration after EVAR for the AAA concomitant with CIAA. It was considered important to ensure sufficient landing length of leg to avoid late leg migration.

0056

Delayed Abdominal Closure Prevent Abdominal Compartment Syndrome for a Ruptured Abdominal Aortic Aneurysm—Report of a Case

Yutaka Hasegawa, Masahiko Ezure, Noritsugu Naito, Syuichi Okada, Chieri Kimura, Shuichi Okonogi, Hitomi Takihara, Tatsuo Kaneko

Division of Cardiovascular Surgery, Gunma Prefectural Cardiovascular Center, Maebashi, Japan

Introduction: In spite of modern advances in medical care, the surgical mortality of ruptured abdominal aortic aneurysm (rAAA) remains high at 40% to 50%. In these patients, multiple organ failure (MOF) is one of the reasons for the high mortality rates. An acute increase in intra-abdominal pressure and abdominal compartment syndrome (ACS) are common causes of MOF. Delayed abdominal closure is effective to prevent ACS in rAAA patients. We present a case of rAAA successfully achieved delayed abdominal closure.

Case Report: A 66-year-old man lost consciousness complained of severe abdominal pain. He underwent computed tomography (CT) at a neighboring hospital. The CT scan showed an 85 mm infrarenal AAA with a large retroperitoneal hematoma. He was brought to our hospital. On arrival he presented with hemorrhagic shock, a 12Fr occlusion balloon catheter was inserted from his femoral artery and inflated at proximal abdominal aorta. He underwent an emergency operation. A ruptured hole was observed on the front wall of the aneurysm. The aneurysm was resected and reconstructed with a prosthetic bifurcated graft. The abdominal wall was distended because of the retroperitoneal hematoma and severe edematous bowel change. A delayed abdominal closure was performed to prevent ACS. A 10 cm wide Esmarch's rubber sheet was placed over the enteric canal, and sutured to the edge of the abdominal wall. A hydrocellular polyurethane dressing and a 19-F J-VAC silicone drain were placed on the rubber sheet. The wound was covered with an iodine drape and was drained by continuous suction (50 cm H₂O of negative pressure). The abdominal distension improved by 4 days after the primary operation, and therefore a secondary abdominal closure was performed. No infection was seen, and the wound healing was good.

Conclusion: The delayed abdominal closure technique is considered to be useful to prevent ACS for the treatment of rAAA.

0060

Crossover Chimney Technique to Preserve the Internal Iliac Artery in Common Iliac Artery Aneurysms

Ho Kyun Lee¹, Oh Hyun Park¹, Jae Kyu Kim², Soo Jin Na Choi¹, Sang Young Chung¹

¹Department of Surgery, Chonnam National University Medical School, Gwangju, Republic of Korea

²Department of Radiology, Chonnam National University Medical School, Gwangju, Republic of Korea

Purpose: We report a technique to preserve the internal iliac artery (IIA) in case of aortoiliac aneurysms.

Cases: 67-year-old male visited hospital for known history of right common iliac artery aneurysm. Physical examination was remarkable for a palpable abdominal mass at RLQ. Computed tomography (CT) angiography of the abdomen and measured the Rt CIA at 4 cm. Decision was made to perform an endovascular aneurysm repair (EVAR) with crossover chimney technique. This technique has been used in 2 patients with success. There was no acute branch occlusion or type I endoleak from the IIA or chimney graft gutters on imaging follow-up study.

0061

Endovascular Exclusion of Abdominal Aortic Aneurysm in Patients with Concomitant Abdominal Malignancy

Ho Kyun Lee¹, Oh Hyun Park¹, Jae Kyu Kim², Soo Jin Na Choi¹, Sang Young Chung¹

¹Department of Surgery, Chonnam National University Medical School, Gwangju, Republic of Korea

²Department of Radiology, Chonnam National University Medical School, Gwangju, Republic of Korea

Purpose: To assess the outcomes of endovascular aortic aneurysm repair (EVAR) for the treatment of abdominal aortic aneurysm in patients undergoing curative surgical treatment for concomitant abdominal malignancy.

Material and Methods: Materials were 23 patients with both abdominal neoplasia and AAA were treated by surgical method and EVAR. The neoplasm consisted with gastric, colorectal, pancreas, prostate and gall bladder. The follow up period was 3–57 months (mean 25.8 months). All medical record and imaging analysis were reviewed with CTA and/or color Doppler US, retrospectively.

Results: Successful endoluminal repair was accomplished in all twelve patients. The mean interval after EVAR to surgery was 58.6 days. Small amount of type 2 endoleaks were detected in four patients (17%). Adult respiratory distress syndrome after Whipple's operation on postoperative 20th day was developed in one patient, which led to hopeless discharge. There were no procedure-related mortalities or morbidity and graft-related infection.

Conclusion: Exclusion of AAA in patients with accompanying malignancy show with a relatively low procedure morbidity and mortality. So endoluminal AAA repair in patients with synchronous neoplasia may allow greater flexibility in the management of offending malignancy.

0073

The Effect of Steroid Therapy on Postoperative Inflammatory Response after Endovascular Abdominal Aortic Aneurysm Repair

Kazuto Maruta, Atsushi Aoki, Tadashi Omoto, Hirofumi Iizuka, Hiroyuki Kawaura

Showa University School of Medicine Cardiovascular Surgery,
Tokyo, Japan

Background: Unexpected systemic inflammatory response with high fever and increase in C-reactive protein (CRP) occurred frequently after endovascular abdominal aortic aneurysm repair (EVAR). This excessive inflammatory response affects on the postoperative course. We evaluated the effects of steroid on the postoperative inflammatory response after EVAR.

Methods: Steroid therapy, intravenous infusion of methylprednisolone 1000 mg at the beginning of the anesthesia induction, was introduced since December 2012. After induction of the steroid therapy, 20 patients underwent EVAR with steroid therapy (Group S). These patients were compared with the 20 patients underwent EVAR without steroid therapy from June 2012 to March 2014 (Group C). White blood cell count (WBC), CRP and maximum body temperature (BT) and number of patients who experienced of high fever (>38 degree) were compared between two groups from postoperative day (POD) 1 to POD 7.

Results: There was no significant difference in age, female gender, operation time, maximum aneurysm diameter and the frequency of unilateral internal iliac artery coil embolization. Although there was no difference in WBC between the two groups, CRP was significantly higher in Group C than Group S on POD 1 (Group C 2.40 ± 1.79 vs Group S 1.02 ± 0.82 , $P = 0.003$), and POD 3 (10.28 ± 5.25 vs 1.71 ± 1.59 , $p < 0.001$). BT was significantly higher in Group C than Group S on POD 1 (37.7 ± 0.6 vs 36.7 ± 0.4 , $p < 0.001$), POD 2 (37.9 ± 0.6 vs 36.9 ± 0.4 , $p < 0.001$), and POD 3 (37.6 ± 0.6 vs 37.1 ± 0.7 , $p = 0.024$). Furthermore significantly more patients experienced high fever (>38 degree) in Group C than Group S on POD 1 (Group C 7 patients vs Group S 0 patient, $P = 0.004$), POD 2 (7 vs 0, $P = 0.004$), and POD 3 (8 vs 1, $P = 0.008$).

Conclusions: Steroid pretreatment before implantation of the graft reduces the early postoperative inflammatory response after EVAR, without increasing postoperative infection.

0098

Successful Fenestrated EVAR to a Left Common Iliac Artery Aneurysm for a Living Kidney Transplantation Donor

Takao Miki¹, Norimasa Koike¹, Toru Takahashi¹, Jun Mohara¹, Kei Shibuya², Takashi Hachiya³, Izumi Takeyoshi¹

¹Department of Thoracic and Visceral Organ Surgery, Gunma University Graduate School of Medicine, Maebashi City, Japan

²Department of Diagnostic Radiology and Nuclear Medicine, Gunma University Graduate School of Medicine, Maebashi City, Japan

³Department of Cardiovascular Surgery, Saitama Cardiovascular and Respiratory Center, Saitama City, Japan

A 79-year-old male presented to our hospital for the treatment of a 30-mm diameter left common iliac artery aneurysm. He was the donor of a living kidney to be transplanted into his son. The aneurysm was discovered by his previous physician in a preoperative computed tomography (CT) scan. After repair of the aneurysm, the left nephrectomy procedure was planned using retroperitoneoscopy due to the risk of rupture during harvest surgery. Endovascular aneurysm repair (EVAR) was chosen over conventional graft replacement therapy to avoid dissection of adhesions for harvesting. Thin-slice CT revealed that the right kidney had double renal arteries, with the lower branch originating from the lower position of the abdominal aorta. It was thus necessary to protect right renal function after the left nephrectomy. Therefore, a homemade fenestrated stent graft was used to preserve the lower artery of the right kidney. Fenestrated EVAR, following the coil embolization to the left internal iliac artery, was completed and no visible endoleak was found in the final angiography of the procedure. On the fourth postoperative day, enhanced CT showed no endoleak, and blood flow of both right and left renal arteries, including the right lower branch, was maintained. In addition, the postoperative serum creatinine level remained within normal limits. With no major complications, the patient was discharged on the sixth postoperative day. Three months after the operation, the left nephrectomy and living kidney transplantation to his son was performed with safety. Six months after the operation, enhanced CT also showed no endoleak and dilatation of the aneurysm. Although serum creatinine level fell to 1.27, his daily life had almost no trouble. This case is a rare example of homemade fenestrated EVAR for a donor prior to living kidney transplantation.

The Experience of In Situ Antibiotic-soaked Graft Replacement with Omental Wrapping in Patients with Asymptomatic Aortic Graft Enteric Erosion

Shin-Seok Yang, Moonsang Ahn

Chungnam National University Hospital, Daejeon, Republic of Korea

Background: Aortic graft enteric erosion is a rare but potential life-threatening complication in patient who underwent aortic reconstruction with prosthetic graft. Varied approaches have been advocated for graft excision and repair of GI tract.

Case Report: A 72-year-old man presented with asymptomatic aortic graft enteric erosion on gastroduodenoscopy. He had a previous bypass graft due to aortoiliac occlusive disease with both leg claudication at 6 year ago. There was no abnormal finding in blood laboratory test except mild leukocytosis on complete blood count. Computed tomographic angiography confirmed an erosion of duodenal third portion and small amount of perigraft fluid collection. We performed partial excision of graft and primary repair of duodenum. To reconstruct the aorta, we used ripampin-soaked bifurcated Dacron graft for in situ graft replacement. After reconstruction of aorta, graft wrapping using omentum brought through the mesocolon was performed to prevent graft re-infection.

Although delayed passage at 3rd portion of duodenum was revealed on upper gastrointestinal series after 8-day of operation, there was no problem to start a liquid diet. The patient was discharge from the hospital after 1 month. Antibiotic was administered intravenously during hospitalization and oral antibiotic was prescribed for 2 month after discharge.

At 2 month of follow-up, the patient had no symptom and took a regular diet.

Conclusion: In situ antibiotic-soaked graft replacement with omental wrap is a surgical option for aortic graft enteric erosion without excessive perigraft purulence.

0104

Impact of Graft Composition on the Systemic Inflammatory Response after an Elective Repair of an Abdominal Aortic Aneurysm

Ju Yeon Lee¹, Jong Kwan Baek¹, Hyunwook Kwon¹, Gi-Young Ko¹, Youngjin Han¹, Young Soo Chung¹, Tae-Won Kwon¹, Yong-Pil Cho¹

¹University of Ulsan College of Medicine and Asan Medical Center, Seoul, Republic of Korea

²Pusan National University School of Medicine and Medical Research Institute, Pusan, Republic of Korea

³Ulsan University Hospital, Ulsan, Republic of Korea

Background: An acute phase systemic inflammatory response is relatively common following endovascular aneurysm repair (EVAR). Despite of its benign nature in most patients, true

clinical significance is unknown and no clear guidelines exist for management.

Methods: We evaluated retrospectively the risk factors and the role of graft material on an increased risk of developing systemic inflammatory response syndrome (SIRS) and the clinical outcome in patients undergoing an EVAR or open surgical repair (OSR) for an abdominal aortic aneurysm (AAA).

Results: A total of 308 consecutive patients undergoing an AAA repair at our institution were included in this study; 178 (57.8%) received EVAR and 130 (42.2%) OSR. The incidence of SIRS in patients undergoing OSR may be clinically significant ($p = 0.11$), and regardless of treatment modalities, SIRS was observed more frequently in patients treated with woven polyester graft (EVAR, $p = 0.00$; OSR, $p = 0.05$). Postoperative hospitalization was significantly prolonged in the patients experienced SIRS (EVAR, $p = 0.02$; OSR, $p = 0.02$). In multivariate analysis, the initial WBC count ($p = 0.001$) and the use of woven polyester graft ($p = 0.005$) were significantly associated with an increased risk of developing SIRS in patients undergoing EVAR, whereas the use of woven polyester graft remained the only significant factor associated with an increased risk of developing SIRS in patients undergoing OSR without a statistical significance ($p = 0.052$).

Conclusion: The current study shows that the graft composition plays a primordial role in the development of SIRS, and it leads to prolonged hospitalization in both EVAR and OSR patients.

0106

One Case that was Diagnosed with Aortic Aneurysm of IgG4-Related Disease 17 Years after the Pancreaticoduodenectomy

Hirokuni Ono, Syouta Kita, Hirotooshi Suzuki, Masahiro Sagane, Yuka Sakurai, Tokuchirou Nagata, Daijyun Ro, Kiyoshi Chiba, Makoto Ono, Yosuke Kitanaoka, Masahide Chikada, Hiroshi Nishimaki, Takeshi Miyairi

St. Marianna University of Medicine, Kanagawa, Kawasaki, Japan

Pathology could be called IgG4-related disease in vascular disease is present. For example, some of the disease called inflammatory aortic aneurysm is an IgG4-related disease is known. The inflammatory aortic aneurysm exists at 3–10% of the abdominal aortic aneurysm and an arteriosclerosis-related aortic aneurysm is same frequency. The patient was referred to our hospital in the expansion of abdominal aortic aneurysm in a 79-year-old man. Recognizing the contrast effect of the soft tissue of the aortic aneurysm surrounding in CT, was suspected inflammatory aneurysm. Coronary CT even admitted soft tissue thickening the surrounding of the coronary artery. When the suspected IgG4-related disease, was measured IgG4 concentration in blood, it was higher. In addition, when you have been made the pancreaticoduodenectomy and sialoadenectomy 17 years ago, was a re-examination of the pathological findings, that the pancreatic tumors and salivary gland is an IgG4-related disease has been found. Because there is a history of

abdominal surgery, was carried out in the treatment of EVAR for abdominal aortic aneurysm. Since it has also been reported for tissue thickening in the steroid to improve the possibility of aneurysm may explode with increased inflammatory aortic aneurysm of IgG4-related, EVRA was useful.

However, because the aorta can not be removed, there is also a drawback that pathological diagnosis can not be.

That because the lesion extends to multiple organs, it was treated with EVRA prior to performing the medical treatment of steroid was very useful IgG4 -related disease.

0107

An Idiopathic Congenital Abdominal Aortic Aneurysm with Impending Rupture in a 23-Month-Old Boy: two years follow-up

Hyunwook Kwon, Yong-Pil Cho, Seong Chul Kim, Tae-Won Kwon

Asan Medical Center, Seoul, Republic of Korea

Introduction: Abdominal aortic aneurysms are distinctly uncommon in infants and children, and these aneurysms of an idiopathic nature without any definite predisposing factors are exceedingly rare. we report an idiopathic congenital AAA with clinical manifestations caused by impending rupture in a 23-month-old boy.

Case report: A 23-month-old boy who had an uneventful antenatal and neonatal history was admitted to the hospital with a 1-day history of irritability, vomiting and poor oral intake. He was born by normal, full-term, spontaneous vaginal delivery to a 32-year-old mother. Contrast-enhanced axial computed tomography (CT) scan revealed a giant infra-renal AAA with impending rupture, measuring 8.4 cm in maximal diameter and 8.0 cm in length, to be 1.1 cm below the origin of the renal artery and extending 2.3 cm proximal to the aortic bifurcation. An emergency exploratory laparotomy revealed a giant infra-renal AAA with impending rupture, extended about 2.0 cm proximal to the aortic bifurcation. The diameter of the proximal, normal infra-renal aorta was 0.7 cm. After the aorta and both common iliac arteries were isolated and cross-clamped, the aneurysm was opened and repaired with an interposition 0.7 cm-sized cryopreserved adult cadaveric iliac artery from our tissue bank. A straight end-to-end anastomosis was performed using interrupted sutures with polypropylene 7-0. Histologic evaluation of the aorta revealed diffuse myxoid degeneration in the media without any evidence of vasculitis, suggestive of an uncharacterized congenital aortic degenerative change.

Conclusion: We present an idiopathic congenital AAA with impending rupture in a 23-month-old boy, successfully treated with surgical repair using a cryopreserved cadaveric allograft. Two years follow-up is completed with patency to both leg arteries and without any other complications.

0110

Risk Factors on Acute Kidney Injury (AKI) After Endovascular Aortic Aneurysm Repair (EVAR)

Koki Tabata, Kimihiro Komori, Kiyohito Yamamoto, Hiroshi Narita, Hiroshi Banno, Akio Kodama, Masayuki Sugimoto

Nagoya University Graduate School of Medicine, Nagoya, Japan

Background: AKI is an important complication after EVAR with the use of iodinated contrast media or catheters techniques.

Objective: The aim of this study is to evaluate the estimated glomerular filtration rate (eGFR) perioperative EVAR patients and we examined the risk factors of AKI.

Methods: The patients were divided into five groups based on chronic kidney disease (CKD), (G1; eGFR ≥ 90 ml/min/1.73 m², G2; $60 \leq$ eGFR < 90 , G3a; $45 \leq$ eGFR < 60 , G3b; $30 \leq$ eGFR < 45 , G4; eGFR < 30) classification. AKI was defined as an decrease in eGFR $> 25\%$ of the baseline within 7 days after EVAR.

Results: 370 patients (mean age, 77.9 ± 6.7 years) were included. The number of patients were 22 in G1, 150 in G2, 139 in G3a, 59 in G3b and 20 in G4. AKI occurred 30 patients (8.1%) (AKI group) and did not occur in 340 (91.9%) (non-AKI group). The mean dose of contrast agent (AKI group: 125 ± 47 ml vs non-AKI group: 107 ± 49 ml; $P = 0.044$) and the duration of the operative procedure (AKI group: 219 ± 88 min vs non-AKI group: 152 ± 50 min; $P < 0.001$) were significantly different between two groups. However, the age, preoperative eGFR, and the blood loss of the procedure were not significantly different between the groups. AKI was 0% in G1, 7.3% in G2, 10.9% in G3a, 8.5% in G3b, 5.0% in G4. One female patient of G3a received renal replacement in the hospitalization. The amount of the contrast medium in G4 patients is significantly smaller than that of other four groups. Ten patients (16.9%) in G3b and 15 patients (75%) in G4 received intravenous fluids before 12 hours and no patients did in G1, G2 and G3a group. **Conclusion:** The risk factors of AKI after EVAR were prolonged operation time and increased volume of the contrast medium.

0114

Retrospective Review of the Treatment Results of Middle Aortic Syndrome (MAS)

Seoung-Wook Choi, Young-Wook Kim, KI Sung, DI Kim, YS Do, DK Kim

Samsung Medical Center, Seoul, Republic of Korea

MAS is defined as clinical symptoms due to thoracic or abdominal aorta stenosis presenting as lower extremity (LE) ischemia, renal/mesenteric ischemia, and/or renovascular hypertension. In earlier life, it often attributed to congenital aortic coarctation while arteritis is a main cause of this medical condition. We attempted to review the clinical features and treatment results of MAS in a single institution. Between 1994 and 2014, database of the patients who were diagnosed as MAS were retrospectively reviewed.

Diagnosis of MAS was made on an aortogram image and clinical features. In patients with diffuse aortic lesion with heavy calcification were treated with open surgical repair (OSR) while short segment without heavy calcification were treated with endovascular treatment (ET). We investigated the demographic and clinical features, treatment procedures, and postoperative follow-up results. **Results:** During the past 20 years, 19 patients with MAS were detected. Underlying causes of the MAS were Takayasu's arteritis (TA) in 18 (95%) patients and 1 (5%) unknown-cause supra-renal aortic stenosis and heavy calcification combined with infrarenal AAA. Location of aortic stenosis distributed at the suprarenal abdominal aorta (n = 10, 53%), thoraco-abdominal aorta (n = 8, 42%) and descending thoracic aorta (n = 1, 5%). Clinical feature varies from hypertension (n = 17, 89%), LE claudication (n = 10, 53%), chronic renal insufficiency (n = 7, 37%) and abdominal pain or discomfort (n = 2, 11%). The treatments of MAS were 13 (68%) OSR, 6 (32%) ET and 1 medical treatment. 3 renal and 1 superior mesenteric artery reconstruction were performed as an adjuvant procedure. During the follow-up period (mean 64 months, 5~242 months), there was no mortality. Restenosis-free patency of the aorta were 84.2% during the follow-up period (p = 0.359). Graft occlusion developed in 1 (5%) patient in OSR group and 2 (11%) patients in ET resulting in graft patency 91% in OSR group and 100% in ET group. TA was the most common underlying pathology of MAS in adult patients. Treatment results were good after both OSR and ET.

0118

Abdominal Aortic Aneurysm in Giant Cell Aortitis: Case Report

Hyunwook Kwon, Youngjin Han, Yong-Pil Cho, Tae-Won Kwon

Asan Medical Center, Seoul, Republic of Korea

Introduction: GCA is rare but the most common cause of nonatheromatous aortic aneurysm. This report The case of a 57-year-old man who was referred to Asan Medical Center for infrarenal AAA with impending rupture sign was reviewed.

Results: The patients reported persistent low back pain in the last three weeks and aggravation of the abdominal pain in a period of a week. The initial vital sign was stable and the patient had no fever. Laboratory test showed elevated C-reactive protein (CRP) with 7.99 mg/dL and erythrocyte sedimentation rate with 51 mm/hr. Preoperative computed tomography (CT) scan showed the AAA measuring 8 cm extent from 5 cm distal to renal artery to aortic bifurcation with maximal diameter of 7.6 cm. Intraoperative inspection revealed ruptured AAA with infectious granulation tissue on the anterior wall with mural thrombosis. We performed complete excision of aneurysm and Y-graft interposition with GORE-TEX® graft. The graft was wrapped with omental flap. There was no microorganism was founded in blood and tissue culture. Histopathologic analysis of the resected aneurysmal sac reported focal, complete loss of the media in the elastic staining and extensive

perivascular fibrosis consisted of chronic inflammatory cells and occasional giant cell suggesting giant cell aortitis. The patient was discharged 9 day after surgery with unremarkable postoperative course. 15 months after the operation, CT scan demonstrated patent graft and distal run-off and no abnormal postoperative finding. **Conclusion:** The surgical and post operative treatment of nonatheromatous aortic aneurysm must be decided by accurate diagnosis. Open surgical procedures and adequate antibiotics according to cultures of aortic wall or blood is the standard treatment of infected aneurysm. On the other hand, if GCA is founded incidentally after aortic surgery, the patient needs investigation of remaining large and medium sized arteries and corticosteroid can be used to elicit acute symptoms of GCA.

0120

Midterm Outcome after Endovascular Abdominal Aortic Aneurysm Repair on Endurant® Stentgraft System

Kiyoshi Chiba¹, Hiroshi Nishimaki¹, Yukihiisa Ogawa², Hirotoshi Suzuki¹, Yuka Sakurai¹, Masanori Sagane¹, Ro Daijyun¹, Hirokuni Ono¹, Makoto Oono¹, Yousuke Kitataka¹, Masahide Chikada¹, Hiroyuki Abe¹, Takeshi Miyairi¹

¹Department of Cardiovascular Surgery, St. Marianna University School of Medicine, Kawasaki, Kanagawa, Japan

²Department of Radiology, St. Marianna University School of Medicine, Kawasaki, Kanagawa, Japan

Objective: Our study focuses on the midterm result of endovascular abdominal aortic aneurysm repair (EVAR) using the Endurant stentgraft system.

Patients and Methods: A total of 58 (male 46, female 12) patients underwent abdominal aortic aneurysm repair between November 2011 and March 2014. The average patient age was 74.4 ± 9.5 years (55~90 years). The pathology of aneurysm is true 57 (involved to common iliac artery aneurysm 11), impending rupture 1. The average diameter of aneurysm is 52 ± 11 mm (30~84 mm). The evaluation of criteria were endoleaks and the shrinkage of sac after 1 year after EVAR. And we evaluated an aneurysm related mortality and freedom from re-intervention rate using Kaplan-Meier method.

Results: Single EVAR were 42 cases, combined with endovascular treatment is percutaneous transluminal angioplasty were 10 cases, and iliac artery coil embolization were 14 cases. A primary success rate was 100% (58/58), and technical success rate was 98.3% (57/58). There were 5 cases of type II endoleak and 45 cases of type IV endoleak just after EVAR.

In 25 patients which could enforce imaging CT for postoperative one year, the rate of patients with shrinking greater than 5 mm or more was 48%, on average 9.1 ± 2.6 mm (6 to 13 mm). The rate of patients with no shrinking of sac was 52%, while no case show increase diameter. An aneurysm-related mortality is 0%, and freedom from re-intervention is 98.3% after 2 years after EVAR.

Conclusion: The mid term outcome of Endurant® is safe and satisfactory. This device has less type 2 endoleak than other company-related devices, and there is much type 4 endoleak.

In other words, it is predicted that type 2 endoleak is hard to rise because the internal pressure of aneurysms is relatively maintained highly.

0122

One Year Experience of Iliac Bifurcated Device for Aortoiliac Aneurysm in Korean Single Center

Kee Chun Hong¹, Hyun Jun Ahn¹, Keun-Myoung Park¹, Yong Sun Jeon², Soon Gu Cho², Tae Hyun Kong¹, Jung Taek Kim³, Pil Ho Han¹

¹Department of Surgery, Inha University Hospital, Incheon, Republic of Korea

²Department of Radiology, Inha University Hospital, Incheon, Republic of Korea

³Department of Cardiothoracic Surgery, Inha University Hospital, Incheon, Republic of Korea

Background and objectives: Iliac bifurcated device (IBD) is one of method for preservation of internal iliac artery (IIA) in aortoiliac aneurysm repair. But, IBD is still not covered by national insurance system in Korea. The aim of our study is to present the technical aspect and early result of Korean domestic IBD for aortoiliac aneurysm.

Methods: Since 2013, four IBDs were inserted for 4 patients in Inha University Hospital with mean follow up 6.3 months. All IBDs and stent grafts were made by S&G Biotech Inc. (Seongnam, Korea). Percutaneous technique instead of surgical cutdown was adopted in 3 out 4 cases. Contralateral internal iliac artery embolization were performed in 3 patients.

Results: The technical success rate was 100%. There were no morbidity or mortality in all case. Mean procedural time was 176 min (147–240 min). Mean contrast dose used was 184 cc (135–220 cc). Iliac embolizations were performed with Interlock coil (2 patients) and Amplatzer vascular plug (1 patient). Two IBDs were inserted into left IIAs and other two, into right. There was no endoleak in postoperative aortogram. And there was no complication related to IBD (limb occlusion or fracture) during followup period without expansion of aneurysm.

Conclusions: IBD is a safe method for endovascular repair of aortoiliac aneurysm for preservation of IIAs. But longer followup is required to assess the mid- or longterm result.

0132

Endovascular relining of Pergraft Seroma after open surgical repair of AAA

Jang Yong Kim, Kang-Woong Jun, Mi Hyoung Kim, Ji Il Kim, Sang Seob Yun, In Sung Moon, Sang Dong Kim, Sang Hyun Ahn, Sun Chul Park

The Catholic University of Korea, Seoul, Republic of Korea

Introduction: Perigraft seroma after open surgical repair of AAA was rarely reported. PTFE graft or patient hematologic characteristics are known to be risk factors. Many options for treatment have been reported: percutaneous drainage of seroma, opening of aneurysm sac and omental patching for drainage or surgical replacement of previous graft. Recently endovascular relining of graft has been reported as treatment of Perigraft seroma after open surgical repair of AAA.

Case: 65 year old men presented with 10 cm sized aneurysm sac 4 years after open surgical repair of AAA. The aneurysm was 5 cm in diameter at initial treatment and repaired with PTFE graft (18 mm–9 mm bifurcated graft). The patient had a history of Percutaneous coronary intervention and chronic renal failure (Cr 2.0). There was no infection sign in lab and PET CT. Endovascular relining was done with 23 mm EXcluder cuff and 11 mm*10 cm Viabahn under general anesthesia. The vascular access were done with preclose technique using two preclose. There was no postoperative complication. The patient is free of sac enlargement in 6 months's follow up.

0137

Successful Endovascular Repair in a Case of Infected Aortic Aneurysm

Won Yong Sung, Nam Woo Seok, Kim Mi Hyeong, Jun Kang Woong, Ahn Sang Hyun, Hwang Jeong Kye, Kim Sang Dong, Park Sun Cheol, Kim Jang Yong, Yun Sang Seob

Division of Vascular and Transplantation Surgery, Department of Surgery, The Catholic University of Korea School of Medicine, Seoul, Republic of Korea

Introduction: Infected aortic aneurysm (IAA) has a very poor prognosis because these aneurysms have a greater tendency to grow rapidly and to rupture. Conventional open surgical treatment is the gold standard but carries a high mortality due to the severe medical comorbidities, the magnitude of the surgery, and patient instability because of systemic sepsis or rupture. Endovascular aneurysm repair (EVAR) is a relative new and less invasive modality for IAA treatment, and offers some advantages in terms of reduced perioperative morbidity and mortality in high-risk patients. We report a successful EVAR case of IAA treatment.

Case presentation: A 69-year-old man visited our hospital with progressing low back pain for 1 month. We performed a CT angi-

ography which showed an irregularly lobulated saccular aneurysm arising from the posterior aspect of the distal abdominal aorta. We started antibiotic therapy, and checked a follow-up CT angiography at 9th hospital-day. Because of increased size of the aneurysm, an open surgical repair was tried but failed by the hardly calcified neck. One month later, the size of the aneurysm was increased more, we tried endovascular treatment with an unibody graft and cross-femoral bypass and achieved successful result. A pig-tail catheter was inserted into the sac of aneurysm for the purpose of drainage of infected material at 11th post-operative day. The size of the aneurysm was decreased at 1 month later. The patient discharged at 44th-post operative day because he got some troubles with pneumonia and dermatitis. The patient has no fever and no back pain during 2 months after discharge.

Conclusion: EVAR is a possible short-term management technique for IAA patients with high surgical risk.

0158

The Outcomes of Sac dimensions after EVAR and its predisposing factors—A Single Center retrospective study

Min-Hyun Kim, Tae-Seung Lee, Hong-Kyoung Shin, Sae-Lee Kim, In-Hye Moon, Hyung-Sup Park

Seoul National University Bundang Hospital, Seong-Nam, Gyeonggi-Do, Republic of Korea

Background and Purpose: With the relatively minimal invasiveness nature of the procedure, EVAR has gained widespread acceptance for the treatment of abdominal aortic aneurysms. However its long-term results are challenged by endoleaks, sac growth, and eventually reintervention, open surgery, or AAA ruptures. Many contributing factors have been published leading to the failure of EVAR including anatomical infavoriness, EVAR with implications outside the IFU (instructions for use), endoleak types, progressive nature of the disease, and so on. Proper analysis of these factors as well as proper measurements of the dimensions of the sac must be considered beforehand in order to ensure a better prognosis.

Methods and Results: A total of 55 patients undergoing elective EVAR in Seoul National University Bundang Hospital from Sept. 2007 to May 2013 were studied retrospectively. Their sac parameters before the surgery were measured along with the sac size in follow up imaging modalities (CTs). Each patient was accounted for immediate, mid-term, and (if possible) late endoleaks and the changes in the sac parameters. Of the 55 selected, 18 (33%) showed no or minimal change in sac size before or afterhand. Of those 18, 6 (33% or 11% of total) showed increase in sac size with followup studies. Type II endoleak was associated with 7 of the 18 cases, while type III and V were 2 and 1 cases respectively. Neck parameters and other factors were also compared between regressive and nonregressive groups.

Conclusion: With the relatively small population of analysis, the statistical power of this study was minimal. The cohort was also insufficient to do a multivariate analysis. However, the results are

in general agreement with the prior literatures and although are statistically weak, are in concordance with the general conception. Long-term follow up are to be further investigated.

0162

Successful endovascular repair for retrograde type A aortic dissection and abdominal aortic aneurysm with proximal neck dissection

Kenji Aoki, Takeshi Okamoto, Hiroki Sato, Yosuke Horii, Osamu Namura, Kazuhiko Hanzawa, Masanori Tsuchida

Niigata University, Niigata, Japan

Background: Endovascular repair for acute or subacute aortic dissection is challenging.

Methods: We experienced successful endovascular repair for acute aortic dissection and abdominal aortic aneurysm (AAA) with proximal neck dissection in the same patient.

Results: A 67 year-old man with infra-renal AAA of 6cm in diameter was transferred to our hospital for acute type A aortic dissection with an entry in the descending aorta. He immediately received endovascular entry closure with TAG (WL Gore, Flagstaff, AZ). In postoperative computed tomography (CT), the false lumen (FL) was thrombosed in the thoracic aorta but remained patent in the abdominal aorta including the proximal neck of AAA. A large re-entry in the iliac artery was a major source of blood flow into FL. He received endovascular aneurysm repair combined with re-entry closure by using Excluder (WL Gore) during the subacute phase of aortic dissection. The main body was chosen to be suitable to total cross-sectional area of the dissecting neck. FL or shrunk true lumen (TL) was not be referenced. Two weeks after the second intervention, CT showed completely thrombosed FL in the infra-renal aorta. No endoleaks were found in AAA. Three months after the onset, CT showed almost disappeared FL and relatively expanded TL in the thoracic aorta. Early remodeling effects were similarly found in the infra-renal aorta and AAA shrank significantly.

Conclusions: Dissecting aorta can be safely treated with endovascular techniques in acute and subacute phases with complex pathology. Early intervention seems to promote better remodeling. Careful device selection based on understanding of the pathology is very important for technical success.

Conservative Treatment of Spontaneous Abdominal Aortic Dissection

Byung Jun So, Dae Yong Kim, Jeong Byeong Kwon

Wonkwang University Hospital, Iksan, Jeonbuk, Republic of Korea

Spontaneous dissection of the abdominal aorta has been estimated to occur in 0.4% to 2% of all aortic dissections. Because of the rarity of the condition, appropriate management of this disease has not been well defined. We are going to report our recent experience with 5 patients who presented at our institution between February 2004 and June 2013.

Mean age of the 5 patients (2 men, 3 women) was 59 years (range, 48 to 66 years). Mean follow up duration was 5.5 years (range, 1yr to 10 years).

All the patients were presented with abdominal or back pain of less than 3 weeks' duration (Range, 1 to 21 days). All patients had hypertension, one had a history of smoking, and one received surgical treatment due to thoracic aorta dissection at 6 year ago prior to this event. Two patients had entry point at near renal artery and reentry point at the ostium of iliac artery. 3 patients have entry point only at iliac artery near bifurcation, and proximal extension of dissection were shown. The dissection was limited to the infrarenal aorta in 4 patients (80%), did extended into distal iliac artery without ischemic symptoms. We treated them with antihypertensive drug to keep the systolic blood pressure below 100 mmHg and with analgesic to control abdominal pain. Most patient was able to be discharged when they got a stable blood pressure and painless condition. Mean hospital stay was 16 days (range, 5 to 26). During the follow-up period, no patient complained of recurrent abdominal discomfort. Maximal aortic diameter at the dissection level was not changed (no aneurysmal changes).

Our data showed that spontaneous abdominal aortic dissection could be a mild disease if blood pressure can be controlled strictly.

Management of Type II Endoleak after Endovascular Repair of Arterio caval Fistula Complicating Aortoiliac Aneurysm: Case Report and Literature Review

Akhmadu Muradi^{1,2}, Masato Yamaguchi¹, Eisuke Ueshima¹, Takuya Okada¹, Koji Idoguchi¹, Yoshikatsu Nomura³, Yutaka Okita³, Koji Sugimoto¹

¹Center for Endovascular Therapy, Department of Radiology, Kobe University Hospital, Kobe, Japan

²Vascular and Endovascular Division, Department of Surgery, Ciptomangunkusumo Hospital, Faculty of Medicine University of Indonesia, Jakarta, Indonesia

³Cardiovascular Division, Department of Surgery, Kobe University Hospital, Kobe, Japan

Arterio caval fistula (ACF) is an uncommon complication of aneurysmal aortoiliac disease and may manifest a diverse array of symptoms leading to easily delayed diagnosis with subsequent poor outcomes. Endovascular treatment for ACF has now become the preferred attractive alternative to open repair. However, endoleaks sometimes occur and maintain the ACF. Herein, we present the case of a 64-years-old man with persistent fistula after bifurcated stent-graft placement for ACF complicating aortoiliac aneurysm that was maintained by endoleaks from inferior mesenteric and lumbar arteries. Transarterial sac and inferior mesenteric artery embolization successfully resolved the problem without any complications observed within sixteen months follow up. Literature review revealed fifteen cases of type II endoleaks associated with aorto or ilio caval fistulas which had been treated with conservative, open and endovascular approaches. Two of seven cases treated with endovascular techniques failed, resulting in technical and success rate of 71% after mean follow up period of sixteen months. Combination of inflow and outflow control is important to get better long-term outcomes.

Keywords: persistent arterio caval fistula, aortoiliac aneurysm, endoleak, transarterial embolization

(B) Carotid Disease

Endovascular Repair of Giant Iatrogenic Common Carotid Artery Pseudoaneurysm

Yuk Law, Yiu Che Chan, Stephen Wing Keung Cheng

Queen Mary Hospital, The University of Hong Kong, Hong Kong, Hong Kong

Delayed presentation of carotid artery pseudoaneurysm following many years after self-inflicted penetrating injury of the neck is extremely rare. Open surgical carotid repair may involve sternot-

omy for proximal vascular control. Endovascular treatment is a less-invasive treatment option. We report a fifty-five years' old gentleman with history of paranoid schizophrenic who presented with a progressively enlarging left sided neck mass many years after attempted suicide. CT scan confirmed a 6 cm pseudoaneurysm arising from the common carotid artery, and this was successfully treated with endovascular stentgraft.

0095

Clinical features and outcomes of carotid endarterectomy after carotid artery stenting

Ju Yeon Lee, Jae Hyun Kwon, YoungJin Han, Ji-Yun Choi, Yong-Pil Cho, Tae-Won Kwon

University of Ulsan College of Medicine and Asan Medical Center, Seoul, Republic of Korea

Background: Carotid artery stenting (CAS) is now constantly increasing for treatment of carotid artery stenosis and prevention of stroke as alternative to carotid endarterectomy (CEA). With widespread use of CAS, we can expect that complications of CAS such as in-stent restenosis (ISR) will proportionally increase. In this article, we presented our experience of four cases of CEA after CAS at a single academic institute, with review of literatures for management and clinical outcomes of ISR.

Methods: From 1996 to 2013, we retrospectively review the medical records and imaging studies of patients who underwent CEA after CAS at our institution.

Results: From 1995 to 2013, there were four male patients who received CEA after CAS. The mean age of the four patients at CAS was 64 (± 6.5) years old. The mean time interval between CAS and CEA was 30.8(± 24.8) months. In all four cases, stent was successfully removed. In three cases, standard CEA was performed and in one case, partial resection of CCA and ICA with stent and pseudoaneurysm was done. The mean operative time was 279.8 (± 40.8) minutes. No neurologic or major complication occurred after surgery. All four patients remained neurologically asymptomatic over a mean follow-up time of 43.5 (± 17.5) months.

Conclusions: Surgical treatment for ISR or pseudoaneurysm after CAS appears to be feasible and beneficial to patients.

0163

Iatrogenic Giant Pseudoaneurysm of Right Common Carotid Artery in a Case with Multiple Co-morbidities

Ali Gurbuz, Orhan Gokalp, Ismail Yurekli, Ufuk Yetkin, Nagihan Karahan, Filiz Kiliccioglu

Izmir Katip Celebi University Ataturk Training and Research Hospital, Department of Cardiovascular Surgery, Izmir, Turkey

Pseudoaneurysm is a sequel of the arterial wall injury. It may be seen in every segment of the common-, internal- and external carotid arteries.

Our case was a 59-year-old female. She was suffering from a growing pulsatile cystic mass on her neck developed after central venous catheterization for hemodialysis access at another institution for 6 months. Colored Doppler ultrasound confirmed a giant pseudoaneurysm (PSA). Magnetic resonance (MR) angiography showed a pseudoaneurysm of 10 cm in diameter originating from inferior portion of right common carotid artery (CCA) with a 2-mm defect size. Her echocardiography revealed moderate mitral and tricuspid valve insufficiency with a left ventricular ejection fraction of 35% and pulmonary arterial pressure of 80 mm Hg.

She was taken into operating room with a possible diagnosis of giant pseudoaneurysm of right CCA developed as a complication of central venous catheterization. After crossclamping of the above-mentioned arteries the sac was opened. A large amount of organized thrombus material was removed. A 5-mm orifice was detected on CCA. This orifice was closed using 6/0 polypropylene suture in an over-and-over fashion. After extirpation of the whole sac content, the remaining pouch was quite large and Department of Plastic and Reconstructive Surgery was invited to the operating room. They performed the capitonage of the surrounding muscular structures into the pouch. Postoperative early and long-term follow-up was asymptomatic.

Carotid arterial pseudoaneurysms should be treated either surgically or endovascularly due to the risk of neuropathy, rupture and massive bleeding, embolization and stroke. The main purpose of the treatment is the exclusion of the pseudoaneurysm and restoration of the continuity of the intravascular blood flow.

0168

Is Digital Subtraction Angiography of Carotid Artery a Gold Standard Examination Technique in Patients with Serious Left Main Coronary Artery Lesion?

Ufuk Yetkin, Koksai Donmez, Ali Gurbuz

Department of Cardiovascular Surgery, Katip Celebi University Izmir Ataturk Training and Research Hospital, Izmir, Turkey

Digital subtraction angiography of carotid artery is still a gold standard method for surgical decision when compared to less invasive new developed methods.

Our case was a 78 years old male patient. He had coronary and lower extremity angiography in a different country, which had revealed a 90% stenosis in left main coronary artery (LMCA) and 70% short segment stenosis in bilateral iliac arteries. Patient was hospitalized for surgery. Due to serious LMCA lesion and being older than 60 years old, routine carotid artery Doppler ultrasonography was performed preoperatively. A 50–69% stenosis in right internal carotid artery and 70–90% stenosis in left internal carotid artery were revealed. Magnetic resonance imaging was performed for further investigation. Both carotid arteries were reported as free of stenosis. Only an atheromatous plaque in beginning of right internal carotid artery was reported as “impossible to correctly

evaluate” due to suboptimal quality of technique and control Doppler ultrasonography was suggested.

Selective arcus aortography and bilateral carotid artery digital subtraction angiography was planned for exact diagnosis in our patient with serious LMCA lesion. This investigation proved 60% stenosis in iliac arteries. Heavily calcified atheromatous plaque, which was causing a stenosis lesser than 30%, was observed in origin of right internal carotid artery. In addition, wall irregularities were observed due to generalized atheromatous plaques in left main carotid artery. There was not any stenosis in left internal carotid artery. Patient underwent coronary artery bypass grafting surgery. Patient was screened with cerebral pulse oximetry in operating room. Patient recovered uneventfully.

Digital subtraction angiography of carotid artery is gold standard method, for proving non-invasive examination methods, in senile patients with serious left main coronary artery disease. This technique is especially important when surgical interventions may cause additional morbidities and proving exact diagnosis.

(C) Chinese Paper

0224

Management of Hemodialysis Associated Left Innominate Vein Compression Syndrome

Ya-Xue Shi¹, Wei Liang¹, Hao Zhang¹, Yi-Ping Zhou¹, Meng Ye¹, Jie-Jun Cheng², Xiang-Jiang Guo¹, Ji-Wei Zhang¹

¹Department of Vascular Surgery, Ren Ji Hospital, School of Medicine, Shanghai Jiao Tong University, Shanghai, China

²Department of Radiology, Ren Ji Hospital, School of Medicine, Shanghai Jiao Tong University, Shanghai, China

Background: Central venous stenosis or obstruction (CVD) is a serious complication and challenge in hemodialysis patients and results in venous hypertension. Although rare, CVD may also develop without a history of previous central venous catheterization. Recently, the anatomical compression of the left innominate vein by the aorta or its branches behind the sternum was considered as an important cause of the left innominate vein stenosis and the collaterals can not compensate the high flow of the ipsilateral vascular access and leads to the CVD. Due to the similarity to the iliac vein compression syndrome, we called it hemodialysis associated left innominate vein compression syndrome. The aim of this study was to summarize the outcome of management of this syndrome in our center.

Methods: The outcome of the management of hemodialysis associated left innominate vein compression syndrome were evaluated retrospectively. From July 2006 to December 2013, eighteen hemodialysis cases with venous hypertension symptoms were confirmed as left innominate vein compression syndrome by multidetector computed tomography (MDCT), 11 males and 7 females (mean age: 60.94 ± 12.49 years old) with ipsilateral access (mean access time: 45.94 ± 42.93 months). Patients were treated with

conservative therapy ($n = 3$), closure the access ($n = 6$), or endovascular therapy ($n = 9$).

Results: In conservative group with mild symptoms, the longest follow-up time was 16 months, and the symptoms did not further aggravate. All symptoms immediately resolved after closure the access but need establishing a new access on the other upper extremity. In endovascular group, there was one technique failure. Percutaneous transluminal angioplasty (PTA) was conducted in two cases and primary patency was found at 4 and 5 months, respectively. Stent placement had an acceptable primary assisted patency during the follow-up (mean: 20 ± 11.76 months, 7–39 months).

Conclusions: Stent placement is the first choice for the management of hemodialysis associated left innominate vein compression syndrome.

0226

The Short and Mid-term Results of Self-expanding Nitinol Stents for Treatment of Popliteal Arteries Following Suboptimal Balloon Angioplasty

Wei Liang, Peng Wang

Dept. Vascular Surgery, Renji Hospital, School of Medicine, Shanghai Jiaotong University, Shanghai, China

Purposes: To evaluate the short and mid-term results of popliteal artery nitinol stents.

Method: Retrospective study of 51 atherosclerotic popliteal occlusion cases with provisional stent after suboptimal PTA from Dec. 2011 to Jan. 2014.

Results: 1. Technical success rate was 100%. 2. ABI increased significantly from 0.4 ± 0.3 to 0.88 ± 0.11 immediately after procedure ($p < 0.05$). 3. Rutherford Class decreased significantly from 4.63 ± 1.11 to 2.10 ± 0.54 immediately after procedure ($p < 0.05$). 4. The primary patency rates of stents were more than 80% before 6M and less than 60% after 10M. 5. The secondary patency rate was more than 80% after 25M. 6. Stent distal location of P2 was negatively influence of primary patency.

Conclusions: Popliteal standard nitinol stent placement is a reasonable option in CLI patients with suboptimal angioplasty.

0233

Crossover Chimney Technique to Preserve the Internal Iliac Artery in a Ruptured Aortic Dissection Aneurysm with Bilateral Iliac Entry Tears 10 Years after Tevar

Wei-wei Wu, Wei Ye, Su-rong Hua, Chang-wei Liu

Department of Vascular Surgery, Peking Union Medical College Hospital, Beijing, China

The natural history of the aortic growth after thoracic endovascular aortic repair (TEVAR) in Stanford B aortic dissection remains

unclear. We reported a rare case developing a huge aortic dissection aneurysm 10 years after the primary TEVAR which ruptured before admission. The aortography showed multiple distal intimal entry tears locating above and at the origin of the celiac artery, the origin of the right internal iliac artery (IIA) and the end of the left common iliac artery (CIA). The maximum size of the ruptured dissection aneurysm was 137 mm × 97 mm below the renal arteries. The true lumen was compressed and the size of which at the aortic bifurcation was only 8 × 15 mm. Cerebrospinal fluid (CSF) drainage was placed before the procedure to prevent paraplegia. After the exposure of the bilateral common femoral arteries (CFAs), a thoracic stent-graft was deployed above the superior mesenteric artery. The origin of the left IIA was embolized with coils. A crossover sheath was inserted from the right CFA to the left IIA. A Viabahn stent-graft was positioned 2 cm inside the IIA. A unibody bifurcated abdominal stent-graft was deployed below the renal arteries. Limb extensions were positioned to bilateral external iliac arteries (EIAs). After the Viabahn deployment, a self-expandable nitinol stent was deployed overlapping inside the Viabahn, landing in the right EIA and 2 mm distal to the right limb extension. Complete angiography showed there was no endoleak from the IIA or the chimney graft gutter, the false lumen was totally excluded, and the chimney graft to the left IIA was patent. The CSF drainage was removed 48 hours after the procedure and the patient recovered uneventfully. He was discharged with aspirin antiplatelet. The computed tomographic angiography 6 months after the procedure demonstrated a total thrombosis of the false lumen, the patency of all grafts and a good accommodation of the crossover chimney graft with the right iliac limb extension. Our experience showed that type B dissection may develop ruptured aortic dissection aneurysm long time after TEVAR. The multiple entry tears may be troublesome during the reintervention, however the crossover chimney technique may help preserve the IIA flow in case with bilateral iliac entry tears.

0239

Endovascular Treatment for Extrahepatic Portal Vein Bifurcation Stenosis after a Whipple Procedure Using the Kissing Stents Technique

Wen-Guang Zhang, Zhen Li, Zhong-Gao Wang

Department of Endovascular, the First Affiliated Hospital of Zhengzhou University, Zhengzhou, China

A 57-year-old man presented with a rare extrahepatic portal vein bifurcation scar stenosis involving the proximal splenic vein and superior mesenteric vein after a Whipple procedure. He was treated with endovascular coil embolization for the gastroesophageal varices and kissing stents for the portal vein bifurcation stenosis. This case illustrates a rarely seen complication after the Whipple procedure and a novel management strategy that can be considered in the management of this complex disease.

0240

Endovascular Treatment of an Unusual Primary Arterioportal Fistula Complicated by Cavernous Transformation of the Portal Vein Caused by Portal Thrombosis

Wen-Guang Zhang, Zhen Li, Zhong-Gao Wang

Department of Endovascular, the First Affiliated Hospital of Zhengzhou University, Zhengzhou, China

We describe an elderly woman who presented with an unusual primary arterioportal fistula and cavernous transformation of the portal vein caused by portal thrombosis, which were subsequently managed with endovascular coil embolization and transjugular intrahepatic portosystemic shunt using 2 stents after balloon remodeling. This case shows a rarely seen condition in the elderly and a novel management strategy that should be considered in the management of this complex disease.

0249

Inhibition of Experimental Neointimal Hyperplasia by Novel Helical Stent in Porcine Model

Jia-ning Yue, Jin-sheng Li, Wei-guo Fu, Yu-qi Wang

Department of Vascular Surgery, Zhongshan Hospital, Fudan University, Shanghai, China

Background: A bio-mimic helical endovascular stent has been developed and reported a positive outcome in a pilot clinical study. The purpose of our study was to observe neointimal formation and hemodynamics after implantation of the novel helical stent in comparison with a straight stent in a porcine model.

Methods: One helical stent and one controlled straight stent, were separately implanted into both carotid arteries of 14 pigs. Each animal was used as its own self-control, comparing helical stents to straight stents in the quantitative angiographic measurements, duplex-estimated wall shear stress (WSS), and quantitative histomorphometry in 30 days.

Results: At angiographic follow-ups, a spiral blood flow was confirmed in the helical stents; and the average lumen diameter stents was significantly higher in the helical ($P = 0.001$). The WSS was decreased by either helical or straight designs, but helical stent demonstrated a higher WSS, especially in the first half of the stent ($p < 0.05$ at proximal and middle, $p = 0.08$ at the distal). Histomorphometry indicated no difference in injury scores between the two stents. The cross-sectional neointimal areas for helical stents were markedly reduced, as compared to straight stents; and the percentage of in-stent stenosis was shown significant difference between stent designs (from proximal, middle to distal, each $p < 0.05$).

Conclusions: The helical stent design has the characteristics to mimic a physiological-type swirling flow and to optimize the in-stent WSS. This technique appears to inhibit neointimal hyperplasia

and preserve luminal patency, which may be an attractive choice to prevent in-stent stenosis in peripheral interventions.

0252

Percutaneous Transluminal Angioplasty for Atypical Thromboangiitis Obliterans in Arteries Above the Knee

Lianxi Yuan, Junmin Bao

Vascular Surgery Department, Shanghai Changhai Hospital, Shanghai, China

Objective: This study was designed to retrospectively investigate whether percutaneous transluminal angioplasty (PTA) is efficacious and safe for the treatment of atypical thromboangiitis obliterans (ATAO) in arteries with occlusion of long segments.

Methods: From January 2011 to July 2013, 9 consecutive male patients with ATAO involving the external iliac and superficial femoral arteries were treated by PTA alone, without stent placement. Their mean age was 35 years (range, 24–47 years). Preoperative symptoms included severe claudication (n = 2), ischemic pain at rest (n = 4), and ischemic ulcers (n = 3). No any infrapopliteal interventions were performed besides the proximal intervention.

Results: Technical success using PTA was achieved in 100% of cases with occluded arteries, and there were no periprocedural complications. Clinical improvement was observed postoperatively with a significant improvement in Rutherford categories (range, 2–3) and significantly increased ankle-brachial indexes, from 0.59 ± 0.14 to 0.91 ± 0.17 ($p < 0.01$). Ischemic ulcers in three patients healed 3–5 months postoperatively. No recurrent ischemic ulcer was observed, and no amputation was performed in these patients. At follow-up examination (average, 20.9 months), restenosis of the superficial femoral artery was diagnosed in only one patient who continued with a conservative medication regimen and refused additional interventional treatment because his physical symptoms were minor.

Conclusion: PTA might be feasible and safe for the treatment of ATAO patients, and appears to provide positive clinical results at an average follow-up of 20.9 months.

0253

Endovascular Therapy for Long-segment Atherosclerotic Aortoiliac Occlusion

Lianxi Yuan, Junmin Bao

Vascular Surgery Department, Shanghai Changhai Hospital, Shanghai, China

Objective: This retrospective nonrandomized study investigated the outcomes of endovascular therapy for long-segment atherosclerotic aortoiliac occlusion.

Methods: From May 2008 to January 2013, 20 patients (one woman and 19 men; mean age, 66.1 years; range, 43–89 years) underwent stent implantation, with or without catheter-directed thrombolysis (CDT), for long-segment aortoiliac occlusion (>10 mm).

Results: The technical success rate was 95% (19 of 20). No in-hospital mortality was recorded. Aortic thrombus was successfully eliminated with CDT in four patients before percutaneous transluminal angioplasty (PTA) and stenting. Retroperitoneal hemorrhage occurred in one patient, who refused further endovascular surgery. Another 15 patients were treated with PTA and stenting. Postoperative ankle-brachial indexes increased significantly from preoperative values ($P < .05$). Seventeen patients showed clinical improvement from baseline by an average of 2.5 Rutherford categories. The mean follow-up interval was 17.6 months (range, 4–39 months). The primary patency rates were $93.3\% \pm 6.4\%$ at 6 months, $83\% \pm 11.3\%$ at 18 months, and $66.4\% \pm 17.4\%$ at 24 months.

Conclusions: Through brachial and femoral artery puncture, PTA, stenting, and CDT, endovascular therapy is feasible for complete long-segment infrarenal aortic occlusion, with lower complication rates and favorable midterm patency.

0256

Differential Expressions of microRNA between Young and Senescent Endothelial Cells

Henghui Yin, Junbin Zhang, Peng Chen, XiaoNan Zhu, JinSong Wang

Department of Vascular Surgery, The First Affiliated Hospital of Sun Yat-sen University, Guangzhou, China

Objective: To explore the differential expressions of microRNA (miRNA) between young and senescent endothelial cells.

Methods: Young and senescent aorta endothelial cells (EC) were isolated and cultured in young and old male C57BL/6J mice. Immunostaining of VIII factor was performed to identify the endothelial cells. The method of diphenyl tetrazolium bromide (MTT) was employed to compare the cell growth. Microarray was used to detect the differential expression of microRNA between young and senescent endothelial cells and the microarray results were confirmed by real-time polymerase chain reaction (PCR). The expression of endothelial nitric oxide synthase (eNOS) was detected by Western blot.

Results: Primarily cultured endothelial cells were confirmed by the VIII immunostaining factor. Senescent ECs grew more rapidly than young ECs in lower serum ex vivo. Excluding gender difference, miR-135a, miR-182, miR-96, miR-31, miR-126-3p and miR-362-5p were up-regulated over 2 folds in young ECs, and miR-335-3p and miR-335-5p up-regulated over 2 folds in senescent ECs by miRNA microarray and RT-PCR. The up-regulation of miR335-3p in old ECs and the up-regulation of miR-135a, miR-96 in the young ECs might contribute to a lower expression of eNOS in senescent ECs.

Conclusion: The expression of miRNAs changes with advancing age and may result in differential expressions of downstream genes.

Drug Impact on In-stent Restenosis after Percutaneous Transluminal Angioplasty in Peripheral Arterial Disease

Dan Liu, Zhong Chen, Xiao-bin Tang

Beijing Anzhen Hospital Affiliated to Capital Medical University, Beijing, China

Objective: To evaluate the impact of sarpogrelate on the in-stent restenosis (ISR) after percutaneous transluminal angioplasty (PTA) in peripheral arterial disease (PAD).

Methods: Assigned PAD patients who had PTA for the first time to two groups, which were given clopidogrel and aspirin (clopidogrel group) or sarpogrelate and aspirin (sarpogrelate group). All patients are examined by vascular ultrasonography at 6 months after PTA to evaluate the situation of ISR.

Results: 62 patients finished the follow-up visits as required. The diameter stenosis in the sarpogrelate group and clopidogrel group was 7.0% vs. 18.1% ($p = 0.036$), the peak systolic velocity ratio was 1.34 vs. 2.08 ($p = 0.010$) and the cases of ISR was 1 vs. 10 ($p = 0.005$) respectively. All patients were not observed serious adverse events.

Conclusions: Sarpogrelate combined with aspirin is safe and effective. Compare with clopidogrel and aspirin, sarpogrelate and aspirin can significantly reduce the rate of ISR after PTA and the intimal proliferation in the stent.

0259

EPCs Relieve Lower Extremity Ischemia by Paracrine Factors Through VEGF Pathway

Yaoguo Yang, Zhong Chen, lei Kou, Tengfei Zhang, Sheng Wang, Yanwen Qin

The Department of Vascular Surgery, Beijing Anzhen Hospital, Capital Medical University, Beijing, China

Endothelial progenitor cell (EPCs) can promote vascular regeneration, relieve Lower extremity ischemia. Currently, mainstream view suggests that EPCs play a role in part in vascular regeneration through employing paracrine factors to activate vascular endothelial cell or directly transferring to vascular endothelial cell, however, which mechanism being dominant is not clear. In our research, through employing ^{60}Co radiation to block the proliferation of EPCs cells, we explore the possibility that EPCs contribute to vascular regeneration by deploying paracrine factors to activate vascular endothelial cell. We performed magnetic activated cell sorting method to get EPCs cells from mouse bone-marrow, identified the surface markers, CD133+ and CD34+ by flow cytometry. Furthermore, checked whether the EPCs cells are still able to paracrine cytokines after blocking the proliferation of EPCs cells by exposing them under ^{60}Co ; as well as detected that whether the cytokines, that

secreted from deploying cell culture supernate stimulating vascular endothelial cell, was able to activate vascular endothelial cells. Meanwhile, observed the relieving lower extremity ischemia difference between normal EPCs cells and EPCs cells exposed by ^{60}Co after transplantation of these EPCs cells into Mouse Hindlimb Ischemia, respectively. The Epc cells from mouse bone-marrow were obtained by CD34 Micro Bead Kit, the surface markers of (89.8%), CD34 (80.5%), and negative for CD31 (14.8%) were identified by flow cytometry. Cell proliferation of Epc cells was inhibited when exposure dose of ^{60}Co radiation reached 15Gy, however, there is no significant effect on its Paracrine $P > 0.05$, cell culture supernate from EPCs cells exposed by ^{60}Co radiation was also capable of activating vascular endothelial cells as normal EPCs cells. EPCs exposed by ^{60}Co radiation or not can significantly improve blood flow of lower limbs ($P < 0.05$) after transplanted into Mouse Hindlimb Ischemia, it showed that EPCs play the role in vascular regeneration mainly through paracrine to activate vascular endothelial cell.

0263

Endovascular Treatment of Long Femoro-popliteal Arterial Occlusions Disease of Lower Extremities

Sheng Guan, Xiao-hu Ge, Qing-bo Fang, Hao Ren, Li-Mujian A

Department of Vascular Center, People's Hospital of Xinjiang Uigur Autonomous Region, Urumchi, China

Objective: To explore the feasibility and outcome of percutaneous transluminal angioplasty (PTA) as a primary treatment modality for long-segment lesions of the long femoro-popliteal arterial occlusions in critical limb ischemia.

Methods: Patients with 46 lesions in their femoro-popliteal arterial occlusions were treated with PTA, the symptoms, intraoperative and postoperative DSA characteristics were retrospectively analyzed. Short-term follow-up were obtained in 8 cases.

Results: The technical success rate related to procedure were 90% and 12 stents were placed after femoro-popliteal arterial occlusions PTA. One case was suffered from amputation due to development of compartment syndrome. The primary patency rate and recurrence rate of 12 months after procedure were 70% and 20% respectively.

Conclusion: Patients with critical limb ischemia could be benefited from PTA in long femoro-popliteal arterial occlusions.

Noninvasive pressure monitoring systems in EVAR surgery

Jie Liu, Xin Jia, Wei Guo

Department of Vascular Surgery, Chinese PLA General Hospital, Beijing, China

The Experience of Diagnosis and Treatment of Traumatic Popliteal Artery Injury

Hong-bo Ci, Hao Ren, Qing-bo Fang, Jia Re Ke Tang, Bing Zhu, Guang-lei Tian, Sheng Guan, Xiao-hu Ge

Division of Vascular Surgery, The people's Hospital of Xinjiang Uigur Autonomous Region, Urumchi, China

Objective: To investigate the diagnosis, operation and management of complications of traumatic popliteal artery injury.

Methods: A retrospective analysis was carried out in which 28 patients of traumatic popliteal artery injury from Jan 2008 to Dec 2013. The management was according to the type of popliteal artery injuries including end-end anastomosis in 5 cases, vein graft in 21 cases, popliteal artery repair in 1 case and underwent endovascular therapy in 1 case.

Results: There was no one dead in this study, 9 cases with osteofascial compartment syndrome received prompt open decompression, 6 cases received amputation in follow-up.

Conclusions: The key of reduce amputation rate including timely diagnosis, reconstruct blood flow and prevent complication.

In-Hospital Efficacy of Endovascular Aortic Repair in Patients with Impending Rupture versus Contained Rupture of Abdominal Aortic Aneurysms

Jiang Xiong, Wei Guo, Xiaoping Liu, Lijun Wang, Xin Jia, Xiaohui Ma, Hongpeng Zhang, Tao Zhang

Department of Vascular Surgery, Clinical Division of Surgery, Chinese PLA General Hospital and Postgraduate Medical School, Beijing, China

Background: The purpose of our study was to compare the efficacy of endovascular aortic repair (EVAR) in patients with impending rupture of abdominal aortic aneurysm (IRAAA) versus contained rupture of abdominal aortic aneurysm (CRAAA).

Methods: Of the 21 patients who underwent EVAR for infrarenal AAA from January 2009 to May 2011, 11 did so for IRAAA and 10 for CRAAA. We compared their demographic and aneurysmal

characteristics, comorbidities, complications, and clinical outcomes during hospitalization.

Results: The CRAAA group was younger than the IRAAA group. There were no group differences in AAA size, operation time, volume of contrast agent, length of hospital stay (LOHS), or preoperative LOHS. A small difference in mean intraoperative blood loss of w4 mL was noted, but was recognized as clinically insignificant. ICU stay and postoperative LOHS were greater in the CRAAA than in the IRAAA. One patient in the IRAAA group had a mild headache after EVAR. Four patients in the CRAAA group had postoperative complications: 1 had acute renal dysfunction; 1 had retroperitoneal infection; 1 had respiratory failure and myocardial infarction; and 1 died of respiratory tract infection and respiratory and cardiac failure.

Conclusions: Patients undergoing EVAR for CRAAA have a higher incidence of postprocedural severe complications and death than patients undergoing EVAR for IRAAA.

Experience of surgical treatment in 58 patients with complicated carotid body tumor (CBT)

Guojun Zeng, Jichu Zhao, Yukui Ma, Bin Huang, Ding Yuan, Yi Yang, Fei Xiong, Xiyang Chen, Tiehao Wang, Zhoupeng Wu, Yiren Liu, Hailong Luo, Han Luo

Division of Vascular Surgery, West China Hospital, Sichuan University, Sichuan, China

Objective: To summarize the experience of surgical treatment in 58 patients with complicated carotid body tumor (CBT).

Methods: Clinical data in 58 with complicated CBTs among 85 CBTs patients were analyzed retrospectively in the recent ten years. Complicated CBT was defined as larger than 5 cm, type Shamblin III, vascular involvement, failure history of operation, with neuroendocrine activity and bilateral CBTs.

Results: All CBTs were excised successfully and confirmed with biopsy. 32 cases were found larger than 5 cm, 56 belong to type Shamblin III, 9 vascular involvements, 4 with failure history of operation, 6 with neuroendocrine activity and 5 bilateral CBTs. In operation, shunts were used in 11 patients and revascularizations were performed in 13 patients (12 autogenous saphenous veins and 1 carotid internal artery). For 5 bilateral CBTs, just excision of larger tumor was performed in 1 case and excision of bilateral tumors in 4 patients (excision in one stage in one patient and two staged resection for 3 patients). 6 patients with neuroendocrine activity underwent operations successfully after careful preparation. There was no relapse or serious complication in follow-up.

Conclusion: Preoperative careful preparation and assessment are very important for complicated CBT. According to the situation of tumor, various methods such as shunt and revascularizations can be used to ensure the safety of patient and successful resection of tumor.

Advancement of Researches on Correlation between Dyslipidemia and Aortic Aneurysm

Ren Wei^{1,2}, Wei Guo¹

¹Department of Vascular Surgery, General Hospital of People's Liberation Army, Beijing, China

²Medical College of Nankai University, Tianjin, China

Objective: To review the studies on correlation between dyslipidemia and aortic aneurysm.

Methods: Literatures concerning blood lipid and aortic aneurysm were consulted and summarized from three aspects: overview of blood lipid, evidence-based data and the related basic mechanism research.

Results: The correlation between dyslipidemia and aortic aneurysm did not come to an consistent conclusion, no matter whether from epidemiological investigations on large scale of the crowd or from the clinical studies. Nevertheless, basic mechanism researches showed that dyslipidemia could affect aortic artery through damaging the endothelium, developing atherosclerosis, and promoting inflammation, etc.

Conclusion: The direct correlation between dyslipidemia and aortic aneurysm has not yet be made sure, and more and more pointed clinical researches and population investigations need to be carried out to answer the question.

A New Type of Endoleak after EVAR Induced by Stanford B Aortic Dissection and its Treatment

Jie Liu, Xin Jia, Wei Guo

Department of Vascular Surgery Chinese PLA General Hospital, Beijing, China

Background and Objectives: EVAR aims at prevention of aneurysm rupture. However, endoleaks are the Achilles heel of EVAR. Endoleaks have been categorized and subcategorized according to the location of the inflow into five types, but there may be other types of endoleak. We aim to describe a case of a new type of endoleak after EVAR induced by Stanford B aortic dissection and its treatment.

Methods: An 80-year-old man was admitted to the emergency room with abdominal and lumbar pain. The patient's history included cardiopathy, hypertension, dyslipidemia, and chronic renal insufficiency. The patient did EVAR 28 months ago due to AAA and did TEVAR 4 months ago due to Stanford B aortic dissection. An emergency CTA showed an endoleak after EVAR and the maximum diameter of AAA was 59.5 millimeter, which was 5.5 millimeter larger than 3 months ago. The DSA showed the distal tear of Stanford B aortic dissection was located near the right renal artery and

the false lumen running into the sac of AAA was the inflow of the endoleak. Because of high speed of blood stream in the inflow, we firstly implanted a GPS stent into the false lumen and secondly we used ten pair of coil to embolize the false lumen (the inflow).

Results: Follow-up after 6 months, the CTA showed endoleak had disappeared and the max diameter of AAA was smaller.

Conclusions: The endoleak induced by Stanford B aortic dissection is different from the other five types of endoleak and it might be a new type of endoleak. GPS stent and coil might be a good choice for the treatment. More studies are warranted.

The Efficacy of Intermittent Pneumatic Compression to Prevent Venous Thromboembolism: A Meta-analysis

Kalifu Baheti, Xiaohu Ge, Sheng Guan

Department of Vascular Surgery, People's Hospital of Xinjiang Uyghur Autonomous Region, Urumchi, China

Objective: The objective is to evaluate the use of intermittent pneumatic compression (IPC) in thromboprophylaxis.

Methods: Two reviewers searched the MEDLINE, EMBASE, and Cochrane Library web of science, CNKI for randomized controlled trials and assessed the outcomes and quality of the trials independently. Trials comparing IPC with pharmacologic thromboprophylaxis, thromboembolic deterrent stockings (TEDS), no prophylaxis.

Results: A total of 15444 hospitalized patients from 63 trials met inclusion criteria and were subject to meta-analysis. IPC was more effective than no IPC prophylaxis in reducing deep vein thrombosis (DVT) [OR = 0.34, 95% CI(0.25~0.45, P <0.00001)] and pulmonary embolism (PE) [OR = 0.45, 95% CI(0.31~0.65, P <0.0001)]. IPC was also more effective than TEDS in reducing DVT [OR = 0.55, 95% CI(0.35~0.88, P = 0.01)], and appeared to be as effective as pharmacologic thromboprophylaxis [OR = 1.05, 95% CI (0.69~1.59, P = 0.82)], but with a reduced risk of bleeding [OR = 0.31, 95% CI(0.19~0.50, P <0.00001)].

Conclusions: The effects of IPC are superior to those of intervention group and TEDS group in terms of preventing thromboembolism of inpatients, and there was no significant difference between IPC and pharmacologic thromboprophylaxis, whereas risk of hemorrhage during IPC is significantly lower than that of pharmacologic thromboprophylaxis.

Gunshot Wound of Thigh

*Baris Akca¹, Koksal Donmez², Didem Avci Donmez³,
Ufuk Yetkin²*

¹Department of Cardiovascular Surgery, Kilis State Hospital, Kilis, Turkey

²Department of Cardiovascular Surgery, Katip Celebi University Izmir Ataturk Training and Research Hospital, Izmir, Turkey

³Department of Emergency, Izmir Tepecik Training and Research Hospital, Izmir, Turkey

In this case, we wanted to share our experience in surgical approach to a patient with serious tissue, bone, and vascular damage caused by military rifle in a rural hospital neighboring to war zone.

A 38 years old male patient admitted to Kilis State Hospital with military rifle wound of right thigh. Right thigh was about the twice size of left thigh. There was 2 cm possible entry wound located medially at 1/3 mid-portion which was saturated by field doctors. Right thigh was stretched and stiff. There was a 5 × 5 cm localized hematoma around the wound. Distal pulses of right leg were not palpable. Coldness, cyanosis, motor dysfunction, and numbness were evident on right leg. Right femur was fractured with fragments. Wound area was explored while protecting saphenous vein. Hematoma was drained. Afterwards, active arterial bleeding was observed. Femoral artery and vein were totally cut. Bleeding was controlled after both ends of the veins were found and clamped. Femoral artery was not suitable for primary reconstruction. Saphenous vein, which was harvested from opposite leg, was interpositioned. In addition, femoral vein was seriously damaged and it was not suitable for end-to-end anastomosis. Another saphenous vein graft was interpositioned. After stabilization of fractured femur, operation was terminated. Dorsalis pedis artery was palpable. Patient's motor functions were normal and there was not any sign of ischemia at postoperative first day.

Gunshot wounds caused by military weapons may cause greater tissue defects and vascular damage with their high kinetic energy. Gold standard of vascular trauma is open surgical management is the gold standard therapy for gunshot wounds. If the hard signs of vascular trauma is evident (pulsatile bleeding, absent distal pulse, limb ischemia, expanding hematoma, shock with ongoing bleeding, bruit or thrill over area of injury), wound must be explored immediately. Early surgical intervention is essential for saving extremity and life.

Multiple Trauma Due to Bombing

*Baris Akca¹, Koksal Donmez², Didem Avci Donmez³,
Ufuk Yetkin²*

¹Kilis State Hospital, Kilis, Turkey

²Katip Celebi University Izmir Ataturk Training and Research Hospital, Izmir, Turkey

³Izmir Tepecik Training and Research Hospital, Izmir, Turkey

In this case we wanted to share our experience in diagnosis and follow-up of a patient with serious multiple trauma due to bombing in a rural hospital neighboring to war zone.

A 25 years old male patient admitted to emergency service due to multiple shrapnel wound caused by bombing. Two possible shrapnel entry points were observed on the chest wall. First one was located 3 cm medially to nipple and second one was about 1 × 1 cm on the sternal body. On his left femoral area, a 10 cm lesion was evident which was explored by field doctors at Syria and partially stitched with a sponge in it. There were multiple shrapnel wounds on both legs. A 3 cm wound was located 2 cm laterally to scrotum. Patient's left frontal bone was fractured and bone fragment was evident in frontal lobe. Orbital fracture, perforation of left eye and a shrapnel right behind the orbita were observed.

Thorax computerized tomography revealed an extrapericardially located shrapnel without pneumothorax, hemothorax or pericardial effusion. Transthoracic echocardiography was normal. Femoral area was explored after previously positioned sponge was removed. Arterial and venous bleeding was evident. Femoral incision was lengthened and area explored. Common femoral artery and vein were intact. There was a muscle injury beginning from medial of common femoral vein through deep tissue for 5 centimeters. A small branch of femoral artery was bleeding and it was repaired with primary suture. After removing foreign body, venous bleeding occurred. Vein injury was repaired with primary suture. Operation was terminated after positioning of a drain.

Surgical approach is gold standard of vascular trauma caused by penetrating trauma with high kinetic energy. Mortality and morbidity may only be reduced with appropriate interdisciplinary approach, which is highly important for saving life and extremity.

Lower Extremity Gunshot Wound

Baris Akca¹, Koksal Donmez², Didem Avci Donmez³,
Ufuk Yetkin²

¹Department of Cardiovascular Surgery, Kilis State Hospital, Kilis, Turkey

²Department of Cardiovascular Surgery, Katip Celebi University Izmir Ataturk Training and Research Hospital, Izmir, Turkey

³Department of Emergency, Izmir Tepecik Training and Research Hospital, Izmir, Turkey

In this case, we wanted to share our experience in surgical approach to a patient with serious lower extremity ischemia caused by military rifle in a rural hospital neighboring to war zone. Patient admitted to Kilis State Hospital.

A 36 years old male patient admitted to our emergency room with military rifle wound of both lower extremities. There were type 3 open fractures of both tibias. Patient was wounded about 6 hours ago. On the physical examination, anterior tibial artery and dorsalis pedis artery pulses were palpable on the right side. On the left side, none of the distal pulses were palpable. There was not any active bleeding. There were not any signs of ischemia like coldness, cyanosis, motor dysfunction, or numbness.

Exploration was decided with orthopedic surgeons for fractured left tibia. Patient underwent emergency surgery. Anterior tibial artery was explored from ankle area. It was totally cut. Tibialis posterior artery was not found due to total dislocation of anatomic planes with fracture. There was not any active bleeding. Saphenous vein was interpositioned to anterior tibial artery. Afterwards, orthopedic surgeons fixated tibia. Distal perfusion was achieved. Dorsalis pedis artery was palpable intraoperatively. Patient's motor functions were normal and there was not any sign of ischemia at postoperative first day.

Gunshot wounds caused by military weapons transfer much energy to soft tissues and bone. This may cause heavy tissue defects. Gold standard of vascular trauma is open surgical management. Due to long transfer times from battle zone to hospital, immediate decision and surgical intervention is essential for saving extremity and life.

Renal Vein Stent Insertion for Nutcracker Syndrome

*Ho Kyun Lee¹, Oh Hyun Park¹, Sang Young Chung¹,
Jae Kyu Kim², Soo Jin Na Choi¹*

¹Department of Surgery, Chonnam National University Medical School, Gwangju, Republic of Korea

²Department of Radiology, Chonnam National University Medical School, Gwangju, Republic of Korea

Introduction: Nutcracker syndrome describes an array of incapacitating symptoms caused by left renal vein hypertension secondary to vein compression between the SMA and the aorta.

Endovascular treatment has evolved as a potential minimally invasive therapy for relief of symptoms caused by this compression syndrome. We report a case of successful percutaneous renal vein stenting for treating nutcracker syndrome.

Case: A healthy 48-year-old female was referred for a second opinion regarding nutcracker syndrome. She described a one-month history of intermittent left flank pain with onset of microscopic hematuria. Urologic evaluation for this constellation of symptoms led to a contrast-enhanced computed tomography (CT) scan of his abdomen/pelvis. The CT scan identified compression of the left renal vein between the SMA and aorta, with an abundance of venous collaterals in the retroperitoneum.

A left renal venography performed at an outside facility confirmed the diagnosis and demonstrated an left renal vein-inferior vena cava (IVC) pressure gradient of 4 mm Hg (normal value <1–2 mm Hg).

Left ovarian vein embolization was performed to facilitate sheath and stent advancement across the stenosis. A 12 mm × 40 mm was then deployed, with 1 cm extension into the IVC. Post stent 12-mm balloon angioplasty was performed to dilate the vein. Completion venography demonstrated a widely patent LRV with decreased collateral filling and disappearance of an LRV-IVC pressure gradient (1 mmHg)

Anticoagulation was start, and the patient remained symptom-free.

Rapid Growth of Infectious Iliac Artery Aneurysm Due to Infectious Embolus after an Operation for Infectious Endocarditis

Yasuhito Sekimoto, Hirohisa Harada

Tokyo Dental College Ichikawa General Hospital, Ichikawa, Chiba, Japan

Background: Vascular complications such as vascular occlusion by infectious emboli, vasculitis and false aneurysms are common progressive features of infectious endocarditis, with a frequency

of approximately 15–35%. False aneurysms are rare complications of endocarditis (5–10%).

Case Report: A 21-year-old female was admitted to other hospital with fever, increase in the number of white blood cells and anemia. After admission, consciousness disorder occurred and head MRI showed multiple infarctions. Then she was referred to our hospital. As transesophageal echocardiography revealed the vegetation at mitral valve, she was diagnosed as infectious endocarditis. Then, replacement of mitral valve was performed immediately. Methicillin sensitive staphylococcus aureus (MSSA) was detected from blood culture and culture of vegetation. After the operation, contrast-enhanced CT showed liver abscess, splenic abscess and occlusion of the left iliac artery. Infectious embolus occluded the left common iliac artery but the blood flow was recanalized from left common femoral artery with collateral vessels. Vascular intervention was not considered because she had no ischemic symptoms. Anti-coagulation drug and antibiotics was continued. Forty-four days after the operation, CT was performed and the occlusion of the left iliac artery did not change, then discharge from hospital was planned. However, 55 days after the operation, left lower abdominal pain occurred suddenly and CT showed the left iliac artery aneurysm with a diameter of 55 mm. Under the diagnosis of infectious iliac artery aneurysm, emergency operation was performed. With middle to lower abdominal incision, the left common iliac artery was cut and closed, an aneurysm was opened and debrided, the stump of the left common iliac artery was covered with greater omentum. The post-operative course was uneventful, and she was discharged 80 days after the first surgery, 25 days after the second surgery.

0090

Popliteal Vein Repair with Posterior Approach in a Patient With Stab Wound

Koksal Donmez, Kazim Ergunes, Ihsan Peker, Bortecin Eygi, Habib Cakir, Banu Lafci, Levent Yilik, Ali Gurbuz

Katip Celebi University Izmir Atatürk Training and Research Hospital, Department of Cardiovascular Surgery, Department of Cardiovascular Surgery, Izmir, Turkey

Background: In this case, we wanted to share our experience in diagnosis and surgical treatment in popliteal vein injury due to stabbing.

Method: A 17 years old male patient admitted to emergency service after stabbing from left popliteal fossa. On the physical examination, there was a 3 cm straight wound located medially at popliteal fossa. Active bleeding was evident. There were not any signs of ischemia like coldness, numbness, motor dysfunction, or cyanosis in his left leg. Anterior tibial artery and dorsal pedal artery pulses were palpable and equal in both extremities. Patient's vital signs were stable (arterial pressure: 110/70 mmHg, 98 beats/minute). He was conscious, cooperating and there was not any additional trauma on his body. Knee joint was free of damage.

Results: Patient underwent emergency surgery. Popliteal artery and vein were explored with vertical incision from popliteal fossa with posterior approach. Popliteal artery was intact. It was suspended with nylon tape and retracted from popliteal vein. Afterwards, popliteal vein was examined. Partial cut was observed. It was repaired primarily with 6/0 prolene suture. All minor bleeding foci were ligated or cauterized. Patient was transferred to intensive care unit. Patient's motor functions were normal and there were not any signs of deep vein thrombosis after operation until discharge. Patient recovered uneventfully.

Conclusion: Venous repair may be performed safely if the patient is stable. Gold standard of vascular trauma is surgical management. If the hard signs of vascular trauma is evident (pulsatile bleeding, absent distal pulse, limb ischemia, expanding hematoma, shock with ongoing bleeding, bruit or thrill over area of injury), immediate decision and surgical intervention is essential. Posterior approach is a safe and feasible method for immediate exploration of popliteal fossa.

0100

Effects of Simultaneous Iliac Artery Angioplasty on Graft and Patient Survival after Living-donor Kidney Transplantation

Duck Jong Han¹, Young Hoon Kim¹, Young Soo Chung², Youngjin Han¹, Heungman Jun³, Tae-Won Kwon¹, Yong-Pil Cho¹

¹University of Ulsan College of Medicine and Asan Medical Center, Seoul, Republic of Korea

²Pusan National University Hospital, Pusan, Republic of Korea

³Korea University Anam Hospital, Seoul, Republic of Korea

Background: Renal transplant candidates with extended indications, such as older age and advanced atherosclerosis, are currently accepted onto the waiting list.

Methods: We evaluated retrospectively the clinical outcomes of simultaneous kidney transplantation and angioplasty, compared with transplantation alone.

Results: We included 748 patients who underwent living-donor kidney transplant due to end-stage renal disease (ESRD) during a five-year period, consisting of 27 kidney transplants with simultaneous angioplasty, and 721 without additional vascular procedures. As candidates for simultaneous angioplasty and transplant, we considered patients with TransAtlantic Inter-Society Consensus (TASC) type A and B aorto-iliac disease. We compared transplant outcomes in patients who did or did not receive simultaneous angioplasty. Although simultaneous iliac artery angioplasty was significantly related to recipient age, diabetes mellitus, hypertension, and coronary artery disease, it was not associated with graft (uncensored, $p = 0.937$; death-censored, $p = 0.981$) or patient ($p = 0.804$) survival during the follow-up period. In addition, simultaneous angioplasty was not associated with a higher risk of delayed graft function ($p = 0.099$) or a longer hospital stay ($p = 0.790$).

There was no significant difference in mortality due to a cardiovascular event between the two groups ($p = 0.199$).

Conclusions: Simultaneous iliac artery angioplasty and kidney transplantation in carefully selected patients can be performed safely with equivalent graft and patient survival to transplantation alone.

0101

Renal Vein Extension during Living-donor Kidney Transplantation in the Era of Laparoscopic Donor Nephrectomy

*Duck Jong Han¹, Youngjin Han¹, Young Hoon Kim¹,
Ki Byung Song¹, Young Soo Chung², Tae-Won Kwon¹,
Yong-Pil Cho¹*

¹University of Ulsan College of Medicine and Asan Medical Center, Seoul, Republic of Korea

²Pusan National University School of Medicine and Medical Research Institute, Pusan, Republic of Korea

Background: To evaluate retrospectively the clinical outcomes of living-donor kidney transplantations (LDKTs) using renal vein extension (RVE) for donor kidneys with short renal veins.

Methods: Between January 2007 and December 2010, a total of 576 LDKTs were performed with grafts generated by hand-assisted laparoscopic donor nephrectomy: 31 (5.4%) transplants with RVE and 545 (94.6%) without an additional vascular procedure for renal vein lengthening. Outcomes were compared in patients who did and did not undergo the RVE procedure during transplantation.

Results: The thirty-one transplants that underwent RVE involved procured kidneys with short renal veins: 29 were right-sided kidneys (93.5%) and 2, left-sided kidneys (6.5%) ($P = 0.00$). RVE grafts were obtained from allogenic gonadal veins from female donors ($n = 16$, 51.6%) and cadaveric iliac veins ($n = 15$, 48.4%). There were no postoperative complications related to the RVE procedure. During a follow-up period of 45.6 ± 15.9 months, there were one (3.2%) graft failure among the 31 patients with RVE and four (0.7%) among the 545 patients without RVE. Delayed graft function was noted in one (3.2%) of the RVE patients and 22 (4.0%) of the patients without RVE. There was no statistically significant difference in graft failure ($P = 0.24$) or delayed graft function ($P = 1.00$) between the two groups.

Conclusion: During LDKT, donor kidneys with exceptionally short renal veins, which may result in unavoidable tension during renal vein anastomosis, may be modified by RVE, thus facilitating a secure anastomosis and reducing postoperative complications.

0113

Comparison of Characteristic between Splenic Artery Aneurysm & Other Splanchnic Artery Aneurysm

*Youn-jung Kim, Young-wook Kim, Young-Soo Do,
Dong-Ik Kim, Yang-Jin Park, Kwang-Bo Park,
Hong-Seok Park*

Samsung Medical Center, 81 Irwon-Ro, Gangnam-gu, Seoul, Republic of Korea

Purpose: Splanchnic artery aneurysm (SAA) is defined as aneurysm occurring at the celiac axis, mesenteric artery or its branches. SAA is uncommon but can cause a major disaster when ruptured. We tried to find clinical and demographic characteristics of SAA by comparing of them between splenic artery aneurysm and other SAAs.

Methods: Medical records of 90 SAA patients detected during the past 10 years were retrospectively reviewed. Postoperative pseudoaneurysms occurring at the splanchnic artery or their branches were excluded from this study. We compared etiology, demographic and clinical features, treatment between splenic artery aneurysm and other SAAs.

Results: SAAs distributed at splenic ($n = 60$, 66.7%) and other splanchnic arteries ($n = 30$, 33.3%) including superior mesenteric ($n = 13$, 43.3%), gastroduodenal ($n = 6$, 20%), proper hepatic artery ($n = 5$, 16.7%) and celiac axis ($n = 5$, 16.7%). Splenic artery aneurysm patients' mean age was 54.5 years old and then that of other SAA was 56.7 (P value = 0.472). Number of female patients of splenic AA patients was 35 (58.3%), other SAA patients was 9 (30%), P value was 0.011. Number of Symptomatic patients was 8 (13.3%) and 12 (40%), P value was 0.004. Preoperative hypertension, ischemic heart disease, diabetes, liver cirrhosis and pancreatitis were identified no significant association. The number of etiology identified patients was 1 in splenic artery aneurysm and 10 in other SAA (P value <0.001). There was one mycotic splenic artery aneurysm case. In other SAA cases, 3 patients were with mycotic Aneurysms. In the others, 2 were SAA with arterial dissection, 2 had fibromuscular dysplasia, 1 had type I neurofibromatosis, 1 had Behcet's disease, and 1 had Arterio-venous malformation.

Conclusion: We found different features between splenic artery aneurysm and other SAA. Female gender was more common in splenic artery aneurysms. Identifiable etiology, symptomatic clinical presentation was more common in other SAAs.

Successful Closure of Inadvertent Subclavian Artery Cannulation during Central Venous Catheter Placement Using a Percutaneous Closure Device

Jun Jie Ng, Jackie Ho

National University Health System, Singapore, Singapore

Introduction: Inadvertent arterial injury during central venous catheters (CVC) insertion frequently happens in critically ill patients. We report our experience in 2 cases where closure of inadvertent subclavian artery (SCA) cannulation was performed using a percutaneous closure device – ProGlide (Abbott Laboratories).

Technique: An angiogram is performed through a sheath inserted to the ipsilateral brachial artery to determine the entry site of the CVC in the SCA relative to important branches. An angioplasty balloon catheter matching the SCA size is introduced and parked at the cannulation site before the CVC is exchanged for the ProGlide. The ProGlide is deployed and an angiogram is performed.

Illustrative Cases

Case 1: An 8.5Fr CVC was inadvertently inserted into the right SCA of a 23-year-old man who presented with septic shock. A 5Fr sheath was placed in the right brachial artery and angiogram showed the cannulation site 8 mm distal to the vertebral artery origin. An 8 × 40 mm angioplasty balloon was introduced and parked at the cannulation site. The balloon was inflated temporarily at 4 atmospheric pressure and the CVC was exchanged for the ProGlide. The ProGlide device was deployed and repeat angiogram showed complete haemostasis.

Case 2: A 12Fr CVC was inadvertently inserted into the left SCA of a 39-year-old man who presented with multi-organ failure after open surgery of infected heart valve. Left brachial access was obtained and angiogram showed the cannulation site 1 cm distal to the vertebral artery origin. A 6 × 40 mm angioplasty balloon was parked at the cannulation site. The CVC was exchanged for the ProGlide and deployed. Angiogram showed small contrast leakage and haemostasis was achieved with balloon tamponade together with external compression.

Conclusion: The ProGlide allows for safe closure of inadvertent SCA cannulation. Placement of an angioplasty balloon catheter allows for a safety back-up if percutaneous closure of the arterial defect fails to achieve haemostasis immediately.

Endovascular Aortic Aneurysm Repair (EVAR) Using Bifurcated Device in a Patient with Femoro-Femoral Bypass

Woo-Sung Yun, Bo-Yang Suh

Division of Transplantation and Vascular Surgery, Department of Surgery, Yeungnam University Medical Center, Yeungnam University College of Medicine, Daegu, Republic of Korea

Seventy-seven year old male presented with abdominal aortic aneurysm (AAA) with bilateral common iliac artery (CIA) aneurysms. He underwent femoro-femoral crossover bypass 8 years ago due to left external iliac artery (EIA) occlusion. In this situation, aorto-uni-iliac (AUI) device is generally used. Because he had bilateral CIA aneurysms, we needed hybrid procedure, such as EIA to internal iliac artery (IIA) bypass. To treat this patient with endovascular way, we used bifurcated type stent graft (Cook Zenith®). One iliac limb was deployed in right EIA via right common femoral access and the other iliac limb (Gore Viabahn®) was placed in right IIA via left axillary access. Left IIA was embolized with coil. We introduce procedure details and technical tips.

Percutaneous Angioplasty Balloon Assisted Thrombin Injection for Pseudoaneurysms

Sujith Wijerathne, Jackie Ho

National University Health System, Singapore, Singapore

Background and Objectives: Thrombin injection is an effective treatment for arterial pseudoaneurysm due to penetrating injury or procedure related trauma. One of the potential complications of this treatment is thrombus embolization into the distal circulation. We report a technique using angioplasty balloon to temporarily occlude the flow to the pseudoaneurysm while injecting thrombin into the sac for both arterial and dialysis fistula pseudoaneurysm.

Methods: Two patients age 47 and 84 were reported. The younger patient had kidney failure using left brachio-cephalic arteriovenous fistula (BC AVF) for hemodialysis. A 5 cm narrow neck pseudoaneurysm developed from the fistula over mid-forearm was noted. The older patient suffered from a 3 cm iatrogenic pseudoaneurysm of the left brachial artery after chimney endovascular stent-graft repair. A brachial access was used for the younger patient and the second patient with radial access. 4Fr sheath was used. After a diagnostic angiogram, angioplasty balloon selected based on the fistula and brachial artery size respectively was parked beneath the pseudoaneurysm neck. Transcutaneous ultrasound was performed to obtain a best view for thrombin injection. The angioplasty balloon was then inflated with low pressure followed immediately with percutaneous ultrasound guided thrombin injection into the

sac. External pressure was then applied for 2 minutes before the balloon deflated for completion angiogram.

Results: Completion angiogram and intra-operative ultrasound showed complete thrombosis of the brachial artery pseudoaneurysm without distal embolization noticed. There was still small amount of residual flow present in the pseudoaneurysm sac in the completion angiogram for the AVF patient but repeat ultrasound performed 1 week later showed complete thrombosis. The BC AVF was cannulated for hemodialysis post-procedural day 1. Subsequent follow-up confirmed complete resolution of the pseudoaneurysm for both patients.

Conclusion: Treatment of arterial and dialysis fistula pseudoaneurysms with percutaneous angioplasty balloon assisted thrombin injection is feasible and safe.

0197

Our Cost-Effective Repair Strategy of Innominate Vein Injury Due to Spreading in Open Heart Surgery

Ufuk Yetkin, Habib Cakir, Ihsan Peker, Koksali Donmez, Ali Gurbuz

Department of Cardiovascular Surgery, Katip Celebi University Izmir Atatürk Training and Research Hospital, Izmir, Turkey

Injury of central venous system may be penetrating or iatrogenic trauma. Innominate vein injury usually occurs due to catheterization or sternal spreading.

Our case was 68 year-old female patient. She was investigated for shortness of breath and chest pain complaints. She was hospitalized for serious aortic valve stenosis and coronary artery disease. Patient had type 2 diabetes mellitus and hemorrhoid in her medical history.

Patient underwent aortic valve replacement and coronary artery bypass grafting surgery under general anesthesia. After median sternotomy of morbid obese patient, all underlying tissue was considered as highly fragile. Although sternal spreader was positioned with great care, left lateral segment of innominate vein torn spontaneously. Bleeding was controlled by digital compression. After control of bleeding, aortic cannulation was completed urgently and avoided from cell saver establishment, which greatly increases operation costs. Venous cannulation was delayed for air resorbing complication. Massive hemorrhagic lodge was aspirated with coronary sucker. Torn part of innominate vein was repaired with 4/0 prolene in an over and over fashion. Venous cannulation was performed with a two-stage cannula afterwards. By using cardiopulmonary bypass, aortic valve replacement and coronary artery bypass grafting of a single vessel was successfully completed after subtotal pericardiectomy procedure. There was not any early or late term complication.

Vascular reconstruction of innominate vein injury is rare. This complication may cause sudden and fatal bleeding. We believe that primary repair of these cases may be handled successfully and effectively by components of cardiopulmonary bypass without any additional costs in practice of open-heart surgery.

0201

A Review of Factors Affecting Limb Salvage in Traumatic Arterial Injury: Kuantan, Malaysia Experience

Ismail Ali¹, Mohd Norhisham Azmi Abdul Rahman¹, Mohamad Sallehudin Che Zan², Hasmali Mohamad², Izatt Syafieq Abd Rashad², Nazri Mohd Yusof³, Ahmad Faidzal Othman¹

¹Vascular Unit, Department of Surgery, Kuliyah (Faculty) of Medicine, International Islamic University Malaysia, Kuantan, Pahang, Malaysia

²Department of Surgery, Hospital Tengku Ampuan Afzan, Kuantan, Pahang, Malaysia

³Department of Orthopaedic and traumatology, Kuliyah (Faculty) of Medicine, International Islamic University Malaysia, Kuantan, Pahang, Malaysia

Arterial injuries to extremities account for 50% of all arterial traumas. These injuries can be quite challenging to the surgeon due to limited time for intervention and any associated injuries. Management of traumatic limb ischemia has evolved from simple ligation of damaged vessel during World War I and II which result in amputation to limb salvage surgery. It has shown dramatic improvement in which the limb salvage rates up to 83.8%.

We reviewed all the cases of traumatic arterial injuries to the extremities that needed intervention from 2011–2013 at our institution. Result of limb salvage and the importance of MESS score preoperatively will be discussed.

0215

Combined Endovascular and Surgical Approach for a Ruptured Extended Thoracic Aortic Aneurysm Patient Presented with Massive Hemoptysis

Yoshihito Irie¹, Shunichi Kondo¹, Eitochi Tsuboi¹, Kyu Rokkaku¹, Hitoshi Yokoyama²

¹Cardiovascular Surgery, Iwaki Kyouritsu General Hospital, Iwaki, Fukushima, Japan

²Cardiovascular Surgery, Fukushima Medical University, Fukushima, Japan

Since thoracic endovascular aneurysm repair (TEVAR) was introduced, hybrid therapy has been applied for the extended arch aneurysm. Our standard strategy for the scheduled operation is to perform a total arch replacement with an elephant trunk followed by TEVAR for the remained descending aortic aneurysm. For the ruptured cases, we perform the Zone 0 TEVAR with total debranching from the ascending aorta. Recently, we experienced a case presented with a massive hemoptysis due to a ruptured descending aortic aneurysm, simultaneously with a ruptured aortic arch. According to our strategy, a total debranching TEVAR in arch and

additional TEVAR in descending aorta could be the best choice. However, the total debranching was unable to perform because the severe calcified ascending aorta and the TEVAR need to perform as soon as possible because the massive hemoptysis. In order to solve both problem, an alternative operation is necessitated.

In this video, we are going to show a combined endovascular and surgical technique including an anastomosis of conventional artificial graft and stent graft to resolve this critical status.

0217

Novel Surgeon-Modified Iliac Branched Device for Preserving Pelvic Flow

Jin Hyun Joh, Bomina Baek

Kyung Hee University Hospital at Gangdong, Seoul,
Republic of Korea

Background: During the endovascular repair of aortoiliac aneurysm, bilateral internal iliac artery (IIA) occlusion is associated with significant morbidity. Iliac branched device (IBD) to preserve the IIA flow has been developed for that purpose. We present the technical aspects of the novel surgeon-modified IBD.

Technical Description: A 66-year-old man presented with bilateral common iliac artery aneurysms. Firstly bilateral inguinal cut-down was made for the access of femoral arteries. At the operative table, surgeon-modified IBD was made for fixing the right common iliac artery aneurysm. A 10 × 71 mm Zenith iliac limb was deployed up to 2 and half stent. A 12 mm elliptical graftomy was done on the 2nd stent of the iliac limb using an ophthalmologic cautery. A 2 cm-lengthed, 7 mm PTFE graft was anastomosed on the iliac limb using 5-0 Prolene. A Cobra catheter with guidewire was inserted into a 20F St. Jude sheath in vitro to confirm the possibility for the insertion of whole device. After insertion of stiff guidewire up to the aortic arch, a 20F St. Jude sheath was inserted up to the aortic bifurcation. The IBD was inserted into this sheath during the collapse Zenith iliac limb using Nylon tape. After we made a through-and-through femoral access, IBD was deployed until the hypogastric branch was opened. An 8F Ansel sheath was inserted at left common femoral artery side via through-and-through femoral wire up to hypogastric branch. Another 0.035 In guidewire was inserted into right IIA via Ansel sheath. After obtaining angiogram of right IIA, preloaded guidewire was removed. Then, a 7 mm V12 balloon expandable stent graft was placed into right IIA. After complete deployment of IBD and IIA stent graft, a routine endovascular aneurysm repair was done. Completion angiogram showed the patent stent graft and no endoleak.

(E) Peripheral Arterial Disease

0002

Algorithm Proposed for the Management of Spontaneous Isolated Dissection of the Superior Mesenteric Artery and New Classification

Baku Takahashi¹, Shinyu Shiroma², Koki Ido², Yoshihiro Nakayama¹, Tomohiro Taguchi², Sumio Okuda², Yosuke Mukae¹

¹Department of cardiovascular surgery, Oosumikanoya Hospital, Kanoya-shi, Kagoshima, Japan

²Department of general surgery, Oosumikanoya Hospital, Kanoya-shi, Kagoshima, Japan

Introduction: Spontaneous isolated dissection of the superior mesenteric artery (SIDSMA) is very rare condition and the best management has been still no consensus. Here, we present three cases of SIDSMA who were treated by surgical revascularization, endovascular therapy and conservative management. The aim of this study is to assess retrospectively, and to propose a new classification and treatment algorithm of SIDSMA.

New classification: We suppose to propose a new classification of two types based on angiographic findings because clinical course did not accord with image findings as for the past classification. Type I: communicating SMA dissection, Type II: non-communicating SMA dissection; Type IIa: thrombosed false lumen with intimal defect or with $\leq 75\%$ stenosis of true lumen, and Type IIb: thrombosed false lumen without intimal defect or with $\geq 75\%$ stenosis of true lumen. By using this classification, we can decide whether you take anticoagulation therapy or not in the conservative treatment. That is, Type I and Type IIa should be taken anticoagulation, and Type IIb should not.

New algorithm: Finally, we would like to propose an algorithm for the management of SIDSMA based on symptomatic presentation and the image findings. At first, surgery is mandatory when there are bowel necrosis or artery rupture; Otherwise, for people with symptoms (transient or ongoing pain), we should perform angiography and endovascular stent placement should be feasible in patients without anatomical problems, and with suspected bowel ischemia regardless of the stenosis level of SMA. On the other hand, asymptomatic patients need conservative therapy based on the new classification, however, we should perform endovascular treatment when symptoms recur and/or last, or when follow-up CT scan demonstrates aneurysm increase or dissection progression.

Conclusion: Endovascular therapy should be the first choice for the symptomatic patients with suspicious of ischemic intestine, however, surgery should be reserved for the patients in the difficult case with endovascular repair.

Characteristics of Ankle-Brachial and Toe-Brachial Indexes and Pulse Volume Waveforms in Healthy Young Adults: Influences of Age and Gender

Yoshiko Watanabe, Hisao Masaki, Atushi Tabuchi, Yasuhiro Yunoki, Hiroshi Furukawa, Takahiko Yamasawa, Hiroki Takiuchi, Takeshi Honda, Noriaki Kuwada, Kazuo Tanemoto

Kawasaki Medical School, Kurashiki, Okayama, Japan

Background and Objectives: Measurements of ankle-brachial index (ABI) and toe-brachial index (TBI) are most common methods of assessing peripheral artery diseases. Peripheral arterial pressures are affected by vascular resistance and arterial stiffness which change with age. However, the influences of age to ABI and TBI have not been decided. This study aimed to investigate the characteristics and standard ranges of ABI, TBI, and pulse volume waveforms at ankles in young adults.

Methods: We analyzed the records of ABI and TBI in healthy subjects aged 20–24 years: ABI, % mean arterial pressure (MAP), and upstroke time (UT) had been recorded in 1300 legs (607 of males and 693 of females), and TBI in 493 toes (251 of males and 242 of females). All measurements had been performed using an ABI-form® (Colin Co., Aichi, Japan) with oscillometric pressure sensors and volume-plethysmographic sensors. Results were expressed as mean (two standard deviations [2SD] range).

Results: ABI was 1.059 (0.895–1.223) and was higher in males than in females ($p < 0.001$). ABI < 0.9 was observed in 1.3% of the legs in males and 14.7% of those in females. TBI was 0.801 (0.533–1.069) and similar in both genders ($p = 0.63$). TBI < 0.7 was observed in 19.1% of the toes. % MAP was higher in females (41.3 [37.3–49.3]) than in males (38.8 [31.2–46.4], $p < 0.001$). UT was 144.2 (110.6–177.8) msec and similar in both genders ($p = 0.95$). The pulse volume waveforms at ankle varied considerably among individuals.

Conclusions: In people in their early 20s, the lower limits of ABI and TBI may be lower than those in aged adults. Ankle %MAP seems to be higher in females in their early 20s than in males of the same age. Age and gender will need to be considered when assessing the limb ischemia by ABI or TBI.

0022

Management of Acute Right and Left Brachial Artery Thrombosis after Catheterization

Kazim Ergunes, Banu Lafci, Orhan Gokalp, Yuksel Besir, Koksai Donmez, Serkan Yazman, Levent Yılık, Ali Gurbuz

Izmir Katip Celebi University Atatürk Training and Research Hospital, Izmir, Turkey

Background and Objectives: Upper extremity acute arterial thrombosis is uncommon when compared with lower extremity

arterial thrombosis. Thromboembolic arterial occlusion is associated with high morbidity and mortality. We presented a case with bilateral acute brachial artery thrombosis after catheterization.

Methods: A 42-year old woman was hospitalised in our clinic on December 23, 2013. She had acute right and left upper extremity pain and discoloration after undergoing peripheral catheterization via right and left brachial artery. The Arterial Doppler ultrasonography showed thrombosis of bilateral brachial arteries.

Results: Thromboembolectomy was performed to the brachial, radial, and ulnar artery of right and left upper extremities with 4/F and 3/F Fogarty catheter. Abundant thrombus was thrown out from proximal and distal segments of right and left brachial arteries. The pulses of these arteries were recovered, postoperatively. Low-molecular-weight heparin was given postoperatively.

Conclusions: Acute upper extremity arterial thromboembolism is an important complication after catheterization. Thromboembolectomy is effective and safe treatment method.

0026

Significance of Infragenicular Bypass for Intermittent Claudication in the Era of Endovascular Treatment

Shinsuke Mii¹, Kiyoshi Tanaka¹, Ryoichi Kyuragi¹, Sosei Kuma²

¹Steel Memorial Yawata Hospital, Kitakyushu-city, Japan

²Kokura Memorial Hospital, Kitakyushu-city, Japan

Background and Objectives: Since the natural history of limb with intermittent claudication (IC) is stable, long durability of revascularization is required in patients with IC. However, the efficacy of endovascular treatment (EVT) for IC due to occlusion of the popliteal and crural artery has not promised and surgical bypass is still selected when conservative treatment does not succeed. The aim of this study is to examine the durability of surgical bypass to infragenicular artery for IC.

Methods: The clinical charts of patients who underwent infragenicular artery bypass for IC for past 20 years was retrospectively checked and operative mortality and morbidity and long-term outcomes (graft patency, amputation-free, life survival) were evaluated. The predictors of long-term outcomes were analyzed by multivariate analysis.

Results: One-hundred six bypasses (distal anastomosis in popliteal artery in 61, crural artery in 45) were performed using vein in 83 and prosthesis in 23. There were 73 denovo cases and 90 patients with arteriosclerosis obliterans. During hospitalization after bypass surgery, 27 patients (25%) had local or systemic complications and one patient died of multiple organ failure. Primary, (PP) secondary (SP), freedom from major amputation (AF) and life survival rate (LS) were 57 and 38, 67 and 56, 95 and 90, and 78 and 58% at 5 and 10 year, respectively. Multivariate analysis showed redo case and prosthetic graft in PP, prosthetic graft in SP, smoking history and prosthetic graft in AF, and age, male, history of stroke

and postoperative non-use of eicosapentaenoic acid in LS as a predictor of each long-term outcome. Sub analysis showed the tendency ($p < 0.1$) that single vein graft was superior to spliced vein graft in PP.

Conclusions: Infragenicular bypass for IC is acceptable in condition of available single vein as a bypass conduit.

0033

Excellent Long Time Patency of Femoro (ilio) Femoro Bypass Graft for Intermitted Claudicants

Hironobu Fujimura

Toyonaka Municipal Hospital, Toyonaka/Osaka, Japan

Aim: To know the long time patency of prosthetic graft for femoro (ilio)femoro (F-F) bypass grafting for intermittent claudicants.

Material and Methods: A retrospective review of F-F bypass patients treated for intermittent claudication between July 2006 and January 2014 was conducted at one institution. Patient characteristics and outcome were reviewed. Kaplan-Meier curves were used to estimate patency rates.

Results: A total of 31 patients took F-F bypass surgery. Four ALI, 4 CLI, 6 patients with distal bypass were exclude. Seventeen patients with intermittent claudication were studied in this series. The primary patency rate was 100% at two years and 100% at five years.

Conclusion: F-F bypass using prosthetic graft for intermittent claudication patients showed excellent long term patency rate.

0053

Treatment Results for Spontaneous Isolated Superior Mesenteric Artery Dissection According to our Previous Guidelines and Collective Literature Review

Byung Sun Cho¹, Hye Young Ahn²

¹Eulji University Hospital, Daejeon, Republic of Korea

²Eulji University College of Nursing, Daejeon, Republic of Korea

Objectives: Isolated superior mesenteric artery dissection (ISMAD) is not a rare disease. However, its optimal treatment strategy has not yet been established.

Materials and Methods: This study included thirteen consecutive patients with ISMAD who were treated between April 2010 and July 2013 according to published treatment guidelines. Through a literature search, ten studies on treatments and outcomes for ISMAD that were published from 2007 to the present were analysed.

Results: In the present study, eleven patients had acute onset abdominal pain and two patients were asymptomatic. Twelve patients were treated with conservative treatment, while one patient underwent coil embolisation. In the literature review, initial conservative treatment, endovascular procedure, and surgical repair were

done in 172, 25, and 14 patients, respectively. Bowel resection was done in 8 patients (3.7%) due to bowel necrosis. Conservative treatment failed in 15 patients (6.8%) during follow-up.

Conclusions: If bowel necrosis or arterial rupture was not present, conservative treatment of ISMAD was a safe and effective treatment. Aneurysmal type IV patients on CT scan should be carefully followed-up and, if there is a recurrence of pain or aneurysmal progression, an endovascular procedure could be safely performed.

0055

A Case of Surgical Treatment for Leriche's Syndrome with Severe Carotid and Coronary Artery Diseases

Shinichiro Taniguchi¹, Seizaburo Sakamoto², Koichiro Takemoto², Hiromasa Kobayashi², Masaki Takahara², Shun Nakaji¹, Ryuichiro Shibata¹

¹Sasebo Chuo Hospital, Cardiovascular Surgery, Sasebo, Nagasaki, Japan

²Sasebo Chuo Hospital, Neurological Surgery, Sasebo, Nagasaki, Japan

Recently, there are increasing numbers of patients with polyvascular disease including peripheral, carotid and coronary artery diseases. Simultaneous or multi-staged surgery for multiple lesions has been recommended for these patients to reduce the incidence of perioperative complications. A 67-year-old male patient was admitted to our hospital complaining of intermittent claudication. Bilateral femoral arteries are not palpable and both ankle brachial pressure index is 0.5. Computed Tomography showed Leriche syndrome with severe calcification of aortic bifurcation and bilateral common iliac arteries. The further examination of coronary and cerebrovascular angiography revealed severe stenoses of left main coronary artery and right internal carotid artery. Each case is unique and requires the use of various criteria to select between methods of operating. This case involves coronary artery disease with ascending aortic calcification, combined with peripheral artery disease of the collateral circulation fed to the legs through the internal thoracic artery and a calcified abdominal aorta refractory to anatomical reconstruction. We selected a three-staged operation of carotid artery stenting (CAS), right axillo-bifemoral bypass grafting and off-pump coronary artery bypass grafting (OPCAB). At first, CAS was performed. The postoperative course was uneventful, and the patient was discharged on the 14th day after OPCAB.

PAD Hidden in Lower Limbs with Normal ABI

Yasuhiro Ozeki¹, Kazuo Tsuyuki¹, Shinichi Watanabe², Kenji Kohno¹, Kyoko Takashima¹, Mayumi Hamada¹, Yuki Tominaga¹, Hiroyoshi Yano¹, Kunio Ebine¹, Susumu Tamura¹, Masashi Yokomuro¹, Toshifumi Murase¹, Kenji Ninomiya¹, Naoya Moriki¹, Kenta Kumagai¹, Itaru Yokouchi¹, Satoru Toi¹

¹Odawara Cardiovascular Hospital, Odawara, Kanagawa, Japan

²Development Center to Support Health and Welfare, Kanagawa Institute of Technology, Atsugi, Kanagawa, Japan

Objective: To clarify the frequency of PAD in lower limbs with normal ABI.

Subjects: The subjects were 206 patients (401 limbs) with normal ABI who complained of intermittent claudication and other symptoms (cold sense, numbness, and pain of lower limbs): 63 patients (126 limbs) with hypertension, diabetes, and lipid metabolism abnormality (coronary risk factor group), 48 patients (95 limbs) with ischemic heart disease (IHD group), and 43 hemodialysis patients (77 limbs) (HD group), as well as 52 control subjects (103 limbs) (N group).

Methods: All subjects performed a 5- or 1-minute exercise-loaded ABI test, and the ankle pressure (Ex-AP) and ABI (Ex-ABI) were measured immediately after walking. Regarding the diagnostic criteria of PAD, when Ex-ABI rose by 15% or higher from that on rest with a 20-mmHg or greater reduction of Ex-AP, the limb was judged as PAD-positive. Limbs with an Ex-AP of 120 mmHg or higher were excluded. When one of the Ex-ABI and Ex-AP criteria was met, or when both criteria were met but Ex-AP was 120 mmHg or higher, the limb was regarded as at high-risk.

Results: No limb was positive in the N group, but 1.8, 7.4, and 19.5% of the limbs were positive in the coronary risk factor, IHD groups, and HD group, respectively. Also, 1.9, 4.5, 4.2, and 32.5% of the limbs were positive in the N group, coronary risk factor, IHD groups, and HD group, respectively, at high-risk.

Conclusion: The frequencies of PAD-positive lower limbs with normal ABI and high-risk limbs were low and varied among diseases.

0076

Long Term Result of Kissing Stent in Aortoiliac Bifurcation: A Single Center Experience

Hong Pil Hwang^{1,2}, Jae Do Yang^{1,2}, Sang In Bae^{1,2}, Young Min Han^{1,2}, Hee Chul Yu¹

¹Chonbuk National University Hospital, Jeonju, Chonbuk, Republic of Korea

²Research Institute of Clinical Medicine, Jeonju, Chonbuk, Republic of Korea

Background: Kissing stent reconstruction of the aortoiliac bifurcation is a widely used technique for the management of aortoiliac

occlusive disease involving the aortic bifurcation or proximal common iliac arteries. The purpose of this study was to evaluate the results of endovascular treatment of symptomatic aortoiliac occlusive disease at the aortoiliac bifurcation with kissing stents in our hospital.

Methods: We reviewed medical records of the patients treated with a kissing stent and retrospectively from January 2007 to December 2012. Follow-up was clinical examination and duplex scan or computed tomography. Patency rates were estimated by Kaplan-Meier analysis, and Cox multivariate regression was used to determine factors associated with patency.

Results: Total 21 patients was included, and all were male (median age 53 ± 15 , range 48–78). Major complaint was claudication ($n = 11$, 52.3%), rest pain ($n = 5$, 23.8%) and gangrene ($n = 5$, 23.8%). TASC distribution was: A 9.5% ($n = 2$), B 19% ($n = 4$), C 33.3% ($n = 7$) and D 38% ($n = 8$). The mean follow-up was 40.7 months. Complication occurred in only one case that was distal limb ischemia by emboli. 6 patients developed a symptomatic restenosis or occlusion. All 6 were treated successfully with endovascular reintervention. There was not major amputation and minor amputation was in 2 patients. Two mortalities were not associated with procedure but underlying diseases (lung cancer and multiple co-morbidities). Primary patency was 89.6% after 1 year, 74.7% after 3 years and 64% after 5 years. Secondary patency was 94.1% after 1 year, 88.2% after 3 years and 68.6% after 5 years. No risk factors for restenosis were identified. There was no significant difference in patency between the TASC B, C, D groups.

Conclusions: Endovascular treatment of symptomatic atherosclerotic aortoiliac bifurcation using kissing stents can be used successfully with comparable patency.

0083

Surgical Experience with Thoracic Outlet Syndrome

Hirotoki Ohkubo, Keita Hayashi, Naotsugu Yamashiro, Shintaro Shibutani, Shinobu Hayashi

Department of Vascular Surgery, Saiseikai Yokohamashi Tobu Hospital, Yokohama/Kanagawa, Japan

Background: Thoracic outlet syndrome (TOS) is a rare disease that can be broadly classified into 3 categories: neurologic TOS (nTOS), venous TOS (vTOS), and arterial TOS (aTOS), accounting for 96%, 3%, and 1% of all cases of TOS, respectively. We describe our experience with patients who underwent surgery for TOS, along with a discussion of the literature.

Subjects: During the 6 years 6 months from April 2007 through October 2013, 5 patients (2 men and 3 women) underwent surgery for TOS. The mean age was 46 ± 10 years.

Results: All patients had claudication of the upper limbs. Two patients also had acute arterial occlusion in the upper limbs. In 1 of these patients, arterial occlusion was limited to the forearm. In the other, thrombotic occlusion involved all arteries distal to the subclavian artery, causing severe limb ischemia. The underlying

cause was apparently compression by the clavicle and the first rib in 4 patients and clavicular and periosteal hyperostosis with compression of the anterior scalene muscle and middle scalene muscle in 1 patient. No patient had a cervical rib. As for the surgical approach, an axillary approach or a supraclavicular approach was used in all patients. All patients perioperatively underwent angiography, and the absence of stenosis was confirmed. Surgery improved symptoms in all patients, and the postoperative course was good.

Conclusions: Vascularization is challenging via an axillary approach, and resection of the first rib is difficult via a supraclavicular approach. Therefore, the preoperative diagnosis of the site of stenosis is very important, and the treatment strategy should be carefully formulated. In patients with acute arterial occlusion of the forearm, the possibility of aTOS should be borne in mind.

0116

A Case of Persistent Sciatic Artery Occlusion with Blue Toe Syndrome

Naotsugu Yamashiro, Hirotoki Ohkubo, Shintaro Shibutani, Keita Hayashi, Shinobu Hayashi, Atsushi Nagashima

Saiseikai Yokohamashi Tobu Hospital, Yokohama/Kanagawa, Japan

Persistent sciatic artery (PSA) is a rare congenital anomaly with an estimated incidence of 0.03–0.06%. It may result in aneurysmal formation and occlusion. We report a case of a chronic total occlusion (CTO) of complete-type PSA in the left limb with blue toe syndrome.

A 73-year-old woman was admitted to our hospital with claudication in her left limb requested more aggressive treatment of the claudication because it had recently become severe. The ankle-brachial index (ABI) for the left limb was 0.76. Ultrasonography and computed tomographic angiography (CTA) revealed that the left PSA extended from the origin of the internal iliac artery to the popliteal artery and had a long CTO. The right PSA has also persisted but been patent. In both extremities, she had patent but hypoplastic external iliac and common femoral arteries leading to the profunda femoral artery, and hypoplastic superficial femoral artery. The artery of lower left limb was enhanced by a collateral branch of the superficial femoral artery. These findings established the diagnosis: CTO of left PSA with blue toe syndrome.

Then, we performed the left common femoral-to below-knee popliteal artery bypass grafting and ligating left PSA below-knee. The postoperative course was good, left limb claudication and blue toe syndrome were improved.

PSAs have an increase rate of aneurysmal dilatation, thrombosis and early atherosclerotic changes. CTO of PSA is a rare vascular condition that can be successfully treated with reconstructive techniques if the diagnosis is correctly established.

0123

Surgical Revascularization in Chronic Mesenteric Ischemia and Abdominal Aortic Aneurysm

Hyuk Jae Jung, Ji Ho Lee, Sang Su Lee

Pusan National University Yangsan Hospital, Yangsan, Gyeongnam, Republic of Korea

Purpose: Chronic mesenteric ischemia cause serious clinical problem resulting in starvation or enteromesenteric infarction. Diagnosis is often delayed due to ambiguous abdominal pain. Typical presentation is postprandial abdominal pain, severe weight loss, and altered bowel habit. We experienced surgical revascularization of patient combining chronic mesenteric ischemia and abdominal aortic aneurysm.

Case: A 77 year-old-male patient was transferred from cardiovascular department. He had several past histories such as hypertension, atrial fibrillation and chronic kidney disease. He had already diagnosed as coronary arterial obstructive disease; 3-vessels disease and had percutaneous coronary intervention with stenting 1 month ago. He was admitted to ER with aggravation of postprandial abdominal pain. The preoperative enhanced computed tomography (CT) with 3D reconstruction revealed 5.6 cm sized AAA, 2.9 cm sized aneurysm in Lt. common iliac artery proximal, and superior mesenteric artery (SMA) occlusion. We confirmed his symptom as being caused by chronic mesenteric ischemia. We first tried to recanalize SMA total occlusion with endovascular approach because of his cardiac condition. However, the selection of SMA was failed due to heavily calcification. So, Procedure was converted into open surgery, which was open AAA repair with bypass between SMA and aortic graft. After bypass operation, the Postprandial pain was completely disappeared. Postoperative CT angiography showed good blood flow.

Conclusion: Although endovascular treatment has been popular, the conventional revascularization may have a role for long term relief from the symptoms and better overall survival in visceral arteries.

0125

Hybrid Treatment in Buerger's Disease

Hyuk Jae Jung, Ji Ho Lee, Sang Su Lee

Pusan National University Yangsan Hospital, Yangsan, Gyeongnam, Republic of Korea

Purpose: Absolute discontinuation of tobacco use is the only strategy proven to prevent the progression of Buerger disease. However, patients need surgical treatment when they are suffering from severe resting pain and claudication. We report successful hybrid operation including femoro-popliteal bypass and angioplasty in Buerger's disease.

Case: A 50-year-old male patient was referred to our hospital for treatment of left leg pain. He had already diagnosed as Buerger's

disease and had pedal bypass 7 years ago. However, he was suffering from intolerable leg pain for 5 years. The angiography revealed total occlusion in left femoropopliteal and infrapopliteal arteries including corkscrew collateral arteries. Femoropopliteal bypass and successful angioplasty in tibioperoneal trunk secured sufficient in-flow. The postoperative doppler pulse of posterior tibial artery and dorsalis pedis was good and patient was discharged 8 days after surgery without any complication. 6 month follow up CT scan revealed patent blood flow and severe pain was dramatically disappeared.

Conclusion: Hybrid treatment including bypass and angioplasty may give feasible option to treat Buerger's disease.

0129

Thoracoabdominal Approach for Visceral Artery Aneurysm with a Common Celiomesenteric Trunk, Caused by Median Arcuate Ligament Syndrome

Hitoshi Inafuku¹, Yukio Kuniyoshi¹, Satoshi Yamashiro¹, Yuichi Totsuka¹, Katsuya Arakaki², Yuji Morishima²

¹University of the Ryukyus, Okinawa, Uehara, Nishihara, Japan

²Urasoe General Hospital, Okinawa, Urasoe, Japan

We report an exceptionally rare case of a celiomesenteric anomaly with visceral aneurysm, caused by median arcuate ligament syndrome and successfully treated by surgically bypassing from descending aorta to common hepatic and splenic artery bypass through a thoracoabdominal approach. A 37-year-old woman was referred to our institution with abdominal visceral artery aneurysm detected on abdominal echography at a medical checkup. Enhanced multi-detector computed tomography (MDCT) demonstrated a saccular aneurysm originating from the celiac artery near the bifurcation of the celiomesenteric trunk. The common hepatic and splenic arteries originated from this aneurysm. Moreover, the orifice of the celiomesenteric trunk was stenosed by the median arcuate ligament. There was no thrombus and atherosclerotic change in the aneurysmal wall. Segmental arterial mediolysis or fibromuscular dysplasia with median arcuate syndrome was suspected, but no other visceral aneurysms were detected on MDCT. The connection between the pancreaticoduodenal artery and superior mesenteric artery (SMA) seemed poor. Transcatheter coil embolization was not indicated due to the neck of the aneurysm was wide and it was located near the bifurcation. We therefore performed aneurysmectomy including the partial wall of the SMA with simultaneous bypass of the common hepatic and splenic artery. Stenosis of the celiomesenteric trunk was also relieved by dissecting the median arcuate ligament. These procedures were performed through a thoracoabdominal approach under a right femoro-femoral (F-F) partial bypass for two reasons. First, the descending aorta was small and would have been totally occluded by partial clamping. Second was the risk of unexpected bleeding during exposure of the aneurysm, which was located just behind the pancreas. The defect in the

SMA was patch augmented using saphenous vein. Pathological findings of the aneurysmal wall were that fibromuscular dysplasia in the intima and degeneration in the media without inflammatory and atherosclerotic changes.

0146

Traumatic Tearing of Common Femoral Artery and External Iliac Vein Treated by Hybrid Operation

Hyuk Jae Jung, Ji Ho Lee, Sang Su Lee

Pusan National University Yangsan Hospital, Yangsan, Gyeongnam, Republic of Korea

Endovascular treatment is an important adjunct to open surgical treatment of vascular injuries in trauma case. It has advantages of operative time saving, decreasing blood loss, and short hospital stay. It also permits immediate control of hemorrhage and facilitate other open surgical repair. We report a rare trauma case of coexisting common femoral artery and external iliac vein tearing caused by falling down from the horse.

Case > A 75-year-old male patient was brought to emergency room with an obvious right thigh swelling, significant pain, and low blood pressure. The horse flipped over and landed on top of the patient. The CT scan showed active bleeding on right common femoral artery (CFA) and massive hematoma in right groin area. The preoperative angiography under mobile C-arm revealed tearing of right common femoral artery on the emergency operation. Using balloon angioplasty, ballooning of external iliac artery provided blockage of hemorrhage. The Viabahn Endoprosthesis (Gore & Associates, Flagstaff, AZ) was deployed through contralateral and retrograde approach at the tearing of right CFA. The final angiography showed complete covering of tearing site. The vertical incision of right groin revealed tearing on external iliac vein (EIV) and massive hematoma around vessel. The direct anastomosis on tearing EIV could provide control of hemorrhage. The patient was survived from severe trauma and can ambulate by hybrid operation. In our experience, the hybrid operation may offer proper treatment of vascular injuries in advantage of less blood loss, rapid operation time, and early ambulation.

Endovascular Treatment for Infrainguinal Chronic Total Occlusions and Severe Stenoses Using the High-frequency Vibrational Energy Device

Masahiro Nakamura, Toshifumi Kudo, Yohei Yamamoto, Sotaro Katsui, Masato Nishizawa, Kimihiro Igari, Shinya Koizumi, Takahiro Toyohuku, Yoshinori Inoue

Tokyo Medical and Dental University, Tokyo, Japan

Background and Objectives: Endovascular treatment (EVT) for infrainguinal chronic total occlusions (CTOs) and severe stenoses are technically challenging. It can be seen that a guide wire crosses the lesion, but the balloon can't cross the lesion especially at the calcified lesion. In April 2014, we started to use the high-frequency vibrational (20 kHz) energy device (CROSSER®) to fragment fibrous and/or calcified atherosclerotic plaque and penetrate CTOs. The aim of this study is to review our early experiences to treat with crosser system, and to assess the efficacy and safety of the device.

Methods: The patients treated with Crosser system in the first month were intended. In each patient, after using the CROSSER® with over-the-wire technique, standard EVT was done with balloons and/or stents.

Results: The device was used in 12 lesions of 10 patients. The patients were eight men and two women, and mean age was 70.4 (range 58–80). Five cases had diabetes, four cases had chronic renal failure on hemodialysis. The Rutherford category was 6 in a case, 5 in four cases, 4 in two cases, 3 in a case, and 1 in a case. Five lesions were located in the superficial femoral artery, one in the popliteal artery, two in the peroneal artery, two in the anterior tibial artery, and one in the posterior tibial artery. Eight lesions were CTOs, and four were severe stenosis. The mean length of lesions was 59.1 centimeters (range 50–150). In all cases, the lesions were successfully crossed. No perforation nor distal embolization was observed.

Conclusions: In our experience, the CROSSER® system was safe and effective. It should be necessary to assess the safety and efficacy of the new system with more cases.

Case Report on Treatment of a True Axillary Artery Aneurysm Associated with Distal Thrombosis in a Professional Basketball Player

Kwok Fai Cheung, Hon Cheung Hui, Wai Yin Lo, Kwong Man Chan, Leung Sing Ho

Princess Margaret Hospital, Hong Kong, Hong Kong

Isolated traumatic true axillary artery aneurysm is rare and generally occurs with repetitive blunt trauma. We report a top-league basketball player in Hong Kong presented with left upper limb

ischemia. Computer tomographic angiogram and digital subtraction angiogram revealed a long segment of complete arterial occlusion at the left proximal brachial artery, whereas the left upper limb is mainly supplied by collateral arteries. There was also a 1.5 cm × 1.3 cm aneurysm with thrombus inside arising from the distal left axillary artery with a wide neck. Emergent exploration, excision of aneurysm and distal embolectomy were performed. He fully recovered postoperatively. The clinical implication of this presentation is the importance of prompt diagnosis, good outcome with emergent vascular intervention.

Management of Mycotic Femoral Pseudoaneurysm in Intravenous Drug Abuser—Single Institute Experience

Zhimin Lin¹, Jack Kian Ch'ng², Benjamin, Soo Yeng Chua²

¹National University of Singapore, Yong Loo Lin School of Medicine, Singapore, Singapore

²Singapore General Hospital, Singapore, Singapore

Aims: Mycotic femoral artery pseudoaneurysm (FAP) is a well-recognized complication in intravenous drug abusers (IVDA). Surgical management remains controversial, ranging from ligation with debridement to extra-anatomical bypass. We present our experience and outcome in this subgroup of patients.

Methods: The medical records of all patients, who are IVDA, presenting to Singapore General Hospital with FAP, between January 2004 and December 2013 were reviewed retrospectively. Demographic data and pre-, intra- and post-operative variables were extracted. The primary outcome of the study was limb salvage rate. Complications and 30-day mortality were our secondary outcomes.

Results: 17 IVDA (16 male and 1 female) presented to our department with FAP over the last decade. 16 patients presented with unilateral FAP, while the remaining patient in our series presented initially with a unilateral pseudoaneurysm and then for a second time with contralateral FAP. Mean age was 45.6 years old (range: 36–58 years). 8 had a positive viral status for hepatitis C. Commonly injected drugs included Midazolam and Buprenorphine. Most common bacteriology isolated from the wound was staphylococcus aureus. The diagnosis of FAP was confirmed clinically in 10 patients, while the other 6 patients were diagnosed on computer tomographic angiography. The most frequent presentation was a painful groin swelling (12 patients). Sixteen cases were managed with arterial ligation and debridement of the necrotic tissue. One patient required revascularization in the form of obturator bypass; the patient eventually underwent a through-knee amputation before finally passing on. Another patient required a high above-knee amputation due to poor perfusion to the limb. The limb salvage rate is 88.2% and 30-day mortality is 94.6%.

Conclusions: Management by ligation and debridement is adequate and well-tolerated in the majority of drug-abusing patients diagnosed with FAP.

Blue Toe Syndrome: A Rare Presentation of Atrial Myxoma

Norhafiza Abdul Rahman¹, Ahmad Faizal Othman¹, Ahmad Khadri Awang²

¹Vascular Unit, Department of Surgery, International Islamic University Malaysia, Kuantan, Pahang, Malaysia

²Cardiothoracic Unit, Department of Surgery, International Islamic University Malaysia, Kuantan, Pahang, Malaysia

Blue toe syndrome is a condition in which patient presented with cyanotic toe caused by fibrino-platelet micro-emboli occlusion of the small digital arteries. Atrial myxoma is the most common primary cardiac tumour. Most patients with atrial myxoma present with emboli to blood vessel of the brain causing ischaemic stroke. We report a case of a 37 year old gentleman who presented with blue toe syndrome affecting right second and fourth toes without any symptoms and signs of cardiac insufficiency or other embolus elsewhere. Further investigation and echocardiography revealed a mass over the left atrium that lead to the provisional diagnosis of atrial myxoma. He underwent excision of the left atrial myxoma with repair of interatrial septum within the same admission. Surgery was uneventful and he was discharged home well.

0221

Comparison Between Surgical Bypass and Percutaneous Transluminal Angioplasty for the Treatment of Peripheral Arterial Disease of Lower Limbs in a Locoregional Hospital in Hong Kong

Lok Ping Si, Kin Leung Hui, Wai Tat Chan

Department of Surgery, Ruttonjee Hospital, Hong Kong, Hong Kong

Background and Objectives: Surgical bypass is the gold standard for treating peripheral arterial disease (PAD) of the lower limbs. Percutaneous transluminal angioplasty (PTA) has emerged in recent years as an alternative for revascularization of the diseased lower limb arteries. This retrospective cohort serves the purpose of showing the non-inferiority of PTA in treating lower limb PAD in our institution.

Methods: Patients received surgical bypass and PTA for symptomatic PAD of lower limbs in Ruttonjee Hospital from 1/1/2008 to 31/12/2013 inclusively were identified and their medical records reviewed.

Results: 48 patients with 51 limbs were included in this retrospective cohort. 12 limbs received surgical bypass and 39 received PTA. Towards the end of the 6-year study period, there was a trend that more and more PTA were performed. And bypass were generally reserved for more advanced disease, e.g. TASC C or D lesions. The mean post-operative length of hospital stay were not statistically different between the two modalities (20.5 days after bypass

vs 14.2 days treatment after PTA, $p = 0.25$). Limb salvage (avoidance of below-knee amputation (BKA) or above) rates were comparable (83.3% vs 76.9%, $p = 0.49$). 3-year patency rates were also comparable for both treatment modalities (75% vs 75.8%, $p = 0.62$). Mean post-operative improvement in ankle-brachial index (ABI) was similar in both groups (0.28 vs 0.36, $p = 0.67$). There were neither severe post-operative complications nor 30-day mortality after bypass surgery or PTA.

Conclusions: PTA in our institution achieved comparable limb salvage rate, patency rate and improvement in ABI when compared to surgical bypass. PTA did not imply additional morbidity and mortality. It should be considered as the primary treatment modality for lower limb PAD whenever possible, given its intrinsic less invasive nature.

0222

Percutaneous Transluminal Angioplasty for the Treatment of Lower Limb Peripheral Arterial Disease: A Six-year Experience in a Locoregional Hospital in Hong Kong

Lok Ping Si, Kin Leung Hui, Wai Tat Chan

Department of Surgery, Ruttonjee Hospital, Hong Kong, Hong Kong

Background and Objectives: Percutaneous transluminal angioplasty (PTA) has emerged in recent years for treating peripheral arterial diseases (PAD) of lower limbs and is gaining more popularity due to its less invasiveness when compared to open bypass surgery, which is the gold standard of PAD treatment. This retrospective cohort serves the purpose of reviewing our performance in this treatment modality and compare with international standards. Also to identify risk factors for PTA failure and limb loss (below-knee amputation (BKA) or above required).

Methods: Patients received PTA for symptomatic PAD of lower limbs in Ruttonjee Hospital from 1/1/2008 to 31/12/2013 inclusively were identified. Their medical records were reviewed.

Results: 38 patients (42 limbs) received PTA for symptomatic lower limb PAD during the 6-year study period. 2 patients (3 limbs) were excluded as they were lost to follow up. Technical and clinical success rates were 84.6% and 75.8% respectively. Limb salvage (avoidance of BKA or above) rate after technically successful PTA was 76.9%. Mean improvement in ABI was 0.36 (95% CI 0.24–0.48, $p < 0.01$). Complete occlusion of the diseased vessel was associated with technical failure ($p = 0.012$). Presence of gangrene at initial presentation was the only identified risk factor for limb loss ($p = 0.001$). Common cardiovascular risk factors such as hypertension, diabetes, history of ischaemic heart diseases and any combination of these were not associated with limb loss ($p > 0.05$). No re-interventions were needed after successful PTA after a mean follow-up period of 37.6 months. The 3-year primary patency rate was 75.8%.

Conclusions: PTA as primary treatment of lower limb PAD in our institution achieved promising results in terms of success rate,

limb salvage rate and 3-year patency, which are all comparable to international standards. PTA should continue to be employed to treat lower limb PAD.

0237

STAT4 is Required for Homocysteine-Induced Proliferation and Migration of Human Aorta Smooth Muscle Cell via MCP-1 Secretion

Weibin Huang, Lei Lu, Hui Xie, Meng Ye, Ji-wei Zhang, Lan Zhang

Department of Vascular Surgery, Renji Hospital, School of Medicine, Shanghai Jiaotong University, Shanghai, China

Background/Aims: Homocysteinaemia is an important independent risk factor for atherosclerosis. We had previously demonstrated that genetic knockout of signal transducer and activator of transcription 4 (STAT4) mediated by specific siRNA inhibited the proliferation of vascular smooth muscle cells (VSMCs). The aim of the present study was to investigate the effects of STAT4 pathway on homocysteine (Hcy)-induced proliferation and migration of VSMCs.

Methods: Human aorta VSMCs was cultured with Hcy (0–0.5 mmol/L). The cells were infected with recombinant lentivirus containing either STAT4 or LacZ gene or DMEM alone in vitro. Meanwhile, MCP-1-neutralizing antibody was used to further investigate the functions of STAT4 pathway in VSMCs activation. The effects of Hcy on VSMCs proliferation and migration were assessed by a cell counting kit and a modified Transwell chamber system, respectively. Protein expressions of total STAT4 and phosphorylated STAT4 (p-STAT4) were examined by Western blot. ELISA assay was performed to determine MCP-1 level.

Results: Our results showed that STAT4 protein was expressed in human aorta VSMCs and activated in response to Hcy stimulation. The activation of STAT4 pathway was accompanied by increased proliferation and migration of human aorta VSMCs. Ectopic expression of STAT4 protein effectively increased Hcy-induced proliferation and migration and the expression of MCP-1, while small molecule-mediated inhibition of MCP-1 expression significantly decreased the above effects.

Conclusions: Our study indicates that STAT4 activation contributes to Hcy-induced proliferation and migration of human aorta VSMCs, and these effects may be mediated by MCP-1 activation.

0244

Successful Treatment of Aberrant Splenic Artery Aneurysm with a Combination of Coils Embolization and Covered Stents: A Report of Three Consecutive Cases and Review of the Literature

Weimin Zhou, Jiehua Qiu, Qingwen Yuan, Jixin Xiong

Department of Vascular Surgery, The Second Affiliated Hospital of Nanchang University, Nanchang, China

A splenic artery arising from the superior mesenteric artery (SMA) is an uncommon anatomical variant which may be associated with an aneurysm. Published such cases have been managed with surgery, combined surgical/endovascular or endovascular techniques, with the latter involving embolization of the aneurysm with coils. We report three consecutive cases of aberrant splenic artery aneurysm that the aberrant splenic artery was embolized with coils and the SMA was excluded with a covered stent. A follow-up computed tomography performed 10 to 12 months after the covered stent placement showed persistent exclusion with marked shrinkage of the aneurysm sac. The authors believe although early results are promising, further careful follow-up will be needed to determine the long-term clinical efficacy, safety and applicability of this approach.

0281

Endovascular retrograde recanalization in critical limb ischaemia using the “SAFARI” technique: a single-centre experience

Jia Sheng Tay, Sulaiman Bin Yusof, Siok Siong Ching, Yin Kai Tan, Wei Cheong Kum

Department of Surgery, Changi General Hospital, Singapore

Background and objectives: To evaluate the applicability and outcome of the SAFARI technique for endovascular retrograde recanalization of critical limb ischaemia (CLI) patients with chronic total occlusions (CTOs) in an Asian population.

Methods: We conducted a single-centre based retrospective review of CLI patients with CTOs who had undergone endovascular retrograde recanalization using the SAFARI technique between May 2010 and February 2013.

Results: Forty CLI patients with CTOs underwent endovascular intervention. The median age was 71 years. 67.5% were male and Chinese accounted for 65% of the patients. 55% were in Rutherford category 6, 37.5% in category 5 and 7.5% in category 4. Antegrade-retrograde access was performed via the femoral artery in 39 cases and the brachial artery in 1 case for the proximal puncture, and the following arteries for the distal puncture: superficial femoral, n = 4 (10%); popliteal, n = 4 (10%); anterior tibial, n = 12 (30%); dorsalis pedis, n = 9 (22.5%); peroneal, n = 4 (10%); and posterior tibial, n = 7 (17.5%). The double-balloon technique was

used in 5 cases (12.5%). Technical success was high at 92.5% (n = 37).

After intervention, 25% (n = 10) had below knee triple vessel runoff, 52.5% (n = 21) had double vessel runoff and 15.0% (n = 6) had single vessel runoff. Stenting for target vessel dissections was required in 12 patients. There were 2 cases of significant bleeding; one common femoral artery pseudoaneurysm was treated with ultrasound-guided thrombin injection and another case of distal puncture site bleeding only required compression.

Conclusions: The SAFARI technique is safe with high technical success rates and acceptable outcomes in Asian CLI patients with CTOs.

(F) Thoracic Aorta Disease

0007

Aortic Coarctation Treated with Self Expandable Stent Graft

Funda Yildirim, Alper Ozbakaloglu, Ozlem Karaaslanyuksel, Taner Kurdal, Mustafa Cerrahoglu, Ihsan Iskesen, Omer Tetik

Celal Bayar University, School of Medicine, Department of Cardiovascular Surgery, Manisa, Turkey

Coarctation of the aorta describes the congenital narrowing of any part of the descending thoracic or abdominal aorta. However it typically refers to narrowing of the proximal thoracic aorta at the level of the ductus or ligamentum arteriosum. Surgical treatment has been used for more than 50 years and serious complications may be seen. Recently endovascular techniques becomes more widespread especially for adult patients because these techniques are less invasive than surgery.

We presented a 19 year old patient with juxtaductal aort coarctation. Physical examination revealed no femoral pulses. The upper extremity blood pressure was measured 160/80 mmHg and 3/6 systolic murmur was heard over precordial and interscapular areas. The laboratory tests was normal. The echocardiographic investigation was showed no anomalies. The coarcted segment was observed with angiographic study.

We planned to implant self expandable stent-graft (Medtronic Valiant Thoracic Stent Graft with the Captiva Delivery System; made in USA). At the angiography laboratory, endovascular aortic stent-graft was implanted via right femoral artery with direct small femoral incision. Left femoral artery exposure was used for angiographic control views. We implanted the graft with 22 mm in radius and 112 mm in short and 124 mm with anchoring system in length. Then we dilated narrowed stent segment by balloon catheter (Medtronic Reliant Stent Graft Balloon catheter; 12 F).

After the procedure the patient had a significantly dilated aorta distal to the previously coarcted segment. One stent graft was enough to treat coarctation. There were no access site complica-

tions. We observed no complications, blood pressure was decreased to normal and the patient was discharged without any problem.

0028

Gigantic Chronic Mega-aneurysm of Aorta with Type 1 Dissection

Cengiz Ozbek², Ufuk Yetkin¹, Koksal Donmez¹, Kazım Ergunes¹, Nagehan Karahan³, Ali Gurbuz¹

¹Department of Cardiovascular Surgery, Katip Celebi University Izmir Ataturk Training and Research Hospital, Izmir, Turkey

²Department of Cardiovascular Surgery, Tepecik Training and Research Hospital, Izmir, Turkey

³Department of Clinical Anesthesiology, Katip Celebi University Izmir Ataturk Training and Research Hospital, Izmir, Turkey

Background: An aortic aneurysm is an enlargement of a weakened area of the aorta. Aneurysms which involve the ascending aorta, aortic arch and descending thoracic aorta. Still a serious problem and most important factor for increasing survival is early diagnosis. Mortality is reduced due to better screening techniques and modern surgical approach.

Methods: A 76 years old male patient admitted to our clinic with dissecting gigantic ascending aorta aneurysm. One year before admitting to our clinic, he had referred to another clinic with shortness of breath and during etiologic research gigantic dissecting ascending aorta aneurysm was diagnosed. Transthoracic echocardiography revealed as 14 mm and ascending aorta aneurysm with visible dissection flap inside. Also, aortic valve insufficiency was 2–3°, ascending aorta diameter was 105 mm and pulmonary artery pressure was 45 mmHg. Thoracic computerized tomography showed ascending aorta aneurysm with a diameter of 11 cm. Afterwards; a percutaneous coronary angiography was performed and coronary arteries were assessed to be normal. In the same session aortography revealed 3° aortic insufficiency and dissecting ascending aorta aneurysm.

Results: Patient underwent surgery under general anesthesia. Gigantic dissecting ascending aorta aneurysm with approximately 130 mm diameter was explored. Aneurysm was reaching to arcus segment. Bentall de Bono procedure was performed with a composite graft including 27 no St Jude mechanical aortic valve (distal anastomosis was performed with open technique while body temperature was reduced to 18°C). Tubular Dacron graft was used for hemiarch replacement. Afterwards, both grafts were end-to-end anastomosed. Due to suspicion of myocardial edema, patient was taken to cardiovascular intensive care unit with open sternum. 24 hours later mediastinum was re-explored and the incision was closed appropriately.

Conclusions: We believe that, mortality rates of dissecting aortic aneurysms may be reduced with modern surgical techniques applied to surgical practice, early diagnosis and optimal timing for treatment.

Our Successful Combined Surgical Strategy with Our Modified Cerebral Perfusion Method in a Patient with Incidentally Found Type 2 Aortic Dissection at Coronary Artery Bypass Surgery

Ufuk Yetkin¹, Habib Cakir¹, Nagehan Karahan²,
Ersin Celik¹, Koksal Donmez¹, **Ali Gurbuz¹**

¹Department of Cardiovascular Surgery, Katip Celebi University Izmir Ataturk Training and Research Hospital, Izmir, Turkey

²Department of Anesthesiology, Katip Celebi University Izmir Ataturk Training and Research Hospital, Izmir, Turkey

Aortic dissection, intramural hematoma, and symptomatic penetrating aortic ulcer are all considered in acute aortic syndrome. Penetrating aortic ulcer is the ulceration of atherosclerotic lesion that is passing through the internal elastic laminate and proceeding to media layer.

A 77 years old male patient admitted to our hospital for chest pain complaint that had started 10 days before his admittance. His coronary angiography revealed multi-vessel, serious coronary artery disease. His echocardiographic examination was normal except pulmonary hypertension (30 mmHg) and mild aortic dilatation (40 mm diameter). Preoperative chest disease consultation was requested. Multiple drugs were added to patient's medication for high-risk chronic obstructive pulmonary disease.

Patient underwent operation with these symptoms. After performing median sternotomy and pericardiotomy, ascending aorta was visualized. Dissection was evident in ascending aorta and intrapericardial fresh thrombi were observed. Right femoral artery was explored immediately and arterial cannulation for cardiopulmonary bypass was carried out from here. Unicaul venous cannulation was performed from right auricle by using a two stage cannula. Patient was cooled to 26°C and total circulatory arrest was initiated. Aortic lumen was severely degenerated and penetrating aortic ulcers were evident. After suspension of innominate artery, retrograde cannula with balloon that is selectively used for coronary sinus perfusion, was used for selective cerebral perfusion. Cerebral perfusion was performed with this modified technique. Proximal and distal anastomosis lines were reinforced with Teflon felt strips by using sandwich technique. A 28 mm Dacron tubular graft was interpositioned between supracoronary aortic region and hemiarch. LAD artery and posterior descending branch of right coronary artery were grafted separately by using native saphenous vein graft. Operation was terminated with mild inotropic support.

Immediate diagnosis and treatment of acute aortic dissection may increase survival rates. Surgical treatment is the only option in any patient at whom proximal aorta is included.

Surgical Treatment of Right-sided Aortic Arch Aneurysm Arising from a Kommerell's Diverticulum with an Aberrant Left Subclavian Artery

Koki Yokawa, Takuo Nomura, Mitsuru Asano

Seirei Mikatahara Hospital, Hamamatsu/Shizuoka, Japan

A 67 year-old man admitted to our institution due to stroke by cardiogenic embolism. A systemic work-up showed mild mitral regurgitation and chronic atrial fibrillation. In addition, supra-aortic malformation and aortic aneurysm were revealed.

The aortic arch and descending aorta were right sided. The first branch of the right arch became the left common carotid artery, the 2nd right carotid artery and the 3rd right subclavian artery. The descending aorta gave origin to the retroesophageal left subclavian artery as the 4th branch.

Three months after rehabilitation, the operation was performed. Under differential lung ventilation, the aortic arch was approached through right intercostal thoracotomy. Right recurrent nerve and the phrenic nerve located next to aortic arch. Therefore, these nerves were pulled away from aortic arch without resection. Cardiopulmonary bypass was established with femoral artery perfusion and femoral vein drainage. The aorta was clamped at aortic arch between 2nd and 3rd branch, and at middle of descending aorta. Graft replacement was performed between distal arch and descending aorta with reconstruction of left subclavian artery.

After the operation, phrenic nerve and recurrent nerve dysfunction was occurred, however, getting better.

Surgery for Acute Type A Aortic Dissection in Octogenarians

Hideyuki Kunishige, Yoshimitsu Ishibashi, Masakazu Kawasaki, Nozomu Inoue

National Hospital Organization Hokkaido Medical Center, Sapporo, Hokkaido, Japan

Background and Objectives: Cardiac surgeons are faced with treating an increasing number of elderly patients with the progressive aging of Japanese populations. Surgery with acute type A aortic dissection is commonly avoided or denied because of the high surgical morbidity and mortality reported in elderly patients. We compared clinical outcomes between octogenarians and those aged less than 80 years who underwent surgical repair at National Hospital Organization Hokkaido Medical Center.

Methods: We reviewed the records of 11 consecutive patients aged 80 years or older (mean age 83 years, range 80–87 years) who underwent operations for acute type A dissection, comparing with 82 concurrent patients aged less than 80 years between January

2000 and December 2013. Hospital mortality, based on our overall experience with all patients operated on for acute type A aortic dissection during the period of the study, were developed by means of multivariate logistic regression with intraoperative and postoperative variables used as independent predictors of outcome.

Results: Hospital mortality in octogenarians was 91%. The 2 groups had similar preoperative characteristics, but the octogenarians group were more likely to have undergone a Hemiarth procedure (52.4% vs 63.6%, $P < .001$), shorter cardiopulmonary bypass times (248.9 ± 50 minutes vs 207.0 ± 70 minutes, $P = .025$), longer mean hospital stay (24.4 days vs 63.6 days, $P < .001$) and higher hospital transfer rate (24.4% vs 63.6%, $P < .001$).

Conclusions: Surgery for acute type A aortic dissection should be offered to octogenarians because careful postoperative follow-up allows early identification of potentially risk factor and permits operation in octogenarians with an acceptable mortality rate. Meticulous operative technique depending on the individual pathophysiology of the aorta is required at the time of operation.

0046

The Timing of Thoracic Endovascular Aortic Repair for Aortic Dissection

Takashi Hashimoto, Noriyuki Kato, Takatoshi Higashigawa, Shuji Chino

Mie University Hospital, Tsu, Japan

Backgrounds and Objectives: It has been known that chronic aortic dissection does not benefit from TEVAR compared to acute aortic dissection, especially as to remodeling of the aorta. This survey is to determine the most appropriate timing of thoracic endovascular aortic repair (TEVAR) for aortic dissection (AD).

Methods: Since January 2006 through October 2013, 35 patients with AD underwent TEVAR in our hospital. Among them, 29 patients could be followed-up with CT over six months. There were 18 men and 11 women. Mean age was 63.3 ± 12.4 years old (range 30–79). The diameters of the aorta, the true lumen, and the false lumen were measured at the level of the most dilated descending aorta and the diaphragm before and after TEVAR.

Results: The cut-off interval, 6 months, between the onset of AD and TEVAR was determined by means of ROC curve. Fifteen patients underwent TEVAR within 6 months of the onset (group I), while the other 14 patients over 6 months (group II). In group I, the diameters of the aorta and the false lumen at the level of the most dilated descending aorta significantly shrank compared to them in group II ($p < 0.01$). In addition, the diameter of the false lumen at the level of the diaphragm significantly shrank in group I compared to that in group II ($p < 0.001$).

Conclusions: To obtain favorable remodeling of the aorta, TEVAR should be done within 6 months of the onset of AD.

0054

Total Endovascular Repair of Aberrant Left Subclavian Artery with Kommerell's Diverticulum Using a Fenestrated Stent Graft

Takeshi Okamoto¹, Yoshihiko Yokoi², Kazuhiko Hanzawa¹, Hiroki Satou¹, Kenji Aoki¹, Osamu Namura¹, Masanori Tsuchida¹

¹Niigata University Graduate School of Medical and Dental Sciences, Niigata, Japan

²Tokyo Women's Medical University Hospital, Tokyo, Japan

We report a case in which Kommerell's diverticulum (KD) was managed successfully by total endovascular repair with a fenestrated stent graft. 68-year-old man was hospitalized for main complaint for a back pain. Computed tomography (CT) demonstrated aortic dissection (Stanford B, DeBakey IIb) and anomalies of the thoracic aorta and great vessels consistent with a right-sided and aberrant left subclavian artery (LSA) originating from the descending thoracic aorta. He left our institution after conservative medical treatment for aortic dissection once. Afterwards, his KD had an ulcer like projection (ULP) and enlarged gradually. Due to the size of the KD and the potential for rupture, he elected to undergo total endovascular repair with a fenestrated stent graft. Our plan was to interrupt a blood flow to a KD. The cervical branches diverged in order of left carotid artery (LCA), right carotid artery (RCA), right subclavian artery (RSA) and KD from ascending aorta. Stent graft had pre-curved structure with fenestration for RCA and RSA was deployed from distal of the orifice of LCA to descending aorta to cover the orifice of KD. Next, we performed embolization to distal of KD. Follow-up CT showed the ULP disappeared and no dilatation of KD. He discharged 12 days after the operation. The treatment for KD usually is based on open or hybrid repair, however, fenestrated stent graft may offer an alternative approach.

0074

Total Debranching TEVAR for Distal Aortic Arch Aneurysm with No Access Routes from the Femoral Artery

Hiroaki Yusa, Imun Tei, Shou Tatebe, Makoto Taoka, Tomoaki Tanabe, Eiichi Tei

Ayase Heart Hospital, Tokyo, Japan

Background: Conventional aortic arch repair is a high-risk procedure, particularly for high-risk patients. Recently, endovascular repair of aortic arch aneurysm is an induced procedure. This technique is less invasive with low morbidity and mortality for high-risk patients.

Method and Results: A 76-year-old man had undergone surgical open repair of the infectious abdominal aortic aneurysm through a median laparotomy 8 years ago. Abdominal aorta was resected

and reconstructed lower extremities blood flow by extra-anatomical bypass from right axillary artery to bilateral femoral arteries. A computed tomography (CT) scan showed a distal aortic arch aneurysm just below the left subclavian artery with a maximum diameter of 60 mm. We selected endovascular intervention because open surgical repair is high risk surgery. However, it was difficult to treat endovascular repair with accessed from iliac and femoral arteries. We selected to be accessed from the ascending aorta after total debranching. Under the general anesthesia, median sternotomy was made. Total debranching of supra-aortic vessels was performed without cardiopulmonary bypass with a side-clamp on the ascending aorta. After the total debranching, Gore C-TAG placed from Zone 0 to Th6. Post operative course was uneventful without any complication. Post operative enhanced CT revealed no evidence of endoleaks.

Conclusion: We report a case of hybrid debranching and thoracic endovascular aneurysm repair (TEVAR) for distal aortic aneurysm after resected abdominal aorta and an extra-anatomic bypass of the infectious abdominal aortic aneurysm. Hybrid debranching and TEVAR is the available surgical option for high-risk patient with thoracic aortic arch aneurysms.

0089

A Case Report of Stanford Type-A Acute Aortic Dissection Resuscitated by Percutaneous Cardiopulmonary Support from Cardiopulmonary Arrest due to Cardiac Tamponade Caused by Aortic Rupture

Yoshio Mori, Yukihiro Matsuno, Yukio Umeda, Hiroshi Takiya

Gifu Prefectural General Medical Center, Gifu, Japan

Percutaneous cardiopulmonary support (PCPS) is usually used for deep cardiogenic shock due to AMI, PE and so on. We report a case in whom we used PCPS for life-saving device for cardiopulmonary arrest (CPA) due to cardiac tamponade caused by aortic rupture of Stanford type-A aortic dissection. Patient was 62-Years old male who had Stanford type-A acute aortic dissection and had deep shock due to cardiac tamponade in emergency room after enhanced CT. Immediately we established PCPS via PCPS cannula inserted to the femoral artery and vein. He was moved to OR supported by PCPS. His heart rhythm became asystole on the operation table. Anesthesiologist intubated trachea and anesthetized him, and we started life-saving surgery. We performed median sternotomy and incised the pericardium, massive bleeding came from the ruptured proximal site of dissected ascending aorta. Distal side of the ruptured site was cross-clamped, and venous cannula were inserted to SVC and IVC via right atrium, routine cardiopulmonary bypass was established with the arterial inflow through arterial cannula to the left femoral artery. PCPS was discontinued. Core-cooling was started. Dissected aortic root was repaired by BioGlue and proximal aortic anastomosis with a graft (Triplex, 22 mm) was performed

first. When the rectal temperature reached 27°C, distal circulatory arrest was induced, and selective cerebral perfusion was started. Distal aortic anastomosis ("hemiarch type repair") was performed with the graft at the proximal level of the brachiocephalic artery. Total cardiopulmonary bypass time was 186 minutes. Open distal time was 46 min. Operation time was 397 min. ICU stay was 20 days due to delayed neurological recovery. Hospital stay was 3 months due to renal failure and paraplegia due to aortic dissection. He brushed with death.

Conclusion: Although rare limited condition, PCPS might be life-saving device for resuscitation from CPA due to cardiac tamponade caused by rupture of type-A aortic dissection.

0091

The Early and Late Results of Surgery for Acute Type A Aortic Dissection in Octogenarians

Atsushi Omura, Mukohara Nobuhiko, Masato Yoshida, Hitoshi Matsuda, Hirohisa Murakami, Hitoshi Minami, Tasuku Honda

Hyogo Brain and Heart Center at Himeji, Hyogo, Japan

Background and Objectives: The number of octogenarians undergoing emergency surgery for acute type A aortic dissection is increasing in the aging society. We examined the early and late results of surgery for acute type A aortic dissection in octogenarians. **Methods:** From January 2001 to April 2014, consecutive 292 patients underwent repair of acute type A aortic dissection at our institution. Of these, 56 octogenarians were retrospectively examined (male 28, mean age 83.8 ± 3.0 years. Risk factor for hospital mortality was analyzed by multiple regression model. Long term survival was assessed by Kaplan-Meier method.

Results: Preoperative shock was seen in 4 patients (7.1%). Organ malperfusion was evident in 12 patients (21.4%). Extent of graft replacement was hemiarch 47 (83.9%), partial (1.8%), and total arch replacement 8 (14.3%). Mean cardiopulmonary bypass and cardiac ischemic time was 169 and 105 minutes, respectively. The 30 day and hospital mortality was 12.5% and 16.1% (7/56, 9/56). Cerebral complication was observed in 4 patients, in which two patients had preoperative shock state. Significant risk factors for hospital mortality in overall cases were octogenarian, shock, organ malperfusion, and serum Creatinine level ≥ 2.0 mg/dl (Odds ratio 2, 95, 5.96, 3.38, and 4.26). The hospital mortality of octogenarian with and without shock or organ malperfusion was 31.5% (5/16) and 10.0% (4/40), respectively (p value 0.1). There was no hospital death in recent 5 years. During follow-up period (mean 41 ± 32 months, range 1–127 months), the 5 year survival was $65.6 \pm 9.9\%$. Initial aortic operation related problem was not observed.

Conclusions: Although octogenarian is still significant risk factors for hospital death, the early result has been improved, and that of uncomplicated patients (without shock nor organ malperfusion) were acceptable. The long term results of hospital survivors were also acceptable.

Prevention of Postoperative Spinal Cord Ischemia in Surgical Treatment of Thoracoabdominal Aortic Aneurysm

Mizuki Ando, Yuichi Totsuka, Ryoko Arakaki, Tatsuya Maeda, Yuya Kise, Hitoshi Inahuku, Moriyasu Nakaema, Takaaki Nagano, Satoshi Yamashiro, Yukio Kuniyoshi

Ryukyu University Hospital, Nishihara, Nakagami/Okinawa, Japan

Preventing postoperative spinal cord ischemia in surgical treatment of thoracoabdominal aortic aneurysm is still controversial, due to the difficulty of identifying the artery of Adamkiewicz (AKA) and associated collateral circulation. However, separating the operation into two periods and using cardiopulmonary bypass (CPB) could offer a solution to this problem by developing the collateral circulation and preventing blood loss. We encountered a 55-year-old man, who underwent replacement of the ascending aorta to the aortic arch in 2002, followed by the descending aorta in 2003, due to dissection of the aorta (DeBakey type I). He then underwent an m-Bentall operation in 2012 due to aortic regurgitation. The patient was left with thoracoabdominal aortic aneurysm below the Th7 level, and aneurysm of both common iliac arteries. Since aneurysms involved an extensive area, we separated the operation into two periods and used CPB to prevent blood loss and avoid spinal cord ischemia. We operated on the lower abdominal and common iliac artery aneurysms first, followed by the thoracoabdominal aortic aneurysm. Since computed tomography showed wide lumbar arteries at the L2 and L4 level, the decision was made to preserve and reconstruct these lumbar arteries. Preoperatively, we constructed a replacement Y-graft containing several branches feeding to the CPB, lumbar arteries, and internal and external iliac arteries. During the reconstruction, we monitored activity of the spinal cord using motor evoked potentials. The patient's postoperative course was well.

Prevention of postoperative spinal cord ischemia in surgical treatment of thoracoabdominal aortic aneurysm has remained controversial because of the anatomical complexity of the region. In cases where the AKA remains undetermined or poor development of collateral circulation is expected, separating the operation into two periods of time could allow development of the collateral circulation, and use of CPB may help prevent spinal cord ischemia by minimizing intraoperative blood loss.

Current Result of Patch Repair for Saccular Aneurysms of the Aortic Arch

Yutaka Kobayashi, Haruo Suzuki, Atsushi Kawakami

Uji-Tokushukai Medical Center, Kyoto, Japan

Background: Saccular aneurysms of the aortic arch are rare, and their surgical repair is high risk procedure with morbidity and mortality. Various techniques have been attempted, but it is where the discussion will remain what best.

Methods: We have selected the patch repair for saccular aneurysm. Indications for patch repair were determined as orifice diameter of aneurysm being less than 1/3 of the total circumference of the aorta. We report our experience of patch repair for saccular aneurysm of the aortic arch. Three patients were performed patch repair with saccular aneurysm. Right anterolateral thoracotomy was performed in all patients. Subclavian or femoral artery and femoral vein were cannulated. They used deep hypothermia (20°C) and circulatory arrest. We did not use cardioplegia and cerebral perfusion.

Results: There was no operative death. Stroke was not found in all patients. The mean of cardiopulmonary bypass time was 240 minutes, ventricular fibrillation time was 39 minutes and circulatory arrest time was 28 minutes. The post-operative course was uncomplicated in all patients.

Conclusions: Repair of saccular aneurysm of the aortic arch by patch repair should be considered, but a study of adaptation should be done with carefully.

Endovascular Treatment of Descending Aorta Stenosis in Takayasu's Arteritis

Sang Jun Park¹, Hojong Park¹, Jae Chol Hwang², Young Woo Seo², Ji Sun Oh³, Hong Rae Cho¹

¹Department of Surgery, University of Ulsan College of Medicine, Ulsan, Republic of Korea

²Department of Radiology, University of Ulsan College of Medicine, Ulsan, Republic of Korea

³Department of Internal Medicine, University of Ulsan College of Medicine, Ulsan, Republic of Korea

Background: Endovascular techniques as arterial stenosis treatments in Takayasu's arteritis have lacked evidence yet. Noteworthy is the fact that surgical approach for descending aorta stenosis is a high risk way when it gets in return. The purpose of this paper is to present a successful endovascular treatment for descending aorta stenosis in Takayasu's arteritis here.

Cases: First case was a 47 year-old man with disable claudication and renovascular hypertension. His initial ankle-brachial index (ABI) was 0.75/0.71 and his left brachial pressure was about 40 mmHg lower than right one. Stent grafts were inserted in his diffuse ste-

notic descending aorta and balloon expansion was followed. His ABI was 1.18/108 and he could reduce hypertension medications after the procedure. Second case was a 49 year-old woman with disable claudication. Her initial ABI was 0.49/0.45. We inserted stent in her focal stenotic descending aorta. Her final ABI was 0.95/0.92. They have been well without symptom recurrence or ABI decrease for 3 years and 4.5 years.

Conclusion: Development of stent graft had expanded the area of endovascular treatment. If we use stent graft, we could solve more problems of Takayasu's arteritis patients in endovascular treatment than before.

0119

Aneurysms of the Innominate Artery: Our Early and Midterm Results of 7 Series of Patients

Yojiro Koda, Atsushi Omura, Hirohisa Murakami, Hitoshi Matsuda, Masato Yoshida, Nobuhiko Mukohara
Hyogo Brain And Heart Center at Himeji, Hyogo, Japan

Background and Objective: Aneurysms of the innominate artery (AIA) are rare aortic pathology. We report our experience with early and midterm results of AIAs in the last 13 years.

Methods: From April 2001 to March 2014, we underwent surgical repair in 7 patients with an AIA. We assessed early and midterm results in these patients.

Results: The mean age was 76 ± 5 years old (male 3). The mean diameter of AIA was 45 ± 19 mm. The underlying cause of aneurysm was atherosclerosis in 5, inflammatory in 1, and infection in 1 patient. Almost AIA (6/7) was accompanied with aneurysm of aortic arch. The symptom was asymptomatic 2, chest pain 2, dyspnea 2, hoarseness 1. Two operations were performed under emergent bias. The first choice of surgery was in-situ reconstruction and graft replacement for associated aneurysms of aortic arch under antegrade cerebral perfusion with moderate hypothermia. The extent of graft replacement was interposition reconstruction of innominate artery in 1, partial arch replacement in 2, total arch replacement in 4. The concomitant procedures were 1 coronary artery bypass grafting and 1 aortic valve replacement. Mean operation, cardiopulmonary bypass, and cerebral perfusion time was 387 ± 39 , 206 ± 25 , and 81 ± 22 minutes, respectively. There was one hospital death in the emergent case for infectious aneurysm. The cause of death was multi-organ failure due to uncontrolled infection. There was no permanent neurological complication. During follow-up period (mean 25 months, range 1–92 months), there was no adverse event including overall death, neurological and aortic related event.

Conclusions: In-situ reconstruction of innominate artery and graft replacement for associated aneurysm offered favorable early and midterm results.

0157

Thoracic Periaortic Hydatid Fluid Collection Mimic Contained Hematoma of Acute Aortic Syndrome

Abdelrahman Elkaialy, Abdeulmohsen Alzakari

King Fahd National Guard Hospital/King Saud Bin Abdulaziz University for Health Sciences, Riyadh, Saudi Arabia

Hydatid disease is caused by the larval stage of *Echinococcus Granulosus* and its cyst almost affects the liver. We report a case of primary hydatid cyst of posterior mediastinum which infiltrates the wall of descending thoracic aorta. Initially, it was diagnosed by CTA as contained hematoma secondary to acute aortic syndrome for penetrating aortic ulcer and was treated by endovascular exclusion. Six months later, patient presented to emergency unit with recurrent symptom of severe chest pain and persistent thoracic cyst. MRI scan of chest diagnosed the periaortic fluid as hydatid cyst and subsequently surgical removal was done. This is the first reported case in the literature where primary mediastinal hydatid cyst infiltrates thoracic aorta with a penetrating ulcer.

0170

Cardiac Arrest Due to Dynamic Obstruction of Aorta during Course of the Acute Type B Aortic Dissection: Case Report

Kimimasa Sakata, Akio Yamashita, Katsunori Takeuchi, Koji Seki, Tatsuro Matsuo, Masaya Aoki, Kanetsugu Nagao, Naoki Yoshimura

Department of Thoracic and Cardiovascular Surgery, University of Toyama, Toyama, Japan

Background: Acute aortic occlusion is a catastrophic event requiring early recognition and intervention. Traditional causes of occlusion as saddle embolus and thrombosis are considered the most frequent causes of aortic dissection

Case: A 75 year-old male patient was admitted to the emergency department of another hospital for sudden intense back pain that happened work. Thoracoabdominal computed tomography angiography (CTA) detected a tear at aortic isthmus just below the left subclavian artery (LSA). The patient was diagnosed with acute type B aortic dissection and treated using strict measures to control the blood pressure and heart rate. The patient became anuric on the sixth day of illness and the femoral artery pulse was not palpable. CTA detected narrowing of the true lumen of the thoracic aorta due to dilatation of false lumen. Therefore the patient was conveyed to our hospital. During transfer, his blood pressure was suddenly elevated followed by cardiopulmonary arrest. After cardiopulmonary resuscitation, the heart resumed beating in several minutes. Acute thrombotic obstruction mediated by narrowing of the true lumen was regarded as a cause of the cardiac arrest. Under general anes-

thetia, a thoracic endovascular aortic repair was performed urgently. His postoperative period was uneventful and the patient was discharged from the hospital on the 14th day.

Endovascular treatment is considered an effective method for patients who cannot tolerate the surgery using artificial heart-lung machine.

Keywords: Aortic Occlusion, Aortic Dissection, TEVAR

0176

Two Stage Operations for Chronic Type B Dissecting Aortic Aneurysm with Aberrant Right Subclavian Artery and Kommerell Diverticulum: A Case Report

Katsunori Takeuchi, Akio Yamashita, Tatsuro Matsuo, Koji Seki, Masaya Aoki, Kimimasa Sakata, Kanetsugu Nagao, Naoki Yoshimura

Department of Thoracic and Cardiovascular Surgery, University of Toyama, Toyama, Japan

Background: Kommerell diverticulum (KD) with aberrant subclavian artery (ASA) is a rare anomaly of aortic arch. Aneurysms originating at ASA from the descending thoracic aorta with KD, include complications of distal embolization, compression of adjacent structures, dissection, and rupture. A number of surgical techniques have been proposed for treatment of these aneurysms.

Case: A 62-year-old man with a type B aortic dissection at onset 9 years ago. During the follow-up period in outpatient department, abdominal aortic replacement was performed for dissected abdominal aortic aneurysm one year ago. Computed Tomography (CT) revealed aortic arch with KD was expanded to 53 mm and aberrant right subclavian artery with retroesophageal segment was expanded to 23 mm in diameter. In consideration of the risk of rupture, we performed two stage operations. In the first, we performed ASA to right carotid artery transposition of distal portion. Subsequently, we performed descending aortic replacement and oversewing the aneurysmal originating at ASA. The patient had delayed postthrombotic leukoencephalopathy, but without other circulation disorder.

Performing subclavian reconstruction before the intrathoracic repair would be expected to reduce the subsequent risk of distal ischemia or subclavian steal.

Keywords: Kommerell diverticulum, aortic dissection

(G) Vascular Access

0004

Superficialization of the Deep-seated Cephalic Vein with Native Arteriovenous Fistula for Effective Hemodialysis Access Construction

Dan Song, Sangchul Yun, Seok Han

Soonchunhyang University Seoul Hospital, Seoul, Republic of Korea

Purpose: Best type of vascular access for hemodialysis is the native AVF. However, despite proper blood flow, for some patients, especially those who are obese, considerable difficulties occur with the fistula puncturing due to their deep vein position. In all of those patients, a transposition under the skin of the venous part the fistula was attempted to facilitate good cannulation.

Method: From September 2005 to August 2012, 11 patients who had superficialization and transposition of the cephalic vein of fistula in our hospital were enrolled. The patients underwent a through history and physical examination, investigation of proximal and central vein patency with fistulogram, and examination of the depth from skin with doppler ultrasonogram.

Results: The mean age was 53 years, the female was 3. The operation site were 10 patient in forearm, 16 patients in upperarm. In preoperative Doppler USG, mean depth from skin to vein were 4.3 mm (3~6.4). Late revisions with continued patency were required in 15 patients, including PTA of a stenosis in 15, open thrombectomy in two, and bypass to brachial vein due to cephalic arch stenosis in 4 cases. According to life table analysis, the primary patent rate at 1.7 years were 77%, 60%, the secondary patent rate at 1.7 years were 100% all, respectively.

Conclusion: The superficialization and transposition of cephalic vein is a relatively simple and effective method of AVF creation in patients with deeply located cephalic vein of upper limbs.

0008

Role of Prophylactic Antibiotic in the Placement of Totally Implanted Central Venous Access Port

Chong-Chi Chiu, Tsung-Chih Tsai

Department of General Surgery, Chi Mei Medical Center, Tainan and Liouying, Taiwan

Background: Role of antibiotic prophylaxis during placement of totally implanted central venous access port (Port-A) is controversial. This retrospective review compared the rate of catheter-related infection (CRI) with and without peri-operative antibiotic.

Methods: This was a single hospital study that compared patients treated with and without a single dose of antibiotic during Port-A placement. CRI were defined as a patient treated with antibiotics for port site inflammation, positive blood cultures, or suspicion of

infection that led to Port-A removal within 30-day period of implantation.

Results: Port-A were placed in 215 patients, 125 of whom (58.1%) received antibiotic prophylaxis. Surgical technique and patient demographics were similar to those patients not receiving antibiotic (90). All 7 (3.26%) CRI occurred in the non-prophylactic antibiotic group ($P = 0.418$), with 5 infections resulting in port removal.

Conclusions: Single-dose peri-operative antibiotic may decrease Port-A infection rates and should be studied further in a prospective randomized trial.

0037

Intra-operative Cephalic Vein Distensibility Can Predict Nonmaturation of Radiocephalic Arteriovenous Fistula

Mihyeong Kim¹, Youngkyun Kim², Insung Moon¹, Jiil Kim¹

¹Seoul St. Mary's Hospital, Seoul, Republic of Korea

²Daejeon Sun Hospital, Daejeon, Republic of Korea

Introduction: The approximately 30–40% nonmaturation rate of native arteriovenous fistula (AVF) is a major unsolved problem. There are few studies, however, about the risk factors for nonmaturation. We evaluated the pre-operative, intra-operative, and post-operative variables that are associated with radiocephalic AVF (RCAVF) nonmaturation.

Methods: A total of 77 subjects who underwent RCAVF creation in our hospital from November 2009 through June 2011 were included. We investigated demographic data, pre- and post-operative color duplex ultrasound (CDU), and intra-operative parameters including natural cephalic vein diameter, maximally dilated cephalic vein diameter, cephalic vein distensibility.

Results: In univariate analysis, there were significant differences in the intra-operative maximal cephalic vein diameter (4.69 ± 0.70 mm vs. 4.08 ± 0.59 mm, $p = 0.002$), intra-operative cephalic vein distensibility (IOCVD) (2.09 ± 0.31 vs. 1.80 ± 0.18 , $p = 0.000$), post-operative cephalic vein flow (1091.88 ± 535.36 ml/min vs. 644.81 ± 448.67 ml/min, $p = 0.003$), and diameter (4.37 ± 1.03 mm vs. 3.72 ± 0.84 mm, $p = 0.027$) as measured by CDU at one week post-op, between maturation and non-maturation RCAVF groups. IOCVD (Odds ratio: 0.065, 95% CI: 0.005–0.842, $p = 0.036$) was the only significant risk factor for nonmaturation in a multivariate analysis.

Conclusion: These results suggest that IOCVD is a predictor of RCAVF nonmaturation. To improve the maturation rate of native AVF, if IOCVD is low, another AVF formation should be considered, and these patients need to be followed closely postoperatively to determine the early treatment of nonmaturation.

0039

Stentgraft Insertions for Thrombosed Arteriovenous Grafts Outflow Stenosis

Petr Bachleda¹, Petr Utíkal², Martin Köcher¹, Marie Cerna², Jana Fialová²

¹LF UP, Olomouc, Czech Republic

²Fakultní nemocnice, Olomouc, Czech Republic

Background and Objectives: Prosthetic arteriovenous grafts (AVG) are indicated in patients with failed arteriovenous fistula or unsuitable vessels. The major drawbacks include thrombosis, infection risks and steal syndrome. Their overwhelming disadvantage is their propensity for venous outflow (VAG) stenosis caused by endothelial and fibromuscular hyperplasia. Stenosis at VAG is leading to thrombosis. The thrombosis can be managed surgically or by percutaneous methods with/without stenting or stentgraft insertion. Here we present a modified AVG thrombosis therapy and evaluate the efficacy of a stentgraft insertion in the treatment of venous outflow stenosis in thrombosed AVG.

Methods: Stentgrafts were deployed for treatment of failed AVG in case of significant anastomotic venous outflow stenosis after surgical graft thrombectomy. The minimal graft incision was made on the arterial site, and thrombectomy was performed with Fogarty catheters through the incision. The thrombectomy was followed by angiography, balloon dilatation and stentgraft insertion. Technical and clinical success was achieved in all patients. Regular duplex ultrasound follow-up was scheduled every two weeks after insertion; angiography was performed in 8th and 20th week. Outcome data were analyzed by Kaplan-Meier analysis.

Results: Over the period 2011–2012 fifteen patients with failed AVGs were treated successfully with stentgraft (Viabahn, GORE). There was one early thrombosis (6.6%). The estimated 6 and 12-months patency were 87.5% and 63.4%, respectively. Freedom for re-interventions was 80.2% at 6 months and 62.5% at 12 months. One patient required re-intervention for arterial inflow stenosis (6.6%), other AVG had been taken out because of infection (6.6%).

Conclusions: Stentgrafts can be successfully used to improve patency rates of thrombosed AVGs for haemodialysis. Surgical thrombectomy of clotted AVG using a Fogarty catheter is followed by subsequent angiography with intraoperative endovascular treatment of a stenotic VAG with balloon angioplasty and stentgraft placement.

Supported by the grant project IGA NT 14361, CZ.

Early Detection of Infection of Arteriovenous Graft for Hemodialysis; The Significance of Radionuclide Methods

*Petr Bachleda¹, Petr Utíkal², Jana Fialová²,
Lucie Kalinová¹, Miroslav Mysliveček²*

¹LF UP, Olomouc, Czech Republic

²Fakultní nemocnice, Olomouc, Czech Republic

Introduction and Aims: The use of arteriovenous graft (AVG) is often the last possibility to ensure the quality approach to hemodialysis (HD). Infection of AVG is a serious complication. Treatment of developed AVG infection is problematic, graft must be removed and access to HD is lost. Therefore, early detection of AVG infection is for the treatment essential. Radionuclide methods are emerging as a promising tool to detect infection of AVG. The aim of our study is to evaluate the options and benefits of PET/CT and labeled leukocytes scintigraphy (LLS) in early detection of AVG infection.

Methods: Between 7/2010–12/2013 were 63 AVG inserted in 56 patients. During the first year since the insertion of AVG patients were monitored by protocol - clinical, bacteriological and laboratory. PET/CT and LLS were performed after 10, 30 and 50 weeks from the insertion of AVG.

Results: From the group of 56, 10 patients died, 5 has to be excluded for non-compliance, in 11 patients there were repeated graft closures and in 2 patients we had to remove the prosthesis due to infection progression. Annual monitoring was closed in 23 AVGs. PET/CT and LLS showed infection in 10 AVGs. All these patients were given antibiotic treatment according to microbiological findings. Clinical manifestations of developed infection occurred in 3 AVGs, both grafts had to be removed. In 7 patients was AVG infection treated successfully and access to HD rescued.

Conclusions: Evaluation with PET/CT and LLS seems to be sensitive for the detection of early AVG infection with poor or no clinical signs. As for practical use it is necessary to specify the frequency and timing of radionuclide controls. We estimate that 20 and 40 weeks from the insertion of AVG is the best timing for radionuclide control.

The project was supported by grant IGA Ministry of Health 11062-5/2010.

Inferior Vena Cava as a “Run-of Conduit” for Arteriovenous Grafts in Selected Hemodialysis Patients: Is it Still Relevant?

*Igor Rabin¹, Leonid Feldman², Laurian Copel³,
Jonathan Lorber¹, Arie Bass¹*

¹Vascular Surgery Department, Assaf Harofeh Medical Center, Affiliated to Sackler Faculty of Medicine, Tel-Aviv University, Zerifin, Israel

²Nephrology Department, Assaf Harofeh Medical Center, Affiliated to Sackler Faculty of Medicine, Tel-Aviv University, Zerifin, Israel

³Department of Radiology, Assaf Harofeh Medical Center, Affiliated to Sackler Faculty of Medicine, Tel-Aviv University, Zerifin, Israel

Introduction: The rate of patients in whom usual anatomic sites of arteriovenous fistula (AVF) or arteriovenous graft (AVG) have been exhausted is constantly increasing. Unorthodox surgical approach, creating “exotic AVG”, may offer the sole solution in these patients. We hereby describe our experience construction exotic vascular access (EVA), with using of inferior vena cava (IVC) as venous outlet.

Patients and Methods: During 8 years period, we performed 781 operations of vascular access for patients with end stage renal failure, 7 patients were treated by EVA. In all patients the inferior vena cava (IVC) was used as the venous outlet, while the arterial inflow varied.

Pre operative data included full clinical, sonographical and radiological examination. An emphasis was put on asserting IVC patency, utilizing duplex, ascending venography or CT venography.

Surgical Technique: Arterial inflow was taken from the femoral artery in the groin - in 4 patients, from the arterial limb of a previously placed femoral AV graft in one patient and from the axillary artery - in two patients.

Transperitoneal approach to the infrarenal IVC was used in 2 patients and retroperitoneal approach was used in 5 patients.

Results: 3 of these patients are alive with up to 87 month patency recorded. Of the 4 patients deceased, 3 patients died on post operative day 4–11, 1 patient died a year following EVA construction due to non operative related cause with patent graft.

Conclusions: Longer survival of patients treated by hemodialysis has evolved in an increasing incidence of patients left without conventional hemodialysis access. A variety of techniques were described in these patients. In the era of the newest modern endovascular solutions, such as HeRO® graft and GORE® Hybrid Vascular Graft, we believe, that described techniques still have important role in the treatment of selected patients.

Percutaneous Access for Endovascular Stenting—The Pioneer Experience in a Local Center

TLD Fung, KF Cheung, KM Chan, WY Lo, LF Cheng, LS Ho

Princess Margaret Hospital, Hong Kong, Hong Kong

Introduction: Percutaneous approach for endovascular aortic stenting has been developed since 1999. Potential benefits included reduced procedure time, local complication, time to discharge and time to ambulation. This is the first reported series in our locality.

Method: Retrospective review on all patients who underwent percutaneous endovascular stenting between 2012 and 2014 were reviewed. Preclose technique was performed with Proglide device. Descriptive statistics on patients' characteristics, access site status and outcome were performed.

Result: There were total 12 cases that included 10 elective EVAR/TEVAR and 2 trauma cases with thoracic aortic dissection/transection. In total 22 femoral arteriotomies were closed with the Preclose technique. The failure rate was 4.5%. The local complication rate was 4.5%, which was just one case of hematoma. Early ambulation and discharge could be achieved in most of the elective cases.

Conclusion: Percutaneous approach for endovascular aortic stenting is feasible, potentially beneficial, and non-inferior to open approach in terms of complication rate. Stringent case selection is the key to success at the very beginning of the learning curve.

0103

Comparison of Surgical and Endovascular Salvage Procedures for Juxta-Anastomotic Stenosis in Autogenous Wrist Radiocephalic Arteriovenous Fistula

Hyunwook Kwon, Ji Yoon Choi, Youngjin Han, Tae-Won Kwon, Yong-Pil Cho

Asan Medical Center, Seoul, Republic of Korea

Background: Although dysfunctional radiocephalic arteriovenous fistulas (RCAVFs) are typically treated surgically, the endovascular approach is also considered suitable. The aim of this retrospective study was to compare the cumulative patency rates following surgical and endovascular salvaging of dysfunctional RCAVFs, and to evaluate whether the maturity of vascular access sites at the time of treatment influenced the outcomes.

Methods: A total of 60 patients underwent surgical or endovascular salvage treatment for juxta-anastomotic stenosis of autogenous wrist RCAVFs: 35 patients underwent proximal neo-anastomosis, and 25 underwent percutaneous transluminal angioplasty (PTA).

Results: Clinical and anatomical success rates were, respectively, 100% and 97.1% in the surgery group, and 100% and 96.0% in the

angioplasty group ($p = 0.81$). The post-treatment restenosis rate was higher in the angioplasty group ($n = 11$, 46.0%) than in the surgery group ($n = 8$, 22.8%), without reaching statistical significance ($p = 0.15$). In a Kaplan-Meier analysis, the primary and assisted primary patency rates were significantly higher in the surgery group ($p = 0.03$ and $p = 0.02$, respectively), but there was no significant difference in secondary patency rates between the groups ($p = 0.55$). When stratified by RCAVF maturity at the time of treatment, no significant difference was noted in primary patency rates between the treatment groups. After adjusting for other variables, the relative risk of restenosis was significantly higher in the angioplasty group (HR, 2.71; 95% CI, 1.07–6.83; $p = 0.01$).

Conclusions: Post-treatment primary and assisted primary patency rates after proximal neo-anastomosis were significantly higher than after PTA, and RCAVF maturity did not influence the outcomes.

0138

Hemodynamic Simulation of Arteriovenous Fistulas Having Different Anastomosis Angles—reverse Anastomosis

Sun Cheol Park¹, Jinkee Lee²

¹The Catholic University of Korea, School of Medicine, Seoul, Republic of Korea

²Sungkyunkwan University, school of Mechanical Engineering, Suwon, Republic of Korea

Radio-cephalic arterio-venous fistula (AVF) is the best choice for achieving vascular access (VA) for haemodialysis (HD), but even this type of AVF has relatively high rates of early failure. Failure of radio-cephalic AVF means impossible use of the VA for dialysis and usually due to a juxta-anastomotic stenosis. Low haemodynamic shear contributes to the pathophysiology of VA failure due to thrombosis secondary to stenosis formation as well as VA re-occlusion after percutaneous interventions. The effect of the anastomosis angle on the disturbed flow patterns in AVF has not yet been investigated. We made a 3D meshes design of arterio-venous end to side anastomosis according the various angles (45°, 90°) including 135° of “reverse anastomosis” using SolidWorks 2013 (Solid Works Corporation). Furthermore using COMSOL Multiphysics (COMSOL corporation) as a 3D multiphysics simulation software, we simulated various hemodynamic factors influencing on wall shear stress on anastomosis site including parabolic velocities and viscosity of blood, complete cardiac pulse cycles and maximal shear stress. The result shows that the large anastomosis angle (135°) has smaller shear stress that have the advantage for reducing AVF failures. Among the differ anastomosis angle, we considered in this study, the larger (135°) angle (“reverse anastomosis”) would be the preferred choice that minimizes the development of anastomotic stenosis. Surgeon who performed AVF operation should consider this “reverse AVF”.

Lipectomy as an Salvage Option for Deeply Located Arteriovenous Fistula

Hyoungh Tae Kim, *Seulgi Hyun, Uijun Park, Won Hyun Cho*

Keimyung University Dongsan Medical Center, Daegu,
Republic of Korea

As nutritional status of general population improves, obesity became a global health problem in developed countries. According to the Korean registry of ESRD, ESRD patients with high BMI are also increasing. As a consequence, fistulas which are not amenable for needling owing to their deep location are not uncommon recently. Superficialization of fistula by long incision along the fistula and relocation of the fistula beneath the skin has been a standard salvage procedure for such a deeply located fistula. Shortcoming of the superficialization are long incision, wound healing problem, and need for admission. Here we introduce initial experiences of simple lipectomies for such deeply located fistulas. **Method:** After local infiltration, two or three short transverse incisions are made over the course of fistula, skin flaps are developed and subcutaneous fat above the superficial fascia are removed. After placing closed suction drain, wounds are closed interruptedly. **Case:** We did lipectomies in two patients, sixty years of female of BMI 35 and 30 year old male of BMI 41. Depth of the fistula were 8 to 12 mm and 10 to 13 mm for the first patient's forearm fistula and second patient's upper arm fistula. After lipectomy, their fistula was able to use for dialysis and functions well for 8 and 14 months after the operations, respectively. **Summary:** Lipectomy is simple and safe salvage option for the deeply located AV fistulas and can be done outpatient setting.

0200

Successful Limb Salvage after An Iatrogenic Femoral Arterio-venous Fistula: A Case Report

Mohd Abdul Rauf Paharudin,

Mohd Norhisham Azmi Abdul Rahman,

Ahmad Faizal Othman

Vascular Unit, Department of Surgery, International Islamic University
Malaysia, Kuantan, Pahang, Malaysia

Arterio-Venous Fistula (AVF) is rare. It is described as anomalous communication between an artery and vein which is frequently caused by iatrogenic or traumatic etiology. Femoral AVF is always happens secondary to percutaneous vascular intervention or penetrating trauma. We will report a case of iatrogenic arteriovenous fistula that was successfully treated and the limb was salvaged.

0220

The Mid-Sternal Length, a Practical Anatomical Landmark for Optimal Positioning of Long-Term Central Venous Catheters

Fereshteh Salimi, *Amir Keshavarzian, Navab Ghasemi,*
Mohammad Imani

Isfahan University of Medical Sciences, Isfahan, Iran

Background: Long-term tunneled catheters are used for the hemodialysis or chemotherapy in many patients. Proper placement of the catheter tip could reduce early and late catheter related complications. Aim of the present study was to evaluate a new formula for proper placement of tunneled hemodialysis or infusion port device by using an external anatomic landmark.

Materials and Methods: A total of 64 adult patients undergoing elective placement of tunneled Central Venous Catheter (CVC) requiring hemodialysis or chemotherapy were enrolled in this prospective study during 2011–2012 in the university hospital. The catheter length to be inserted in the right internal jugular vein (IJV) was calculated by adding two measurements (the shortest straight length between the insertion point of the needle and the suprasternal notch plus half of sternal length). The catheter position was considered correct if the tip was positioned in the right atrium (RA) or Superior vena cava (SVC)-RA junction.

Results: The patients were 55.28 ± 19.85 years of age, weighed 5.78 ± 16.62 kg and were 166.07 ± 10.27 cm tall. Catheters were inserted successfully in 88% of patients ($n = 56$). Catheter tip positions in the failures were SVC ($n = 5$), tricuspid valve ($n = 2$), and right ventricle ($n = 1$) in our patients.

Conclusion: Long-term hemodialysis or port CVC could easily insert in the right IJV by using half of the sternal length as an external landmark among adult patients.

(H) Venous Disease

0018

Preliminary Report: Study of Inflammatory Responses in Varicose Veins Surgery, a Comparison between Conventional Venous Stripping and Endo-Venous Radio-Frequency Ablation (EV-RFA)

Pisake Boontham, *Norraporn Chairaroon,*
Nunthapol Pongrattananan, Anucha Panoi,
Tamrongroj Temudom, Chaiwat Kunanuson

Division of Vascular Surgery, Department of Surgery, Phramongkutklao
Hospital, Bangkok, Thailand

Background: Endo-Venous Radio-Frequency Ablation (EV-RFA) for the treatment of varicose veins is thought to produce less post-operative complications than the conventional venous stripping, in

particular, post-operative pain by a considerable amount of studies, whereas very few studies have been performed on molecular basis. This study aims to determine the inflammatory responses of EV-RFA and conventional venous stripping for the treatment of varicose veins by comparison of preoperative and postoperative levels of Interleukin-6 (IL-6) and C-Reactive Protein (CRP). Along with the inflammatory study, this study provides data comparison of visual analogue pain scores and ecchymosis between the two methods.

Methods: A prospective non randomized controlled trial study was performed by measuring IL-6 and CRP levels at preoperative and 24 hours postoperative periods in the symptomatic varicose patients who underwent EV-RFA or conventional venous stripping.

Result: 21 patients were enrolled, 7 patients underwent conventional venous stripping, and 14 patients underwent EV-RFA. There were no differences in the demographic data. The difference between pre and post-operative levels of IL-6 and CRP were significant in the EV-RFA group ($P = 0.022$ and 0.008 respectively), also the difference between pre and post-operative levels of IL-6 and CRP were significant in the venous stripping group ($P = 0.018$ and 0.043 respectively). Further, comparing the postoperative level of IL-6, postoperative ecchymosis and pain scores between EV-RFA and venous stripping group were significant difference. ($P = 0.012$, 0.001 , 0.046 respectively)

Conclusion: Post-operative inflammatory response is significantly different between the two methods of venous surgery, EV-RFA and conventional venous stripping, along with pain scores and ecchymosis.

0020

Cartheter-Directed Trombolysis with rt-PA in a Patient with Lower Extremity Deep Venous Thrombosis Developing after Medical Abortus

Ismail Yurekli, Kazim Ergunes, Levent Yilik, Yuksel Besir, Ufuk Yetkin, Serkan Yazman, Tayfun Goktogan, Ali Gurbuz

Izmir Katip Celebi University Atatürk Training and Research Hospital, Izmir, Turkey

Background and Objectives: Deep venous thrombosis (DVT) is an important cause of morbidity and mortality in patients not receiving appropriate and effective treatment. We presented a patient having left lower extremity DVT developing after medical abortus.

Methods: A 32-year old woman admitted emergency department of our hospital on April 2, 2014. She had pain and edema in the left lower extremity. She was performed medical abortus two month ago. She was treated due to DVT in right lower extremity one month ago. The venous Doppler ultrasonography showed thrombosis of iliac, femoral, and popliteal veins.

Results: A combination of catheter-directed thrombolysis with recombinant tissue plasminogen activator (rt-PA) and heparin were immediately started. The patient's symptoms, particularly pain and edema continued to improve in the left lower extremity. She was

discharged ten days after rt-PA with low-molecular-weight heparin treatment.

Conclusions: rt-PA and heparin treatments are safe, affordable, and more complete treatment options for acute DVT of the lower extremity.

0036

The Clinical Importance of Anomaly on Inferior Vena Cava in the Graft Donation Surgery from a Deceased Donor

Mihyeong Kim, Kangwoong Jun, Insung Moon, Jiil Kim

Seoul St. Mary's Hospital, Seoul, Republic of Korea

Introduction: Anomaly of inferior vena cava (IVC) is rare. Most cases were found during nephrectomy for a living donor kidney transplantation or during evaluations for other disease. To the best of our knowledge, anomalies of IVC which were found in the graft donation surgery from a deceased donor have never been reported. We experienced each cases of left-sided IVC and duplicated IVC during the graft donation surgery from a deceased donor.

Case 1: 55 year-old male was diagnosed brain death and his family decided to donate his internal organs. Graft donation surgery was performed and we dissected the infrarenal aorta, and then, tried to find the IVC on the right side of the aorta, but we failed. The IVC was found in the left side of the aorta. The left renal vein was shorter than right.

Case 2: 44 year-old female was diagnosed brain death. Graft donation surgery was performed, and the infrarenal aorta was identified and the IVC was recognized in the right side of the aorta. During further dissection, we found that the left gonadal vein and another vein were drained into the left renal vein. We traced this unknown vein, and figured out that it was an additional left IVC. Both side grafts needed renal vein angioplasties.

Conclusion: Radiologic evaluations are uncommonly performed in deceased donor, so it is difficult to know anatomic anomalies before surgery. If the operator failed to perceive anomalies of the IVC, it can lead to unexpected bleeding. In the case of duplicated IVC without control of left-sided additional IVC, continuous drainage of warm blood from the left lower extremity affect the efficient graft cooling. And several cases reported attendant anatomic variations such as circumcaval ureter, retrocaval ureter, and renal arterial variation, so it needs a caution to do surgery.

Prevalence of Lower Limb Varix in Hemodialysis Patients

Yasuhiro Ozeki¹, Kazuo Tsuyuki¹, Shinichi Watanabe², Kunio Ebine¹, Susumu Tamura¹, Masashi Yokomuro¹, Toshifumi Murase¹, Kenji Ninomiya¹, Naoya Moriki¹, Kenta Kumagai¹, Itaru Yokouchi¹, Satoru Toi¹, Kenji Kohno¹, Kyoko Takashima¹, Mayumi Hamada¹, Yuki Tominaga¹, Hiroyoshi Yano¹

¹Odawara Cardiovascular Hospital, Odawara, Kanagawa, Japan

²Development Center to Support Health and Welfare, Kanagawa Institute of Technology, Atsugi, Kanagawa, Japan

Objective: Sixty-four lower limb varix patients have been treated with endovenous laser ablation at our hospital since June 2013, but this treatment has not been applied to a hemodialysis patient. Thus, we investigated and discussed the prevalence of lower limb varix in hemodialysis patients.

Material and Methods: Of 286 patients being treated with hemodialysis at our hospital (190 males and 96 females aged 26–91 years (mean: 66.8 years old)), those with a C2 or larger varix (the varix diameter in a standing position is 3 mm or larger) on clinical CEAP classification were counted, and the presence or absence of varix-induced symptoms (such as easy fatigability and pain) was investigated.

Results: Only 4 (1.4%) of the 286 patients had a C2 or larger varix, and only one of them complained of easy fatigability. According to a study reported by Hirai, et al. in Japan, the saphenous and segment types of Leu's varix classification may correspond to a C2 or larger varix in our study, and 156 (24.6%) of 632 patients (105 males and 527 females aged 15–90 years (mean: 42.7 years old)) had these types of varices in their study. The prevalence in our hemodialysis patients was significantly lower ($p < 0.001$).

Conclusion: Primary lower limb varices are caused by insufficiency of superficial venous valves, and this may be due to an increased pressure loaded on valves. Arteriosclerosis is severe in many hemodialysis patients and blood flow is decreased in the lower limbs, reducing the venous blood pressure and pressure loaded on superficial venous valves. These were assumed to be the causes of varices.

0109

Use of meso-Rex Shunt with Transposition of the Coronary Vein for the Management of Extrahepatic Portal Vein Obstruction

Hyunwuk Kwon, Yong-Pil Cho, Tae-Yong Ha, Gi-Young Ko, Kyung-Mo Kim, Sung-Gyu Lee

Asan Medical Center, Seoul, Republic of Korea

Introduction: The meso-Rex shunt is used to safely and effectively treat patients with portal hypertension due to extrahepatic portal vein obstruction. Here, we present a case of a 20-year-old

man with idiopathic extrahepatic portal vein obstruction, who was treated with a new technique of transposition of the coronary vein
Case: The patient had a previous clinical history of increased abdominal volume and five episodes of gastrointestinal bleeding, and was diagnosed with idiopathic portal vein obstruction at 5 years of age. After laparotomy, the round ligament was dissected toward the distal part of the left portal vein at the level of the Rex recessus. The left portal vein was then approached, and its ventral and lateral aspects were dissected over a length of 3–4 cm. The intrahepatic left portal vein was evaluated by surgical exploration, and its diameter was approximately 3 mm. Splenectomy was performed because of massive splenomegaly. There was a nest of peripancreatic collaterals with flow toward the gastroesophageal junction through a series of large varices, which included the coronary vein with an adequate diameter and flow in the hepatopetal direction. This vein was fully mobilized, divided, and then transposed across the mesocolon and behind the pylorus to the intrahepatic left portal vein to which it was anastomosed end-to-side using non-absorbable monofilament interrupted sutures. Unclamping of the meso-Rex shunt immediately allowed adequate portal flow into the liver, as confirmed by intraoperative portography, and there were no remaining large portosystemic shunts

Conclusion: In this case report, we propose a new technique for the transposition of the coronary vein for the management of extrahepatic portal vein obstruction without a vascular conduit, which simplified the operative procedures, resulting in reduced total operating time and no need for procurement of autologous veins or for simultaneous embolization of collaterals to augment portal flow.

0135

Study of 5 Cases that Required PCPS for Acute Pulmonary Embolism

Sakurai Yuka¹, Abe Hiroyuki², Suzuki Hirotooshi¹, Sagane Masatoshi¹, Ro Daijyun¹, Chiba Kiyoshi¹, Ono Hirokuni¹, Oono Makoto¹, Kitanaka Yousuke¹, Masahide Chikada¹, Nishimaki Hiroshi¹, Miyairi Takeshi¹

¹St Marianna University of Medicine Cardiovascular Surgery, Kanagawa, Japan

²Keiai Hospital, Kanagawa, Japan

Background: Acute pulmonary embolism has a high mortality rate despite advances in diagnosis therapy. The management of patients with acute pulmonary embolism (PE) remains unclear. Surgical embolectomy has now been liberalised for hemodynamic stable patients with right ventricular dysfunction. PCPS is recommended as an important heart-lung support for hemodynamic unstable patients.

Methods: From 2009 to 2013, 301 cases of acute pulmonary embolism were registered in our hospital. 5 patients were received Percutaneous cardiopulmonary support (PCPS) for cardiopulmonary arrest. The average age of patients was 57 years and 66% were

female. One patient of them were pulmonary embolectomy hemodynamics unstable.

Results: One patient has experienced cardiopulmonary arrest before embolectomy, then Percutaneous cardiopulmonary support (PCPS) was introduced, then underwent surgical embolectomy, and survived. Another patient underwent a catheter, He was survival. Another patient to the other hemodynamic stability without surgery or catheter, he was survival. 2 patients died. Since PCPS cannot be maintained. The in-hospital mortality rate was 40%.

Conclusions: Providing immediate percutaneous cardiopulmonary support to patients with cardiogenic shock could help to resuscitate and stabilize cardiopulmonary function and allow for a good outcome of pulmonary embolectomy. Pulmonary embolectomy is an effective therapeutic option for patients with pulmonary embolism.

0141

Simultaneous Percutaneous Treatment of Bilateral (B/L) Varicocele and B/L Lower Limbs Varicose Veins in an Infertile Male in Era of Hybrid Operating Room

Sandeep Raj Pandey

Norvic Int'l Hospital, Kathmandu, Nepal

Objective: To assess benefit of treating B/L varicocele and B/L lower limbs varicose veins in hybrid operating room in same sitting.

Materials and Methods: A 30 years old gentleman presented with complaints of B/L lower limbs pain and swelling. He also had scrotal pain with azoospermia. Duplex evaluation revealed B/L lower limbs varicose veins and B/L varicocele. He underwent simultaneous B/L Percutaneous Embolisation of varicocele with B/L Endovenous thermal ablation of his varicose veins under General Anesthesia (GA). Total Procedural time was less than 2 hours. The Procedure was carried out as a Day Care basis. Routine follow-up was done at intervals of 3 months and 6 months respectively. No any major complication was encountered.

Result: AT 3 months Complete Thrombosis of the abnormal pampiform plexus and LSV with no reflux on valsalva was observed on duplex and had relieved from lower limbs and scrotal pain. At 6 months semen analysis showed significant improvement in sperm count and motility.

Conclusion: Varicocele along with lower limbs varicose veins is common in young adult. Simultaneous treatment in hybrid operating room under GA is a cost effective alternative. Minimally invasive nature gives well toleration with shorter recovery time and less discomfort.

Keywords: Varicocele; Varicose veins; Percutaneous; Hybrid; Infertile

0147

Deep Vein Thrombosis of Unusual Etiology as a Hip Joint Ganglion Cyst

In Mok Jung, Jung Kee Chung, Young Ho Soh

SNU-SMG Boramae Medical Center, Seoul, Republic of Korea

Purpose: We present a case of a deep vein thrombosis of unusual etiology as a hip joint ganglion cyst.

Case: Our 68-years old patient developed progressive right leg swelling from 3 weeks ago. CT angiography revealed a focal DVT (Deep vein thrombosis) in right CFV (Common femoral vein). Initial thrombolysis was done, but failed. We decided to perform a surgical thrombectomy for intractable focal DVT. At exploration, we found a hip joint ganglion cyst compressing CFV. Surgical removal of the cyst and open thrombectomy for impacted thrombus resulted in a little improvement of the swelling, but thrombosis recurred. One week later, thrombolysis was performed again and thereafter swelling was decreased. After 15 months, he resumed his normal activity without leg swelling and deep vein thrombosis.

Conclusion: Venous compression due to external cystic lesions, although rare, is recognized. This differential diagnosis should also be taken into account. Therapeutic options are the surgical removal of the cyst with thrombectomy and thrombolysis if needed.

0160

Surgical Treatment of Inferior Vena Cava (IVC) Malignant Thrombus with Cardiac Extension Secondary to Pelvic Tumor

Abdelrahman Elkaialy, Faisal Alsafi, Haney Najm

King Fahd National Guard Hospital/King Saud Bin Abdulaziz University of Health Sciences, Riyadh, Saudi Arabia

A pelvic sarcoma with cardiac extension through IVC is an extremely rare complex neoplasm. We report a woman 46 years old who underwent hysterectomy for endometrial stromal sarcoma 6 years previously and developed local recurrence with cardiac extension. CTA revealed a pelvic mass, a mass in right internal iliac vein, right common iliac vein, as well as the IVC, extending into the right atrium. The patient underwent one stage combined multidisciplinary thoracoabdominal operation. Infrahepatic IVC venotomy enabled removal of all tumor thrombus. Transesophageal echo confirmed clearance of right atrium from tumor. Venovenous bypass with mild hypothermia provided the required circulatory support during surgery. One year of follow up till present showed no recurrence. Aggressive surgical treatment provides the only reasonable chance for cure and prevents sudden death due to pulmonary embolism.

Our Approach to Right Lower Extremity Deep Vein Thrombosis in a Patient with Complicated Takayasu's Arteritis

Ufuk Yetkin, Ihsan Peker, Koksak Donmez, Ali Gurbuz

Department of Cardiovascular Surgery, Katip Celebi University Izmir Ataturk Training and Research Hospital, Izmir, Turkey

Takayasu's Arteritis, is an inflammatory vasculitis, which is usually observed in female patients younger than 40 years old and involves aorta and main branches. Due to stenosis of cranial arteries, transient blindness and blurring in vision may be observed.

A 72 years old female patient admitted to our hospital for swelling and pain complaint in her right leg with 10 days of history. Doppler Ultrasonography revealed acute deep vein thrombosis in femoral vein. Takayasu's arteritis was diagnosed 37 years ago after a stroke attack, which resulted with right hemiparesis. She was under control since then. She was bilaterally blind for 30 years.

We treated our patient with low molecular weight heparin (LMWH) subcutaneously and medical therapy (Eau de Goulard and chondroitin polysulfate topically, oxerutin, non-steroid anti-inflammatory drugs, low dose enteric coated acetyl salicylic acid and extremity elevation). Patient was hospitalized for 8 days. Her symptoms regressed gradually. She was discharged with LMWH and additional medical therapy. Patient is still under control of rheumatology and cardiovascular surgery outpatient clinic.

Takayasu's arteritis is a chronic vasculitis but its coincidence with deep vein thrombosis is rare. Medical treatment of such patients must be planned carefully for chronic disease and systemic involvement. Safety and efficacy of treatment is especially important for providing required medical therapy.

0167

Five Years Experience of Conventional Venous Stripping for Varicose Veins at Lampang Hospital, Thailand: It's Still Working

Boonsap Sakboon¹, Nuttapon Arayawudhikul²

¹Lampang Hospital, Lampang, Thailand

²Chiangmai University, Chiangmai, Thailand

Objective: To study and review the outcome of conventional venous stripping for varicose veins at Lampang Hospital; a new cardiac center in the local hospital in the north of Thailand that had to deal with varicose disease without endovascular laser.

Methods: Data of venous stripping procedure by CVT unit at Lampang Hospital were collected from July 2009 to May 2014. All of 60 patients came with symptom of leg pain and result of retrograde (reversed) venous flow of GSV. Every patients were discharged in the morning after the day of surgery and was followed up at two weeks and one month.

Results: Of all 60 patients could be followed up in accordance with the protocol. The treatment was successful in all patients, no wound complication nor recurrence. The symptoms of all patients were improved completely.

Conclusion: Conventional venous stripping for varicose veins is still working and easy to do. The result was satisfied by both patients and surgeons even had limited of time and lack of facility in an advance choices.

0177

Short-term Catheter-directed Thrombolysis with Low-dose Urokinase Followed by Aspiration Thrombectomy for Treatment of Symptomatic Acute Lower Extremity Deep Venous Thrombosis

Soo Jin Na Choi¹, Hag Zu Kim², Ho Kyun Lee¹, Sang Young Chung¹

¹Chonnam National University Hospital, Gwangju, Republic of Korea

²Health Insurance Review & Assessment Service, Seoul, Republic of Korea

Objective: To evaluate the venous patency, correlation between pretreatment location of thrombus & rethrombosis, and complication of stent in patients treated by catheter-directed thrombolysis with low-dose urokinase for symptomatic acute lower extremity deep venous thrombosis.

Materials and Methods: Ninety-eight consecutive patients (62 women and 36 men; mean age, 62.6 years), treated by catheter-directed thrombolysis with low-dose UK were included. Immediate venous patency was evaluated in terms of technical success (successful restoration of antegrade in-line flow in the treated vein with residual stenosis of less than 30%) and clinical success (significant reduction of clinical symptoms before hospital discharge). Late venous patency was evaluated in terms of primary patency rate and clinical success. Correlation between pretreatment location of thrombus & rethrombosis was evaluated using chi-square analysis. Complication of stent was also evaluated.

Results: Immediate technical success and immediate clinical success were achieved in all patients. There was no major systemic bleeding complication. The primary patency rate at 6 months and 12 months was 72% and 59%, respectively. Eighty (82%) patients were symptomatic improved after a median clinical follow-up of 30 months, eleven (11%) patients were unchanged, three (3%) patients were aggravated and four (4%) patients had no clinical follow-up. Pretreatment location of thrombus (internal iliac vein, deep femoral vein and infrapopliteal veins) showed no significant correlation with rethrombosis (p-value: 0.92, 0.68, 0.54). Five (7%) patients showed complications of stent such as fracture (two patients; 3%), collapse (significantly decreased anterior-posterior diameter of stent; two patients; 3%) and shortening (one patient; 1%).

Conclusion: Short-term catheter-directed thrombolysis with low-dose UK can be an effective, safe method to manage the lower extremity DVT. And there is a no significant correlation between

pretreatment location of thrombus and rethrombosis. And stent-deployment also can be an safe method to manage the lower extremity DVT.

0178

Endovenous Therapy for Venous Insufficiency: A Review of 79 Consecutive Cases

Chun Ling Patricia Yih, Yin Chun Skyi Pang, Chung Ngai Tang

Department of Surgery, Pamela Youde Nethersole Eastern Hospital, 3 Lok Man Road, Chai Wan, Hong Kong

Background: Symptomatic varicose veins are a common disease. Endovenous options of ablation offer an attractive alternative to traditional open surgery for patients suffering from venous insufficiency, with potential advantages of decreased scarring, decreased incisional pain, and faster functional recovery.

We analyzed the results of 79 consecutive patients treated in our department using endovenous methods.

Methods: We retrospectively reviewed 79 consecutive patients treated in our department using endovenous methods. Background demographics, symptom severity (Venous Clinical Severity Score, VCSS), and clinical assessment (Clinical, Etiological, Anatomical, and Pathophysiology, CEAP) were recorded preoperatively. Postoperative outcome was assessed in terms of complications, recurrence, and VCSS.

Results: Of the 79 patients, 54 (68.3%) had unilateral disease and 25 (31.6%) had bilateral disease. 67 (84.8%) were operated by RFA, whereas there were 4 each of Mechanochemical ablation and injection sclerotherapy (5.06% each). Preoperative mean CEAP score was 2.8 ± 1.2 . Significant reduction in VCSS preoperatively vs postoperatively was observed (6.3 ± 2.2 vs 1.9 ± 1.5 , $p = 0.00$). There was one (1.3%) conversion to groin incision due to vein tortuosity causing difficult cannulation. Minor complications were noted in 5 patients (6.3%). There were no major complications. At a median FU length of 43.7 weeks (4–147), 2 patients (2.5%) developed recurrence of venous insufficiency symptoms.

Conclusion: Endovenous means are safe and effective in treating symptomatic varicose veins, with significant reduction in symptom severity. Minor complications are uncommonly observed, and recurrence is rare.

0184

Splenic Vein Aneurysm Associated with Splenic Arteriovenous Fistula—A Case Report

Dae Yong Kim, Byeong Kwon Jeong, Byung Jun So

Wonkwang Uni Hosp., Iksan, Jeonbuk, Republic of Korea

Splenic vein aneurysms are rare. Possible etiology includes portal hypertension or a congenital weakness in the vein wall. Most splenic vein aneurysms are asymptomatic and are usually incidental findings. The natural history is unknown, but is thought to include rupture, thrombosis, or compression of adjacent structures. The appropriate management is also unknown, but has included noninvasive follow-up, plication, and aneurysm excision.

We are going to make a case report about 55 year-old woman with no significant medical history who had abdominal pain and was found to have a splenic vein aneurysm, which did not seem to relate abdominal pain.

A 4 cm in diameter contrast enhancing mass in the left mid abdomen was demonstrated by means of a helical computed tomography (CT) scan, which was associated with splenic arterio-venous fistula.

Because no other source for the abdominal pain could be determined, the aneurysm was excised because of its size, while spleen was preserved. The patient had no postoperative complications. The patient was discharged on the 12th postoperative day.

0192

Successful Medical Treatment of A Patient with Chronologically Discordant Superficial and Deep Combined Thrombophlebitis that is Complicated with Cellulitis

Ufuk Yetkin, Koksal Donmez, Hasan Iner, Ihsan Peker, Ali Gurbuz

Department of Cardiovascular Surgery, Katip Celebi University Izmir Ataturk Training and Research Hospital, Izmir, Turkey

Joined lesion of deep and superficial thrombophlebitis, which is associated with cellulitis, is a rare and combined pathology.

Our case was 54 years old male patient. Three weeks before admitting to our hospital, patient had pain, discoloration, sensitivity, and firmness at vena saphena magna trajectory of left lower extremity. There was a 5 cm circumference difference below knee and 3 cm circumference difference above knee in left lower extremity. There was fever and discoloration throughout all extremity. There was not any significance in his medical history.

Colored Doppler ultrasonography revealed total occlusion with acute thrombi in vena saphena magna, popliteal vein, and crural branches. In addition, subacute-chronic thrombi and partial blood flow were observed in common, superficial and deep femoral vein. There was edema and lymphatic dilatation in cutaneous and

subcutaneous tissue, which was consistent with cellulitis. Patient was consulted to infectious disease clinic. Due to their suggestion, empiric two wide spectrum parenteral antibiotics were administered. In addition, subcutaneous low molecular weight heparin (tinzaparin-consistent with weight), non-steroid anti-inflammatory drug, enteric-coated acetyl salicylic acid, per oral venotonic (oxerutin) and eau de Goulard attachment 4 times a day were administered. Left lower extremity was elevated optimally. Patient became asymptomatic in 9th day of medical treatment and all of his symptoms completely regressed. Patient was discharged with ambulatory medical treatment. There was not any significance in thrombophilia examination.

Deep, superficial, or combined thrombophlebitis cases associated with cellulitis is extremely rare. We believe that this combined systemic treatment is safe, efficient, and effectively reducing patient discomfort.

0194

Popeye Syndrome: Hemodialysis Catheter Related Central Vein Occlusion

Patrick Louie Maglaya, Leoncio Kaw

Philippine General Hospital, National Capital Region, The Philippines

As a complication of vascular access, central vein occlusion (CVO) has been documented with incidence as high as 40%, in high volume centers. It has been postulated that such occlusion is brought about by endothelial hyperplasia due to turbulence brought about by high-flow access; and repetitive foreign body trauma along the vessel sidewalls. Chart review of all adult patients from January 2008–April 2014, documented with catheter related CVO yielded 4% (16 of 457) incidence among patients with hemodialysis catheter placement.

Mean age of the study population (N = 11) was , inclusive of 6 male and 5 female. Average onset of symptoms after catheter placement was 92 days. There was a 100% correlation of unilateral extremity and facial edema with the laterality of catheter placement and AV access. Complications of CVO noted were venous hypertension (91%), venous stasis ulcer (72%) and fistula dysfunction (27%). Patients underwent digital subtraction venography with note of CVO at innominate vein (91%) subclavian vein (37%) and superior vena cava (64%). Patients were subjected to endovascular (balloon angioplasty and stenting) (45%), open surgical bypass (37%) and ligation of arteriovenous fistula (18%). Outcomes were monitored via venous access pressure and graft flow rate over a perioperative (30-day) and postoperative period (90-days) which showed patency of endovascular (100%) and surgical treatment (100% and 75%) respectively. There was a 91% subjective report of symptomatic resolution of unilateral extremity and facial edema during both perioperative and postoperative periods.

0236

PROC Mutations Causing Inherited Venous Thrombosis in Chinese Population

*Haoyu Deng^{1,4}, Jun Xie², Wei Shen³, Yi Gu³, Biqin Fang¹, Jiaquan Chen¹, Hui Xie¹, Weibin Huang¹, Meng Ye¹, Lei LV¹, Jiwei Zhang¹, **Lan Zhang¹***

¹Department of Vascular Surgery, Renji Hospital, School of Medicine, Shanghai JiaoTong University, Shanghai, China

²The State Key Lab of Genetic Engineering, School of Life Sciences, Fudan University, Shanghai, China

³Department of Clinical Laboratory, Renji Hospital, School of Medicine, Shanghai JiaoTong University, Shanghai, China

⁴Department of Pathology and Laboratory Medicine, Faculty of Medicine, University of British Columbia, Vancouver, Canada

⁵Centre for Heart Lung Innovation, St. Paul's Hospital, Vancouver, Canada

Hereditary protein C (PC) deficiency causing by PROC mutations is one of the most prevalent congenital factors promoting venous thromboembolism (VTE) in Asia especially in China. Here we report nine pedigrees that have been diagnosed as hereditary VTE including a pedigree that carries a first-reported mutation site (c.1157T >C, p.Leu386Pro). Furthermore, the space structures of mutant PC were predicted by using Homology modeling for the analysis of molecular dynamics. The results demonstrated mutations of c.565C >T (p.Arg189Trp) and c.1157T >C (p.Leu386Pro) impaired the original space structures of PC. Molecular dynamics analysis suggested that c.565C >T impaired the hydrogen bonds between Arg189 and His41, while c.1157T >C significantly unregulated the Van der Waals' (VDW's) interaction energy between Leu386 and Tyr435Thr436 from -5.70 kal/mol to 31986.45 kal/mol contributing instability of space structure of PC. These findings provided information about the potential mechanism by which PROC mutation mediated the pathogenesis of venous thromboembolism and an important implication for developing new therapy.

Authors Index

AUTHORS INDEX

| Last Name | First Name | Presentation Code | Page | | | | | | |
|-------------------------|-----------------|-------------------|-----------------------|------------------|---------------|-------------------|--------------------------|------|------|
| A | A, Li-Mujian | | | Bao, Junmin | 0110 | S082 | | 0149 | S027 |
| | | | | | 0252 | S090 | | 0154 | S027 |
| | | | | | 0253 | S090 | | 0148 | S034 |
| | | | | Bass, Arie | 0050 | S117 | | 0078 | S086 |
| | | 0271 | S025 | Besir, Yuksel | 0022 | S101 | Cheng, SW | 0152 | S020 |
| | | 0276 | S060 | | 0020 | S120 | Cheol, Park Sun | 0137 | S084 |
| | | 0263 | S091 | Boontham, Pisake | 0018 | S119 | Cheung, Grace | 0195 | S024 |
| | Abe, Hiroyuki | 0120 | S083 | | | | Cheung, KF | 0052 | S118 |
| | | 0135 | S121 | C | | | Cheung, Kwok Fai | 0069 | S042 |
| | Ahn, Hye Young | 0053 | S102 | | Cabasa, Alduz | 0145 | S058 | | 0165 |
| Ahn, Hyun Jun | 0128 | S046 | Cakir, Habib | | 0090 | S096 | Chiba, Kiyoshi | 0106 | S081 |
| | 0122 | S084 | | | 0197 | S099 | | 0120 | S083 |
| Ahn, Moonsang | 0099 | S081 | | | 0029 | S110 | | 0135 | S121 |
| Ahn, Sang Hyun | 0127 | S057 | Celik, Ersin | | 0029 | S110 | Chikada, Masahide | 0106 | S081 |
| | 0132 | S084 | Cerna, Marie | | 0039 | S116 | | 0120 | S083 |
| Akca, Baris | 0030 | S094 | cerrahoglu, mustafa | | 0010 | S077 | | 0135 | S121 |
| | 0038 | S094 | Cerrahoglu, Mustafa | | 0007 | S109 | Ching, Siok Siong | 0281 | S108 |
| | 0051 | S095 | Chairaroon, Norraporn | | 0018 | S119 | Chino, Shuji | 0046 | S111 |
| Ali, Ismail | 0201 | S099 | Chan, Herman | 0172 | S021 | Chiu, Chong-Chi | 0008 | S115 | |
| AlKohlani, Hussin | 0190 | S036 | Chan, KM | 0052 | S118 | Chng, Siew Ping | 0155 | S051 | |
| Alsaifi, Faisal | 0160 | S122 | Chan, Kwong Man | 0069 | S042 | Ch'ng, Jack Kian | 0155 | S051 | |
| AlTurki, Saud | 0190 | S036 | | 0165 | S106 | | 0180 | S106 | |
| AlWahbi, Abdullah | 0190 | S036 | Chan, Wai Hong | 0171 | S039 | Cho, Byung Sun | 0053 | S102 | |
| Alzakari, Abdeulmohsen | 0157 | S114 | Chan, Wai Tat | 0221 | S107 | Cho, Daniel | 0159 | S052 | |
| Anand, Vivek | 0134 | S050 | | 0222 | S107 | Cho, Hong Rae | 0094 | S113 | |
| | 0136 | S057 | Chan, YC | 0152 | S020 | Cho, Soon Gu | 0128 | S046 | |
| Ando, Mizuki | 0092 | S113 | Chan, Yiu Che | 0195 | S024 | | 0122 | S084 | |
| Aoki, Atsushi | 0073 | S080 | | 0149 | S027 | Cho, Won Hyun | 0182 | S119 | |
| Aoki, Kenji | 0162 | S085 | | 0154 | S027 | Cho, Yong-Pil | 0104 | S081 | |
| | 0054 | S111 | | 0148 | S034 | | 0107 | S082 | |
| Aoki, Masaya | 0170 | S114 | | 0078 | S086 | | 0118 | S083 | |
| | 0176 | S115 | Chang, Guangqi | 0085 | S048 | | 0095 | S087 | |
| Arakaki, Katsuya | 0129 | S105 | | 0260 | S059 | | 0100 | S096 | |
| Arakaki, Ryoko | 0086 | S033 | Chang, Guang-Qi | 0277 | S035 | | 0101 | S097 | |
| | 0092 | S113 | Chen, Dafang | 0262 | S029 | | 0103 | S118 | |
| Arayawudhikul, Nuttapon | 0167 | S123 | Chen, Feng | 0262 | S029 | | 0109 | S121 | |
| Asano, Mitsuru | 0032 | S110 | | 0245 | S038 | Cho, Young I | 0159 | S052 | |
| Asano, Souichi | 0096 | S039 | Chen, Jiaquan | 0236 | S125 | Choi, Ji Yoon | 0103 | S118 | |
| Ashraf, M | 0057 | S054 | Chen, Jia-quan | 0235 | S047 | Choi, Ji-Yun | 0095 | S087 | |
| Awang, Ahmad Khadri | 0199 | S107 | Chen, Jie | 0278 | S053 | Choi, Jung-Hyun | 0216 | S044 | |
| Azizi, Zainal Ariffin | 0064 | S029 | Chen, Peng | 0256 | S090 | Choi, Seoung-Wook | 0207 | S022 | |
| | 0031 | S042 | Chen, Qingwen | 0245 | S038 | | 0206 | S040 | |
| | 0144 | S055 | Chen, Xiyang | 0273 | S026 | | 0114 | S082 | |
| B | | | | 0261 | S041 | Choi, Soo Jin Na | 0060 | S079 | |
| | | | | 0272 | S092 | | 0061 | S079 | |
| | Bachleda, Petr | 0039 | S116 | Chen, Zhong | 0257 | S028 | | 0059 | S095 |
| | | 0049 | S117 | | 0258 | S091 | | 0177 | S123 |
| | Bae, Mi-ju | 0041 | S056 | | 0259 | S091 | Choo, Zhen Wei | 0112 | S031 |
| | | 0042 | S077 | Cheng, Can | 0246 | S041 | Chow, Felix Che-Iok | 0195 | S024 |
| | Bae, Sang In | 0076 | S103 | | 0247 | S041 | Chu, CM | 0173 | S036 |
| | Baek, Bomina | 0217 | S100 | Cheng, Jie-Jun | 0224 | S088 | Chua, Benjamin, Soo Yeng | | |
| | Baek, Jong Kwan | 0104 | S081 | Cheng, LF | 0052 | S118 | | 0155 | S051 |
| | Baheti, Kalifu | 0280 | S093 | Cheng, Long | 0191 | S052 | | 0180 | S106 |
| Banno, Hiroshi | 0062 | S026 | Cheng, Stephen WK | 0195 | S024 | Chung, Jung Kee | 0147 | S122 | |

| Last Name | First Name | Presentation Code | Page | | | | | | |
|-----------------------|------------|-------------------|------|---------------------------|------|------|--------------------|------|------|
| | | | | F | | | | | |
| Chung, Sang Young | | 0060 | S079 | Faidsal, A | 0057 | S054 | Guo, Lianrui | 0280 | S093 |
| | | 0061 | S079 | Fan, Xue-qiang | 0234 | S049 | Guo, Wei | 0228 | S032 |
| | | 0059 | S095 | | 0278 | S053 | | 0262 | S029 |
| | | 0177 | S123 | Fang, Biqin | 0236 | S125 | | 0265 | S035 |
| | | | | Fang, Qing-bo | 0271 | S025 | | 0270 | S035 |
| Chung, Sung Woon | | 0041 | S056 | | 0268 | S038 | | 0223 | S040 |
| | | 0042 | S077 | | 0275 | S038 | | 0264 | S092 |
| | | | | | 0263 | S091 | | 0269 | S092 |
| Chung, Young Soo | | 0104 | S081 | | 0266 | S092 | | 0274 | S093 |
| | | 0100 | S096 | Fang, Zhengdong | 0246 | S041 | Guo, Xiang-Jiang | 0279 | S093 |
| | | 0101 | S097 | | 0247 | S041 | Gurbuz, Ali | 0224 | S088 |
| Ci, Hong-bo | | 0268 | S038 | Feldman, Leonid | 0050 | S117 | | 0163 | S087 |
| | | 0275 | S038 | Feng, Juefei | 0188 | S043 | | 0168 | S087 |
| | | 0267 | S050 | Feng, Yaping | 0191 | S052 | | 0090 | S096 |
| | | 0276 | S060 | Fialová, Jana | 0039 | S116 | | 0197 | S099 |
| | | 0266 | S092 | | 0049 | S117 | | 0022 | S101 |
| Copel, Laurian | | 0050 | S117 | Fong, Yewfah | 0186 | S021 | | 0028 | S109 |
| | | | | | 0189 | S044 | | 0029 | S110 |
| | | | | | 0242 | S025 | | 0020 | S120 |
| D | | | | Fu, Mingti | 0250 | S023 | | 0164 | S123 |
| Daijyun, Ro | 0120 | S083 | | Fu, Wei-guo | 0249 | S089 | | 0192 | S124 |
| Deng, Haoyu | 0236 | S125 | | | | | | | |
| Ding, Pengxu | 0242 | S025 | | Fujimura, Hironobu | 0033 | S102 | H | | |
| | 0241 | S059 | | Fukuoka, Ryosuke | 0102 | S043 | Ha, Tae-Yong | 0109 | S121 |
| Do, Young-Soo | 0113 | S097 | | Fung, TLD | 0052 | S118 | Hachiya, Takashi | 0098 | S080 |
| Do, YS | 0114 | S082 | | Furukawa, Hiroshi | 0208 | S037 | Hafizan, MT | 0057 | S054 |
| Dong, Kim Sang | 0137 | S084 | | | 0006 | S101 | Hamada, Mayumi | 0063 | S103 |
| Donmez, Didem Avci | 0030 | S094 | | G | | | | 0075 | S121 |
| | 0038 | S094 | | Garin, Aries | 0179 | S039 | Han, Duck Jong | 0100 | S096 |
| | 0051 | S095 | | Ge, Xiaohu | 0280 | S093 | | 0101 | S097 |
| Donmez, Koksai | 0168 | S087 | | Ge, Xiao-hu | 0271 | S025 | Han, Pil Ho | 0128 | S046 |
| | 0030 | S094 | | | 0268 | S038 | | 0122 | S084 |
| | 0038 | S094 | | | 0275 | S038 | Han, Seok | 0003 | S053 |
| | 0051 | S095 | | | 0267 | S050 | | 0004 | S115 |
| | 0090 | S096 | | | 0276 | S060 | Han, Seung-Rim | 0133 | S031 |
| | 0197 | S099 | | | 0263 | S091 | Han, Xinwei | 0242 | S025 |
| | 0022 | S101 | | | 0266 | S092 | Han, Young Min | 0076 | S103 |
| | 0028 | S109 | | | 0265 | S035 | Han, Youngjin | 0104 | S081 |
| | 0029 | S110 | | Ge, Yang-yang | 0220 | S119 | | 0118 | S083 |
| | 0164 | S123 | | Ghasemi, Navab | 0156 | S051 | | 0095 | S087 |
| Duan, Chen | 0192 | S124 | | Goh, Jason Chin Hock | 0163 | S087 | | 0100 | S096 |
| | 0265 | S035 | | Gokalp, Orhan | 0022 | S101 | | 0101 | S097 |
| | | | | | 0020 | S120 | | 0103 | S118 |
| | | | | Goktogan, Tayfun | 0144 | S055 | Hanif, H | 0057 | S054 |
| | | | | Govindarajanathan, Naresh | 0236 | S125 | Hanzawa, Kazuhiko | 0162 | S085 |
| E | | | | | 0228 | S032 | | 0054 | S111 |
| Ebine, Kunio | 0063 | S103 | | Gu, Yi | 0254 | S050 | Harada, Hirohisa | 0048 | S078 |
| | 0075 | S121 | | Gu, Yongquan | 0255 | S025 | | 0088 | S095 |
| Ebrahimi, Emad | 0108 | S055 | | | 0271 | S025 | Haruta, Naoki | 0017 | S020 |
| Edward-Hui, Kin-Leung | 0171 | S039 | | Guan, Sheng | 0268 | S038 | Hasegawa, Yutaka | 0056 | S079 |
| Elkaialy, Abdelrahman | 0190 | S036 | | | 0275 | S038 | Hashimoto, Takashi | 0046 | S111 |
| | 0157 | S114 | | | 0267 | S050 | Hayashi, Keita | 0083 | S103 |
| | 0160 | S122 | | | 0276 | S060 | | 0116 | S104 |
| | | | | | 0263 | S091 | Hayashi, Shinobu | 0082 | S020 |
| | 0090 | S096 | | | 0266 | S092 | Hayashida, Naoki | 0096 | S039 |
| Ergunes, Kazim | 0022 | S101 | | | | | | | |
| | 0020 | S120 | | | | | | | |
| | 0028 | S109 | | | | | | | |
| Ergunes, Kazim | 0028 | S109 | | | | | | | |
| Eygi, Bortecin | 0090 | S096 | | | | | | | |
| Ezure, Masahiko | 0056 | S079 | | | | | | | |

| Last Name | First Name | Presentation Code | Page | | | | | | |
|------------------------|------------|-------------------|------|-------------------------|------|------|---------------------------|------|------|
| | | | | Iner, Hasan | 0092 | S113 | Kawasaki, Masakazu | 0044 | S110 |
| | | | | Inoue, Kentaro | 0192 | S124 | Kawasaki, Yasuhito | 0102 | S043 |
| | | | | Inoue, Nozomu | 0017 | S020 | Kawaura, Hiroyuki | 0073 | S080 |
| Henmi, Soihito | | 0025 | S033 | Inoue, Yoshinori | 0044 | S110 | Kazemzadeh, Gholamhossein | | |
| Heo, Seon-Hee | | 0206 | S040 | Irie, Yoshihito | 0150 | S106 | | 0108 | S055 |
| Higashigawa, Takatoshi | | 0046 | S111 | Ishibashi, Yoshimitsu | 0215 | S099 | Keshavarzian, Amir | 0220 | S119 |
| Hirose, Nobuyuki | | 0096 | S039 | Ishii, Takaaki | 0044 | S110 | Khang, Nan Chuang | 0064 | S029 |
| Ho, Jackie | | 0124 | S098 | Iskesen, Ihsan | 0102 | S043 | Kiliccioglu, Filiz | 0163 | S087 |
| | | 0153 | S098 | | 0010 | S077 | Kim, Dae Yong | 0181 | S086 |
| Ho, Jackie Pei | | 0111 | S046 | | 0007 | S109 | | 0184 | S124 |
| | | 0156 | S051 | | | | Kim, DI | 0114 | S082 |
| Ho, Leung Sing | | 0069 | S042 | J | | | Kim, DK | 0114 | S082 |
| | | 0165 | S106 | Jamaludin, Mohd. Auri | 0144 | S055 | Kim, Dong-Ik | 0207 | S022 |
| Ho, LS | | 0052 | S118 | Jeon, Yong Sun | 0128 | S046 | | 0205 | S028 |
| Honda, Takeshi | | 0208 | S037 | | 0122 | S084 | | 0133 | S031 |
| | | 0006 | S101 | Jeong, Byeong kwon | 0184 | S124 | | 0206 | S040 |
| Honda, Tasuku | | 0091 | S112 | Jia, Senhao | 0223 | S040 | | 0143 | S043 |
| Hong, Kee Chun | | 0128 | S046 | | 0265 | S035 | | 0204 | S049 |
| | | 0122 | S084 | Jia, Xin | 0265 | S035 | | 0142 | S051 |
| Horii, Yosuke | | 0162 | S085 | | 0270 | S035 | | 0113 | S097 |
| Horsirimanont, Suthas | | 0070 | S023 | | 0223 | S040 | KIM, Doosang | 0159 | S052 |
| | | 0081 | S024 | | 0264 | S092 | Kim, Duk-kyung | 0207 | S022 |
| | | 0068 | S030 | | 0269 | S092 | Kim, Hag Zu | 0177 | S123 |
| | | 0121 | S046 | | 0279 | S093 | Kim, Hyoung Tae | 0182 | S119 |
| | | 0005 | S054 | Jiang, Jun-hao | 0250 | S023 | Kim, Jae Kyu | 0060 | S079 |
| Hoshina, Katsuyuki | | 0065 | S027 | Jin, Xing | 0251 | S048 | | 0061 | S079 |
| Hoshino, Shunichi | | 0077 | S042 | Jirasiritham, Chakrapan | 0081 | S024 | | 0059 | S095 |
| Hu, Lu | | 0191 | S052 | | 0121 | S046 | Kim, Jang Yong | 0128 | S046 |
| Hu, Yonghua | | 0262 | S029 | Jirasiritham, Sapon | 0070 | S023 | | 0127 | S057 |
| Hua, Su-rong | | 0232 | S047 | | 0068 | S030 | | 0132 | S084 |
| | | 0233 | S088 | | 0005 | S054 | Kim, Ji Il | 0127 | S057 |
| Hua, Zhaohui | | 0242 | S025 | Jun, Heungman | 0100 | S096 | | 0132 | S084 |
| | | 0241 | S059 | Jun, Kangwoong | 0036 | S120 | Kim, Jiil | 0037 | S116 |
| Huang, Bin | | 0273 | S026 | Jun, Kang-Woong | 0127 | S057 | | 0036 | S120 |
| | | 0261 | S041 | | 0132 | S084 | Kim, Jung Taek | 0122 | S084 |
| | | 0272 | S092 | Jung, Hyuk Jae | 0126 | S057 | Kim, Kyung-Mo | 0109 | S121 |
| Huang, Weibin | | 0237 | S108 | | 0123 | S104 | Kim, Mi Hyoung | 0127 | S057 |
| | | 0236 | S125 | | 0125 | S104 | | 0132 | S084 |
| Hui, Hon Cheung | | 0165 | S106 | | 0146 | S105 | Kim, Mihyeong | 0037 | S116 |
| Hui, Kin Leung | | 0221 | S107 | Jung, In Mok | 0147 | S122 | | 0036 | S120 |
| | | 0222 | S107 | | | | Kim, Min su | 0042 | S077 |
| Huo, Zijun | | 0085 | S048 | K | | | Kim, Min-Hyun | 0158 | S085 |
| Hwang, Hong Pil | | 0076 | S103 | Kabasawa, Masashi | 0096 | S039 | Kim, Sae-Lee | 0158 | S085 |
| Hwang, Jae Chol | | 0094 | S113 | Kalinova, Lucie | 0049 | S117 | Kim, Sang Dong | 0127 | S057 |
| Hyeong, Kim Mi | | 0137 | S084 | Kaneko, Tatsuo | 0056 | S079 | | 0132 | S084 |
| Hyun, Ahn Sang | | 0137 | S084 | Karaaslanyuksel, Ozlem | 0010 | S077 | Kim, Seong Chul | 0107 | S082 |
| Hyun, Seulgi | | 0182 | S119 | | 0007 | S109 | Kim, Young Hoon | 0100 | S096 |
| | | | | Karahan, Nagehan | 0028 | S109 | | 0101 | S097 |
| I | | | | | 0029 | S110 | Kim, Youngkyun | 0037 | S116 |
| Ido, Koki | | 0002 | S100 | | 0163 | S087 | Kim, Young-Wook | 0207 | S022 |
| Idoguchi, Koji | | 0209 | S032 | Katayama, Tomohiro | 0102 | S043 | | 0205 | S028 |
| | | 0210 | S086 | Katayama, Yoshihiko | 0017 | S020 | | 0133 | S031 |
| Igari, Kimihiro | | 0150 | S106 | Kato, Noriyuki | 0046 | S111 | | 0206 | S040 |
| Iizuka, Hirofumi | | 0073 | S080 | Katsui, Sotaro | 0150 | S106 | | 0143 | S043 |
| Imani, Mohammad | | 0220 | S119 | Kaw, Leoncio | 0194 | S125 | | 0204 | S049 |
| Inafuku, Hitoshi | | 0086 | S033 | Kaw, Leoncio Jr. | 0145 | S058 | | 0114 | S082 |
| | | 0129 | S105 | Kawakami, Atsushi | 0093 | S113 | | 0113 | S097 |

| Last Name | First Name | Presentation Code | Page | | | | | | |
|---------------------|------------|-------------------|------|-------------------------|------|------|------------------------|------|------|
| | | | | | 0103 | S118 | | 0255 | S025 |
| | | | | Kwon, Jae Hyun | 0095 | S087 | | 0241 | S059 |
| | | | | Kwon, Jeong Byeong | 0181 | S086 | | 0239 | S089 |
| Kim, Youn-Jung | | 0205 | S028 | Kwon, Tae-Won | 0104 | S081 | | 0240 | S089 |
| | | 0204 | S049 | | 0107 | S082 | Li, Zilun | 0260 | S059 |
| | | 0113 | S097 | | 0118 | S083 | Liang, Gangzhu | 0191 | S052 |
| Kimura, Chieri | | 0056 | S079 | | 0095 | S087 | Liang, Wei | 0224 | S088 |
| Kise, Yuya | | 0086 | S033 | | 0100 | S096 | | 0226 | S088 |
| | | 0092 | S113 | | 0101 | S097 | Lin, Fan | 0278 | S053 |
| Kita, syouta | | 0106 | S081 | | 0103 | S118 | Lin, Zhimin | 0155 | S051 |
| Kitagawa, Yuko | | 0082 | S020 | Kye, Hwang Jeong | 0137 | S084 | | 0180 | S106 |
| Kitanaka, Yosuke | | 0106 | S081 | Kyuragi, Ryoichi | 0026 | S101 | Liu, Bao | 0232 | S047 |
| Kitanaka, Yousuke | | 0120 | S083 | | | | Liu, Chang-wei | 0232 | S047 |
| | | 0135 | S121 | L | | | | 0233 | S088 |
| Kito, Hiroyuki | | 0096 | S039 | Lafci, Banu | 0090 | S096 | Liu, Dan | 0258 | S091 |
| Ko, Gi-Young | | 0104 | S081 | | 0022 | S101 | Liu, Hui | 0257 | S028 |
| | | 0109 | S121 | Lajom, Cristina Marie | 0179 | S039 | Liu, Huimin | 0188 | S043 |
| Kobayashi, Hiromasa | | 0055 | S102 | Lam, YH | 0173 | S036 | | 0189 | S044 |
| Kobayashi, Yutaka | | 0093 | S113 | Lapena-Kare, Lara | 0179 | S039 | Liu, Jiang-tao | 0278 | S053 |
| Köcher, Martin | | 0039 | S116 | Lat, Alexander | 0179 | S039 | Liu, Jie | 0265 | S035 |
| Koda, Yojiro | | 0119 | S114 | Lau, James | 0173 | S036 | | 0223 | S040 |
| Kodama, Akio | | 0062 | S026 | Lau, Rainbow | 0172 | S021 | | 0264 | S092 |
| | | 0110 | S082 | Law, Y | 0152 | S020 | | 0279 | S093 |
| Kohno, Kenji | | 0063 | S103 | Law, Yuk | 0149 | S027 | Liu, Peng | 0234 | S049 |
| | | 0075 | S121 | | 0154 | S027 | | 0278 | S053 |
| Koike, Norimasa | | 0047 | S078 | | 0078 | S086 | Liu, Shirui | 0241 | S059 |
| | | 0098 | S080 | Lawanwong, Kwanchai | 0005 | S054 | Liu, Xiaoping | 0270 | S035 |
| Koizumi, Shinya | | 0150 | S106 | Lee, Ho Kyun | 0060 | S079 | | 0269 | S092 |
| Komada, Takuya | | 0017 | S020 | | 0061 | S079 | Liu, Yiren | 0272 | S092 |
| Komori, Kimihiro | | 0062 | S026 | | 0059 | S095 | Liu, Yue | 0087 | S034 |
| | | 0110 | S082 | | 0177 | S123 | Lo, Wai Yin | 0069 | S042 |
| Kondo, Shunichi | | 0215 | S099 | Lee, Jae Hoon | 0045 | S078 | | 0165 | S106 |
| Kong, Tae Hyun | | 0128 | S046 | Lee, Ji Ho | 0126 | S057 | Lo, WY | 0052 | S118 |
| | | 0122 | S084 | | 0123 | S104 | Lorber, Jonathan | 0050 | S117 |
| Kou, Lei | | 0257 | S028 | | 0125 | S104 | Lu, Lei | 0237 | S108 |
| | | 0259 | S091 | | 0146 | S105 | Luo, Hailong | 0272 | S092 |
| Kudo, Toshifumi | | 0150 | S106 | Lee, Jinkee | 0138 | S118 | Luo, Han | 0272 | S092 |
| Kum, Wei Cheong | | 0281 | S108 | Lee, Ju Yeon | 0104 | S081 | Luo, Xiaoyun | 0191 | S052 |
| Kuma, Sosei | | 0026 | S101 | | 0095 | S087 | LV, Lei | 0235 | S047 |
| Kumagai, Kenta | | 0063 | S103 | Lee, KF | 0152 | S020 | | 0236 | S125 |
| | | 0075 | S121 | Lee, Kwok Fai | 0154 | S027 | | | |
| Kumaraguru, P | | 0057 | S054 | Lee, Sang Su | 0126 | S057 | M | | |
| Kunanuson, Chaiwat | | 0018 | S119 | | 0123 | S104 | M, Vishnu | 0134 | S050 |
| Kunishige, Hideyuki | | 0044 | S110 | | 0125 | S104 | | 0136 | S057 |
| Kuniyoshi, Yukio | | 0086 | S033 | | 0146 | S105 | Ma, Bo | 0278 | S053 |
| | | 0129 | S105 | Lee, SK | 0057 | S054 | Ma, Xiaohui | 0270 | S035 |
| | | 0092 | S113 | Lee, Sung-Gyu | 0109 | S121 | | 0269 | S092 |
| Kurdal, Taner | | 0010 | S077 | Lee, Tae-Seung | 0158 | S085 | Ma, Xiu-xian | 0255 | S025 |
| | | 0007 | S109 | Leela-Udomlipi, Surasak | 0070 | S023 | Ma, Yukui | 0261 | S041 |
| Kusagawa, Hitoshi | | 0017 | S020 | | 0068 | S030 | | 0272 | S092 |
| Kuwada, Noriaki | | 0208 | S037 | | 0005 | S054 | Maeda, Tatsuya | 0092 | S113 |
| | | 0006 | S101 | Leong, BDK | 0057 | S054 | Maglaya, Patrick Louie | 0194 | S125 |
| Kwok, Micky | | 0172 | S021 | Lertsithichai, Panuwat | 0005 | S054 | Majumder, Arunesh | 0105 | S045 |
| Kwon, Hyunwok | | 0109 | S121 | Li, Jin-sheng | 0249 | S089 | Mal, Lekhraj | 0185 | S059 |
| Kwon, Hyunwook | | 0104 | S081 | Li, Song-Qi | 0277 | S035 | Manani, Reza | 0108 | S055 |
| | | 0107 | S082 | Li, Yong-jun | 0232 | S047 | Maruta, Kazuto | 0073 | S080 |
| | | 0118 | S083 | Li, Zhen | 0242 | S025 | Masaki, Hisao | 0208 | S037 |

| Last Name | First Name | Presentation Code | Page | | | | | | |
|--------------------|------------|-------------------|------|---------------------|------|------|----------------------------|------|------|
| | | | | Nagashima, Atsushi | 0116 | S104 | | 0119 | S114 |
| | | | | Nagata, Tokuchirou | 0106 | S081 | Omura, Atushi | 0169 | S058 |
| | | | | Naito, Noritsugu | 0056 | S079 | Ono, Hirokuni | 0106 | S081 |
| | | 0006 | S101 | Najm, Haney | 0160 | S122 | | 0120 | S083 |
| Matsubara, Kentaro | | 0082 | S020 | Nakaema, Moriyasu | 0092 | S113 | | 0135 | S121 |
| Matsuda, Hitoshi | | 0025 | S033 | Nakagiri, Keitaro | 0025 | S033 | Ono, Makoto | 0106 | S081 |
| | | 0169 | S058 | Nakaji, Shun | 0055 | S102 | Oono, Makoto | 0120 | S083 |
| | | 0091 | S112 | Nakamura, Masahiro | 0150 | S106 | | 0135 | S121 |
| | | 0119 | S114 | Nakayama, Yoshihiro | 0002 | S100 | Orejola, Wilmo | 0087 | S034 |
| Matsuno, Yukihiro | | 0089 | S112 | Namura, Osamu | 0162 | S085 | Othman, Ahmad Faidzal | 0198 | S056 |
| Matsuo, Kouzou | | 0096 | S039 | | 0054 | S111 | | 0201 | S099 |
| Matsuo, Tatsuro | | 0170 | S114 | Napolitano, Massimo | 0087 | S034 | | 0199 | S107 |
| | | 0176 | S115 | Narayanan, Sriram | 0186 | S021 | | 0200 | S119 |
| Mayahara, Taku | | 0102 | S043 | | 0188 | S043 | Otsuru, Minoru | 0102 | S043 |
| Mayumi, Kensaku | | 0102 | S043 | | 0189 | S044 | ozbakaloglu, alper | 0010 | S077 |
| Mei, Jiakai | | 0230 | S037 | Naresh, G | 0057 | S054 | Ozbakaloglu, Alper | 0007 | S109 |
| Mii, Shinsuke | | 0026 | S101 | Narita, Hiroshi | 0062 | S026 | Ozbek, Cengiz | 0028 | S109 |
| Miki, Takao | | 0047 | S078 | | 0110 | S082 | Ozeki, Yasuhiro | 0063 | S103 |
| | | 0098 | S080 | Ng, Calvin | 0172 | S021 | | 0075 | S121 |
| Minami, Hitoshi | | 0025 | S033 | Ng, Jun Jie | 0124 | S098 | Ozu, Yasuhisa | 0017 | S020 |
| | | 0169 | S058 | Ninomiya, Kenji | 0063 | S103 | | | |
| | | 0091 | S112 | | 0075 | S121 | P | | |
| Mitsuoka, Hiroshi | | 0071 | S030 | Nishimaki, Hiroshi | 0106 | S081 | Paharudin, Mohd Abdul Rauf | | |
| Miyairi, Takeshi | | 0106 | S081 | | 0120 | S083 | | 0200 | S119 |
| | | 0120 | S083 | | 0135 | S121 | Pan, Ye | 0230 | S037 |
| | | 0135 | S121 | Nishino, Takako | 0096 | S039 | Pandey, Sandeep Raj | 0016 | S056 |
| Mohamad, Hasmali | | 0201 | S099 | Nishiyama, Jyunji | 0102 | S043 | | 0015 | S077 |
| Mohara, Jun | | 0047 | S078 | Nishizawa, Masato | 0150 | S106 | | 0141 | S122 |
| | | 0098 | S080 | Niu, Luyuan | 0191 | S052 | Pang, Yin Chun Skyi | 0178 | S124 |
| Moon, In Sung | | 0127 | S057 | Nobuhiko, Mukohara | 0091 | S112 | Panoi, Anucha | 0018 | S119 |
| | | 0132 | S084 | Nomura, Takuo | 0032 | S110 | Park, Ho-Chul | 0216 | S044 |
| | | 0037 | S116 | Nomura, Yoshikatsu | 0209 | S032 | Park, Hojong | 0094 | S113 |
| | | 0036 | S120 | | 0210 | S086 | Park, Hong-Seok | 0113 | S097 |
| Moon, In-Hye | | 0158 | S085 | O | | | Park, Hyung-Sup | 0158 | S085 |
| Mori, Yoshio | | 0089 | S112 | Obara, Hideaki | 0082 | S020 | Park, Jae Young | 0080 | S055 |
| Moriki, Naoya | | 0063 | S103 | O'Connor, David | 0087 | S034 | Park, Keun-Myoung | 0128 | S046 |
| | | 0075 | S121 | Oda, Teiji | 0131 | S036 | | 0122 | S084 |
| Morishima, Yuji | | 0129 | S105 | Ogawa, Tomohiro | 0077 | S042 | Park, Ki Hyuk | 0045 | S078 |
| Mukae, Yosuke | | 0002 | S100 | Ogawa, Yukihiisa | 0120 | S083 | Park, Kihyuk | 0193 | S022 |
| Mukohara, Nobuhiko | | 0025 | S033 | Oh, Ji Sun | 0094 | S113 | Park, Kwang-Bo | 0113 | S097 |
| | | 0169 | S058 | Ohba, Masanao | 0096 | S039 | Park, Oh Hyun | 0060 | S079 |
| | | 0119 | S114 | Ohkubo, Hirotoki | 0082 | S020 | | 0061 | S079 |
| Muradi, Akhmadu | | 0209 | S032 | | 0083 | S103 | Park, Sang Jun | 0059 | S095 |
| | | 0210 | S086 | | 0116 | S104 | Park, Sun Cheol | 0094 | S113 |
| Murakami, Hirohisa | | 0025 | S033 | Okada, Syuichi | 0056 | S079 | Park, Sun Chul | 0138 | S118 |
| | | 0169 | S058 | Okada, Takuya | 0209 | S032 | | 0127 | S057 |
| | | 0091 | S112 | | 0210 | S086 | | 0132 | S084 |
| | | 0119 | S114 | Okamoto, Takeshi | 0162 | S085 | Park, Uijun | 0182 | S119 |
| Murase, Toshifumi | | 0063 | S103 | | 0054 | S111 | Park, Yang-Jin | 0133 | S031 |
| | | 0075 | S121 | Okita, Yutaka | 0209 | S032 | | 0207 | S022 |
| Murayama, Hirokazu | | 0096 | S039 | | 0210 | S086 | | 0205 | S028 |
| Myslavec, Miroslav | | 0049 | S117 | Okonogi, Shuichi | 0056 | S079 | | 0206 | S040 |
| N | | | | Okuda, Sumio | 0002 | S100 | | 0143 | S043 |
| Nagano, Takaaki | | 0092 | S113 | Omoto, Tadashi | 0073 | S080 | | 0204 | S049 |
| Nagao, Kanetsugu | | 0170 | S114 | Omura, Atsushi | 0025 | S033 | Park, Yoong-Seok | 0113 | S097 |
| | | 0176 | S115 | | 0091 | S112 | | 0133 | S031 |
| | | | | | | | | 0143 | S043 |

| Last Name | First Name | Presentation Code | Page | | | | | | |
|-----------------------------------|------------|-------------------|------|---------------------------|------|------|---------------------|------|------|
| | | | | Sai, Li-mu | 0136 | S057 | Sriram, Narayanan | 0112 | S031 |
| | | | | Sailimu, | 0276 | S060 | Suehiro, Syouchi | 0131 | S036 |
| | | | | Saito, Takaaki | 0268 | S038 | Suesawatee, Arkom | 0070 | S023 |
| Park, Yung-Seok | | 0206 | S040 | | 0071 | S030 | | 0068 | S030 |
| Pei, Jackie Ho | | 0105 | S045 | Sakai, Mari | 0169 | S058 | Sueta, Tomonori | 0096 | S039 |
| Peker, Ihsan | | 0090 | S096 | Sakamoto, Seizaburo | 0055 | S102 | Sugimoto, Koji | 0209 | S032 |
| | | 0197 | S099 | Sakata, Kimimasa | 0170 | S114 | | 0210 | S086 |
| | | 0164 | S123 | | 0176 | S115 | Sugimoto, Masayuki | 0062 | S026 |
| | | 0192 | S124 | Sakboon, Boonsap | 0167 | S123 | | 0110 | S082 |
| Pongrattananan, Nunthapol | | | | Sakurai, Yuka | 0106 | S081 | Suh, Bo-Yang | 0151 | S098 |
| | | 0018 | S119 | | 0120 | S083 | Sun, Xiaojie | 0246 | S041 |
| Pootracool, Piyanut | | 0070 | S023 | | 0135 | S121 | | 0247 | S041 |
| | | 0068 | S030 | Salimi, Fereshteh | 0220 | S119 | Sundeeep, Punamiya | 0112 | S031 |
| Pootrakool, Piyanut | | 0005 | S054 | Sanchez, Josefino | 0179 | S039 | Sung, KI | 0114 | S082 |
| Poprom, Napaphat | | 0081 | S024 | Sato, Hiroki | 0162 | S085 | Sung, Won Yong | 0137 | S084 |
| | | 0121 | S046 | Satou, Hiroki | 0054 | S111 | Suresh, K.R. | 0134 | S050 |
| Purino, Pio | | 0179 | S039 | Seki, Koji | 0170 | S114 | | 0136 | S057 |
| | | | | | 0176 | S115 | Suzuki, Haruo | 0093 | S113 |
| Q | | | | Sekimoto, Yasuhito | 0048 | S078 | Suzuki, Hirotooshi | 0106 | S081 |
| Qi, Lixing | | 0228 | S032 | | 0088 | S095 | | 0120 | S083 |
| Qian, Song-yi | | 0278 | S053 | Seo, Young Woo | 0094 | S113 | | 0135 | S121 |
| Qin, Yanwen | | 0259 | S091 | Seob, Yun Sang | 0137 | S084 | | | |
| Qiu, Jiehua | | 0245 | S038 | Seok, Nam Woo | 0137 | S084 | T | | |
| | | 0244 | S108 | Shao, Mingzhe | 0230 | S037 | Tabata, Koki | 0110 | S082 |
| | | | | Shen, Wei | 0236 | S125 | Tabuchi, Atsushi | 0208 | S037 |
| R | | | | Shi, Ya-Xue | 0224 | S088 | Tabuchi, Atushi | 0006 | S101 |
| Rabin, Igor | | 0050 | S117 | Shibata, Ryuichiro | 0055 | S102 | Taguchi, Tomohiro | 0002 | S100 |
| Rahman, Mohd Norhisham Azmi Abdul | | | | Shibutani, Shintaro | 0082 | S020 | Takahara, Masaki | 0055 | S102 |
| | | 0198 | S056 | | 0083 | S103 | Takahashi, Baku | 0002 | S100 |
| | | 0201 | S099 | | 0116 | S104 | Takahashi, Toru | 0047 | S078 |
| | | 0200 | S119 | Shibuya, Kei | 0047 | S078 | | 0098 | S080 |
| Rahman, Norhafiza Abdul | | | | | 0098 | S080 | Takashima, Kyoko | 0063 | S103 |
| | | 0199 | S107 | Shigematsu, Kunihiro | 0065 | S027 | | 0075 | S121 |
| Raj, Sumanth | | 0134 | S050 | | 0024 | S045 | Takemoto, Koichiro | 0055 | S102 |
| | | 0136 | S057 | Shih, Chun-Che | 0166 | S031 | Takeuchi, Katsunori | 0170 | S114 |
| Rashad, Izatt Syafieq Abd | | | | Shimizu, Kouji | 0131 | S036 | | 0176 | S115 |
| | | 0201 | S099 | Shin, Hong-Kyoung | 0158 | S085 | Takeyoshi, Izumi | 0047 | S078 |
| Rehman, Zia Ur | | 0187 | S032 | Shinozaki, Koji | 0102 | S043 | | 0098 | S080 |
| | | 0185 | S059 | Shirasu, Takuro | 0065 | S027 | Takahara, Hitomi | 0056 | S079 |
| Ren, Hao | | 0271 | S025 | Shiroma, Shinyu | 0002 | S100 | Takiuchi, Hiroki | 0208 | S037 |
| | | 0268 | S038 | Si, Lok Ping | 0221 | S107 | | 0006 | S101 |
| | | 0275 | S038 | | 0222 | S107 | Takiya, Hiroshi | 0089 | S112 |
| | | 0267 | S050 | Simonian, Gregory | 0087 | S034 | Tamura, Susumu | 0063 | S103 |
| | | 0276 | S060 | Singh, Amritpal | 0111 | S046 | | 0075 | S121 |
| | | 0263 | S091 | Siribumrungwong, Boonying | | | Tan, Chun Hai | 0112 | S031 |
| | | 0266 | S092 | | 0081 | S024 | Tan, KL | 0057 | S054 |
| Ren, Shi-yan | | 0278 | S053 | | 0121 | S046 | Tan, Ming Yuan | 0186 | S021 |
| Renny-Yien, Ling-Chu | | 0171 | S039 | Skyi-Pang, Yin-Chun | 0171 | S039 | Tan, Seck Guan | 0155 | S051 |
| Ro, Daijyun | | 0106 | S081 | So, Byung Jun | 0181 | S086 | Tan, Yin Kai | 0281 | S108 |
| | | 0135 | S121 | | 0184 | S124 | Tanabe, Tomoaki | 0074 | S111 |
| Rokkaku, Kyu | | 0215 | S099 | Soh, Young Ho | 0147 | S122 | Tanaka, Kiyoshi | 0026 | S101 |
| | | | | Song, Dan | 0003 | S053 | Tanemoto, Kazuo | 0208 | S037 |
| S | | | | | 0004 | S115 | | 0006 | S101 |
| Sagane, Masahiro | | 0106 | S081 | Song, Ki Byung | 0101 | S097 | Tang, Chung Ngai | 0171 | S039 |
| Sagane, Masanori | | 0120 | S083 | Song, Xiao-jun | 0232 | S047 | | 0178 | S124 |
| Sagane, Masatoshi | | 0135 | S121 | Sophie, Ziad | 0187 | S032 | Tang, Haitao | 0238 | S048 |
| Sahu, Tapish | | 0134 | S050 | | 0185 | S059 | Tang, Jia Re Ke | 0275 | S038 |

| Last Name | First Name | Presentation Code | Page | | | | | | |
|-----------------------|------------|-------------------|------|-------------------------|------|------|---------------------|------|------|
| | | | | Wan, Song | 0173 | S036 | Wu, Haisheng | 0230 | S037 |
| | | | | | 0172 | S021 | Wu, Hejie | 0246 | S041 |
| | | | | | 0173 | S036 | | 0247 | S041 |
| | | 0267 | S050 | Wang, Fei | 0278 | S053 | Wu, Qinghua | 0257 | S028 |
| | | 0266 | S092 | Wang, Jingsong | 0085 | S048 | Wu, Ridong | 0085 | S048 |
| Tang, Xiaobin | | 0257 | S028 | Wang, Jinsong | 0260 | S059 | Wu, Tao | 0262 | S029 |
| Tang, Xiao-bin | | 0258 | S091 | Wang, JinSong | 0256 | S090 | Wu, Wei-wei | 0232 | S047 |
| Taniguchi, Ryosuke | | 0024 | S045 | Wang, Jin-Song | 0277 | S035 | | 0233 | S088 |
| Taniguchi, Shinichiro | | 0055 | S102 | Wang, Lijun | 0270 | S035 | Wu, Xuejun | 0251 | S048 |
| Taoka, Makoto | | 0074 | S111 | | 0269 | S092 | Wu, Zhangmin | 0257 | S028 |
| Tatebe, Shou | | 0074 | S111 | Wang, Maohua | 0251 | S048 | Wu, Zhiwei | 0241 | S059 |
| Tay, Jia Sheng | | 0281 | S108 | Wang, Mian | 0277 | S035 | Wu, Zhong-yin | 0265 | S035 |
| Tei, Eiichi | | 0074 | S111 | Wang, Peng | 0226 | S088 | Wu, Zhoupeng | 0273 | S026 |
| Tei, Imun | | 0074 | S111 | Wang, Sheng | 0257 | S028 | | 0272 | S092 |
| Temudom, Tamrongroj | | 0018 | S119 | | 0259 | S091 | | | |
| Tetik, Omer | | 0010 | S077 | Wang, Shenming | 0085 | S048 | X | | |
| | | 0007 | S109 | | 0260 | S059 | Xie, Hui | 0235 | S047 |
| Thakkinstian, Ammarin | | 0081 | S024 | Wang, Shen-Ming | 0277 | S035 | | 0237 | S108 |
| | | 0121 | S046 | Wang, Siwen | 0085 | S048 | | 0236 | S125 |
| Thant, Kyi Zin | | 0156 | S051 | Wang, Tiehao | 0272 | S092 | Xie, Jun | 0236 | S125 |
| Tian, Guang-lei | | 0275 | S038 | Wang, Xiaotian | 0246 | S041 | Xiong, Fei | 0261 | S041 |
| | | 0267 | S050 | | 0247 | S041 | | 0272 | S092 |
| | | 0276 | S060 | Wang, Yu-qi | 0250 | S023 | Xiong, Jiang | 0262 | S029 |
| | | 0266 | S092 | | 0249 | S089 | | 0270 | S035 |
| Ting, Albert CW | | 0152 | S020 | Wang, Zhiwei | 0242 | S025 | | 0269 | S092 |
| | | 0148 | S034 | | 0241 | S059 | Xiong, Jixin | 0245 | S038 |
| | | 0154 | S027 | Wang, Zhi-wei | 0255 | S025 | | 0244 | S108 |
| Tirapanich, Wiwat | | 0070 | S023 | Wang, Zhonggao | 0242 | S025 | Xu, Peng | 0241 | S059 |
| | | 0068 | S030 | | 0228 | S032 | | | |
| | | 0005 | S054 | | 0254 | S050 | Y | | |
| Toi, Satoru | | 0063 | S103 | | 0241 | S059 | Yamaguchi, Masato | 0209 | S032 |
| | | 0075 | S121 | Wang, Zhong-Gao | 0239 | S089 | | 0210 | S086 |
| Tominaga, Yuki | | 0063 | S103 | | 0240 | S089 | Yamamoto, Kiyohito | 0062 | S026 |
| | | 0075 | S121 | Watanabe, Shinichi | 0063 | S103 | | 0110 | S082 |
| Tong, Sheau Wann | | 0031 | S042 | | 0075 | S121 | Yamamoto, Yohei | 0150 | S106 |
| Tono, Ken | | 0102 | S043 | Watanabe, Toshiaki | 0065 | S027 | Yamasawa, Takahiko | 0208 | S037 |
| Totsuka, Yuichi | | 0129 | S105 | | 0024 | S045 | | 0006 | S101 |
| | | 0092 | S113 | Watanabe, Yoshiko | 0208 | S037 | Yamashiro, Naotsugu | 0083 | S103 |
| Toyohuku, Takahiro | | 0150 | S106 | | 0006 | S101 | | 0116 | S104 |
| Tsai, Tsung-Chih | | 0008 | S115 | Wei, Ren | 0274 | S093 | Yamashiro, Satoshi | 0086 | S033 |
| Tsuboi, Eitochi | | 0215 | S099 | Wei, Yingqi | 0262 | S029 | | 0129 | S105 |
| Tsuchida, Masanori | | 0162 | S085 | Wijerathne, Sujith | 0153 | S098 | | 0092 | S113 |
| | | 0054 | S111 | Wilasrusmee, Chumpon | 0081 | S024 | Yamashita, Akio | 0170 | S114 |
| Tsuyuki, Kazuo | | 0063 | S103 | | 0121 | S046 | | 0176 | S115 |
| | | 0075 | S121 | Wildermann, Michael | 0087 | S034 | Yamazoe, Shinji | 0048 | S078 |
| Tu, Jian | | 0085 | S048 | Wong, Po Yan | 0069 | S042 | Yang, Jae Do | 0076 | S103 |
| | | | | Wong, Randolph | 0172 | S021 | Yang, Liao | 0257 | S028 |
| U | | | | | 0173 | S036 | Yang, Shin-Seok | 0099 | S081 |
| Ueshima, Eisuke | | 0210 | S086 | Wongserepipatana, Jarim | | | Yang, Yaoguo | 0259 | S091 |
| Umeda, Yukio | | 0089 | S112 | | 0081 | S024 | Yang, Yi | 0273 | S026 |
| Underwood, Malcolm | | 0172 | S021 | | 0121 | S046 | | 0261 | S041 |
| | | 0173 | S036 | Woo, Shin-Young | 0207 | S022 | | 0272 | S092 |
| Utikal, Petr | | 0039 | S116 | | 0205 | S028 | Yang, Yu-guang | 0278 | S053 |
| | | 0049 | S117 | | 0133 | S031 | Yano, Hiroyoshi | 0063 | S103 |
| | | | | | 0204 | S049 | | 0075 | S121 |
| W | | | | Woong, Jun Kang | 0137 | S084 | Yao, Chen | 0277 | S035 |
| Wan, Innes | | 0172 | S021 | Wu, Danming | 0238 | S048 | | 0085 | S048 |

| Last Name | First Name | Presentation Code | Page | | | | | | |
|-------------------------|------------|-------------------|------|-----------------------------|------|------|------------------|------|------|
| | | | | Yu, Simon | 0173 | S036 | | 0241 | S059 |
| | | | | Yuan, Ding | 0273 | S026 | Zhang, Wen-Guang | 0239 | S089 |
| | | | | | 0261 | S041 | | 0240 | S089 |
| | | 0260 | S059 | | 0272 | S092 | Zhao, Hui | 0191 | S052 |
| Yasuda, Seiji | | 0102 | S043 | Yuan, Kai | 0235 | S047 | Zhao, Jichu | 0272 | S092 |
| Yazman, Serkan | | 0022 | S101 | Yuan, Lianxi | 0252 | S090 | Zhao, Jichun | 0273 | S026 |
| | | 0020 | S120 | | 0253 | S090 | | 0261 | S041 |
| Ye, Meng | | 0235 | S047 | Yuan, Qingwen | 0244 | S108 | Zhao, Jun | 0230 | S037 |
| | | 0224 | S088 | Yue, Jia-ning | 0250 | S023 | Zhen, Ya-nam | 0278 | S053 |
| | | 0237 | S108 | | 0249 | S089 | Zheng, Xia | 0278 | S053 |
| | | 0236 | S125 | Yun, Sang Seob | 0127 | S057 | Zhou, Wei | 0245 | S038 |
| Ye, Wei | | 0232 | S047 | | 0132 | S084 | Zhou, Weimin | 0245 | S038 |
| | | 0233 | S088 | Yun, Sangchul | 0003 | S053 | | 0244 | S108 |
| Ye, Zhi-dong | | 0234 | S049 | | 0004 | S115 | Zhou, Yi-Ping | 0224 | S088 |
| | | 0278 | S053 | Yun, Woo-Sung | 0151 | S098 | Zhou, Yubin | 0238 | S048 |
| Yetkin, Ufuk | | 0163 | S087 | Yunoki, Yasuhiro | 0208 | S037 | Zhu, Bin | 0271 | S025 |
| | | 0168 | S087 | | 0006 | S101 | Zhu, Bing | 0267 | S050 |
| | | 0030 | S094 | Yurekli, Ismail | 0163 | S087 | | 0276 | S060 |
| | | 0038 | S094 | | 0020 | S120 | | 0266 | S092 |
| | | 0051 | S095 | Yusa, Hiroaki | 0074 | S111 | Zhu, Feng | 0267 | S050 |
| | | 0197 | S099 | Yusof, Nazri Mohd | 0201 | S099 | Zhu, XiaoNan | 0256 | S090 |
| | | 0028 | S109 | Yusof, Sulaiman Bin | 0281 | S108 | Zuo, Shangwei | 0262 | S029 |
| | | 0029 | S110 | | | | | | |
| | | 0020 | S120 | Z | | | | | |
| | | 0164 | S123 | Zainal, AA | 0057 | S054 | | | |
| | | 0192 | S124 | Zan, Mohamad Sallehudin Che | | | | | |
| Yeung, Eugene | | 0172 | S021 | | 0201 | S099 | | | |
| Yih, Chun Ling Patricia | | 0178 | S124 | Zeng, Guojun | 0273 | S026 | | | |
| Yildirim, Funda | | 0010 | S077 | | 0261 | S041 | | | |
| | | 0007 | S109 | | 0272 | S092 | | | |
| Yilik, Levent | | 0090 | S096 | Zeng, Rong | 0232 | S047 | | | |
| | | 0020 | S120 | Zhai, Mengyao | 0257 | S028 | | | |
| Yilik, Levent | | 0022 | S101 | Zhang, Changming | 0191 | S052 | | | |
| Yin, Henghui | | 0085 | S048 | Zhang, Fuxian | 0213 | S023 | | | |
| | | 0260 | S059 | | 0211 | S025 | | | |
| | | 0256 | S090 | | 0191 | S052 | | | |
| Yin, Heng-Hui | | 0277 | S035 | | 0212 | S053 | | | |
| Yip, HC | | 0152 | S020 | Zhang, Hao | 0224 | S088 | | | |
| YIP, Hon Chi | | 0154 | S027 | Zhang, Hongpeng | 0223 | S040 | | | |
| | | 0148 | S034 | | 0269 | S092 | | | |
| Yokawa, Koki | | 0032 | S110 | Zhang, Huan | 0191 | S052 | | | |
| Yokoi, Yoshihiko | | 0054 | S111 | Zhang, Jian | 0228 | S032 | | | |
| Yokomuro, Masashi | | 0063 | S103 | | 0230 | S037 | | | |
| | | 0075 | S121 | | 0254 | S050 | | | |
| Yokouchi, Itaru | | 0063 | S103 | Zhang, Jingyong | 0251 | S048 | | | |
| | | 0075 | S121 | Zhang, Jiwei | 0236 | S125 | | | |
| Yokoyama, Hitoshi | | 0215 | S099 | Zhang, Ji-Wei | 0235 | S047 | | | |
| Yong, Kim Jang | | 0137 | S084 | | 0224 | S088 | | | |
| Yoo, Chang Hyun | | 0080 | S055 | | 0237 | S108 | | | |
| Yoshida, Masato | | 0025 | S033 | Zhang, Junbin | 0256 | S090 | | | |
| | | 0169 | S058 | Zhang, Lan | 0235 | S047 | | | |
| | | 0091 | S112 | | 0237 | S108 | | | |
| | | 0119 | S114 | | 0236 | S125 | | | |
| Yoshimura, Naoki | | 0170 | S114 | Zhang, Minhong | 0223 | S040 | | | |
| | | 0176 | S115 | Zhang, Tao | 0269 | S092 | | | |
| You, Qingsheng | | 0230 | S037 | Zhang, Tengfei | 0259 | S091 | | | |
| Yu, Hee Chul | | 0076 | S103 | Zhang, Wenguang | 0242 | S025 | | | |