

Case Report

Fetal Intra-Abdominal Umbilical Vein Varix in Monochorionic Twins: Is it Significant?

Hamizah ISMAIL¹, Yao-Lung CHANG^{2,3}, Shuenn-Dyh CHANG^{2,3},
Zalina NUSEE¹

Submitted: 8 Jul 2011
Accepted: 25 Nov 2011

¹ Department of Obstetrics and Gynaecology, Kulliyah of Medicine, International Islamic University Malaysia, Jalan Hospital Campus, 25100, Kuantan, Pahang, Malaysia

² Department of Obstetrics and Gynecology, Linkou Chang Gung Memorial Hospital, 5, Fu-Hsing Street, Kuei Shan Hsiang, Taoyuan Hsien, 333, Taiwan, Republic of China

³ College of Medicine, Chang Gung University, 259 Wen-Hwa 1st Road, Kwei-Shan Tao-Yuan, 333, Taiwan, Republic of China

Abstract

A 30-years-old Taiwanese female in her second pregnancy spontaneously conceived a monochorionic twin pregnancy. A routine ultrasound at 27 weeks of gestation revealed a selective intrauterine growth restriction (sIUGR) fetus and an appropriate gestational age (AGA) fetus. The AGA fetus was found to have a fetal intra-abdominal umbilical vein (FIUV) varix. Serial ultrasounds showed no changes in the FIUV varix. 2 weeks later, the pregnancy progressed to twin-twin transfusion syndrome (TTTS). Repeated amnioreductions were required at 29 and 30 weeks gestation. The babies were delivered by caesarean section at 31 weeks due to fetal distress in the sIUGR fetus. Both fetuses survived the neonatal period with problems of prematurity. The FIUV varix disappeared a few days after delivery.

Keywords: intra-abdominal, multiple pregnancies, ultrasound, umbilical vein, varix

Introduction

The evolution of ultrasound techniques has improved the diagnosis and follow-up management of fetal intra-abdominal umbilical vein (FIUV) varix. The detection of a cystic mass along the natural course of the umbilical vein with grey scale ultrasound raises the suspicions of a FIUV varix. However, colour and pulsed Doppler can further define the venous vascular anomalies, and these techniques are useful for detecting and monitoring thromboses (1).

FIUV varix is defined as an umbilical vein diameter of more than 9 mm or when the diameter is larger than the intra-hepatic portion of the vein by 50% or more (2). It has been associated with intrauterine fetal death, structural fetal anomalies, chromosomes anomalies, trisomy 21, hydrops fetalis, and intrauterine growth restriction (IUGR) (3). Favourable outcomes were reported especially when there were no co-existing fetal abnormalities (4). The management of FIUV varix, especially the follow-up and timing of delivery, is still controversial.

More than 100 cases of FIUV varix have been reported in singleton pregnancies, but to date, no reported cases have specifically involved multiple pregnancies. We report a case of monochorionic twins with a selective intrauterine growth restriction (sIUGR) fetus and an appropriate gestational age (AGA) fetus with a FIUV varix. The pregnancy then progressed to twin-twin transfusion syndrome (TTTS).

Case Report

A 30-years-old Taiwanese, gravida 2 para 1 female was managed at our tertiary care centre for a monochorionic twin pregnancy. Her first pregnancy was uneventful, and she had no previous history of twins or congenital anomalies. She was a non-smoker, and her marriage was non-consanguineous. Her blood group is B rhesus positive, and her husband's blood group is A rhesus negative.

A routine ultrasound at 12 weeks gestation

revealed a monochorionic diamniotic twin pregnancy. In Taiwan, amniocentesis is routinely offered for women above 35 however it is also performed upon couple request. In this case, it was performed at 16 weeks on couple request and confirmed that both fetuses were carrying the 46, XX karyotype. A detailed ultrasound at 18 weeks showed neither congenital anomalies nor complications of the pregnancy.

The 2 weekly serial ultrasounds were normal until 27 weeks of gestation; then, 1 of the fetuses was found to have sIUGR (fetal weight below the 3rd percentile and fetal weight discordance of 39%). The sIUGR-twin had an amniotic fluid maximum vertical pocket (MVP) of 4.0 cm and absent end-diastolic velocity (aEDV) of the umbilical artery. However, the mid-cerebral artery peak systolic velocity and ductus venosus flow were normal.

The other fetus was AGA with an amniotic fluid MVP of 7.5 cm and normal umbilical artery flow. However, there was an intra-abdominal cystic mass that measured 1.52 × 1.26 cm. The presence of turbulence Doppler flow suggested a FIUV varix, and fortunately, there was no evidence of thrombosis (Figures 1 and 2).

Repeat ultrasound 2 weeks later, at 29 weeks gestation showed that the FIUV varix remained the same size with no thrombosis; however, the amniotic fluid MVP increased to 12 cm and the sIUGR-twin appeared to be stuck against the uterine wall. A diagnosis of TTTS was then made. Amnioreductions were performed twice, at 29 weeks and 30 weeks of gestation, and betamethasone was administered to promote fetal lung maturity. The fetuses were closely monitored with serial non-stress cardiotocograph tests and Doppler ultrasounds.

At 31 weeks, the FIUV varix in the AGA-twin remained the same. Unfortunately, the twins were delivered with an emergency caesarean section, as there were multiple spontaneous fetal heart decelerations of the sIUGR-twin. The outcomes of the babies are summarised in Table 1.

Discussion

Many reports on FIUV varix have involved singleton pregnancies. Of 91 cases reviewed by Fung et al. (5), 31.9% were detected prenatally by ultrasound of cardiovascular anomalies, hydropic features, and anaemia. In addition, 9.9% exhibited chromosomal anomalies, 13% exhibited perinatal losses, and only 59% had a normal obstetrics outcome. Therefore, those authors recommended detailed sonography, karyotyping,

and intensive surveillance including colour Doppler ultrasound from the moment of diagnosis until delivery, especially in cases that present before 26 weeks (5). This recommendation is supported by Byers et al. (4) who also advocated searching for other anomalies, especially markers of aneuploidy. In isolated FIUV varix, Fung et al. (5) found 8.1% of unexplained intrauterine deaths between 29 and 38 weeks of gestation. There was an increased incidence of intrauterine death,

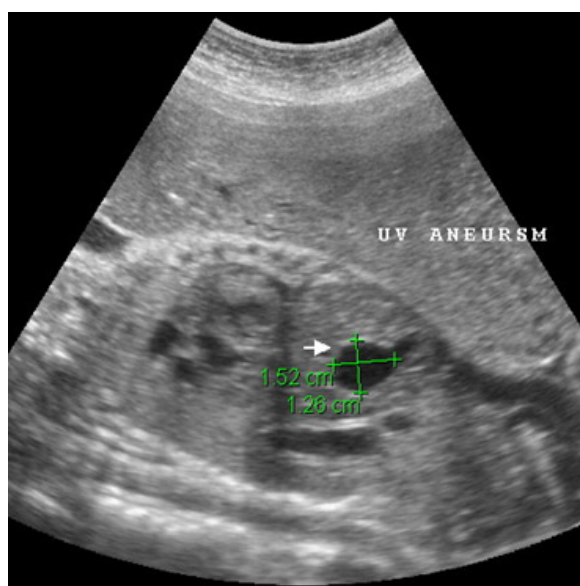


Figure 1: Ultrasound image showing the intra abdominal cystic mass.

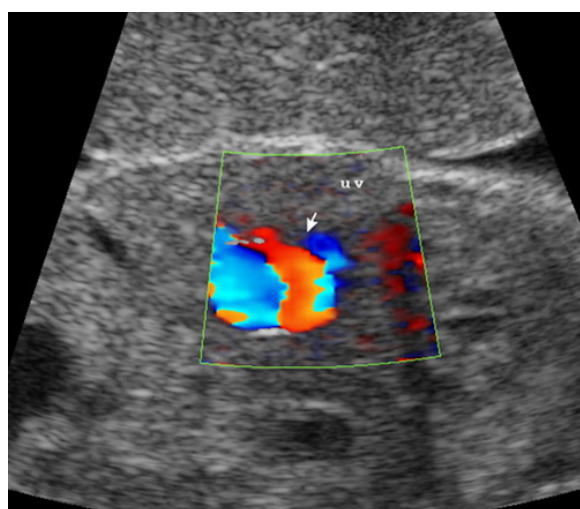


Figure 2: Ultrasound image showing turbulence flow on colour Doppler in the cystic mass.

Table 1: Outcome of the babies during delivery and neonatal period

| Parameters | Twin with varix (AGA / recipient) | Co-twin (sIUGR / donor) |
|---------------------------------------|--|---|
| APGAR score | 7 ^{1 min} 8 ^{5 min} | 8 ^{1 min} 9 ^{5 min} |
| Weight | 1.515 g (25%–50%) | 820 g (< 10%) |
| Birth weight discordant | | 45% |
| Ponderal index | 2.9 (> 90%) | 2.5 (50%–75%) |
| Fetal/placenta ratio | 3.8 | 5.4 |
| Problems at birth until neonatal life | <ul style="list-style-type: none"> • Respiratory distress • Coagulopathy | <ul style="list-style-type: none"> • Respiratory distress • Hypoglycemia • Hypoalbuminemia |
| Repeated ultrasounds of brain | Basically was an extremely premature brain | Basically was an extremely premature brain |
| Ultrasound of abdomen | No umbilical vein varix on 5th day of life | Ultrasound was not performed as it was not necessary |
| Discharge | Day 43 | Still warded for prematurity at day 43 |

Abbreviations: AGA = appropriate gestational age, APGAR = appearance, pulse, grimace, activity, respiratory, sIUGR = selective intrauterine growth restriction.

thrombosis of the umbilical vein, and abnormal antenatal CTG especially when the diagnoses were made before 26 weeks. However, Byers et al. (4) reported a favourable obstetrics outcome in an isolated FIUV varix.

Only 5 reports of FIUV varix series included 1 or 2 cases of FIUV varix in multiple pregnancies, as shown in Table 2. The FIUV varix in monozygotic pregnancies were mainly diagnosed at mid-trimester ranging from 23 weeks to 34 weeks. The majority of them were delivered prematurely probably because of complications of the twin pregnancy itself. In the 3 cases of monozygotic twins complicated by TTTS or sIUGR, the FIUV varix always occurred in the AGA or recipient fetuses. This finding may merely be a coincidence, or it might be the possible result of a direct mechanical response to the increased fetoplacental circulation, which could act as a protective reservoir mechanism because the 3 affected fetuses were born alive. Our case was diagnosed prior to the occurrence of TTTS, and this suggests that the protective mechanism for the fetus occurred earlier than the clinically detected TTTS.

Sepulveda et al. (2) reported 1 case of extensive thrombosis in a fetus with rhesus isoimmunisation following blood transfusion. This case indicates that FIUV varix might aggravate

thrombotic events and extra care is needed for any fetal procedure through the umbilical vein, such as intrauterine blood transfusions.

Whether the occurrence of FIUV varix in twins with high hemodynamic circulation was a coincidence or whether FIUV varix alters the prognosis of the fetuses are questions that require further prospective studies.

In the singleton series, Yagel et al. (6) advocated a close monitoring of FIUV varix fetuses with early delivery at 34 weeks gestation. Delivery after the establishment of fetal pulmonary maturity or labour induction by 40 weeks gestation were also suggested by others (5–7), even in cases involving an isolated FIUV varix.

The complications of umbilical vein varix reported in singleton pregnancies might not be observed with the multiple pregnancies especially in the monozygotic twins. The monozygotic twins generally would have had close fetal surveillance and delivered at an earlier gestational age before any adverse effect of FIUV varix could be seen.

In monozygotic twin pregnancies, FIUV varix is significant and could be a good predictive factor for fetal survival, but this requires further prospective studies.

Table 2: Literature review of umbilical vein varix in multiple pregnancy

| Study | Chorionicity | Antenatal complication | Gestational age at diagnosis | Size of FIUV varix | Twin with FIUV varix | The co-twin |
|---|---------------|---|------------------------------|--------------------|---|---|
| Estroff and Benacerraf, 1992 (8) 1 of 5 cases | n/a | • None | 29 weeks | 15 mm | • Healthy baby | • Normal |
| Sepulveda et al., 1998 (2) 1 twin of 10 cases | n/a | • Rhesus incompatibility | 30 weeks | 15 mm | • Died shortly after intrauterine blood transfusion at 32 weeks • Post-mortem extensive thrombosis in FIUV varix | • n/a |
| Viora et al., 2004 (9) 1 twin of 12 cases | Monochorionic | • IUGR • Delivered at 35 weeks and 6 days | 28 weeks 3 days | n/a | • AGA • Alive • Female • 1780 g | • IUGR • Alive • Female • 1050 g |
| Fung et al., 2005 (5) 1 twin of 13 cases | Monochorionic | • None delivered at term | 34 weeks | 10 mm | • Alive • Extra-thumb | • Alive |
| Byers et al., 2009 (4, personal communication) 2 twin cases of 52 FIUV varix cases | Monochorionic | • TTTS • Delivered at 33 weeks due to worsening diabetes • Mother had PCOS, diabetes on insulin, and chronic hypertension | 31 weeks 3 days | 12.7 mm | • Recipient alive | • Donor alive |
| | Monochorionic | • TRAP • Delivered at 28 weeks and 5 days due to deterioration of pump twin | 23 weeks 5 days | 12 mm | • Pump twin with single umbilical artery, tricuspid regurgitation, cardiac enlargement, and reversal flow of ductus venosus • APGAR score 7 ^{1 min} 8 ^{5 min} | • Acardia |

| Study | Chorionicity | Antenatal complication | Gestational age at diagnosis | Size of FIUV varix | Twin with FIUV varix | The co-twin |
|-------------------------------------|---------------|---|------------------------------|--------------------|---|---|
| Ismail et al., 2012 (current study) | Monochorionic | <ul style="list-style-type: none"> • sIUGR→TTTS • Repeated amnio reductions • Delivered at 31 weeks 4 days due to fetal distress of sIUGR-twin | 27 weeks | 15 mm | <ul style="list-style-type: none"> • AGA • Recipient twin • Female | <ul style="list-style-type: none"> • sIUGR • aEDV/fetal distress • Female • Alive |

Abbreviations: aEDV = absent of end diastolic velocity, AGA = appropriate gestational age, APGAR = appearance, pulse, grimace, activity, respiration, FIUV = fetal intra-abdominal umbilical vein, n/a = not available, PCOS = polycystic ovarian syndrome, sIUGR = selective intra-uterine growth restriction, TRAP = twin reversed arterial perfusion, TTTS = twin-twin transfusion syndrome.

Authors' Contributions

Conception and design: ZN

Provision of patients: YLC, SDC

Analysis and interpretation of the data: HI, YLC, SDC

Drafting of the article: HI

Critical revision of the article: HI, ZN

Correspondence

Dr Yao-Lung Chang

MB (CGMC Taiwan), Fellow in Perinatal Medicine (CGMH, Linkou, Taiwan), Fellow in Fetal Diagnosis and Therapy (Florida Institute, Florida, USA)

Department of Obstetrics and Gynecology

Chang Gung Memorial Hospital

5, Fu-Shin Street, Kwei-Shan

Tao-Yuan, 333, Taiwan

Tel: +886-3328 1200 8251

Fax: +886-3328 8252

Email: j12054@cgmh.org.tw

References

1. Sciaky-Tamir Y, Cohen SM, Hochner-Celnikier D, Valsky DV, Messing B, Yagel S. Three-Dimensional Power Doppler (3DPD) ultrasound in the diagnosis and follow-up of fetal vascular anomalies. *Am J Obstet Gynecol.* 2006;**194**(1):274–281.
2. Sepulveda W, Mackenna A, Sanchez J, Corral E, Carstens E. Fetal prognosis in varix of the intrafetal umbilical vein. *J Ultrasound Med.* 1998;**17**(3):171–175.
3. Mahony BS, Megahan JP, Nyberg DA, Reisner DP. Varix of the fetal intra-abdominal umbilical vein: Comparison with normal. *J Ultrasound Med.* 1992;**11**(2):73–76.
4. Byers BD, Goharkhay N, Mateus J, Ward KK, Munn MB, Wen TS. Pregnancy outcome after ultrasound diagnosis of fetal intra-abdominal umbilical vein varix. *Ultrasound Obstet Gynecol.* 2009;**33**(3):282–286.
5. Fung TY, Leung TN, Leung TY, Lau TK. Fetal intra-abdominal umbilical vein varix: What is the clinical significance? *Ultrasound Obstet Gynecol.* 2005;**25**(2):149–154.
6. Yagel S, Valsky DV, Rosenak D, Porat S, Hochner-Celnikier D. Adverse outcome of isolated fetal intraabdominal umbilical vein varix despite close monitoring. *Ultrasound Obstet Gynecol.* 2004;**24**(6):359.
7. Weissmenn-Brenner A, Simchen MJ, Moran O, Kassif E, Achiron R, Zalel Y. Isolated fetal umbilical vein varix—prenatal sonographic diagnosis and suggested management. *Prenat Diagn.* 2009;**29**(3):229–233.
8. Estroff JA, Benacerraf BR. Fetal umbilical vein varix: Aonographic appearance and postnatal outcome. *J Ultrasound Med.* 1992;**11**(3):69–73.
9. Viora E, Sciarrone A, Bastonero s, Errantea G, Mortaraa G, Chiappa E, et al. Anomalies of the fetal venous system: A report of 26 cases and review of the literature. *Fetal Diagn Ther.* 2004;**19**(5):440–447. doi: 10.1159/000078997.