



Delay in diagnosis of blunt abdominal injuries in children & adolescents: A pictorial review of CT abdomen in HTAA*



Radhiana H¹, Azian AA¹, Mubarak MY², Siti Kamariah CH¹, Azlin S¹, Amran AR¹

¹Department of Radiology, International Islamic University Malaysia (IIUM), Kuantan, Pahang, Malaysia
²Department of Diagnostic Imaging, Hospital Tengku Ampuan Afzan (HTAA)*, Kuantan, Pahang, Malaysia

Introduction

Blunt abdominal injuries are often difficult to be accurately assessed clinically especially with concomitant external injury, in patients with head injury and in paediatric patients¹.

CT scan is the modality of choice for the evaluation of abdominal injury due to blunt trauma in hemodynamically stable children as it is widely available, rapidly performed with accurate depiction of various solid and hollow viscus injuries and associated retroperitoneal or pancreatic injuries².

Delay in diagnosis may not alter the mortality or choice of management but could significantly increase the rate of complications and prolong the length of hospital stay, hence timely and accurate diagnosis of intra abdominal injury is of utmost importance³.

Aim

To review & to find out the possible causes of delay in the diagnosis of blunt abdominal injuries in children & adolescents and its impact on the management and subsequent outcome.

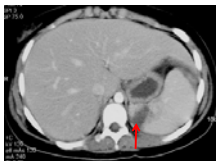Method

- We reviewed all CT scan of the abdomen performed for the evaluation of traumatic intra abdominal injuries from January 2008 to June 2009.
- There were 37 cases done of patients aged 18 years and below.
- In six patients, the examination was delayed i.e. performed more than 24 hours after the initial incident.
- These cases were illustrated as below.

Case 1

A 13-year old girl, who was involved in a road traffic accident and sustained distal end fracture of right fibula. POP was applied and she was discharged home.

Two days later she presented again with abdominal pain, diarrhoea and vomiting. She was admitted with clinical impression of dehydration secondary to acute gastroenteritis. However, blood investigation showed a drop in haemoglobin level that raised the suspicion of intra abdominal injury.



CT scan showed haematoma in the spleen parenchyma (arrow) with no disruption of its outline. No perisplenic blood collection. At lower scan (images not shown) there was minimal blood collection in the pelvis.

Operation done one day after the CT scan due to continuous drop in hemoglobin level showed active bleeding from a branch of left ovarian artery and laceration of left broad ligament, lower abdominal wall contusion and minimal pool of blood in the pelvis. Other organs were normal.

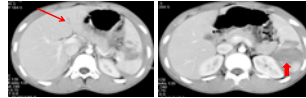
She recovered fully and was discharged from the hospital 19 days after the operation.

Acknowledgements:

- Director General of Health, MOH Malaysia
- Hospital Director, HTAA
- Head of Department, Dept of Diagnostic Imaging, HTAA
- MRTs Dept of Radiology IIUM & Radiographers Dept of Diagnostic Imaging HTAA

Case 2

A 15-year old boy who was kicked while playing football. He presented 2 weeks after the incident with persistent epigastric pain. Clinically there was abdominal tenderness and blood investigation showed haemoglobin level of 8 gm/dL.

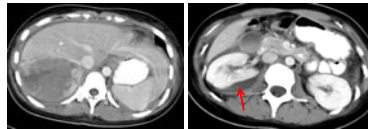


CT scan showed a small laceration in the liver (long arrow) and more severe splenic injury with multiple intraparenchymal hematomas (block arrow).

He was managed conservatively with uneventful recovery.

Case 3

A 17-year old girl, MVA with ribs fracture and pneumohaemothorax. She was noted to have abdominal distension with low haemoglobin level, 3 days after admission.



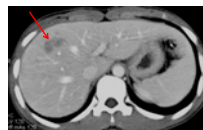CT scan showed large intra parenchymal hematoma in the liver with subcapsular collection in the right kidney (arrow).

She was managed conservatively with uneventful recovery.

Case 4

A 16-year old boy, MVA with fracture distal end right radius, Salter Harris fracture of right ulna and fracture of left radius. He was referred from a district hospital for further management.

In HTAA further examination revealed tenderness at the right hypochondrium. Haemoglobin level was normal.



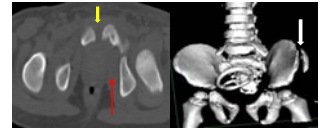CT scan showed haematoma in the liver parenchyma (arrow). Other organs were normal.

He was managed conservatively.

His family had refused open reduction and internal fixation of both upper limbs fracture and opted for traditional treatment.

Case 5

A 2-year old pedestrian, hit and dragged by a lorry. He sustained degloving injury of right thigh which extend to right iliac fossa and closed fracture of left iliac crest & left superior pubic ramus. He was unable to pass urine since the accident and suprapubic catheter was inserted. Two days later he had haematuria and CT scan was performed to rule out genitourinary tract injury.

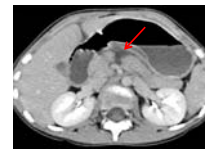

CT scan & 3D reconstruction of the pelvic bone, showed fracture of left pubic bone (white arrow) with diastasis of symphysis pubis (yellow arrow) and swollen left obturator internus muscle (red arrow). No other intra abdominal injuries were detected on CT abdomen.

Ascending urethrogram done after CT scan revealed a urethral injury. Urethroplasty is planned.

Case 6

A 9-year old girl who fell from bicycle. Laceration wound at the forehead was sutured at a district hospital. Mother noticed a bruise on the abdomen, but she was reassured and patient was discharged home. She presented 2 days later with abdominal pain and persistent vomiting and was referred to our hospital, HTAA for further management.



CT scan showed transection of the body of pancreas (arrow). Other organs were normal.

She was managed conservatively. Her condition was complicated by the development of pancreatic pseudocyst which was drained percutaneously.

She recovered fully after 2 months.

Conclusion

Delay in the diagnosis of blunt abdominal injuries in trauma are multifactorial.

Diagnostic delay in these cases can be avoided with careful repeated clinical assessment and proper evaluation using appropriate diagnostic tools.

Summary of Cases

Case	Age (Yr)	Sex	Duration of CT scan from initial trauma (Days)	Reason for delay in diagnosis & Other injuries (if any)	CT scan findings	Management & Outcome
CASE 1	14	F	2	Missed on initial review. Fracture of right fibula.	Grade II spleen injury	Operated
CASE 2	15	M	14	Delay in presentation	Grade I liver injury and Grade III spleen injury	Conservative management
CASE 3	17	F	3	Missed on initial review. Severe thoracic injury	Grade IV liver injury and Grade I right kidney injury	Conservative management
CASE 4	16	M	1+	Missed on initial review. Fracture of right radius and ulna, left radius	Grade I liver injury	Conservative management
CASE 5	2	M	5	More remarkable external injury. Degloving injury of right thigh	No solid organ injury. Pelvic fracture	Conservative management. Planned for urethroplasty
CASE 6	9	F	2	Missed on initial review. Laceration wound at forehead	Transected pancreas	Percutaneous drainage of pancreatic pseudocyst

References

- Federle MP, Goldberg HI, Kaiser JA, Moss AA, et al. Evaluation of abdominal trauma by computed tomography. Radiology 1981; 138:637-644.
- Ruess L, Sivit CJ, Eichelberger MR, Gotschall CS et al. Blunt abdominal trauma in children: Impact of CT on operative and nonoperative management. AJR 1997; 169:1011-1014.
- Lynn KN, Werder GM, Callaghan RM, Sullivan AN, et al. Pediatric blunt splenic trauma: a comprehensive review. Pediatr Radiol 2009; 39:904-916.