

CASE REPORT



# Root canal treatment of a maxillary left first molar with 2 palatal canals - a case report

Hema Devi Sivan<sup>1\*</sup>, Nurul Farah Azih<sup>1</sup>, Musliana Mustaffa<sup>2</sup>

<sup>1</sup> Unit Pakar Pergigian Restoratif, Klinik Pakar Pergigian Jalan Gambut, 25200 Kuantan, Pahang, Malaysia.

<sup>2</sup> Department of Restorative Dentistry, Kulliyah of Dentistry, International Islamic University Malaysia, 25200 Kuantan, Pahang, Malaysia.

## Abstract

Comprehensive knowledge of normal dental anatomy and awareness of potential anatomical variations are crucial to successful endodontic treatment. Anatomical variations such as additional canals in the palatal root of the maxillary molar are poorly reported, attributed to their low prevalence in general populations. This case report highlights the utilization of cone beam computed tomography (CBCT) as a diagnostic tool for locating additional canal in the palatal root of maxillary left first molar. The application of CBCT imaging technology in endodontics enables precise diagnosis through enhanced visualization of anatomical variations, thereby enhancing treatment planning and management of cases presenting with complex canal morphology. The present case documents the successful management of a maxillary left first molar exhibiting abnormal morphology of four canals: two located in the palatal root, one in the mesiobuccal root, and one in the distobuccal root. The canals were biomechanically prepared with crown-down technique and obturated using cold lateral compaction technique with gutta-percha points and AH-Plus root canal sealer. Post-treatment evaluation at six months demonstrated clinical success, with the tooth remaining asymptomatic and maintaining its normal function.

**Keywords:** aberrant root canal, CBCT aided, endodontic management, maxillary molar

**Received:**

13 March 2025

**Revised:**

6 July 2025

**Accepted:**

6 July 2025

**Published Online:**

31 July 2025

**How to cite this article:**

Sivan, H. D., Azih, N. F., & Mustaffa, M. (2025). Root canal treatment of a maxillary left first molar with 2 palatal canals - a case report. *IIUM Journal of Orofacial and Health Sciences*, 6(2), 262-267. <https://doi.org/10.31436/ijohs.v6i2.312>

**Article DOI:**

<https://doi.org/10.31436/ijohs.v6i2.312>

**\*Corresponding author**

**Address:**

Unit Pakar Pergigian Restoratif, Klinik Pakar Pergigian Jalan Gambut, 25200 Kuantan, Pahang, Malaysia.

**Telephone:** +601156888050

**Email address:**

[hemadevisivan@gmail.com](mailto:hemadevisivan@gmail.com)

## Introduction

The success of root canal treatment heavily relies on knowledge of the anatomy of the roots and canals of the tooth in question (Cleghorn *et al.*, 2006). However, anatomical variations can occur, resulting in complicated root canal treatment. Incomplete endodontic treatment is more likely to occur in teeth with such anatomical complexities, resulting in endodontic failure (Song *et al.*, 2011). Literature indicates a generally low reported prevalence (<2%) of anatomical variations in the palatal root canal of maxillary molars (Wasti *et al.*, 2001; Neelakantan *et al.*, 2010). However, specific populations reveal higher frequencies of additional palatal root canals. Prevalence

rates include 33.3% in maxillary first molars among Pakistani subjects (Wasti *et al.*, 2001), 9.7% in maxillary first molars in an Indian population (Neelakantan *et al.*, 2010), 6% in maxillary second molars in a Chinese population (Weng *et al.*, 2009), and 14% in maxillary second molars of an Indian population (Singh & Pawar, 2015). These higher prevalence rates in certain ethnic populations suggest an increased risk of missed root canals identification during root canal treatment, particularly in dental practitioners possessing limited knowledge of these anatomical variations in these ethnic groups.

Accurate root canal morphology identification and characterization prior to

initiating root canal treatment is of utmost importance as inability to detect these anatomical complexities or variations can result in incomplete chemomechanical debridement, microbial colonization, and subsequent treatment failure. The interpretation of these morphological variations through preoperative radiographic images remains challenging. This highlights the importance of the usage of more advanced imaging (Holderrieth & Gernhardt, 2009).

Treatment outcomes can be significantly improved through the integration of cone beam computed tomography (CBCT) coupled with treatment under magnification, as well as advanced clinical skills and experience of the dental practitioner. The application of CBCT in assessment of anatomical variations in the palatal root has been reported in previous case reports with favorable treatment outcomes (Asghari *et al.*, 2015; Sung *et al.*, 2021; Al-Qudah *et al.*, 2023).

This case report presents the clinical application of CBCT as a useful imaging technique for the management of a maxillary left first molar presenting with abnormal canal configuration of two canals in the palatal root.

## Case report

A 63-year-old Indian man was referred to the Restorative Unit of Klinik Pergigian Pakar Jaian Gambut, Kuantan, Pahang for the management of a maxillary left first molar with necrotic pulp, symptomatic apical periodontitis and calcified mesiobuccal canals. The patient reported intermittent throbbing pain for the past five years, occasionally affecting sleep and meals. Pulp extirpation of tooth 26 was carried out by the primary care unit for pain management and MB root canals could not be localized. Patient had no known medical illness. Extra oral examination revealed no significant findings. Intra oral examination revealed a supragingival intact Class II composite restoration, no soft tissue swelling or sinus

tract, no tooth mobility, probing depth within normal limits, and tenderness to palpation and percussion. Periapical radiograph of tooth 26 revealed an ill-defined periapical lesion measuring approximately 4 mm in diameter in relation to the palatal root. A limited field-of-view CBCT was taken as an additional diagnostic aid to establish the diagnosis as well as identification and localization of calcified MB root canals. The scanning parameters were 90 kV, 5 mA, with a spatial resolution of 80 microns (Castellini X Radius Trio Plus, Cefla, Italy). Comprehensive observation of the root anatomy, the dimensions of the periapical lesions, and their relations with surrounding tissue was performed across all planes. An ill-defined radiolucent lesion was noted in the periapical region of the palatal root measuring approximately 5 mm in diameter in the coronal plane, but the number of canals could not be determined (Figure 1). However, the axial plane confirmed the presence of three root canals: two palatal root canals, and one DB root canal. The MB root appeared oval shaped with narrowing in the mid region indicative of 2 root canals. Both canals appeared completely calcified with no periapical radiolucency (Figure 2).

Based on the findings, the diagnosis was established as previously initiated RCT of tooth 26 with necrotic pulp and symptomatic periapical periodontitis.

The diagnostic findings were explained to the patient during the initial visit, and root canal treatment was proposed for the management of tooth 26. Patient understood and consented to the procedure. Local anaesthesia (adrenaline 1:100 000 with 2% lidocaine, Septanest Special, Septodont, Paris, France) was administered to the buccal and palatal side of tooth 26. A rubber dam was placed. Procedure was done under 5.0x dental loupes. Examination of the pulp chamber confirmed the presence of two root canal orifices on the palatal aspect after the access cavity was modified from conventional triangular to square shape with endodontic access bur no. A0164 (Dentsply Maillefer, Baillaigues, Switzerland) (Figure 3).

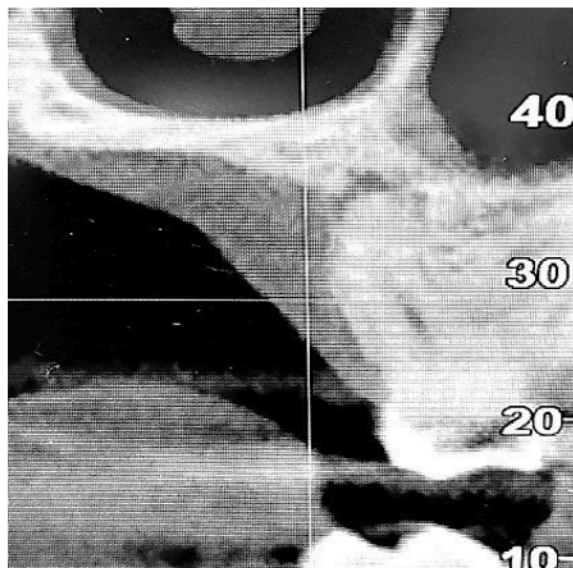


Figure 1. Palatal root with periapical lesion observed in the coronal plane.

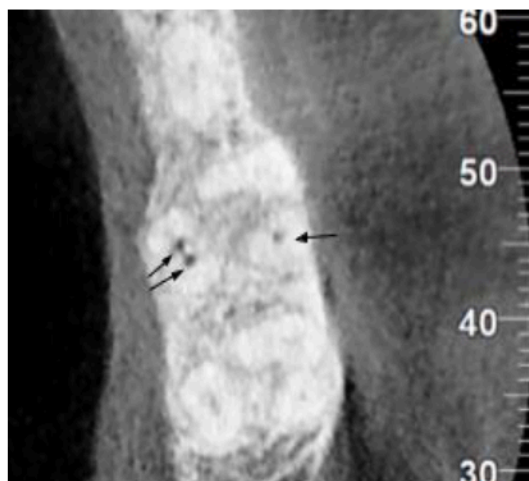


Figure 2. Two palatal root canals, oval shaped MB root with calcified MB2 root canal, and one DB canal were observed.

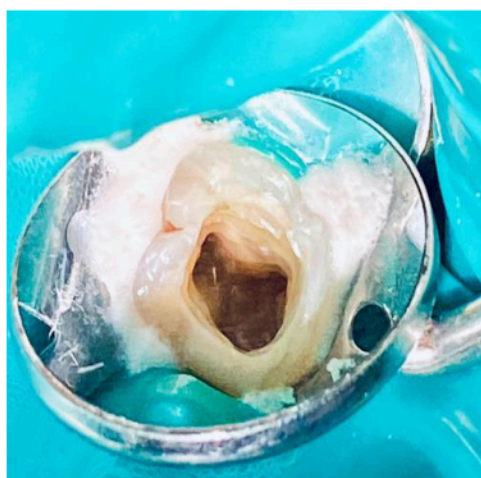


Figure 3. Square shaped access cavity.



Exploration with a DG-16 explorer revealed MB and DB root canals. Troughing of the pulp chamber floor about 2 mm palatal to the MB1 root canal and about 1mm mesial to the line drawn from MB1 to the palatal canal was done. No catch was detected. Ultrasonic tips were used to remove pulp calcifications and troughing was repeated yet no catch was detected. 1% methylene blue, a non-toxic dye was brushed over the chamber floor and then washed with water. No stain indicative of root canal orifice was seen. No further attempts were made to locate the MB2 root canal.

The working length of all the root canals was determined using an electronic apex locator (Dentaport ZX, Morita MFG Corp, Japan) and confirmed with a working length radiograph. The root canals were initially instrumented with an ISO 10 K-file and 15 K-file (Dentsply Maillefer, Switzerland). A glide path was prepared under copious irrigation with 3% sodium hypochlorite (CanalPro, Coltene, USA) (25 mL per canal). The MB1 root canal was instrumented with ProTaper Gold rotary files until F1 (Dentsply Sirona, Switzerland). Meanwhile, the DB and two

root canals in the palatal root were instrumented with ProTaper Gold rotary files until F2 (Dentsply Sirona, Switzerland). All the root canals were copiously irrigated with 3% sodium hypochlorite (CanalPro, Coltene, USA) (25 mL per canal), followed by a final rinse with 17% EDTA (CanalPro, Coltene, USA) for 30s before drying the canals with matched paper points (Dentsply Maillefer, Baillaigues, Switzerland). The root canals were obturated with gutta-percha (Dentsply, Maillefer, Switzerland) using the cold lateral compaction technique and AH Plus root canal sealer (Dentsply, De Trey, Germany). The access cavity was restored with Filtek P60 (3M ESPE, USA) composite resin, and the tooth was scheduled for full coverage ceramic crown restoration treatment. The tooth was reviewed at three months, and six months (Figure 4) following completion of root canal treatment, and was asymptomatic and functional. IOPA of tooth 26 shows a root canal treated tooth with obturated canals of adequate length and density (Farzaneh *et al.*, 2004). No evidence of periapical radiolucency is seen and the lamina dura is intact.

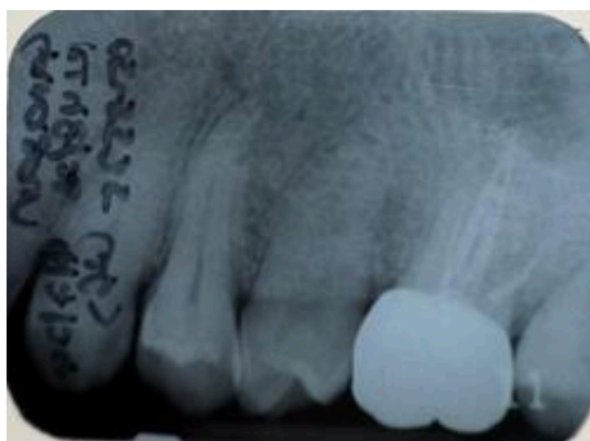

Figure 4. Periapical radiograph at 6-month follow-up.

## Discussion

One of the primary objectives of chemomechanical debridement of the root canal system during root canal treatment is to reduce microorganisms to a subcritical level necessary for periapical healing (Ng *et*

*al.*, 2008; Azim *et al.*, 2016). A thorough understanding of the root canal anatomy is necessary prior to root canal treatment to ensure successful treatment outcomes (Nosrat *et al.*, 2015; Azim *et al.*, 2015), where treatment failures frequently result from the inadequate detection of complex root canal

morphology and unidentified root canal systems (Nair, 2006).

Maxillary molars are commonly associated with carious lesions and represent the second most frequently endodontically treated teeth (Hull *et al.*, 2008; Fransson *et al.*, 2016). The typical morphology of this tooth consists of three roots: one or two root canals in the MB root, one root canal in the DB root, and one root canal in the palatal root (Wilcox *et al.*, 1989; Cleghorn *et al.*, 2006). This current case report portrays the successful non-surgical management of a maxillary left first molar with one MB root canal, one DB and two palatal root canals. The root canals were first visualized using CBCT, and were subsequently verified through visual inspection with the aid of dental loupes.

Management of anatomies such as these can be aided by an analysis of two or more diagnostic periapical radiographs taken at various horizontal angulations or sophisticated diagnostic radiographic techniques like CBCT. Conventional radiographs present inherent limitations at effective assessment of root canal configurations, CBCT serves as an invaluable diagnostic tool for detailed *in vivo* analysis and elucidation of the root canal morphology of maxillary molars (Vizzotto *et al.*, 2013; Nosrat *et al.*, 2015). Current guidelines, specifically the joint position statement by the AAE and AAOMR (2015) recommend a limited field-of-view CBCT imaging modality for cases presenting with the potential for additional root canals or complex root canal morphologies. For this current case, a limited field-of-view CBCT was taken as an additional diagnostic aid to establish the diagnosis as well as identification and localization of calcified MB canals. This CBCT suggested the possibility of the presence of an additional palatal root canal.

When managing cases where it is possible for two palatal root canals to exist, modification of the access cavity is indicated. For this current case, the palatal root canal orifice was not located in the center relative to the tooth shape but mesially. The access cavity was expanded in the distal direction

using an endodontic access bur no. A0164 (Dentsply Maillefer, Baillaigues, Switzerland) resulting in a square shaped access cavity.

In this clinical case, the procedure was done under 5.0x loupes which helped in locating the additional canal. It offered excellent operating field illumination and magnification which allowed the visualization of the pulpal floor as well as the root canal orifice. (Low *et al.*, 2018).

Fins, isthmus areas, and other irregularities may add to the treatment's difficulties (Shalavi *et al.*, 2012). Routine endodontic procedures like irrigation, cleaning, shaping and obturation primarily act on the main root canal, which harbors maximum microorganisms. It has been observed that part of the root canal space often remains untouched during cleaning and shaping, regardless of the technique and instruments employed (Lin *et al.*, 1991). However, one of the aims of obturation is entombment of bacteria within the dentinal tubules and root canal ramifications. So in a well-obtured root canal, these remnant bacteria usually die or are prevented from gaining access to periradicular tissues, thereby preventing reinfection (Siqueira *et al.*, 2001) Thus inability to locate and manage an isthmus rarely causes failure of orthograde endodontic treatment as seen in this case.

Locating the calcified MB2 root canal was a major challenge in this case. Despite the usage of CBCT for exact evaluation, modification of access cavity from triangular to rhomboid shape (Zhouk *et al.*, 2020), applying dental loupes (Camacho-Aparicio L.A *et al.*, 2022) usage of DG 16 explorer and 1% methylene blue as dye, MB2 root canal was not detected. This could be due to the calcific nature of the canal as seen in the CBCT as well as limited experience of the clinician.

## Conclusion

Comprehensive understanding of the normal root canal morphology and its anatomical variations, coupled with

thorough preoperative assessments incorporating CBCT imaging technology enhanced the management of tooth 26 with four root canals, underscoring the significance of advanced diagnostic imaging in identifying and effectively treating anatomical variations for successful endodontic treatment outcomes.

## References

- AAE and AAOMR Joint Position Statement (2015). Use of cone beam computed tomography in endodontics 2015 update. *Journal of Endodontics*, 41,1393-1396.
- Al-Qudah, A., Afaneh, A., Hassounah, L. (2023). A case report of a maxillary second molar with two distinct palatal canals, confirmed by CBCT. *Clinical Cosmetic and Investigational Dentistry*, 15,199-203
- Asghari, V., Rahimi, S., Ghasemi, N., Talebzadeh, B., Norlouoni, A. (2015). Treatment of a maxillary first molar with two palatal roots. *Iran Endodontic Journal*, 10(4), 287-289.
- Azim, A.A., Griggs, J.A., Huang, G.T. (2016). The Tennessee study: factors affecting treatment outcome and healing time following nonsurgical root canal treatment. *International Endodontic Journal*, 49, 6-16.
- Azim, A.A., Deutsch, A.S., Solomon, C.S. (2015). Prevalence of middle mesial canals in mandibular molars after guided troughing under high magnification: an in vivo investigation. *Journal of Endodontics*, 41, 164-168.
- Camacho-Aparicio, L.A., Borges-Yáñez, S.A., Estrada, D., Azcárraga, M., Jiménez, R., González-Plata-R, R. (2022). Validity of the dental operating microscope and selective dentin removal with ultrasonic tips for locating the second mesiobuccal canal (MB2) in maxillary first molars: an in vivo study. *Journal of Clinical and Experimental Dentistry*, 14, e471-e478.
- Farzaneh, M., Abitbol, S., Lawrence, H.P., Friedman, S. (2004). Toronto Study. Treatment outcome in endodontics-the Toronto Study. Phase II: initial treatment. *Journal of Endodontics*, 30(5), 302-309.
- Fransson, H., Dawson, V.S., Frisk, F., Bjørndal, L., EndoReCo, Kvist, T. (2016). Survival of root-filled teeth in the Swedish adult population. *Journal of Endodontics*, 42, 216-220.
- Holderrieth, S., Gernhardt, C.R. (2009). Maxillary molars with morphologic variations of the palatal root canals: a report of four cases. *Journal of Endodontics*, 35 (7), 1060-1065.
- Hull, T.E., Robertson, P.B., Steiner, J.C., del Aguila, M.A. (2003). Patterns of endodontic care for a Washington state population. *Journal of Endodontics*, 29, 553-556.
- Nair P.N. (2006). On the causes of persistent apical periodontitis: a review. *International Endodontic Journal*, 2006, 39, 249-281.
- Neelakantan, P., Subbarao, C., Ahuja, R., Subbarao, C.V., Gutmann, J.L. (2010). Cone-beam computed tomography study of root and canal morphology of maxillary first and second molars in an Indian population. *Journal of Endodontics*, 36, 1622-1627.
- Ng, Y.L., Mann, V., Rahbaran, S., Lewsey, J., Gulabivala, K., (2008). Outcome of primary root canal treatment: systematic review of the literature-part 2. Influence of clinical factors. *International Endodontic Journal*, 41, 6-31.
- Nosrat, A., Deschenes, R.J., Tordik, P.A., Hicks, M.L., Fouad, A.F. (2015). Middle mesial canals in mandibular molars: incidence and related factors. *Journal of Endodontics*, 41, 28-32.
- Lin, L.M., Pascon, E.A., Skribner J., Gängler P., Langeland K. (1991) Clinical, radiographic, and histologic study of endodontic treatment failures. *Oral Surgery, Oral Medicine, Oral Pathology*. 71, 603-611.
- Low, J.F., Dom, T.N.M., Baharin, S.A. (2018) Magnification in endodontics: a review of its application and acceptance among dental practitioners. *European Journal of Dentistry*, 12, 610-616.
- Shalavi, S., Mohammadi, Z., Abdolrazzaghi, M. (2012) Root canal treatment of maxillary and mandibular three-rooted premolars: case reports. *Iran Endodontic Journal*, 7, 161-164.
- Singh, S., Pawar, M. (2015). Root canal morphology of South Asian Indian maxillary molar teeth. *European Journal of Dentistry*, 9, 133-144.
- Siqueira, J.F. (2001) Aetiology of root canal treatment failure: why well-treated teeth can fail. *International Endodontic Journal*, 34, 1-10.
- Stone, L.H., Stroner, W.F. (1981). Maxillary molars demonstrating more than one palatal root canal. *Oral Surgery Oral Medicine Oral Pathology*, 51, 649-652.
- Song M., Kim H. C., Lee W., and Kim E. (2011). Analysis of the cause of failure in nonsurgical endodontic treatment by microscopic inspection during endodontic microsurgery. *Journal of Endodontics*. 37 (11), 1516-1519.
- Sung, K.H., Hwang, H.K., Jo, H.H. (2021). Maxillary First Molars with Two Palatal Root Canals. *Case Reports in Dentistry*, 2021(1), 8885923.
- Vizzotto, M.B., Silveira, P.F., Arus, N.A., Montagner, F., Gomes, B.P., da Silveira, H.E. (2013). CBCT for the assessment of second mesiobuccal (MB2) canals in maxillary molar teeth: effect of voxel size and presence of root filling. *International Endodontic Journal*, 46, 870-876.
- Wasti, F., Shearer, A.C., Wilson, N.H. (2001). Root canal systems of the mandibular and maxillary first permanent molar teeth of south Asian Pakistanis. *International Endodontic Journal*, 34, 263-266.
- Weng, X.L., Yu, S.B., Zhao, S.L., Wang, H.G., Mu, T., Tang, R.Y., et al. (2009). Root canal morphology of permanent maxillary teeth in the Han nationality in the Chinese Guanzhong area: a new modified root canal staining technique. *Journal of Endodontics*, 35, 651-656.
- Wilcox, L.R., Walton, R.E., Case, W.B. (1989). Molar access: shape and outline according to orifice locations. *Journal of Endodontics*, 15, 315-318.
- Zhuk, R., Taylor, S., Johnson, J.D., Paranjpe A. (2020). Locating the MB2 canal in relation to MB1 in maxillary first molars using CBCT imaging. *Australian Endodontic Journal*. 46, 184-190.