

Paws, probes, and PCR: Unraveling the clinical jigsaw puzzle of *Bartonella henselae* infection

P4070

Ummu Afeera Zainulabid^{1,6}, Siti Roszilawati Ramli², Rohaizam Jaafar³, Nurul Akmal Kamarudin⁴, Ong May Ling⁵, Saw Yen Tsen⁶, Yeow Yong Yaw⁶, Sheena Kristil Ravintharan⁶, Khairil Erwan Khalid⁶, Leong Chee Loon⁶

¹ Department of Internal Medicine, Kulliyah of Medicine, International Islamic University Malaysia - Kuantan (Malaysia)

² Bacteriology Unit, Infectious Disease Research Centre (IDRC), Institute for Medical Research (IMR), National Institutes of Health (NIH) - Kuala Lumpur (Malaysia)

³ Otorhinolaryngology Unit, Hospital Kuala Lumpur - (Malaysia)

⁴ Histopathology Unit, Hospital Kuala Lumpur - (Malaysia)

⁵ Radiology Unit, Hospital Kuala Lumpur - Malaysia,

⁶ Infectious Disease Unit, Hospital Kuala Lumpur - (Malaysia)



BACKGROUND



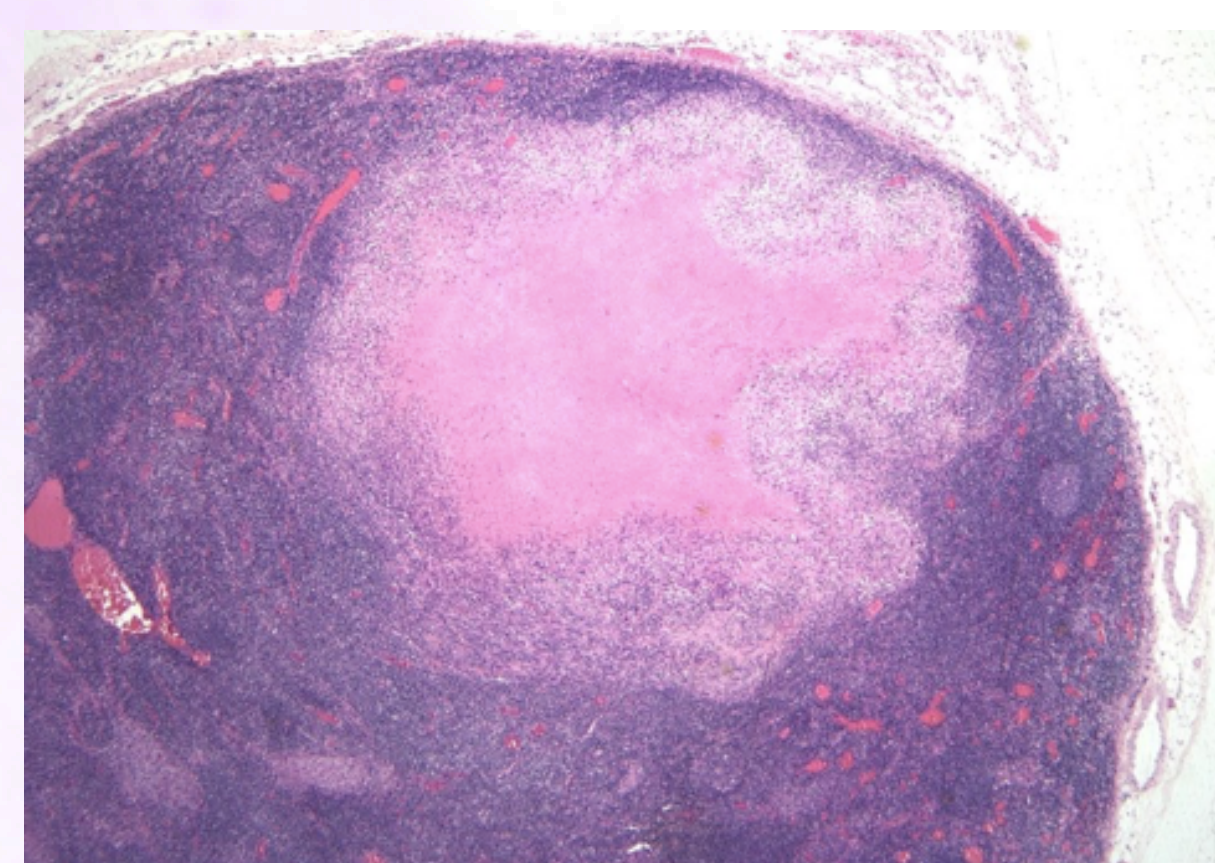
In immunocompromised individuals presenting with pyrexia of unknown origin, *Bartonella spp.* infection warrants specific diagnostic consideration. Our case underscores the significance of probing into a patient's history, particularly past exposures to cats, as a crucial step in unraveling complex clinical scenarios. Notably, despite negative serological findings, a definitive diagnosis in our case was achieved through molecular techniques, highlighting the indispensable role of PCR. This instance emphasizes the critical importance of molecular tools, specifically PCR, in navigating intricate and uncommon presentations of *Bartonella spp.* infection.

CASE DESCRIPTION

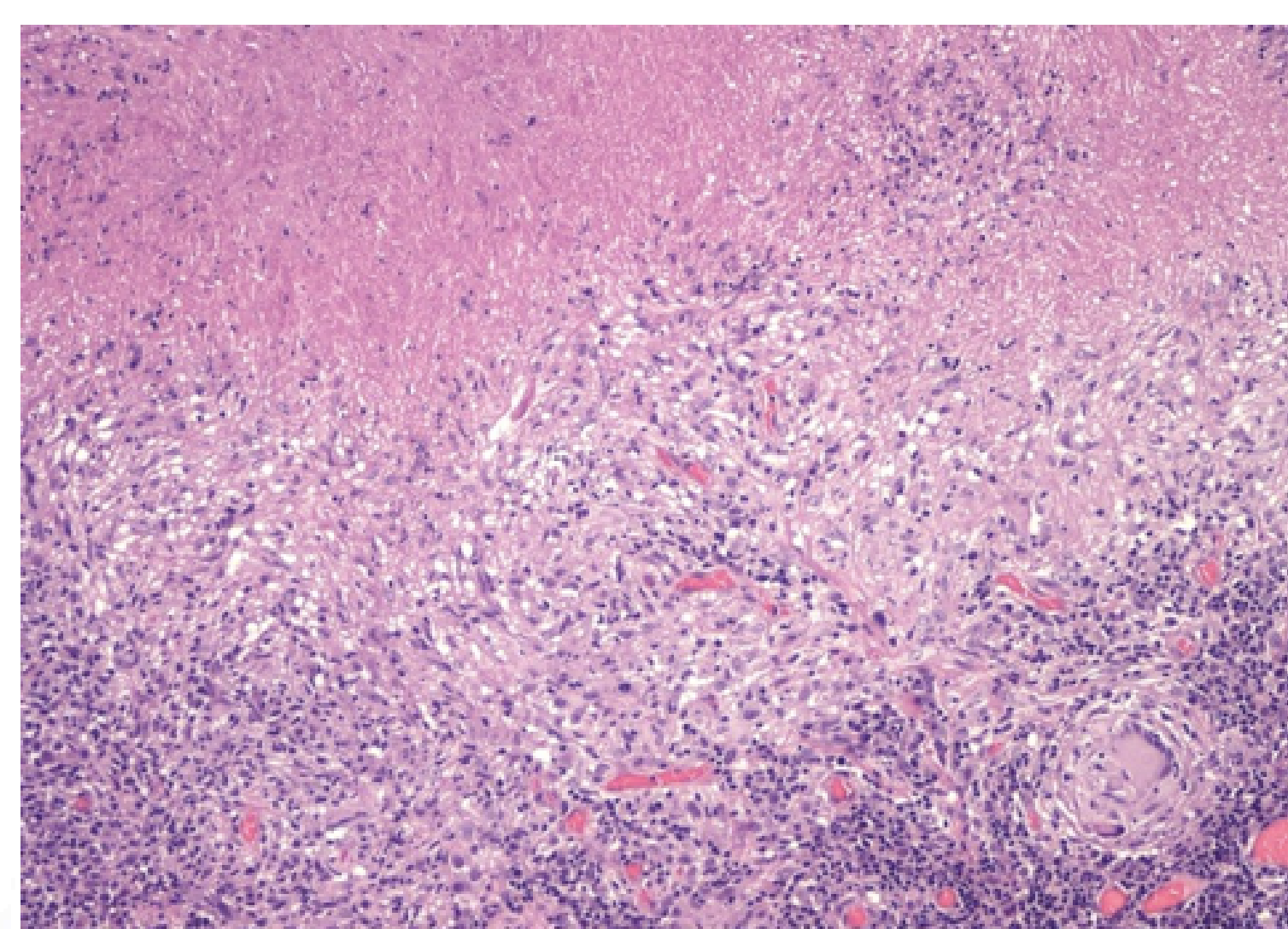


A 38-year-old male, diagnosed with retroviral disease in June 2021 and exhibiting an undetected viral load since November 2021, initially presented with rashes on both shins and calves. Subsequently, he developed blurred vision in the left eye, diagnosed as retinitis, with an MRI revealing a left orbital pseudotumor. Prednisolone brought symptomatic relief, yet a follow-up MRI disclosed a residual lesion. Over the ensuing months, the patient experienced persistent fever, arthralgia, and myalgia. Considering his history of hiking and jungle exposure, tick-borne diseases were contemplated, leading to the initiation of Doxycycline. The patient notably showed a positive response to the Doxycycline treatment. A CT scan highlighted ipsilateral right lymphadenopathy in the supraclavicular, right retropectoral, right axillary, and paraaortic regions. Lymph node biopsy elucidated necrotizing granuloma. This biopsy crucially prompted a reassessment of the patient's history, shedding new light on the significance of past cat exposure and scratches. Intriguingly, while traditional serological testing for *Bartonella* yielded negative results, the detection of *Bartonella henselae* DNA by PCR from the lymph node provided a pivotal diagnostic clue in this case.

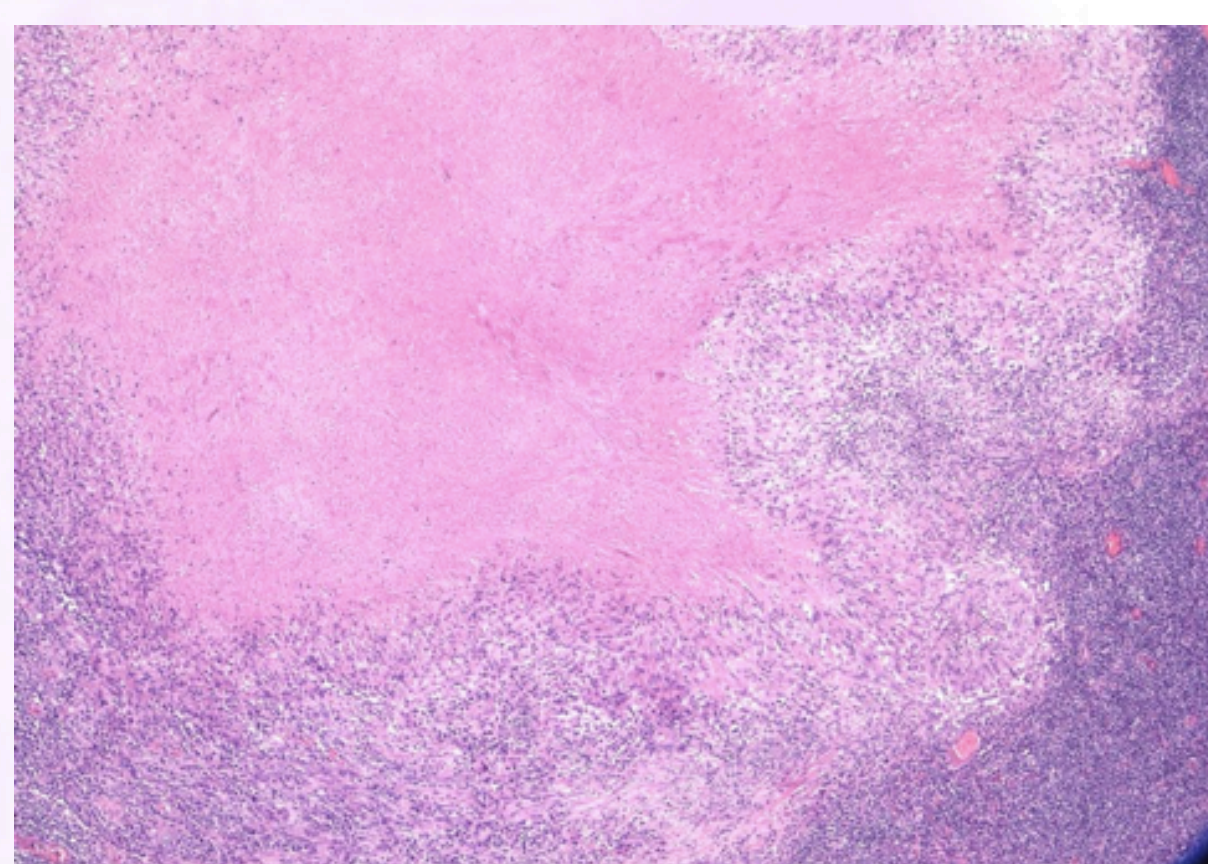Figure 1: Histopathological examination of right supraclavicular lymph node biopsy.



a) Section shows lymph node with granulomatous inflammation. (HPE 2x)



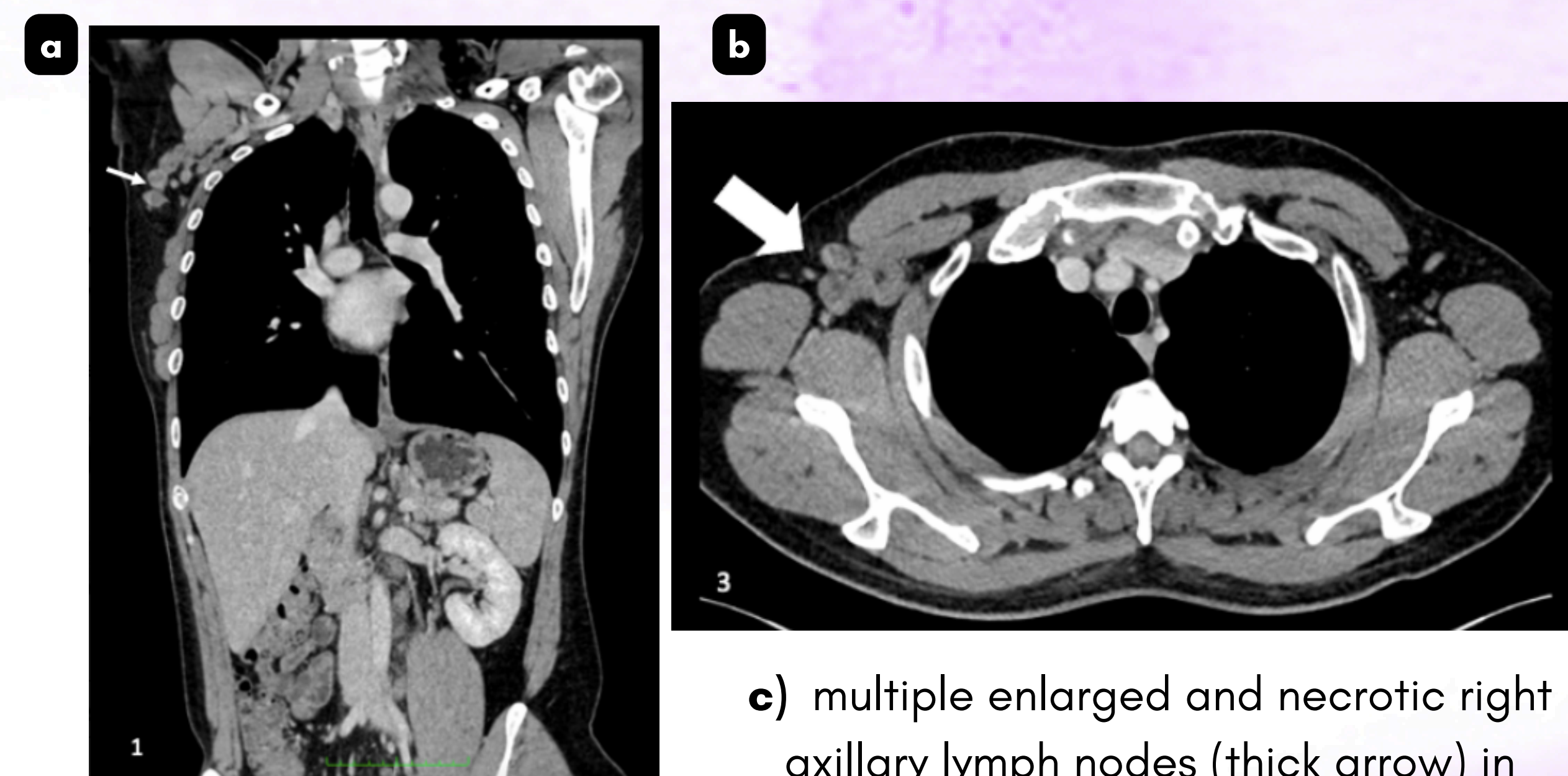
c) The granuloma shows large central necrotic core, which are rimmed by aggregates of epithelioid histiocytes admixed with several multinucleated giant cells. (HPE 10x)



b) The granuloma shows large central necrotic core, which are rimmed by aggregates of epithelioid histiocytes admixed with several multinucleated giant cells. (HPE 4x)

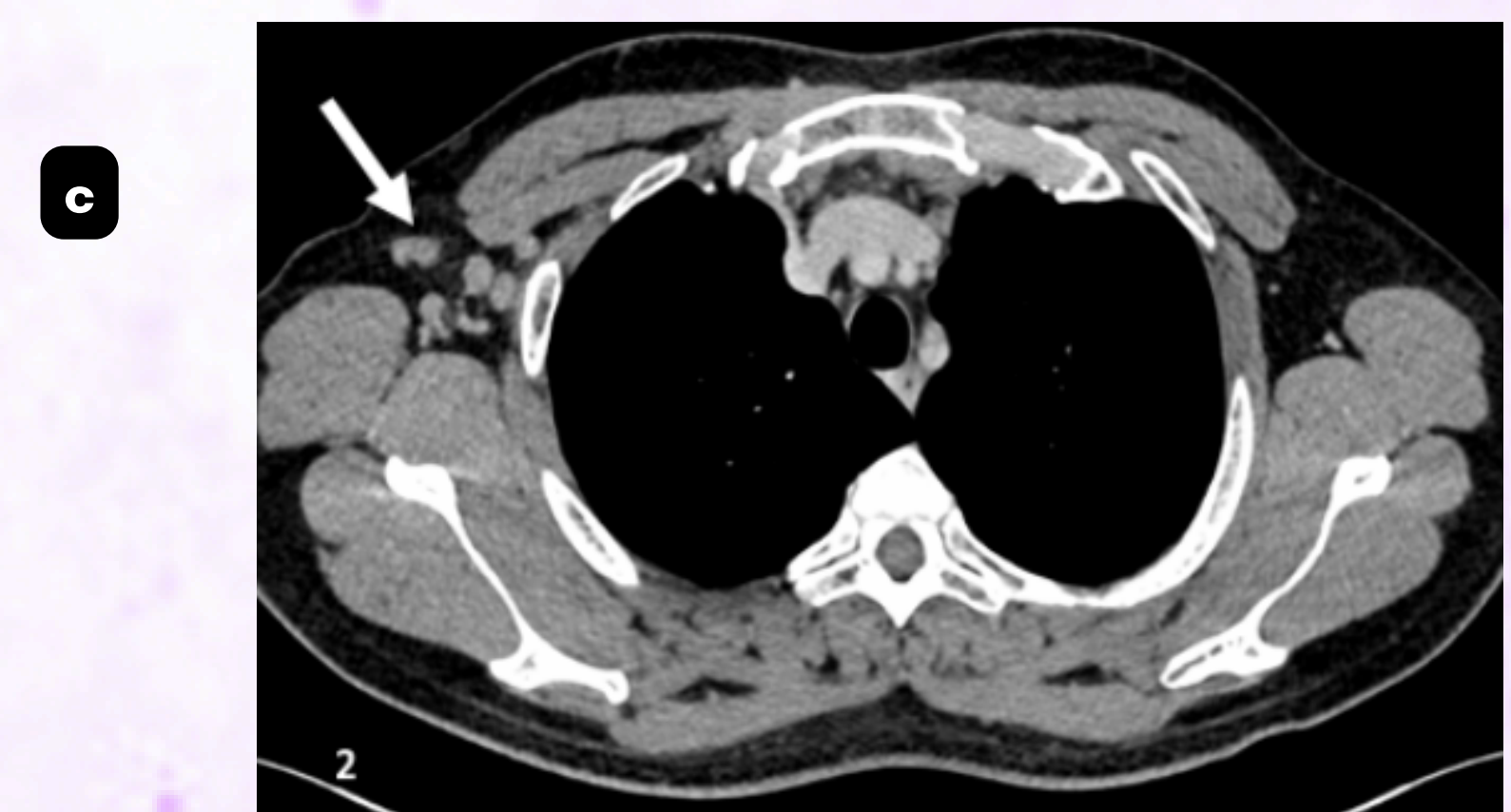
- Special stains, including PAS and GMS, reveal no evidence of fungal elements. Ziehl-Neelsen staining yields negative results for acid-fast bacilli, and the Warthin-Starry stain shows no bacterial colonies.

Figure 2: Radiological examination



a) multiple enlarged and necrotic right axillary lymph nodes (thin arrow) in coronal view

c) multiple enlarged and necrotic right axillary lymph nodes (thick arrow) in axial view



b) multiple enlarged right axillary lymph nodes (thin arrow) in axial view.

DISCUSSION



In this distinctive case, the alignment of clinical symptoms, imaging findings, and a lymph node biopsy prompted a profound reevaluation of the patient's history, emphasizing the pivotal role of cat exposure in *Bartonella spp.* infection. This case underscores the importance of molecular techniques, specifically PCR, in enhancing diagnostic precision for elusive infections. It reinforces the significance of thorough investigations in nuanced clinical scenarios, particularly among individuals with retroviral disease.