



## CASE REPORT

# Orbital cellulitis complicated with subperiosteal abscess following post-nasopharyngeal swab for COVID-19: A case report

Mohd-Asyraf Abdul-Kadir<sup>1,2</sup>  | Abdul-Hadi Rosli<sup>2</sup> 

<sup>1</sup>Department of Ophthalmology,  
Universiti Malaysia Sarawak, Sarawak,  
Malaysia

<sup>2</sup>Department of Ophthalmology,  
Kulliyah of Medicine, International  
Islamic University Malaysia, Pahang,  
Malaysia

**Correspondence**

Mohd-Asyraf Abdul-Kadir,  
Department of Ophthalmology,  
Kulliyah of Medicine, International  
Islamic University Malaysia, Pahang,  
Malaysia.  
Email: [akmasyraf@unimas.my](mailto:akmasyraf@unimas.my)

**Key Clinical Message**

The nasopharyngeal swab for COVID-19 is associated with low risks of severe complications, but it is important to consider the patient's medical history and anatomy of the nasal cavity to ensure safety and accuracy of the test. Orbital complications can occur up to 85% secondary to acute sinusitis, and prompt treatments are crucial, particularly in the pediatric group. A conservative approach is effective for subperiosteal abscess if certain criteria are met, and it is not an absolute indication for immediate surgical intervention. However, timely management of orbital cellulitis is essential for better outcomes.

**Abstract**

Pre-septal and orbital cellulitis are more commonly seen in children than in adults. The incidence of pediatric orbital cellulitis is 1.6 in 100,000. The impact of COVID-19 has led to the increasing practice of nasopharyngeal swab surveillance. We presented a case of rare pediatric orbital cellulitis complicated with subperiosteal abscess secondary to severe acute sinusitis following a nasopharyngeal swab. A 4-year-old boy was brought in by his mother with increasing painful left eye swelling and redness. Three days prior, the patient developed a fever and mild rhinitis with loss of appetite which raised concerns about COVID-19. He had a nasopharyngeal swab on that same day and tested negative. Clinically, there was marked erythematous and tender peri-orbital and facial oedema involving the left nasal bridge, maxilla extended to the left upper lip with a deviation of the left nasal tip contralaterally. Computed tomography confirmed left orbital cellulitis with left eye proptosis, fullness of left maxillary and ethmoidal sinuses and left subperiosteal abscess. The patient received empirical antibiotics and surgical intervention promptly and recovered well with improvements in ocular symptoms. The nasal swabbing techniques may vary among practitioners, and it is associated with extremely low risks of severe complications from 0.001% to 0.16%. Whether the swab had aggravated the underlying rhinitis or traumatized the turbinates leading to sinus drainage obstruction; a nasal swab may impose the risk of severe orbital infection in a susceptible pediatric patient. Any health practitioner conducting the nasal swab should be vigilant about this potential complication.

This is an open access article under the terms of the [Creative Commons Attribution-NonCommercial-NoDerivs](https://creativecommons.org/licenses/by-nc-nd/4.0/) License, which permits use and distribution in any medium, provided the original work is properly cited, the use is non-commercial and no modifications or adaptations are made.

© 2023 The Authors. *Clinical Case Reports* published by John Wiley & Sons Ltd.

## KEYWORDS

COVID-19, nasopharyngeal swab, orbital cellulitis, SARS-CoV-2

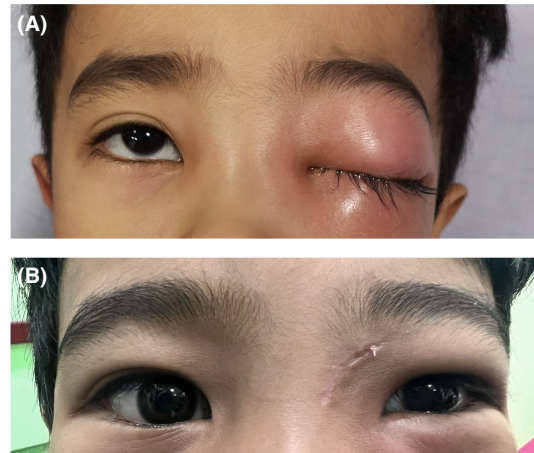
## 1 | INTRODUCTION

Pre-septal and orbital cellulitis are more commonly seen in children than in adults. As both entities affect different anatomical sites, pre-septal cellulitis is almost three times more frequent than orbital cellulitis.<sup>1</sup> The incidence of pediatric orbital cellulitis is 1.6 in 100,000, and early recognition and prompt treatment of orbital cellulitis have improved its mortality and morbidity.<sup>2,3</sup> Chandler et al described stages of pre-septal to orbital cellulitis according to its extension which may lead to intracranial abscess and cavernous sinus thrombosis.<sup>4</sup> Sinus disease has been identified as a common risk factor for the development of pediatric orbital cellulitis and can be seen up to 91% in radiographic imaging.<sup>5,6</sup>

The impact of the global widespread coronavirus disease 2019 (COVID-19) caused by severe acute respiratory syndrome coronavirus 2 (SARS-CoV-2) has led to the increasing practice of infection surveillance including routine anterior nasal, mid-turbinate, and nasopharyngeal swabs as per recommendation by US Centers for Disease Control and Prevention (CDC).<sup>7</sup> A series of 4876 oropharyngeal and nasopharyngeal swabs had shown the swabs were practically safe to detect SARS-CoV-2, and its complications were associated with nasal anatomical variations, nasal mucosal fragility, and other comorbidities.<sup>8</sup> Therefore, we presented a case report of rare pediatric orbital cellulitis complicated with subperiosteal abscess secondary to severe acute sinusitis following a nasopharyngeal swab.

## 2 | CASE REPORT

A 4-year-old Malay boy was brought in by his mother with increasing painful left eye swelling and redness. Three days before to the presentation, the patient developed a fever and mild nasal congestion with loss of appetite which raised the concern about COVID-19. He had a nasopharyngeal swab on the same day and tested negative. However, on the following day, the patient developed mild left eye redness and a general practitioner commenced him on oral antibiotic and topical chloramphenicol. Yet, the left eyelids began to swell, and the swelling had spread to the cheek region. It became erythematous and more painful, and the patient was unable to open his left eye. The mother denied any previous history of sinusitis, nasal or ocular surgery, facial trauma or insect bite and the developmental and medical histories were unremarkable.



**FIGURE 1** Patient's pre- and post-medical and surgical treatments. (A) Patient presented with left orbital cellulitis with proptosis and mild ophthalmoplegia. (B) Patient's external eye appearance following 3 months post-operative.

The patient was alert, mildly dehydrated, and febrile on arrival. On the limited ocular examination due to lack of cooperation, there was marked periorbital and facial oedema that was tender and warm involving the left nasal bridge, maxilla extended to left upper lip with a deviation of left nasal tip contralaterally. He was unable to open the left eye voluntarily, but it was noted there was mild ophthalmoplegia with proptosis (Figure 1A). There was no evidence of foreign body or insect bites around the eyelids and the rest of the external ocular examination was unremarkable. He was treated empirically with intravenous and topical antibiotics with a provisional diagnosis of orbital cellulitis. Other differential diagnoses were pre-septal cellulitis and orbital rhabdomyosarcoma.

Inflammatory markers were elevated with a C-reactive protein of 17.11 mg/dL and white blood cell counts of  $17.9 \times 10^9/L$  (Neutrophils 78.9%). Computed tomography (CT) head, orbit and sinus showed left eye proptosis, with underlying fullness of left maxillary and ethmoidal sinuses, left subperiosteal abscess, with thickening and enhancement of left extraconal superior, medial, and inferior spaces, extended inferiorly to the periorbital region, left cheek and mandible (Figure 2). The empirical antibiotics were escalated accordingly; however, patient's ocular condition remained unchanged within 48 hours. Our Otorhinolaryngology (ENT) colleagues were consulted, and external decompression and drainage of the abscess were performed. The patient underwent the operation

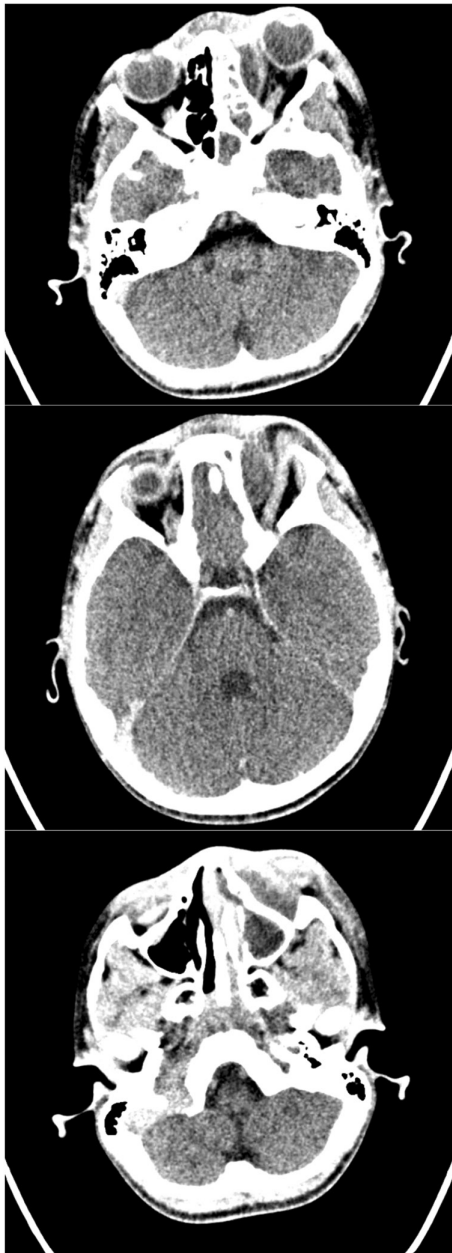

FIGURE 2 Computed tomography (CT) of orbit and sinus.

uneventfully and recovered well with gradual improvements in ocular symptoms. At follow-up 3 months in ophthalmology outpatient, he had symmetrical bilateral external ocular appearance with equivocal ocular functions (Figure 1B).

### 3 | DISCUSSION

The nasopharyngeal swab is widely implemented and mostly validated for the detection of SARS-CoV-2 infection. While the techniques may vary among practitioners and produce unpleasant sensations, it is associated with extremely low risks of severe

complications ranging from 0.001% to 0.16%.<sup>8,9</sup> Most reported complications were epistaxis and impacted broken swabs.<sup>8,9</sup> There was a case of nasal septum abscess in an immunocompromised patient that was incised and drained under local anesthesia successfully.<sup>8</sup> Other occasional reports include iatrogenic cerebrospinal fluid leak, lamina cribrosa fracture, and ethmoidal silent sinus syndrome.<sup>10-12</sup> Therefore, it is important to establish the patient's medical history before nasopharyngeal swab testing including a history of septal deviations, previous sinus or trans-sphenoidal surgery and potential concerns of skull base injuries.<sup>13</sup>

In our case report, whether the nasopharyngeal swab had aggravated potentially underlying rhinitis that the patient might have had earlier on, or the invasive test could have traumatized the turbinates that led to a possible sinus drainage obstruction and severe acute sinusitis; there were all remained as hypotheses. With the correct sampling without force, considering the anatomy of the nasal cavity and its vital adjacent structures like orbit and skull base will ensure the safety and accuracy of the test.<sup>14</sup> Moreover, nasopharyngeal samplings in children can be affected by the child's comprehension and cooperation.<sup>15</sup>

Orbital complications can occur up to 85% secondary to acute sinusitis and if untreated, it can lead to sinister complications like blindness and extension of the infection intracranially.<sup>16</sup> It is crucial not to miss post-septal cellulitis even though marked periorbital oedema can hinder a full ocular examination.<sup>17</sup> Therefore, CT orbit, brain and sinus is warranted if bedside examination cannot rule out orbital cellulitis or there were suspicions of post-septal involvement. Prompt treatments are warranted for these patients particularly, in the pediatric group, yet the consensus between surgical versus medical treatments for each stage of orbital cellulitis and the role of surgery for subperiosteal abscess remain conflicting. A systematic review recommended a conservative approach is effective for subperiosteal abscess if certain criteria are met and it is not an absolute indication for immediate surgical intervention.<sup>18</sup> In our case, given the patient was not responded well to intravenous treatment with the concern of deteriorating visual prognosis, the decision for surgical decompression was pursued. The timely management of orbital cellulitis in our case led to better outcomes for the child (Figure 2).

### 4 | CONCLUSION

Although nasopharyngeal swab testing appears to be a safe method and a gold standard for detecting COVID-19, it can still predispose the risk of severe orbital cellulitis that can cause poor visual prognosis if missed.

## AUTHOR CONTRIBUTIONS

**Mohd-Asyraf Abdul-Kadir:** Conceptualization; methodology; visualization; writing – original draft; writing – review and editing. **Abdul-Hadi Rosli:** Conceptualization; supervision; writing – review and editing.

## ACKNOWLEDGMENTS

We thank our Radiology and ENT departments for their supports in managing this case.

## FUNDING INFORMATION

No financial support was received for the case report.

## CONFLICT OF INTEREST STATEMENT

The authors declare that they have no competing interests.

## DATA AVAILABILITY STATEMENT

All data regarding this study have been reported in the manuscript. Please contact the corresponding author if you are interested in any further information.

## ETHICAL APPROVAL

Written informed consent was obtained from the guardian of the patient. The guardian also consented to participate for investigation and treatment of the patient.

## CONSENT

Written informed consent was obtained from the guardian of the patient for publication of this case report and any accompanying images.

## ORCID

Mohd-Asyraf Abdul-Kadir  <https://orcid.org/0000-0002-2414-8232>

Abdul-Hadi Rosli  <https://orcid.org/0000-0002-4866-9892>

## REFERENCES

- Hauser A, Fogarasi S. Periorbital and orbital cellulitis. *Pediatr Rev.* 2010;31(6):242-249.
- Chaudhry IA, Al-Rashed W, Arat YO. The hot orbit: orbital cellulitis. *Middle East Afr J Ophthalmol.* 2012;19(1):34-42.
- Murphy C, Livingstone I, Foot B, Murgatroyd H, MacEwen CJ. Orbital cellulitis in Scotland: current incidence, aetiology, management and outcomes. *Br J Ophthalmol.* 2014;98(11):1575-1578.
- Chandler JR, Langenbrunner DJ, Stevens ER. The pathogenesis of orbital complications in acute sinusitis. *Laryngoscope.* 1970;80(9):1414-1428.
- Ferguson MP, McNab AA. Current treatment and outcome in orbital cellulitis. *Aust N Z J Ophthalmol.* 1999;27(6):375-379.
- Chaudhry IA, Shamsi FA, Elzaridi E, et al. Outcome of treated orbital cellulitis in a tertiary eye care center in the middle east. *Ophthalmology.* 2007;114(2):345-354.
- Centers for Disease Control and Prevention. Interim guidelines for collecting, handling, and testing clinical specimens for COVID-19. 2021. Accessed 2022 July 15. <https://www.cdc.gov/coronavirus/2019-ncov/lab/guidelines-clinical-specimens.html>
- Fabbris C, Cestaro W, Menegaldo A, et al. Is oro/nasopharyngeal swab for SARS-CoV-2 detection a safe procedure? Complications observed among a case series of 4876 consecutive swabs. *Am J Otolaryngol.* 2021;42(1):102758.
- Koskinen A, Tolvi M, Jauhiainen M, Kekäläinen E, Laulajainen-Hongisto A, Lamminmäki S. Complications of COVID-19 nasopharyngeal swab test. *JAMA Otolaryngol Head Neck Surg.* 2021;147(7):672-674.
- Ribeiro SPP, Loureiro RM, Gil JM, Dutra DL, Gomes RLE, Daniel MM. Ethmoidal silent sinus syndrome after nasal swab test. *Neuroradiology.* 2022;64(1):205-207.
- Sullivan CB, Schwalje AT, Jensen M, et al. Cerebrospinal fluid leak after nasal swab testing for coronavirus disease 2019. *JAMA Otolaryngol Head Neck Surg.* 2020;146(12):1179-1181.
- Knížek Z, Michálek R, Vodicka J, Zdobinská P. Cribriform plate injury after nasal swab testing for COVID-19. *JAMA Otolaryngol Head Neck Surg.* 2021;147(10):915-917.
- Clark JH, Pang S, Naclerio RM, Kashima M. Complications of nasal SARS-CoV-2 testing: a review. *J Invest Med.* 2021;69(8):1399-1403.
- Higgins TS, Wu AW, Ting JY. SARS-CoV-2 nasopharyngeal swab testing-false-negative results from a pervasive anatomical misconception. *JAMA Otolaryngol Head Neck Surg.* 2020;146(11):993-994.
- Pondaven-Letourmy S, Alvin F, Boumghit Y, Simon F. How to perform a nasopharyngeal swab in adults and children in the COVID-19 era. *Eur Ann Otorhinolaryngol Head Neck Dis.* 2020;137(4):325-327.
- Suhaili DN, Goh BS, Gendeh BS. A ten year retrospective review of orbital complications secondary to acute sinusitis in children. *Med J Malaysia.* 2010;65(1):49-52.
- Givner LB. Periorbital versus orbital cellulitis. *Pediatr Infect Dis J.* 2002;21(12):1157-1158.
- Wong SJ, Levi J. Management of pediatric orbital cellulitis: a systematic review. *Int J Pediatr Otorhinolaryngol.* 2018;110:123-129.

**How to cite this article:** Abdul-Kadir M-A, Rosli A-H. Orbital cellulitis complicated with subperiosteal abscess following post-nasopharyngeal swab for COVID-19: A case report. *Clin Case Rep.* 2023;11:e07324. doi:[10.1002/ccr3.7324](https://doi.org/10.1002/ccr3.7324)