

Tonsillitis



● Diagnosis almost certain

Case contributed by Mohd Radhwan Bin Abidin

× Citation, DOI, disclosures and case data

Share

Add to ▾

Citation: Abidin M, Tonsillitis. Case study, Radiopaedia.org (Accessed on 19 Dec 2023) <https://doi.org/10.53347/rID-175784>

DOI: <https://doi.org/10.53347/rID-175784>

Permalink: <https://radiopaedia.org/cases/175784>

rID: 175784

Disclosures: At the time the case was submitted for publication Mohd Radhwan Bin Abidin had no financial relationships to ineligible companies to disclose.

[View Mohd Radhwan Bin Abidin's current disclosures](#)

Case published: 21 Sep 2023

Revisions: 3 times, by 3 contributors - see full revision history and disclosures

Systems: Head & Neck

Institution: International Islamic University Malaysia

Quiz mode: Excluded

How to use cases

You can use Radiopaedia cases in a variety of ways to help you learn and teach.

- Add cases to playlists
- Share cases with the diagnosis hidden
- Use images in presentations
- Use them in multiple choice question

Creating your own cases is easy.

- Case creation learning pathway

Presentation

Dysphagia with intermittent choking.

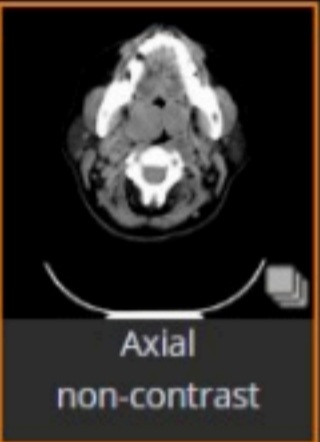
Patient Data

Age: 50 years

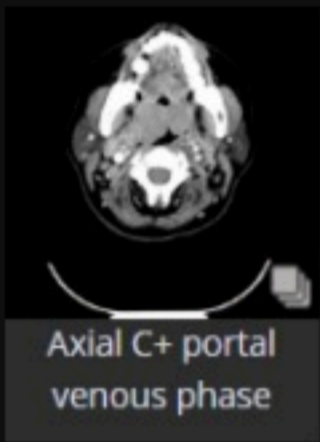
Gender: Female

Neck

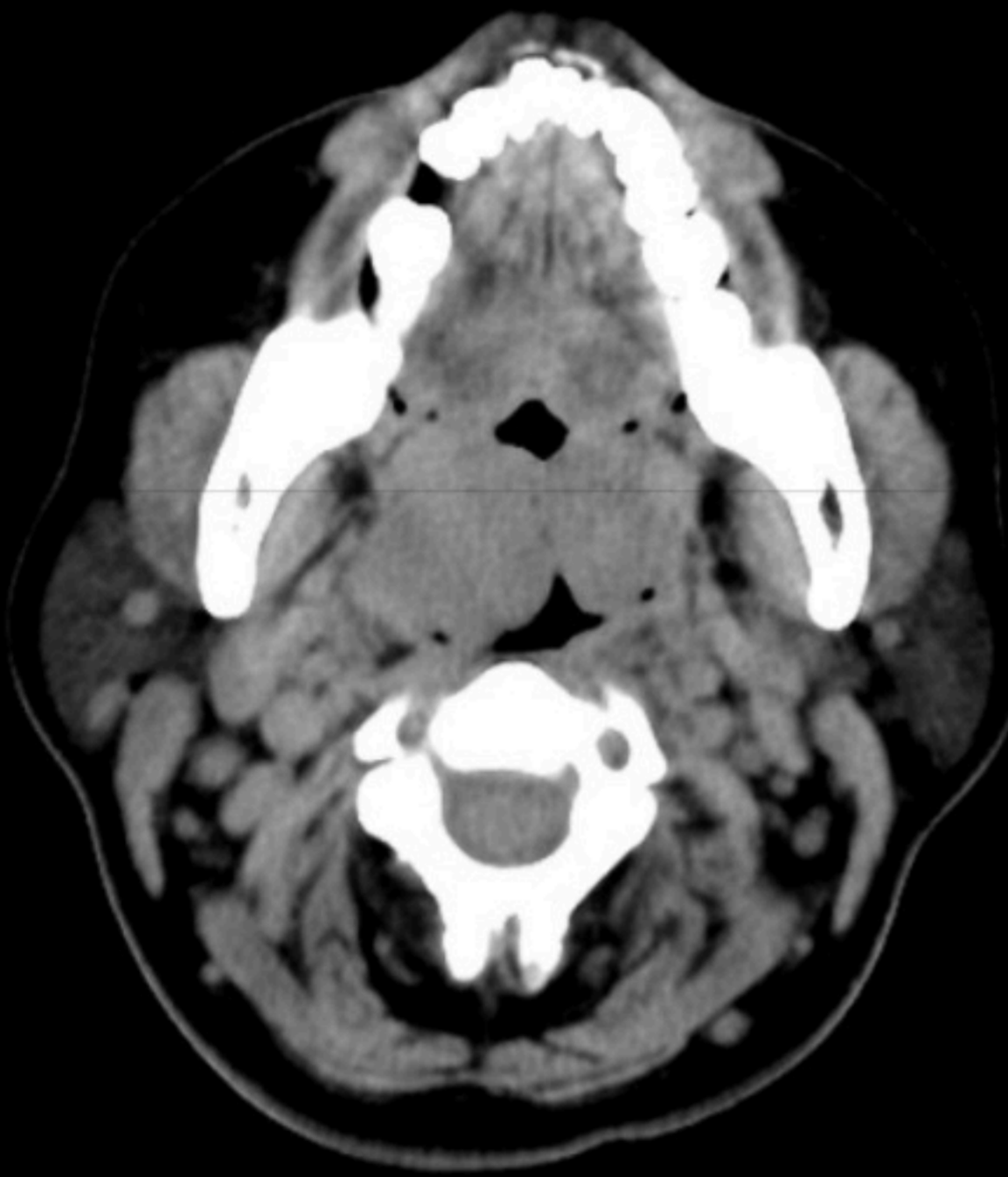
CT



Axial non-contrast



Axial C+ portal venous phase



Bilateral palatine tonsils are enlarged, and touching each other forming a 'kissing tonsils' sign. It causes significant airway obstruction. Adenoid tonsils are also enlarged. However, no airway obstruction.

Multiple enlarged cervical nodes. Deep spaces of the neck are normal. Bilateral internal jugular veins and internal carotid arteries are patent.

Case Discussion

Bilateral palatine and adenoid tonsillitis causing significant airway obstruction.

Kissing tonsils sign is the enlargement of bilateral palatine tonsils touching each other. It causes significant airway obstruction.

ADVERTISEMENT: Supporters see fewer/no ads

← Ads by Google

Send feedback

Why this ad? ⓘ