

MSGH BULLETIN 2023 SUPPLEMENT

GUT 2023



Malaysian Society of
Gastroenterology & Hepatology

in collaboration with:



Asian Pacific Association
of Gastroenterology

Annual Scientific Meeting of **MSGH**

incorporating

**12th Asian Pacific Topic Conference 2023
on Gut Microbiota**

Translating Science into Real-World Practice

18th to 20th August 2023

Shangri-La Kuala Lumpur, Malaysia

www.msgh.org.my

CONTENTS

MSGH Executive Committee 2021-2023	2
Organising Committee, GUT 2023	3
Message from the President, MSGH 2021-2023 & Organising Chair GUT 2023	4
23 rd MSGH Oration - Professor Dr Michael Kamm Citation by Professor Dr Ida Normiha Hilmi	5
20 th Panir Chelvam Memorial Lecture - Professor Dr Jose D Sollano, Jr Citation by Professor Dr Chan Wah Kheong	6 - 7
Programme Summary	8
Pre-Congress Workshop 1 & 2	9 - 11
Daily Programme	
• 18 th August 2023 (Friday)	12 - 14
• 19 th August 2023 (Saturday)	15 - 17
• 20 th August 2023 (Sunday)	18 - 19
Moderators / Chairpersons	20 - 21
Faculty Biodata	22 - 40
List of Abstracts	
• Lectures & Symposia	41 - 88
• E-Poster Presentations	89 - 99
• Oral Presentations	100- 108
• Poster Presentations	109 - 209
Floor Plan	210
Trade Exhibition	211
Acknowledgements	212 - 213

MSGH EXECUTIVE COMMITTEE 2021-2023

President

Professor Dr Lee Yeong Yeh

President Elect

Datuk Dr Raman Muthukaruppan

Immediate Past President

Professor Dr Raja Affendi Raja Ali

Honorary Secretary

Dr Haniza Omar

Honorary Treasurer

Dr Sattian Kollanavelu

Executive Committee Members

Professor Dr Ida Normiha Hilmi

Datuk Dr Jayaram Menon

Dato' Dr Mahendra Raj

Dr Nik Razima Wan Ibrahim

Datuk Dr Ryan Ponnudurai

Coopted Executive Committee Members

Dr Abraham Mathew George

Dr Alex Leow Hwong Ruey

Dr Soon Su Yang

Dr Tan Soek Siam

ORGANISING COMMITTEE

Chair, Organising Committee
Co-Chair, Scientific Committee
Finance & Sponsorship
Professor Dr Lee Yeong Yeh

Co-Chair, Organising Committee
Datuk Dr Raman Muthukaruppan

Chair, Scientific Committee
Dr Haniza Omar

Scientific Committee
Professor Dr Ida Normiha Hilmi
Datuk Dr Jayaram Menon
Dato' Dr S Mahendra Raj
Dr Soon Su Yang

Publicity & Social Media
Dr Nik Razima
Professor Dr Raja Affendi Raja Ali
Dr Tan Soek Siam
Dr Abraham George

Finance & Sponsorship
Dr Sattian Kollanavelu
Datuk Dr Ryan Ponnudurai
Dr Alex Leow Hwong Ruey

Scientific Advisory Members
Professor Dr Emad El-Omar
Professor Dr Justin Wu Che-Yuen

MESSAGE



Dear Colleagues and Friends

On behalf of the Organising Committee, we extend our warmest welcome. Our flagship Annual Scientific Congress, GUT 2023, now in its 28th iteration, also incorporates the 12th Asian Pacific Topic Conference (APTC) 2023 on Gut Microbiota. The overarching theme is 'Translating Science into Real-World Practice'. We hope you will enjoy the scientific programme and the typical Malaysian hospitality.

The 12th APTC is a single topic conference on gut microbiota co-hosted with the Asian Pacific Association of Gastroenterology. The science of gut microbiota has grown exponentially in the past decade, and its importance in real-world clinical practice is greatly felt. Brought to you by a scientific team led by Professor Dr Emad El-Omar, Sydney, Australia, the aim is to bridge the gap between science and clinical practice. We have planned a meticulous scientific programme and a selection of world-class faculty. This meeting will be in a hybrid format where attendees from the Asia Pacific can have the option to attend either physically or virtually.

As per previous years, GUT 2023 is designed for everyone with an interest in gut health including primary care practitioners, family physicians, scientists, surgeons, general physicians and gastroenterologists. For the very first time, GUT 2023 will feature a motility workshop as a pre-congress programme. The Congress has received more than 80 high-quality research papers, and selected authors will stand a chance to win the prestigious Young Investigator Awards for best oral papers and e-posters. In addition, we will have more than 30 industry partners at the physical booths offering the most innovative and latest information on products and equipment.

As the Organising Committee, we are excited with our scientific programme and hope you are too. We look forward to your participation in the scientific discussion and deliberations.

A handwritten signature in black ink, appearing to read 'Lee Yeong Yeh'.

**Professor Dr
Lee Yeong Yeh**
Organising Chair GUT 2023 &
President, MSGH

A handwritten signature in black ink, appearing to read 'Justin Wu Che-Yuen'.

**Professor Dr
Justin Wu Che-Yuen**
President, APAGE

A handwritten signature in black ink, appearing to read 'Emad El-Omar'.

**Professor Dr
Emad El-Omar**
Lead Scientific Advisor
12th APTC 2023

23RD MSGH ORATION

PROFESSOR DR MICHAEL KAMM

Citation by Professor Dr Ida Normiha Hilmi



“The Gut Microbiome - Cause and Cure of Gut Diseases”

Professor Dr Michael Kamm graduated in Medicine from the University of Melbourne and St Vincent's Hospital in 1978. For 22 years, from 1986 till 2008, he worked at St Mark's Hospital, the London specialist hospital for intestinal diseases, where he was Professor of Gastroenterology (Imperial College), Chairman of Medicine, and Director of the Inflammatory Bowel Disease and Physiology Units. In 2008, he returned to his hometown, Melbourne, to establish a clinical practice, and to take up a clinical, research and academic position at St Vincent's Hospital and University of Melbourne.

Professor Kamm is a recognized world leader in the field of both functional and inflammatory bowel disease (IBD) and his phenomenal research over the decades has resulted in groundbreaking changes of many conditions with a current H index of 150 (global top 1%), six books on inflammatory bowel disease and functional gut disorders, approximately 800 peer-reviewed original publications (including in the New England Journal of Medicine and the Lancet), 26 book chapters and 11 Leading Articles or Editorials. He is on the Editorial Board of several journals and has won numerous awards for his academic achievements. In terms of functional anorectal diseases, he was responsible for the development of topical nitric oxide donors and calcium channel blockers which have supplanted surgical sphincterotomy for anal fissure. He also developed behavioural therapies and sacral electrical stimulation which have become successful treatments for constipation and incontinence; as well as identifying three new myopathies affecting intestinal or sphincter smooth muscle.

His contribution to IBD has been equally remarkable. He conducted the first controlled trial of anti-TNF therapy in Crohn's disease. Upon his return to Asia Pacific, he quickly developed a framework for IBD research in collaboration with Professor Siew-Chien Ng from the Chinese University of Hong Kong. The ACCESS collaboration has produced multiple landmark papers on the epidemiology of IBD in Asia. He is currently running a large collaborative study examining the microbiological and dietary basis that may be responsible for the recent emergence of IBD in Asia (the “ENIGMA” study). He published the landmark Post Operative Crohn's Endoscopic Recurrence (“POCER”) study in the Lancet which has resulted in a paradigm shift in the post operative surveillance and management for Crohn's disease. He has been instrumental in changing cancer surveillance practice and international guidelines, based on research in large long-term cohorts.

Professor Kamm is a speaker par excellence; with a unique style that makes his talks both simultaneously highly educational and enthralling. In recognition of this global giant in gastroenterology, we are very privileged to have Professor Kamm to deliver this year's MSGH oration “The Gut Microbiome - Cause and Cure of Gut Diseases”.

20TH PANIR CHELVAM MEMORIAL LECTURE

PROFESSOR DR JOSE D SOLLANO, JR

Citation by Professor Dr Chan Wah Kheong



“NAFLD, MAFLD, MASLD and Fatty Liver: What’s the debate all about?”

Professor Dr Jose D Sollano, a remarkable beacon in the field of Medicine, stands as an inspiring figure whose contributions have reshaped the landscape of Gastroenterology and ignited a wave of transformative change across Asia and beyond.

A distinguished alumnus of the University of Santo Tomas, Professor Dr Sollano’s unwavering dedication to his craft has propelled him to the forefront of medical excellence. As a Professor in the Faculty of Medicine and Surgery of the University of Santo Tomas and Chief of Endoscopy of the University Hospital, the added expertise he gained from foreign trainings in Hepatology and Advanced Therapeutic Endoscopy inspired him to open novel training programmes to not only train countless aspiring physicians but also instilled a passion for knowledge and excellence in future generations of medical professionals.

Professor Dr Sollano’s visionary spirit manifested early in his career when he established the Inflammatory Bowel Disease (IBD) Club of the Philippines in 1990, paving the way for groundbreaking epidemiological study and enhanced understanding of IBD in his homeland. Through his pioneering efforts, he has brought hope and improved the lives of numerous patients, while shaping the trajectory of medical advancements in the country.

The depth of Professor Dr Sollano’s knowledge is mirrored in his varied publications, encompassing peer-reviewed articles across multiple disciplines. His expertise spans a wide range, from inflammatory bowel diseases to chronic hepatitis B & C, gastroesophageal reflux disease, and therapeutic endoscopy. This breadth of knowledge has positioned him as a key opinion leader in Asia, where he has played a pivotal role in the development of several clinical practice guidelines, contributing significantly to the advancement of medical standards in the region.

Recognized for his exceptional leadership skills, Professor Dr Sollano has held esteemed positions in prestigious organizations, assuming the Presidency of the Philippine College of Physicians, the Hepatology Society of the Philippines, the Philippine Society of Gastroenterology & Digestive Endoscopy, and the Asian Pacific Association for the Study of the Liver (APASL). He is recognized with a Lifetime Achievement Award by the Philippine Society of Gastroenterology and is the recipient of the prestigious 2023 Jose P Rizal Award of the Philippine Medical Association.



20TH PANIR CHELVAM MEMORIAL LECTURE

PROFESSOR DR JOSE D SOLLANO, JR

Citation by Professor Dr Chan Wah Kheong

His unwavering commitment to serving others and improving healthcare systems has made him a trusted figure and a source of inspiration for colleagues in the region and in the world.

As we reflect upon the remarkable achievements of Prof Sollano, we are reminded that true greatness lies not only in individual accomplishments but also in the positive impact one has on the lives of others. Through his pioneering research, leadership and dedication, Professor Dr Sollano has left an indelible mark on the field of Gastroenterology, inspiring a generation of medical professionals to reach new heights and revolutionize the way we approach patient care.

It is my pleasure and honour to call upon Prof Sollano to deliver the 20th Panir Chelvam Lecture entitled “NAFLD, MAFLD, MASLD and Fatty Liver: What’s the debate all about?”

PROGRAMME SUMMARY

Date Time	16 th August 2023 (Wednesday)	17 th August 2023 (Thursday)	18 th August 2023 (Friday)	19 th August 2023 (Saturday)		20 th August 2023 (Sunday)			
	PRE-CONGRESS WORKSHOPS		GUT 2023 - Sabah Room	GUT 2023 - Sabah Room	12th APTC - Sarawak Room	GUT 2023 - Sabah Room	12th APTC - Sarawak Room		
0700 - 0800	Pre-Congress Workshop 1 DAY 1: G.I. MOTILITY WORKSHOP Venue : UiTM Puncak Alam, Selangor, Malaysia	Pre-Congress Workshop 1 DAY 2: G.I. MOTILITY WORKSHOP Venue : UiTM Puncak Alam, Selangor, Malaysia				MSGH MAFLD Interest Group Inaugural Meeting <i>(Pre-Registration Required)</i>			
0800 - 0830			WELCOME REMARKS						
0830 - 0900			SYMPOSIUM 1 Overlap Gut-Brain Disorders	SYMPOSIUM 3 Inflammatory Bowel Disease	SYMPOSIUM A Basic Science - Gut Microbiota in Health	SYMPOSIUM 6 Metabolic-Associated Fatty Liver Disease	SYMPOSIUM D Gut Microbiota and Disorders of the Brain-Gut Axis		
0900 - 0930									
0930 - 1000									
1000 - 1030				LECTURE 1 20 th Panir Chelvam Lecture	LECTURE 2 23 rd MSGH Oration		STATE-OF-ART LECTURE		
1030 - 1100				Break / Booth Visit					
1100 - 1130				Young Investigator Award	SYMPOSIUM 4 Hepatocellular Carcinoma	SYMPOSIUM B Gut Microbiota and GI Cancers	SYMPOSIUM 7 Colorectal Cancer	SYMPOSIUM E Gut Microbiota-Translating Research into Practice	
1130 - 1200									
1200 - 1230									
1230 - 1300				Lunch Satellite Symposium 1	Lunch Satellite Symposium 3		Lunch Satellite Symposium 5		
1300 - 1330									
1330 - 1400				Lunch Satellite Symposium 2	Lunch Satellite Symposium 4		Closing and Prize Presentation		
1400 - 1430							Lunch		
1430 - 1500									
1500 - 1530				SYMPOSIUM 2 GERD	SYMPOSIUM 5 Disorders of EGJ Outflow - A Joint Societies Consensus	SYMPOSIUM C Manipulation of Gut Microbiota			
1530 - 1600									
1600 - 1630				Break / Booth Visit					
1630 - 1700			Tea Satellite Symposium 1	Tea Satellite Symposium 2					
1700 - 1730									
1730 - 1800									
1800 - 1900									
1930 - 2130					OPENING CEREMONY	MSGH Annual General Meeting			
					Presidential Dinner <i>(By Invitation Only)</i>				
		Pre-Congress Workshop 2 NEW INSIGHTS ON CHRONIC LIVER DISEASE AND PORTAL HYPERTENSION: UPDATE FROM BAVENO VII Time : 1730 hrs - 2130 hrs Venue : Perak Room, Shangri-La Hotel, Malaysia							

PRE-CONGRESS WORKSHOP 1

G.I. MOTILITY WORKSHOP *(By Invitation Only)*

Date : 16th - 17th August 2023 (Wednesday - Thursday)

Venue : UiTM Puncak Alam, Selangor, Malaysia

The GUT 2023 MSGH Annual Scientific Meeting Motility Pre-Congress Workshop marks historic first for a gastrointestinal (GI) motility being organised in conjunction with the acclaimed GUT conference. The two-day programme is organised in collaboration by the Malaysian Society of Gastroenterology & Hepatology (MSGH), Gastroenterology Unit of Universiti Teknologi MARA (GastroUiTM) and Medic Pro Healthcare and will be held at the new Hospital Al-Sultan Abdullah UiTM in Puncak Alam, Selangor.

The workshop is held in recognition of the increasing importance that motility and pH impedance testing plays in our day-to-day clinical practice and aim to highlight its indispensable role. Under the tutelage of Professor Dr Lee Yeong Yeh, it promises to be a thrilling programme incorporating a series of lectures and hands-on sessions on the pertinent aspects of Oesophageal High-Resolution Manometry and 24-hour pH Impedance Reflux Monitoring.

Future advances will also be highlighted, with *The MiVu™ Mucosal Integrity Testing System* being put on the spotlight during its official launch at the event, introducing an exciting new technology to budding and seasoned motility enthusiasts.

The GUT 2023 MSGH Annual Scientific Meeting Motility Pre-Congress Workshop represents the coming of age for neurogastroenterology and GI motility in Malaysia, with an exciting programme for all GI motility enthusiasts as well as the opportunity to convene and interact with experts of the field. See you there!

MSGH GUT 2023 Pre-Congress
G.I. Motility Workshop

16th to 17th August 2023

Hospital Al-Sultan Abdullah,
UiTM Puncak Alam,
Selangor, Malaysia

Highlights

- High Resolution Impedance Manometry
- pH-Impedance Study
- MiVu Mucosal Integrity Testing System

ORGANIZED BY :

Malaysian Society of Gastroenterology & Hepatology
Universiti Teknologi MARA
Gastroenterology Unit of Universiti Teknologi MARA
MedicPro™

PRE-CONGRESS WORKSHOP 2

NEW INSIGHTS ON CHRONIC LIVER DISEASE AND PORTAL HYPERTENSION: UPDATE FROM BAVENO VII

(By Invitation Only)

Date : 17th August 2023 (Thursday)

Venue : Perak Room, Shangri-La Kuala Lumpur, Malaysia

Moderators : Sanjiv Mahadeva, Haniza Omar, Ganesalingam Kanagasabai

PROGRAMME

1730 - 1800 Registration / Refreshment

1800 - 1805 Welcome Speech

Lee Yeong Yeh

1805 - 1825 Integrating New Concepts in Liver Cirrhosis in Clinical Practice

Tan Soek Siam

1825 - 1845 Delaying Variceal Surveillance: Convincing or Contentious?

Ruveena Bhavani Rajaram

1845 - 1905 FibroScan® and Liver Diseases: Utility & Practical Application

Chan Wah Kheong

1905 - 2000 Hands-On Session

2000 - 2030 Case Discussion

Nik Arsyad Nik Mohamad Affendi

2030 - 2130 Closing Remarks & Dinner

Ruveena Bhavani Rajaram

PRE-CONGRESS WORKSHOP 2



Malaysian Society of
Gastroenterology and Hepatology

NEW INSIGHT ON CHRONIC LIVER DISEASE & PORTAL HYPERTENSION **UPDATE FROM BAVENO VII**

Date: 17th August 2023 (Thursday)

Venue: Perak Room (Shangri-La Hotel KL)

Time: 6.00pm to 9.30pm

Moderators: Prof. Dr Sanjiv Mahadeva, Dr Haniza Omar, Dr Ganesalingam Kanagasabai



Integrating New Concepts in Liver Cirrhosis in Clinical Practice

Dr Tan Soek Siam
Hospital Selayang



Delaying Variceal Surveillance: Convincing or Contentious?

Dr Ruveena Bhavani Rajaram
University Malaya Medical Centre



FibroScan and Liver Diseases: Utility and Practical Application

Prof. Dr. Chan Wah Kheong
University Malaya Medical Centre
#Hands-on: FibroScan with Spleen Stiffness Measurement (SSM)



Case Discussion

Dr Nik Arsyad Nik Muhamad Affendi
International Islamic University Malaysia

For free registration please contact the below (while seats are available):



017-362 4228

cheesan.wong@uitm.net

- Guests registration/ refreshment starts at 5.30pm,
- Closing/Dinner at 8.30pm

echosens

UITM

DAILY PROGRAMME

18th August 2023 (Friday)

Sabah Room

- 0820 - 0830 Welcome Remarks by Organising Chair & President of MSGH
Lee Yeong Yeh
- 0830 - 1000 **SYMPOSIUM 1 | Overlap Gut-Brain Disorders**
Moderators: Lee Yeong Yeh / Raja Affendi Raja Ali
Epidemiology and Impact of Overlap Gut-Brain Disorders
Gerald Holtmann (Australia)

Pathophysiology of Overlap Gut-Brain Disorders
Kok-Ann Gwee (Singapore)

Management of Overlap Gut-Brain Disorders
Uday Chand Ghoshal (India)

Interactive Case-Based Discussion
Case 1 - FD-Constipation
Kewin Siah (Singapore)

Case 2 - FD-GERD
Khairul Najmi (Malaysia)

Q&A
- 1000 - 1030 **LECTURE 1**
20th Panir Chelvam Lecture
Citation: Chan Wah Kheong
NAFLD, MAFLD, MASLD and Fatty Liver: What's the Debate All About?
Jose D Sollano, Jr (Philippines)
- 1030 - 1100 Break / Booth Visit
- 1100 - 1230 **Young Investigator Award**
• **Best Oral Paper**
• **Best e-Poster**

DAILY PROGRAMME

18th August 2023 (Friday)

Sabah Room

- 1230 - 1330 **Lunch Satellite Symposium 1 (Pfizer)**
Moderator: Ida Normiha Hilmi
New Horizon in Ulcerative Colitis Treatment: the Role of Tofacitinib
Taku Kobayashi (Japan) - Virtual
- 1330 - 1430 **Lunch Satellite Symposium 2 (Servier)**
Exploring the GI Tract's Final Frontier: Dysbiosis and Hemorrhoidal Disease
Moderator: Mahendra Raj
Lecture 1 - Connecting the Dots between Diarrhoea and Dysbiosis
Lee Yeong Yeh (Malaysia)

Lecture 2 - Recent Advances in the Management of Hemorrhoidal Disease
Paul Selvindoss (Malaysia)
- 1430 - 1600 **SYMPOSIUM 2 | Conundrums in Approach & Management of GERD**
Moderators: Andrew Chua Seng Boon / Abraham George
Refractory GERD: Clinical Significance and Treatment Options
Somchai Leelakusolvong (Thailand)

Joint MSGH-SEAGMA Lecture: Approach to Overlapping Disorders in GERD
Hidekazu Suzuki (Japan)

What is the Role of Manometry & pH-Impedance in GERD? Case Studies
Justin Wu Che-Yuen (Hong Kong)

Laparoscopic Fundoplication for GERD: The Who, What and How
Siow Sze Li (Malaysia)

Q&A
- 1600 - 1630 Break / Booth Visit

DAILY PROGRAMME

18th August 2023 (Friday)

Sabah Room

1630 - 1800	Tea Satellite Symposium 1	
1630 - 1700	<i>Moderator: Nazri Mustaffa</i> Mesalazine Granules for IBD, an Old Drug in New Splendour (<i>DCH Auriga</i>) <i>Wolfgang Kruis (Germany) - Virtual</i>	
1700 - 1730	<i>Moderator: Ida Normiha Hilmi</i> IBD Monitoring Reimagined: Patient Centric Innovation - Current State and Future Directions (<i>Ferring</i>) <i>Alex Leow Hwong Ruey (Malaysia)</i>	
	Panel Discussion: Empowering the Patients, Excelling in Disease Control - Real World Scenarios in IBD (<i>Ferring</i>) <i>Panelists: Ida Normiha Hilmi / Alex Leow Hwong Ruey / Sooi Choong Yeong</i>	
1730 - 1800	<i>Moderator: Nik Razima</i> Moving Toward Remission: Long Term Treatment and Real-World Effectiveness of Ustekinumab in IBD (<i>Johnson & Johnson</i>) <i>Malcolm Tan Teck Kiang (Singapore)</i>	
1800 - 1900	OPENING CEREMONY Speeches by <i>Lee Yeong Yeh / Justin Wu Che-Yuen / Emad El-Omar</i>	Grand Ballroom Foyer
1930 - 2130	PRESIDENTIAL DINNER (<i>By Invitation Only</i>)	Sarawak Room

DAILY PROGRAMME

19th August 2023 (Saturday)

	GUT 2023 - Sabah Room	12 th APTC - Sarawak Room
0830 - 1000	<p>SYMPOSIUM 3 Inflammatory Bowel Disease (Joint RAPID-MSGH Forum) Moderators: Wong Zhiqin / Ida Normiha Hilmi</p> <p>Common Errors in the Diagnosis of IBD and How to Avoid Them <i>Siew-Chien Ng (Hong Kong)</i></p> <p>Mimics of IBD</p> <ol style="list-style-type: none"> Histological Perspectives (10 min) <i>Pavitratha Puspanathan (Malaysia)</i> Clinical Perspectives (10 min) <i>Soo-Kyung Park (Korea)</i> <p>Is it Time to Bid Adieu to Serology in the Diagnosis of IBD? <i>Juanda Leo Hartono (Singapore)</i></p> <p>Q&A</p> <p>Case Discussion on IBD-associated Dysplasia Panelists: Luqman Mazlan / Juanda Leo Hartono / Pavitratha Puspanathan</p> <p>CASE 1 <i>Nik Arsyad Nik Mohamad Affendi (Malaysia)</i></p> <p>CASE 2 <i>Subhathira Manohkaran (Malaysia)</i></p>	<p>SYMPOSIUM A Basic Science - Gut Microbiota in Health Moderators: Mahendra Raj / Lee Yeong Yeh</p> <p>Early Life & Ageing <i>Emad El-Omar (Australia)</i></p> <p>Diet & the Environment <i>Michael Kamm (Australia)</i></p> <p>Making Sense of Metagenomics <i>Howard Yim Chi Ho (Australia)</i></p> <p>Making Sense of Metabolomics <i>Chong Chun Wie (Malaysia)</i></p> <p>Q&A</p>
1000 - 1030	<p>LECTURE 2 23rd MSGH Oration Citation: Ida Normiha Hilmi</p> <p>The Gut Microbiome - Cause and Cure of Gut Diseases <i>Michael Kamm (Australia)</i></p>	Sabah Room
1030 - 1100	Break / Booth Visit	

DAILY PROGRAMME

19th August 2023 (Saturday)

	GUT 2023 - Sabah Room	12 th APTC - Sarawak Room
1100 - 1230	<p>SYMPOSIUM 4 Hepatocellular Carcinoma (Liver Multidisciplinary-Themed Symposium) Moderators: Sattian Kollanthavelu / Tan Soek Siam Navigating the Complex Treatment Algorithm of HCC <i>Cosmas Rinaldi A Lesmana (Indonesia) - Virtual</i></p> <p>Supported Lecture (Roche) Revolutionizing HCC Surveillance: The Role of Innovative Biomarkers in Early Detection and Diagnosis <i>Tawesak Tawandee (Thailand)</i></p> <p>Liver Transplant in HCC - DDLT vs LDLT Settings. MSGH-MST Joint Societies Lectureship <i>Mark Dhinesh Muthiah (Singapore)</i></p> <p>Q&A</p>	<p>SYMPOSIUM B Gut Microbiota and GI Cancers Moderators: Mahendra Raj / Nik Razima Gastric Cancer <i>Francis Chan Ka Leung (Hong Kong)</i></p> <p>Gut Microbiome and Hepatocellular Carcinoma <i>Amany Zekry (Australia)</i></p> <p>Colorectal Cancer <i>Joseph J Y Sung (Singapore)</i></p> <p>Pancreatic Cancer <i>Christian Jobin (United States) - Virtual</i></p> <p>Q&A</p>
1230 - 1330	<p>Lunch Satellite Symposium 3 (AstraZeneca) Moderator: Ryan Ponnudurai Rationale Use of Acid Suppressive Therapy <i>Francis Chan Ka Leung (Hong Kong)</i></p>	Sabah Room
1330 - 1430	<p>Lunch Satellite Symposium 4 (Takeda) Moderator: Raja Affendi Raja Ali Lecture 1: Optimising Treatment Options in IBD Management <i>Siew-Chien Ng (Hong Kong)</i></p> <p>Lecture 2: Diagnosis and Treatment of <i>Helicobacter pylori</i> Infection - Updates on the Latest Malaysian Consensus Report <i>Alex Leow Hwong Ruey (Malaysia)</i></p>	Sabah Room

DAILY PROGRAMME

19th August 2023 (Saturday)

	GUT 2023 - Sabah Room	12 th APTC - Sarawak Room
1430 - 1600	<p>SYMPOSIUM 5 Disorders of EGJ Outflow - A Joint Societies Consensus (Upper GI Multidisciplinary-Themed Symposium) Moderators: Raman Muthukaruppan / Sattian Kollanthavelu</p> <p>Definition, Who and How Should One be Tested? <i>Lee Yeong Yeh (Malaysia)</i></p> <p>What are the Diagnostic Tests and Treatment Outcomes? <i>Chuah Kee Huat (Malaysia)</i></p> <p>What are the Non-Surgical and Surgical Options? <i>Hans Alexander Mahendran (Malaysia)</i></p> <p>What Other Considerations? Post-Treatment Complications, Relapse or Refractory, and Cancer Surveillance <i>Ho Shiaw Hooi (Malaysia)</i></p> <p>Q&A</p>	<p>SYMPOSIUM C Manipulation of Gut Microbiota Moderators: Sanjiv Mahadeva / Soon Su Yang</p> <p>Manipulation of Gut Microbiota Using Probiotics in Management of Irritable Bowel Syndrome <i>Uday Chand Ghoshal (India)</i></p> <p>Prebiotics and Fibre <i>Gerald Holtmann (Australia)</i></p> <p>Faecal Transplantation <i>Jonathan Lee Wei Jie (Singapore) - Virtual</i></p> <p>Other Novel Approaches <i>David Ong Eng Hui (Singapore)</i></p> <p>Q&A</p>
1600 - 1630	Break / Booth Visit	
1630 - 1800	Sabah Room	
1630 - 1700	<p>Tea Satellite Symposium 2</p> <p>Moderator: Ruveena Bhavani Rajaram Anchoring Holistic Management of Fatty Liver in Asian Context (<i>Viatris</i>) <i>George Boon-Bee Goh (Singapore)</i></p>	
1700 - 1730	<p>Moderator: Chan Wah Kheong Clinical evidence and usage of UDCA in management of MAFLD (<i>Pro.Med.Cs</i>) <i>Krzysztof Tomaszewicz (Poland)</i></p>	
1730 - 1800	<p>Moderator: Raja Affendi Raja Ali Closing the Immunisation Gap towards a Hepatitis-Free Nation (<i>GSK</i>) <i>Tan Soek Siam (Malaysia)</i></p>	
1800 - 1930	Perak Room	
	MSGH Annual General Meeting	

DAILY PROGRAMME

20th August 2023 (Sunday)

0700 - 0820 **MSGH MAFLD Interest Group Inaugural Meeting** (*Pre-Registration Required*) Perak Room
Chairpersons: Tan Soek Siam / Chan Siew Pheng
Rapporteur: Ang Ban Hong
 Implementing the Right Care in the Right Place for MAFLD for People with Type 2 Diabetes and/or Metabolic Diseases - Case Identification

GUT 2023 - Sabah Room	12 th APTC - Sarawak Room
<p>0830 - 1000</p> <p>SYMPOSIUM 6 Metabolic-Associated Fatty Liver Disease <i>Moderators:</i> Tan Soek Siam / Haniza Omar From NAFLD to MAFLD <i>Krzysztof Tomasiewicz (Poland)</i></p> <p>The Patient with MAFLD and High Liver Stiffness Measurement: What Next? <i>Chan Wah Kheong (Malaysia)</i></p> <p>A Practical Approach to Lifestyle Modification and Cardiovascular Disease Risk Reduction for MAFLD <i>George Boon-Bee Goh (Singapore)</i></p> <p>Emerging Novel Therapies for Steatohepatitis <i>Phunchai Charatcharoenwiththaya (Thailand) - Virtual</i></p> <p>Is There a Role for “-biotics” in MAFLD? <i>Amany Zekry (Australia)</i></p> <p>Q&A</p>	<p>SYMPOSIUM D Gut Microbiota and Disorders of the Brain-Gut Axis <i>Moderators:</i> Raja Affendi Raja Ali, Emad El-Omar The Microbiota-Gut-Brain Axis as an Experience-Dependent Modulator of Brain Function and Dysfunction <i>Anthony Hannan (Australia)</i></p> <p>Neurodevelopmental Disorders <i>Sven Pettersson (Singapore)</i></p> <p>Mood and Depressive Disorders <i>Felice Jacka (Australia) - Virtual</i></p> <p>Disorders of Gut-Brain Interactions <i>Justin Wu Che-Yuen (Hong Kong)</i></p> <p>Q&A</p>

1000 - 1030 **STATE-OF-ART LECTURE** Sabah Room
Moderator: Lee Yeong Yeh
 Gut Microbiota and Metabolic Disorders
Chun-Ying Wu (Taiwan) - Virtual

1030 - 1100 Break / Booth Visit

DAILY PROGRAMME

20th August 2023 (Sunday)

	GUT 2023 - Sabah Room	12 th APTC - Sarawak Room
1100 - 1230	<p>SYMPOSIUM 7 Colorectal Cancer (Lower GI Multidisciplinary-Themed Symposium) <i>Moderators:</i> Fitjerald Henry / Jayaram Menon Use of Artificial Intelligence in Colorectal Cancer Screening <i>Joseph J Y Sung (Singapore)</i></p> <p>Colorectal Cancer Screening: Role of Endoscopy Training and Credentialing <i>Benedict Devereaux (Australia)</i></p> <p>CRC Screening: Challenges and Cost-Economic Implications <i>Hyun-Soo Kim (Korea)</i></p> <p>Managing Functional Disorders after Rectal Cancer Surgery <i>Luqman Mazlan (Malaysia)</i></p> <p>Q&A</p>	<p>SYMPOSIUM E Gut Microbiota-Translating Research into Practice <i>Moderators:</i> Chong Chun Wie / Ivy Chung Microbiome Research Centre <i>Emad El-Omar (Australia)</i></p> <p>Clinical Application and Personalisation of the Gut Microbiome <i>Siew-Chien Ng (Hong Kong)</i></p> <p>Start-Up Experience 1: What I Learn from My Journey with AMILI? <i>Jeremy Lim (Singapore) - Virtual</i></p> <p>Start-Up Experience 2: What I Learn from My Journey with AGTC Genomics? <i>Leong Chee Onn (Malaysia)</i></p> <p>Q&A</p>
1230 - 1330	<p>Lunch Satellite Symposium 5 (Abbott) Setting the Right Tone for GI Motility: A Case-Based Discussion <i>Andrew Chua Seng Boon (Malaysia) / Alex Leow Hwong Ruey (Malaysia)</i></p>	Sabah Room
1330 - 1350	<p>Closing and Prize Presentation</p>	Sabah Room
1350 - 1430	<p>Lunch</p>	Melaka Room

MODERATORS

Abraham George

KPJ Johor Specialist Hospital
Johor

Andrew Chua Seng Boon

Pusat Gastro Ipoh
Ipoh, Perak

Ivy Chung

Universiti Malaya
Kuala Lumpur

Fitjerald Henry

Hospital Selayang
Selangor

Haniza Omar

Hospital Selayang
Selangor

Ida Normiha Hilmi

Universiti Malaya Medical Centre
Kuala Lumpur

Jayaram Menon

Pantai Hospital Ayer Keroh
Melaka

Mahendra Raj

Pantai Hospital Kuala Lumpur
Kuala Lumpur

Nazri Mustaffa

Hospital Universiti Sains Malaysia
Kubang Kerian, Kelantan

Nik Arsyad Nik Mohamad Affendi

Universiti Malaya
Kuala Lumpur

Nik Razima Wan Ibrahim

Hospital Serdang
Selangor

Raja Affendi Raja Ali

Universiti Kebangsaan Malaysia Medical Centre
Kuala Lumpur

Raman Muthukaruppan

Hospital Queen Elizabeth
Kota Kinabalu, Sabah

Ryan Ponnudurai

Prince Court Medical Centre
Kuala Lumpur

Ruveena Bhavani Rajaram

Universiti Malaya Medical Centre
Kuala Lumpur

Sattian Kholanthavelu

Hospital Tuanku Ja'afar
Seremban, Negeri Sembilan

MODERATORS

Sanjiv Mahadeva

Universiti Malaya
Kuala Lumpur

Sooi Choong Yeong

Hospital Tengku Ampuan Afzan
Kuantan, Pahang

Soon Su Yang

KPJ Kuching Specialist Hospital
Sarawak

Subhathira Manohkaran

Universiti Malaya
Kuala Lumpur

Tan Huk Joo

Pantai Hospital Kuala Lumpur
Kuala Lumpur

Wong Zhiqin

Universiti Kebangsaan Malaysia
Kuala Lumpur

FACULTY BIODATA



Francis Chan Ka Leung

Professor Dr Francis Chan, Dean of Medicine of The Chinese University of Hong Kong, is an internationally renowned clinician-scientist and an entrepreneur. He pioneered the research of colorectal cancer screening and fecal bacteria-DNA technology and established the Asia's first Microbiota Innovation Center (MagIC). His contributions in gastroenterology are recognized worldwide with numerous awards and honours, including the first Chinese to receive the International Leadership Award of the American College of Gastroenterology in 2018, being named the top 0.06% World Expert in Aspirin by ExpertScape in 2019 and multiple awards in the International Exhibition of Inventions of Geneva 2022 and 2023.



Chan Wah Kheong

Professor Dr Chan is Professor of Medicine at the Universiti Malaya and Senior Consultant Gastroenterologist and Hepatologist at the Universiti Malaya Medical Centre and the Universiti Malaya Specialist Centre. He is Associate Editor for Journal of Gastroenterology and Hepatology, and is in the Editorial Board for Clinical Gastroenterology and Hepatology, Alimentary Pharmacology and Therapeutics, and Clinical and Molecular Hepatology. He has published numerous full papers in peer-reviewed journals. Besides being an expert in the diagnosis and treatment of gastrointestinal and liver diseases, he is passionate about diagnostic and therapeutic endoscopic procedures, including endoscopic ultrasonography and endoscopic retrograde cholangiopancreatography.



Phunchai Charatcharoenwiththaya

Professor Dr Phunchai Charatcharoenwiththaya is the President-Elect of the Thai Association for the Study of the Liver. He holds the position of Consultant at the Faculty of Medicine, Siriraj Hospital and is a Professor of Medicine in the Division of Gastroenterology. Additionally, he serves as an Associate Editor for the Siriraj Medical Journal and is a member of the editorial board for the Journal of Clinical Translational Hepatology. His research interests revolve around chronic liver diseases, with a focus on fatty liver disease, viral hepatitis, autoimmune liver disease, and cirrhotic complications. He has published over 100 peer-reviewed articles.



Chong Chun Wie

Dr Chong is an Associate Professor and the Deputy Head of School (Research) at the School of Pharmacy, Monash University Malaysia. Dr Chong is an experienced researcher in environmental microbial ecology and the human gut microbiome. He strongly advocates microbiome health in Malaysia and has been actively involved in public talks and microbiome bioinformatics training workshops. His current research interest includes understanding the gut-brain axis in the development of neurological disorders, the interplay between diet, gut microbiome and host metabolism, and the impact of antibiotics on the gut microbiome.

FACULTY BIODATA



Andrew Seng Boon Chua

Dato' Dr Andrew Chua Seng Boon graduated from Trinity College Dublin, Ireland in 1986. He started his medical career working at St James Hospital in Dublin before returning back to Malaysia in 1993, and continued working in Ipoh, Malaysia. He is currently the President of SEAGMA, fellow of ROME foundation and a council member of ANMA representing Malaysia. He was also one of the Past-President of the MSGH. Dato Dr Chua is part of Editorial Board Member of the World Journal Of Gastroenterology, Journal of Neurogastroenterology and Motility as well as reviewer for numerous international journals. He has had multiple publications in major journals including Gut, Lancet, BMJ, WJOG, J Neurogastroenterology Motility and many others.



Chuah Kee Huat

Dr Chuah is currently a Consultant in Internal Medicine, Gastroenterology and Hepatology at Universiti Malaya Medical Centre and Universiti Malaya Specialist Centre. He is also a medical lecturer in Universiti Malaya. He is well trained in general gastrointestinal endoscopic procedures and advanced endoscopic procedures, including endoscopic ultrasound (EUS), endoscopic retrograde cholangiopancreatography (ERCP). He has specialist interest in performing oesophageal high-resolution manometry.

Dr Chuah has also made significant contributions to the field through his publications in international peer-reviewed prestigious medical journals, like Clinical Gastroenterology & Hepatology, Alimentary & Pharmacology Therapeutics, Neurogastroenterology & Motility and Liver International. He also received multiple awards for his work from local and international conferences. He is actively participating in local and international research collaborations.



Benedict Devereaux

Professor Dr Benedict (Ben) Devereaux is the President of the Gastroenterological Society of Australia and Professor at the School of Medicine, University of Queensland and a Senior Consultant Gastroenterologist at the Royal Brisbane and Women's Hospital.

He trained at the University of Queensland and Royal Brisbane Hospital before completing fellowships in Endoscopic Retrograde Cholangiopancreatography (ERCP) and Endoscopic Ultrasound (EUS), at Indiana University Medical Center in Indianapolis, USA. He has special interests in pancreatico-biliary endoscopy, pancreatic neoplasia, endoscopy training strategies and governance and infection prevention and control in endoscopy.

FACULTY BIODATA



Emad El-Omar

Professor Dr El-Omar graduated in Medicine from Glasgow University, Scotland, and trained as a gastroenterologist. He worked as a Visiting Scholar/Scientist at Vanderbilt University, TN, and National Cancer Institute, MD, USA, and was Professor of Gastroenterology at Aberdeen University, Scotland, for 16 years before taking up the Chair of Medicine at St George & Sutherland Clinical Campus, UNSW Sydney. He is the Editor in Chief of the journal Gut. His research interests include all aspects of the microbiome, inflammation driven GI cancer and IBD. He is the Director of the UNSW Microbiome Research Centre at St George Hospital, Sydney, Australia.



George Boon-Bee Goh

Dr George Goh is a Senior Consultant Gastroenterologist at Singapore General Hospital, with appointments as fellow of Academy of Medicine, Singapore (FAMS) and member of the American Association for the Study of Liver Disease (AASLD), Clinical Associate Professor, Duke-NUS Medical School and Clinical Lecturer, National University of Singapore. He is currently director of the Clinical Trials Research Centre in SGH.

He has a subspeciality interest in hepatology, particularly MAFLD and is actively involved in several international MAFLD interest groups and consensus networks. He currently leads a dedicated Metabolic Liver Clinic and service at SGH.

As a researcher, he is local Principal Investigator of several ongoing international pharmaceutical interventional MAFLD trials. He has published in the fields of Fatty Liver, liver cirrhosis, hepatocellular carcinoma and organ transplantation, and has been an invited faculty at local, regional and international conferences.

FACULTY BIODATA



Uday Chand Ghoshal

Dr Uday C Ghoshal, MD, DNB, DM, FACG, RFF is Professor and Head of Dept. of Gastroenterology, Sanjay Gandhi Postgraduate Institute of Medical Sciences, Lucknow, India. He is a member of Rome-Asian working team, Rome Working Team on Multinational, Cross-Cultural Research and Intestinal Microenvironment and FGIDs committee of Rome Foundation, Fellow of Rome Foundation and Co-Chair of Rome Research Committee. He is a Fellow of American College of Gastroenterology, and a member of Indian Society of Gastroenterology, Indian National Association of Study of Liver, Society of Gastrointestinal Endoscopy of India (Governing Council Member) and Association of Physicians of India. He is a founder member and the Secretary General of Asian Neurogastroenterology and Motility Association and Honorary Secretary of Indian Motility and Functional Bowel Disease Association. He is currently an associate editor of J Neurogastroenterology and Motility, editorial board member of J Gastroenterol Hepatol, World J Gastroenterol and American J Robotic Surgery. He is also a peer reviewer to 35 international journals. He is in the advisory board of Nature Reviews Gastroenterology and Hepatology. He is the National Coordinator of Indian Society of Gastroenterology Task Force on IBS. He is also the Chair of Epidemiology and Infection section of Asian IBS Consensus and Asian Dyspepsia Consensus Teams and member of Asian Barrett's Consortium. He has received 33 awards and orations including 8 gold medals during MBBS study. He was a visiting clinician to Mayo Clinic, Scottsdale, USA, Hamad Medical Corporation, Doha, Qatar, and WHO Fellow in Prince of Songkhla University, Hat Yai, Thailand. To date he has 367 publications with 15489 citations and H index: 64.



Kok-Ann Gwee

Associate Professor Dr Kok-Ann Gwee is Adjunct Associate Professor of Medicine at the National University of Singapore, and Consultant Gastroenterologist at Gleneagles Hospital, Singapore. He obtained his PhD from University of Sheffield for his thesis on Post-infection IBS. His research includes epidemiology and Asian socio-cultural perspectives of GI diseases, and the roles of inflammation, gut microbes, probiotics, sleep disturbance and psychological factors in FGID. A founding member and past president of the ANMA, Associate Professor Dr Gwee was a member of the Rome IV committees. He is the lead author of the APAGE guidelines for the management of overlapping FGID.

FACULTY BIODATA



Anthony Hannan

Professor Dr Hannan received his undergraduate and PhD training from the University of Sydney. He was awarded a Nuffield Medical Fellowship at the University of Oxford, where he held other positions before being recruited to the Florey Institute. He is currently Research Co-Lead, Mental Health Mission, and head of Epigenetics and Neural Plasticity, at the Florey, University of Melbourne, Australia. His laboratory provided the first demonstration in any genetic animal model that environmental stimulation can be therapeutic. This has led to new insights into gene-environment interactions in various neurological and psychiatric disorders, including Huntington's disease, dementia, schizophrenia, autism, depression and anxiety disorders.



Hans Alexander Mahendran

Dr Hans Mahendran is currently the Consultant Upper GI Surgeon in Hospital Sultanah Aminah, Johor Bahru, Johor. His main interests include upper gastrointestinal cancers looking at demographics, trends, and improved treatment pathways. He is a member of the National Upper GI Training Committee, a member of the National Specialist Registry Certification Committee and the Head of Upper GI Surgical Services in Ministry of Health Malaysia. His includes the management of intestinal failure, clinical nutrition in critically malnourished patients and oesophago-gastric surgery for benign and malignant pathology.



Juanda Leo Hartono

Dr Juanda Leo Hartono is currently Senior Consultant, Director of IBD in the Division of Gastroenterology and Hepatology at the National University Hospital as well as the Assistant Professor, at the Yong Loo Lin School of Medicine, National University of Singapore.

Following his basic medical degree, Dr Juanda completed his M.Med (Universiti Malaya) in 2008 and (MRCP) (UK) in 2009. He completed his Gastroenterology specialty training at National University Hospital Singapore in 2014 followed by one-year IBD fellowship at The Royal London Hospital in UK. He previously served as Clinical Director in Division of Gastroenterology & Hepatology and is currently the lead in Inflammatory Bowel Disease service at National University Hospital Singapore. In addition, he is a core faculty in both undergraduate and postgraduate (gastroenterology specialist) education in National University of Singapore.

FACULTY BIODATA



Gerald Holtmann

Professor Dr Gerald Holtmann is Director of the Department of Gastroenterology and Hepatology at the Princess Alexandra Hospital and Director of Clinical Innovation at the University of Queensland, Australia. He also serves on the Boards of the West Moreton Hospital and Health Service and UQ Health Care, and Gastroenterological Society of Australia (GESA). In addition, he chairs the Multicultural Committee of the Rome Foundation. With approximately 350 peer reviewed PubMed listed publications he is an internationally recognized specialist in the field of Neurogastroenterology and Health Service Innovation.



Ho Shiaw Hooi

Associate Professor Dr Ho Shiaw Hooi works at Universiti Malaya Medical Centre as the Senior Consultant Physician and Gastroenterologist and the Head of the Combined Endoscopy Unit. His other portfolios include associate editor of BioMed Central Gastroenterology (journal), international advisor of Advances in Digestive Medicine (journal), councillor member of the Asia Pacific Society of Digestive Endoscopy (APSDE) and Fellow of the Japan Gastroenterological Endoscopy Society (JGES). He is also a faculty member of the Asian Novel Bio-Imaging & Intervention Group (ANBIIG) and the co-chair and board member in the Medical Working Group (MWG) of Asia-Pacific Advanced Network (APAN) which is active in organising various international teleconferences among healthcare practitioners.



Felice Jacka

Professor Dr Felice Jacka is Alfred Deakin Professor of Nutritional Psychiatry, Director of the Food & Mood Centre at Deakin University, Australia, and founder of the International Society for Nutritional Psychiatry Research. The results of the studies she has led have been cited in more than 100 policy documents globally (WHO, UNICEF) and influenced clinical guidelines in psychiatry in Australia and elsewhere. She is an ISI Highly Cited Researcher (2020-2022), putting her in the top 0.1% of publishing scientists worldwide for impact. In 2021 she was awarded a Medal of the Order of Australia (OAM) for her services to Nutritional Psychiatry.

FACULTY BIODATA



Christian Jobin

Professor Dr Christian Jobin is the Gatorade Trust Professor of Medicine at the University of Florida Gainesville, USA. He is the Co-Leader of the Cancer Therapeutics Host Response research program at the University of Florida Health Cancer Center. Professor Dr Jobin's research focuses on establishing the functional impact of microbiota in cancer development and therapeutics. He has published over 210 scientific manuscripts, many appearing in high impact journals (*Science, Nature, Nat. Comm., Nat. Micro., Nat. Cancer, Immunity, J. Clin. Invest., J. Exp. Med., Gastroenterology and Gut*) and presented his work at various national and international scientific meetings (>250 conferences). His research is supported by different NIH institutes (NCI, NIAID and NIDDK) and by the Department of Defense, USA.



Michael Kamm

Professor Dr Michael Kamm graduated in Medicine from the University of Melbourne and St Vincent's Hospital in 1978. For 22 years, he worked at St Mark's Hospital, the London specialist hospital for intestinal diseases, where he was Professor of Gastroenterology (Imperial College), Chairman of Medicine, and Director of the Inflammatory Bowel Disease and Physiology Units. In 2008, he returned to his hometown, Melbourne, to establish a clinical practice, and to take up a clinical, research and academic position at St Vincent's Hospital and University of Melbourne, Australia.

He is a recognized world leader in the field of both functional and inflammatory bowel disease (IBD) and his phenomenal research over the decades has resulted in groundbreaking changes of many conditions with a current H index of 150 (global top 1%), 6 books on inflammatory bowel disease and functional gut disorders, approximately 800 peer-reviewed original publications (including in the New England Journal of Medicine and the Lancet), 26 book chapters and 11 Leading Articles or Editorials. He is on the Editorial Board of several journals and has won numerous awards for his academic achievements.



Khairul Najmi Muhammad Nawawi

Dr Khairul Najmi is a Consultant Physician, Gastroenterologist & Hepatologist in Hospital Canselor Tuanku Muhriz, Universiti Kebangsaan Malaysia, Kuala Lumpur. He is currently the Head of Gastroenterology & Hepatology Unit and Deputy Head of Endoscopy Service Centre. His area of interest includes diagnostic & therapeutic endoscopy, luminal diseases such as inflammatory bowel disease, hepatology especially metabolic dysfunction-associated steatotic liver disease (MASLD) and gastrointestinal malignancy such as colorectal cancer. He is also a member of GUT Research Group UKM, Research Committee for Regional Academic Partnership for Intestinal Diseases (RAPID), and a member of South East Asia Gastro-Neuromotility Association (SEAGMA).

FACULTY BIODATA



Hyun-Soo Kim

Professor Dr Hyun-Soo Kim is now based at College of Medicine, Yonsei University Wonju, Korea. He is also the Chairman of the Clinical Trial Center, Wonju Severance Christian Hospital and the Auditor of Korean Association for the Study of Intestinal Diseases. Professor Dr Kim's research interest is in the population-based screening of colorectal cancers through not only clinical trials but also healthcare big data. He had led the colorectal tumor research group as a member of the Korean Association for the Study of Intestinal Diseases (KASID) and had served as the head of big data research group in both Korean Society of Gastroenterology (KSG) and a consultant of the colonoscopy pilot study as the primary screening test in Korea. Through several scientific committee chairs for KASID and KSG, he has published over 140 peer-reviewed papers with an H-index of 41 with over 5,200 citations.



Taku Kobayashi

Associate Professor Dr Taku Kobayashi is the present Director and Associate Professor at the Centre for Advanced IBD Research and Treatment, Kitasato University Kitasato Institute Hospital, Tokyo, Japan. He is Director of the International Exchange Committee of the Japanese Society of IBD and a Clinical Research Committee member for the Asian Organization for Crohn's and Colitis. He is also a committee member for the national IBD clinical guideline. He serves as a councillor for several Japanese gastroenterology societies. His main research interests lie in inflammatory bowel disease, mucosal immunology, and therapeutic endoscopy of gastrointestinal diseases.



Wolfgang Kruis

Professor Dr Wolfgang Kruis is a Professor of Medicine at the University of Cologne, Germany. He received his initial medical education in University of Munich and graduated in 1982. He subsequently continued as Research Fellow at the Mayo Clinic, Rochester, USA. He then returned and served at the Teaching Hospital University of Cologne where he was later appointed as Head of the Department of Gastroenterology, Pulmonology and General Internal Medicine there until 2018. Currently he is Member of the Faculty of Human Medicine, University of Cologne as well as Independent adviser of many international trials and the German Association of Gastroenterology Digestion and Nutrition.

FACULTY BIODATA



Jonathan Lee Wei Jie

Dr Jonathan Lee is a Clinician-Scientist at National University of Singapore Medicine, with a special interest in the field of Microbiome Medicine, as well as Consultant Gastroenterology at NUH. He completed his research fellowship (2019-2021), at the Broad Institute, MIT-Harvard, to study multi-omics integrative analysis of host-microbiome interactions in gastrointestinal disease, under Professor Ramnik Xavier. He is currently the lead for the National University Hospital's Fecal Microbiota Transplant Service. Dr Lee is a Principal Investigator at iHealthtech NUS, where his laboratory focuses on microbiome discovery and multi-omics validation. He has published extensively in top journals such as Gut, Cancer Cell, Cell Host & Microbes, Nature Communications, Genome Medicine and Theranostics. Currently his research focus are (a) using microbiome to improve detections of gastrointestinal cancers, (b) using microbiome to guide therapy and (c) studying microbiome associated with metabolic risk.




Somchai Leelakusolvong

Professor Dr Somchai Leelakusolvong is the Professor of Medicine/Gastrointestinal Division at the Department of Medicine, Siriraj Hospital, Mahidol University, Thailand.

He is one of the most awarded and honored personnel of the Faculty of Medicine Siriraj Hospital, Mahidol University, Thailand who now serves as the Director of Siriraj Gastrointestinal Endoscopy Center and the chief of Motility Unit at the centre. He is also the President of Gastrointestinal Association of Thailand and the Congress President for the upcoming APDW 2023 which will be held in Bangkok this year.

He has produced many papers which included studies on ERCP, Third space endoscopy as well as most recently the Thailand Guide for Medical Management of Gastroesophageal Reflux Disease.



Lee Yeong Yeh

Professor Dr Lee is Professor of Medicine and Consultant of Gastroenterology, Hepatology and Internal Medicine at Universiti Sains Malaysia, Kelantan, Malaysia. He has published more than 300 papers in high-impact journals including Gastroenterology and Gut. He is senior editor of journals including the Journal of the Royal College of Physicians of Edinburgh, and the Malaysian Journal of Medical Sciences. He involves actively in many leadership capacity including President of the Malaysian Society of Gastroenterology & Hepatology, Past Scientific Chair of Asia Pacific Digestive Week 2021, council member of the Asian Pacific Association of Gastroenterology, and the College of Physician, Academy of Medicine of Malaysia.

FACULTY BIODATA



Leong Chee Onn

Dr Leong has extensive experience in the field of genomics, having received several prestigious awards, including the FMD Fellowship (USA), the Institute of Biomedical Science President's Award (UK), and the Top Research Scientist Malaysia (TRSM). He was previously a Senior Research Fellow at Harvard Medical School and Massachusetts General Hospital in Boston, USA. Dr. Leong is currently a Fellow of the Institute of Biomedical Science (FIBMS, UK), Fellow of the Royal Society of Biology (FRSB, UK), and Fellow of the Royal Society of Chemistry (FRSC, UK). He served as a professor of genomics and Deputy Director of Research at the International Medical University, Malaysia. He is the founder and CEO of AGTC Genomics, a technology company that specializes in advanced genomics technology and also holds the position of adjunct professor and visiting fellow at the Broad Institute of Harvard and MIT.



Alex Leow Hwong Ruey

Dr Alex Leow is Consultant Gastroenterologist and Hepatologist in Pantai Hospital Kuala Lumpur and is Honorary Consultant Gastroenterologist and Hepatologist to Universiti Malaya Medical Centre, Kuala Lumpur, Malaysia. He previously worked as Associate Professor in the Department of Medicine at the Universiti Malaya. He is currently a member of the Asian EUS Group, Chairman of the Malaysian IBD Special Interest Group, the past Secretary General of the Organising Committee of the Asia Pacific Digestive Week 2021 and Executive Committee Member of the Malaysian Society of Gastroenterology and Hepatology since 2017.



Cosmas Rinaldi A Lesmana

Associate Professor Dr Cosmas Rinaldi A Lesmana is an Associate Professor and Senior Consultant in the Department of Internal Medicine, Hepatobiliary Division, Dr Cipto Mangunkusumo National General Hospital, Universitas Indonesia, Jakarta, Indonesia. He has won several awards for his research, where his innovation research projects have been selected for presentation during Digestive Disease Week, 2017 and 2023 in USA. Dr Lesmana is a member of several professional associations. He also has published many papers in peer-reviewed international journals and his interest includes liver cirrhosis, portal hypertension, hepatocellular carcinoma, pancreato-biliary diseases, and diagnostic as well as therapeutic endoscopy, especially endoscopic ultrasound (EUS).

FACULTY BIODATA



Jeremy Lim

Associate Professor Dr Jeremy Lim is the Co-Founder and CEO of AMiLi, the only precision gut health company in the region providing microbiome transplant, sequencing, and in vitro and in vivo analytical services in Southeast Asia.

He is a medical doctor by training with post-graduate qualification in surgery and preventative medicine. He holds a faculty position at the National University of Singapore Saw Swee Hock School of Public Health as director global health and is also an adjunct faculty in Monash Malaysia.



Luqman Mazlan

Dr Luqman Mazlan is a Consultant Colorectal & General Surgeon at Pantai Hospital Kuala Lumpur. He has a special interest in recurrent and locally invasive colorectal cancers and regularly performs complex laparoscopic colorectal surgeries and pelvic exenterations. He has multiple publications and is involved in international trials and various research in colorectal surgery and clinical nutrition.

Dr Luqman has been actively involved in holding educational workshops and courses on colorectal surgery and clinical nutrition, both locally and internationally. He is currently the President of the Malaysian Society of Colorectal Surgeons, Vice-President of the Parenteral and Enteral Nutrition Society of Malaysia and council member of the European Society of Coloproctology Global Reach Committee.



Mark Dhinesh Muthiah

Dr Muthiah's research interest is in the interplay of cardiometabolic diseases and the liver, and he has published extensively on the topic. He is also actively involved in medical education and has received numerous teaching awards. Despite his active involvement in research and education, he runs a busy clinical practice, and holds fast to the belief that excellence in medical research and education can only be borne out passion for clinical medicine.

FACULTY BIODATA



Siew-Chien Ng

Professor Dr Ng is Croucher Professor in Medical Sciences. She is Director for the Microbiota I-Center (MagIC), Assistant Dean (Development) and Professor at the Department of Medicine and Therapeutics, Faculty of Medicine, The Chinese University of Hong Kong. She is the scientific co-founder of GenieBiome Limited.

She is at the forefront of epidemiology, genetics, pathogenesis and treatment of inflammatory bowel disease in Asia Pacific and globally. She pioneered the research on the role of gut microbiota in health and disease; fecal microbiota transplantation and microbial therapeutics as well as COVID-19.

She has published over 300 papers in international journals and filed over 50 patents across the nation, US and Europe.



David Ong Eng Hui

Dr Ong is a Senior Consultant Gastroenterologist at the Mount Elizabeth Orchard Medical Centre, Singapore and the Co-Founder of AMILI, which is South-East Asia's first and only Stool bank. Dr Ong was the first doctor in Singapore to perform a faecal microbiota transplant (FMT) in 2014.

He was the Head of Gastroenterology and Hepatology at the National University Hospital (NUH) from 2017-2021 and remains a visiting senior consultant. He set up the Inflammatory bowel disease (IBD) unit at the National University Hospital (NUH) in 2012 and co-founded the Crohn's and Colitis Society of Singapore, which is a support and advocacy group for IBD patients.

Dr Ong holds an Adjunct Associate Professorship at the National University of Singapore (NUS), Department of Medicine and helped establish the International Council at the NUS Yong Loo Lin School of Medicine. Nationally, Dr Ong served as the President of the Gastroenterological Society of Singapore (GESS).

FACULTY BIODATA



Pavitratha Puspanathan

Dr Pavitratha Puspanathan is a Consultant Anatomic Pathologist currently working at Hospital Pulau Pinang, Malaysia. She completed her Masters in Pathology from UKM in 2012 and was awarded special interest in GI and HB pathology by the Ministry of Health Malaysia in 2022.

Dr Pavitra is a member of ESP, council member of IAP Malaysian Division, organising committee of Asia Pacific IAP 2023, SEA Pathology Steering Committee and part of the National IBD Preceptorship programme.

She is interested in research and teaching and has actively taken part in organising workshops as well as speaking at both local and international conferences.



Soo-Kyung Park

Associate Professor Dr Park completed her Medical degree at Hanyang University and subsequently obtained her PhD at Ulsan University, College of Medicine, Seoul, Korea in 2015. During her gastroenterology training, she has had opportunity as fellows at the Harvard Medical School, Boston, USA and John Radcliffe Hospital, Oxford, England.

Prof Park is an avid academic researcher. She has contributed to research especially in colonoscopy & Inflammatory bowel disease. She has an h index of 21, co-authored 94 publication(s) as well as receiving 1734 citation(s).

Currently she is working at the Division of Gastroenterology, Department of Internal Medicine and Inflammatory Bowel Disease Center, Kangbuk Samsung Hospital, School of Medicine, Sungkyunkwan University, Seoul, Korea.



Paul Selvindoss

Dr Paul is a laparoscopic & colorectal surgeon who has received subspecialty training in Malaysia and completed a colorectal research and clinical fellowship in USC, USA. He did his advanced laparoscopic training in both Australia and France. Dr Paul has presented on various topics in laparoscopic colorectal surgery, proctology, ERAS in colorectal surgery, and surgical pain management and laparoscopic hernia surgery. He is an invited reviewer for the Malaysian Medical Journal. His research interests include laparoscopic GI surgery, hernia surgery, single-port surgery, robotic surgery, and anorectal surgery, particularly fistula in ano.

Presently he has taken up a new role as one of the regional Vice-President for International Society of University Colon and Rectal Surgeons (ISCRUS).

FACULTY BIODATA



Sven Pettersson

Dr Pettersson is an internationally renowned investigator with a string of high-profile publications in areas of eukaryotic gene regulation and in microbe-host interactions. His work on Gut-microbe organ function, including Brain function in the last 15 years has set his international profile in this field of research. In 2021, the Jeffrey Cheah Foundation, Malaysia, awarded him a large grant to establish an ASEAN Microbiome Nutrition Centre (AMNC), jointly between the National Neuroscience Institute Singapore and Sunway University Malaysia. As the Director of this Centre, he and his team focus on gut-brain signaling pathways and their relevance to the development and progression of neurodegenerative diseases including Parkinson's Disease.



Kewin Siah

Dr Kewin Siah is the Director of the Gastro-Motility Lab and Functional Gastrointestinal Disorders Clinical Service in National University Hospital. He is actively involved in education of FGIDs locally. He is the current President of Singapore's IBS Support Group. He is also the General Secretary of the National Foundation of Digestive Disease. He also involved in FGIDs research locally and internationally. He is the Secretary-General of the Asian Neurogastroenterology & Motility Association, co-chair of APAGE's ELC FGIDs committee and actively involved in Rome's Foundation workgroup including Asian-Rome workgroup and DGBIs Overlap diseases. He is also the Asian ambassador for Rome's ROBOT project.



Siow Sze Li

Dr Siow Sze Li is the President of the College of Surgeons, Academy of Medicine of Malaysia and member of the National Conjoint Committee for General Surgery. He is the Head of Department of General Surgery and Head of Day Care Service of Sarawak General Hospital. He is also the adjunct Professor for Taylor's University School of Medicine, lecturer for Universiti Malaysia Sarawak (UNIMAS) & instructor for Care of the Critically Ill Surgical Patient (CCrISP), Royal College of Surgeons of England. He is an examiner for Intercollegiate MRCS exam and appointed external examiner for various universities.

Dr Siow is also a committee member of Society of Endoscopic Laparoscopic Surgery of Malaysia (SELSMA), Malaysian Upper GI Surgical (MUGIS) Society and Malaysian Metabolic and Bariatric Surgery Society (MyMBS).

FACULTY BIODATA



Jose D Sollano, Jr

Professor Dr Jose D Sollano, MD is Professor of Medicine and Gastroenterology of the Faculty of Medicine and Surgery of the University of Santo Tomas and Chief of Hepatology at the University Hospital in Manila, Philippines. He is also Founder and President of the Inflammatory Bowel Disease Club of the Philippines and co-organized the Crohn's & Colitis Philippines -a national IBD patient support group.

He has authored/co-authored five (5) book chapters and several original scientific articles in peer-reviewed journals and has served as faculty and/or convenor of a number of Philippine and Asia-Pacific Clinical Practice Guidelines. He is recognized with a Lifetime Achievement Award by the Philippine Society of Gastroenterology and is the recipient of the prestigious 2023 Jose P Rizal Award of the Philippine Medical Association.

Professor Dr Sollano is a Past President of the Asia Pacific Association for the Study of the Liver (APASL and the Hepatology Society of the Philippines, Philippine Society of Gastroenterology and Digestive Endoscopy, as well as, the Philippine College of Physicians.



Joseph J Y Sung

Professor Sung received his MBBS from The University of Hong Kong, PhD in biomedical sciences from the University of Calgary, and MD from The Chinese University of Hong Kong (CUHK). He holds fellowships in over 10 medical professional societies internationally including Royal Colleges of Physicians of Edinburgh, Glasgow, London, and Australia, the American College of Gastroenterology, and the American Gastroenterological Association. Published over 1000 scientific articles and authored over 30 books, he was recognised as Highly Cited Researcher from 2018-2022. Formerly as Vice-Chancellor at CUHK, he is currently the Dean at Lee Kong Chian School of Medicine, Nanyang Technological University, Singapore.

FACULTY BIODATA



Hidekazu Suzuki

Professor Dr Hidekazu Suzuki graduated from Keio University School of Medicine, Tokyo, Japan in 1989 and went on with his postgraduate course there. Following that, he continued with his as a Postdoctoral Research Fellow at the University of California at San Diego, La Jolla, California, USA. He returned back to Japan until he achieved his professorship at the Keio University School of Medicine.

Professor Dr Suzuki is currently based at Division of Gastroenterology and Hepatology, Department of Internal Medicine, Tokai University School of Medicine in Kanagawa, Japan. He is also the visiting and guest professor at the Tokyo Dental College, Peking University as well as Keio University School of Medicine. To date he holds many posts which includes the President of the Japanese Society for Microcirculation, International committee member of American Gastroenterological Association and Asian Neurogastroenterology and Motility Association (ANMA) Governing Council. He was part of Rome IV committee member and is also the current Rome V committee member.



Tan Soek Siam

Dr Tan Soek Siam is a senior consultant in the Department of Hepatology, Selayang Hospital, Malaysia. She was the head of department and head of hepatology service in MOH up until 2017. Dr Tan graduated from Trinity College, Dublin, Ireland. She did her fellowship in hepatology in the Institute of Liver Study at King's College Hospital, United Kingdom and also received training in Queen Mary Hospital, Hong Kong and University of Michigan, USA. She is a member of the Asia Pacific Association for the Study of the Liver (APASL)-ACLF working party, the APASL-ACLF Research Consortium (AARC). She has authored more than sixty publications in peer review journals, Asia Pacific regional clinical practice guidelines, a few book chapters and a reviewer for several peer review journals. She is a member of the editorial board of the journal Hepatology International. She is the Past President of the Malaysian Society of Gastroenterology and Hepatology (2017-2019) member of the College of Physicians and a fellow of the Academy of Medicine of Malaysia and a member of the Malaysian Transplant Society. She is the deputy chair and scientific co-chair (hepatology) of the Asian Pacific Digestive Week 2021.

FACULTY BIODATA



Malcolm Tan Teck Kiang

Dr Malcolm Tan graduated from the Faculty of Medicine, National University of Singapore, in 2005 with MBBS (Singapore). He attained MRCP (UK) and Master of Medicine (Singapore) in 2010. He completed specialist training in Gastroenterology and Hepatology in 2015 and was awarded with a Health Manpower Development Plan (HMDP) programme. From 2015 and 2016, he completed an Inflammatory Bowel Disease (IBD) Fellowship at the renowned John Radcliffe Hospital, Oxford University Hospital in Oxford under the mentorship of Professors Simon Travis and Satish Keshav.

Dr Malcolm Tan current post is as Senior Consultant in Gastroenterology & Hepatology and Medical Lead of the Inflammatory Bowel Disease Centre at Singapore General Hospital. He is also the Clinical Senior Lecturer, Yong Loo Lin School of Medicine and the current Chairperson of the Joint Committee on Specialist Training (Gastroenterology) Exit Examination Committee in Singapore.



Tawesak Tanwandee

Professor Dr Tawesak Tanwandee is Hepatologist at division of gastroenterology and hepatology at Faculty of Medicine Siriraj Hospital, Mahidol University, Bangkok, Thailand where he has been working for the past 30 years. His current position is Professor of Gastroenterology and Head of Division of Gastroenterology (since 2008). He is currently Steering Member and Past President of APASL as well as Past President of APASL and Thai Association for the Study of the Liver (THASL). His research interest is about treatment of chronic hepatitis B and C, hepatocellular carcinoma and cost effective of treating hepatitis B and C. He received a MD with first class honor and gold medal and received Thai Board of Internal Medicine, Gastroenterology. He also spent two years as a research fellow at the Department of Molecular Virology, Baylor College of Medicine, Houston, TX. He is currently a member of AGA, ACG, AASLD, EASL and APASL.

FACULTY BIODATA



Krzysztof Tomaszewicz

Dr Krzysztof Tomaszewicz is Head of the Department of Infectious Diseases and Hepatology in Medical University of Lublin, Poland. He is also the Vice-President of the Polish Society of Epidemiologists and Infectious Diseases. He heads many national and international research which included Leader of Swiss Contribution Project “Prophylaxis of HCV infection”. He is the current President of the Polish MAFLD Expert Group and also member and reviewer of EASL Congress. On the invitation of WHO, he provides expert review on the topic of HCV elimination. Dr Tomaszewicz is a Member of the Scientific Committee of the project “International Transfer of Health Data” by European Federation of Academies of Sciences and Humanities (ALLEA), Scientific Advisory Board of European Academies (EASAC) and Federation of European Medical Academies (FEAM). On top of that, he is also the Editor-in-Chief of “Clinical and Experimental Hepatology”.



Justin Wu Che-Yuen

Professor Dr Justin Wu is the Associate Dean (Health Systems) of Faculty of Medicine and the Chairman of The Chinese University of Hong Kong (CUHK) Medical Services. He is responsible for the development of collaborative network with private health systems, business and industry partners in Hong Kong, Greater Bay Area and beyond. He graduated from CUHK with Distinction in Medicine in 1993. He underwent internal medicine and gastroenterology training under the supervision of Professor Dr Joseph Sung. He pursued GI motility training in Royal Adelaide Hospital under the supervision of Professor Dr John Dent and Professor Dr Richard Holloway in 2000.

Professor Dr Wu joined CUHK as an associate professor in 2006 and was then promoted to professor in 2009. He has academic and clinical focus in the field of functional gastrointestinal disorder and gastroesophageal reflux disease with over 300 publications in top medical journals including New England Journal of Medicine, Lancet and Gastroenterology and a h-index of 50. He is a member of the Working Group of Chicago Classification for esophageal motility disorders. He is serving as leader in many local and international professional organizations, which include the President of Asian Pacific Association of Gastroenterology, Past President of Hong Kong Society of Gastroenterology, President of APDW 2017, and Scientific Committee Chairman of Asia Neurogastroenterology and Motility Association. He served as the managing director of Journal of Gastroenterology and Hepatology, and International Associate Editor of American Journal of Gastroenterology.

FACULTY BIODATA



Chun-Ying Wu

Professor Dr Wu received his M.D. degree from National Taiwan University (NTU) in 1991, M.P.H. degree from Harvard School of Public Health in 1993, Ph.D. degree from NTU in 2007, and LL.M. degree from Harvard Law School in 2003. He has been positioned as the Chair Professor and Associate Dean of the College of Medicine and Director of Biomedical Informatics, at Taiwan National Yang Ming Chiao Tung University; Director of Taiwan National Microbiota Research Collaboration Core Facility; Chief of the Division of Translational Research, and Professor of Gastroenterology and Hepatology at Taipei Veterans General Hospital.



Howard Yim Chi Ho

Dr Yim completed his PhD at The University of Hong Kong in 2010 and gained postdoctoral training at Monash University. In 2017, he and Professor Dr Emad El-Omar established the first Australian Microbiome Research Centre at University of New South Wales where he leads the cancer research theme.

Over half of Yim's publications are in the top 5% journals. He served as a reviewer for >15 journals and >4 funding bodies, a Topic Editor for *Frontiers in Medicine* and a Specialist Advisor for the Therapeutic Goods Administration, Australian Government. He was an NHMRC Early Career Fellowship recipient and filed 1 patent.



Amany Zekry

Professor Dr Amany Zekry is Head of Gastroenterology and Hepatology at St George Hospital, University of New South Wales (UNSW), Australia. She has an active clinical and basic research agenda and leads the microbiome liver cancer research group at the microbiome research centre, UNSW. At the forefront of this initiative is the exploration of the intricate interplay between the gut microbiome and the immune response within the context of liver cancer. Her work has been published in several high impact journals. Her research is supported by notable institutions, including the National Health and Medical Research Council (NHMRC) and the Cancer Institute.

EPIDEMIOLOGY AND IMPACT OF OVERLAP OF GUT-BRAIN DISORDERS

Gerald Holtmann

University of Queensland, Brisbane, Australia

Disorders of Gut-Brain Interaction (DGBIs), are a range of different conditions that involve chronic or recurring symptoms related to the digestive system without any evidence of structural abnormalities. These disorders include conditions such as irritable bowel syndrome (IBS), functional dyspepsia (FD), and functional constipation, and they are increasingly recognized as a significant issue for public health due to their prevalence and impact on people's quality of life. Epidemiological data shows that these disorders are highly prevalent worldwide, affecting around 10-20% of the general population. They are more common in females and often start during adolescence or early adulthood. The overlap of DGBIs is frequently observed in population-based studies, but it is found to be more common in individuals seeking medical attention or are referred to specialists. Interestingly, patients with overlapping disorders tend to have more severe symptoms and/or psychological comorbidities. Understanding and recognizing the epidemiology and pathophysiology of the overlap of DGBIs is crucial for healthcare providers and researchers. While the current Rome criteria aim to identify specific patterns of symptoms (and therefore specific underlying mechanisms), the existence of overlap suggests that there are common factors that lead to the simultaneous manifestation of different types of DGBIs.

Keywords: Disorders of Gut Brain Interaction, Treatment, Overlap

REFERENCE

Fairlie T, Shah A, Talley NJ, Chey WD, Koloski N, Yeh Lee Y, Gwee KA, Jones MP, Holtmann G. Overlap of disorders of gut-brain interaction: a systematic review and meta-analysis. *Lancet Gastroenterol Hepatol.* 2023 Jul;**8**(7):646-659

PATHOPHYSIOLOGY OF OVERLAP GUT-BRAIN DISORDERS

Kok-Ann Gwee

Gleneagles Hospital, Singapore

Contemporary systems for the diagnosis and management of FGIDs seek to categorize patients into narrowly defined symptom-based sub-classes to enable targeted treatment of putative pathophysiology. Overlap of symptom categories occurs frequently in real world clinical practice, and has a negative impact on treatment outcomes. Investigation of the pathophysiology is limited. An expert panel under the auspices of APAGE has proposed a number of putative pathophysiology to guide selection of treatments. Broadly these comprise (i) fundamental pathophysiology, (ii) multiple pathophysiology, and (iii) symptom misinterpretation. Pathophysiology (eg psychology, gut microbiota, genetics) that transcends clusters will be assumed. Specifically for the FD-IBS overlap syndrome possible pathophysiology includes referred visceral sensations, the gastrocolic reflex, duodenal dysfunction, impaired gas transit in the small intestine, food intolerance, small intestinal bacterial overgrowth.

Keywords: Pathophysiology, Overlap, Gut-Brain

Gwee KA, Lee YY, Suzuki H, Ghoshal UC, Holtmann G, et al, Asia-Pacific guidelines for managing functional dyspepsia overlapping with other gastrointestinal symptoms. J Gastroenterol Hepatol. 2023;197-209

MANIPULATION OF GUT MICROBIOTA USING PROBIOTICS IN MANAGEMENT OF IRRITABLE BOWEL SYNDROME

Uday Chand Ghoshal

Sanjay Gandhi Postgraduate Institute of Medical Sciences, Lucknow, India

In contrast to the earlier belief, it is now being recognized that the overlap between different disorders of gut-brain interaction (DGBI) is rule rather than an exception. In fact, several studies showed that more than half of the patients with DGBI have overlap disorders rather than a single disorder. Overlap DGBI patients usually have greater symptom severity, more psychological comorbidity, poorer quality of life, inadequate treatment response and worse prognosis than those with single disorder. Hence, special attention is needed to treat these patients. However, therapeutic trials to prove efficacy of different treatment options for overlap DGBI are scanty. Currently, most of us practice treating the patients with overlap disorders with combination pharmacotherapy in addition to different non-pharmacological treatment.

SYMPOSIUM 1 - Overlap Gut-Brain Disorders

**INTERACTIVE CASE-BASED DISCUSSION
CASE 1 - FD-CONSTIPATION**

Kewin Siah

National University of Singapore, Singapore

We will be presenting case studies that illustrates the importance and relevance of overlap diseases in clinical practice.

SYMPOSIUM 1 - Overlap Gut-Brain Disorders

**INTERACTIVE CASE-BASED DISCUSSION
CASE 2 - FD-GERD**

Khairul Najmi

Hospital Canselor Tuanku Muhriz, Universiti Kebangsaan Malaysia, Kuala Lumpur, Malaysia

An interactive case discussion, exploring on the step-wise approach and management of the FD-GERD overlap.

Keywords: Case discussion, FD-GERD, overlap gut-brain disorders

NAFLD, MAFLD, MASLD & FATTY LIVER: WHAT IS THE DEBATE ALL ABOUT?

Jose D Sollano, Jr

University of Santo Tomas, Manila, Philippines

In 1980, Ludwig described nonalcoholic steatohepatitis as a poorly understood and hitherto unnamed liver disease of unknown etiology that histologically mimics alcoholic hepatitis, can progress to cirrhosis and seen in patients with obesity-associated diseases, i.e., diabetes and cholelithiasis. Today, NAFLD is perceived as an inconsequential hepatic manifestation of the metabolic syndrome afflicting approximately 25–30% of the global population. Although some patients will develop progressive liver disease that can lead to cirrhosis and liver cancer, data show that cardiovascular disease is the main cause of mortality in patients with NAFLD (followed by non-liver related malignancies, as well as, hepatocellular carcinoma). A new nomenclature, i.e., metabolic dysfunction-associated fatty liver disease (MAFLD) was suggested in 2020 to refer to fatty liver disease related to systemic metabolic dysregulation. It was argued that the name change from nonalcoholic fatty liver disease NAFLD to MAFLD corrects the exclusionary nature of the NAFLD definition and brought with it a simple set of criteria to enable easy office/bedside diagnosis both for the general medical community, including PCPs and pediatricians. MAFLD has a concise diagnostic criterion, removed the requirement to exclude other concomitant liver diseases and reduced the stigma associated with alcohol and obesity. Accumulated data indicate that MAFLD better correlates with noninvasive markers of fatty infiltration, as well as, a worse liver fibrosis stage. MAFLD can also identify better the high-risk groups for all-cause and cardiovascular-related mortality. In June 2023, the AASLD, EASL and ALEH assembled a multi-sectoral consensus development task force and introduced a newer nomenclature, i.e., metabolic dysfunction associated steatotic liver disease (MASLD) indicating that this overarching term includes an affirmative set of diagnostic criteria selected to align with cardiometabolic risk factors already well established and validated in other metabolic disorders. A vigorous and animated debate has ensued since the formal publication of the article. Data gathered from studies done today going forward will help clarify the competing yet overlapping issues brought about by another change in name -in rapid succession.

A holistic, all-of-society approach is necessary in combating this largely lifestyle-driven disease in our increasingly industrialized planet.

Keywords: NAFLD, MAFLD, MASLD

NEW HORIZON IN ULCERATIVE COLITIS TREATMENT: THE ROLE OF TOFACITINIB

Taku Kobayashi

Kitasato University Kitasato Institute Hospital, Tokyo, Japan

The treatment landscape of Ulcerative Colitis (UC) is witnessing exciting advancements, and this presentation highlights one such breakthrough - the recently approved JAK inhibitor, tofacitinib, in Malaysia. With Professor Taku's experience in using tofacitinib for UC patients since its approval in Japan in 2018, this topic will embark on a journey through the latest management strategies in UC. Delving deeper, the talk explores tofacitinib's clinical trial programs and real-world experiences, providing valuable insights into its effectiveness and safety profile, practical considerations for tofacitinib therapy in addressing critical aspects of initiating and monitoring.

To enrich the learning experience, the presentation will feature compelling case studies, showcasing the real-world impact of tofacitinib in UC management. Enriched with relevant case studies, this talk offers a compelling glimpse into the role of tofacitinib in transforming UC treatment. Don't miss this opportunity to discover new possibilities for enhanced patient care.

Keywords: Ulcerative Colitis, Tofacitinib, JAK inhibitor

LECTURE 2 - RECENT ADVANCES IN THE MANAGEMENT OF HEMORRHOIDAL DISEASE

Paul Selvindoss

Glencagles Ampang, Kuala Lumpur, Malaysia

Hemorrhoids are a common anorectal condition that affects up to 50% of adults at some point in their lives. The treatment of hemorrhoids depends on the severity of the symptoms. Mild hemorrhoids can often be managed with conservative measures, such as increasing fiber intake, drinking plenty of fluids, and taking over-the pain reliever and **micronized purified flavinoids**.

The latest research in the management of hemorrhoids is focused on developing new **minimally invasive** procedures that are even more effective and less invasive than the procedures that are currently available.

These include laser Hemorrhoido Plasty LHP, Doppler-Guided Hemorrhoidal Artery Ligation (DG-HAL). Stapled Hemorrhoidopexy (PPH).

Harmonic and ligasure hemorrhoidectomy has also gained popularity in recent years compared to the conventional Milligan-Morgan or Ferguson's procedure.

The introduction **TONE** has also been able to reduce the number of patient who need surgical intervention.

When surgical intervention was need a recent paper has shown. **"No pain no gain"**.

REFRACTORY GERD: CLINICAL SIGNIFICANCE AND TREATMENT OPTIONS

Somchai Leelakusolvong

Siriraj Hospital, Mahidol University, Thailand

The definition of refractory gastroesophageal reflux disease (GERD) remains controversy. Refractory GERD is a condition that a GERD patient who still having reflux symptoms or endoscopic evidence of esophagitis with partial response to the given medications, most of them is proton pump inhibitor (PPI).

The causes of refractory GERD are mainly from two contributing factors. First factor is failure of PPIs. The other factor is the causes of reflux symptoms. Further investigations beyond upper endoscopy such as pH-impedance testing will reveal more physiologic details for explaining the patient's symptoms.

Treatment options in refractory GERD should be considered as following options; conversion to a different/more potent acid suppressive regimen, potassium competitive acid blocker, H₂ receptor antagonist, bile salt binders, transient lower esophageal sphincter relaxation reducers, promotility agents, and mucosal protectants such as alginate. Finally, pain modulators such as tricyclic antidepressant or selective serotonin reuptake inhibitor agents would be benefit in this group especially for functional heartburn and reflux hypersensitive patients. The non-pharmacological management for refractory GERD including Linx system, endoscopic management and surgery. In addition, physician should consider a variety of therapeutic modalities depend on postulated mechanism of the residual symptoms.

Keywords: Gastroesophageal reflux disease, proton pump inhibitor (PPI), treatment

SYMPOSIUM 2 - Conundrums in Approach & Management of GERD

APPROACH TO OVERLAPPING DISORDERS IN GERD

Hidekazu Suzuki

Tokai University School of Medicine, Isehara, Kanagawa, Japan

GERD is a syndrome caused by reflux of acid-containing stomach contents into the esophagus. Because of the high impact of acid reflux, most GERD treatments are resolved with acid-suppressing drugs, PPIs or PCABs. However, it is also true that there is a patient population called PPI- or PCAB-resistant GERD. Based on heartburn and acid regurgitation, which are characteristic symptoms of GERD, functional heartburn and functional dyspepsia (FD) may be included as GERD. On the other hand, it is highly possible that part of the FD-GERD overlap syndrome, in which FD and GERD overlap, is a disease cluster responsible for part of PPI- or PCB-resistant GERD. We, the APAGE working group, have established the concept of FD that overlap with other FGIDs (J Gastroenterol Hepatol. 38:197-209, 2023), and one of these disease clusters is GERD that overlaps with FD (FD-GERD) has also been discussed about its epidemiology, pathogenesis, and treatment. We are currently developing clinical practice guidelines for the FD-GERD overlap. In this presentation, I would like to talk about the current state of this FD-GERD overlap cluster syndrome.

SYMPOSIUM 2 - Conundrums in Approach & Management of GERD

LAPAROSCOPIC FUNDOPLICATION FOR GERD: THE WHO, WHAT AND HOW

Siow Sze Li

Sarawak General Hospital, Sarawak, Malaysia

Laparoscopic fundoplication is the gold standard for surgical treatment of severe gastroesophageal reflux disease (GERD). It has successfully cure GERD in 85-93% of the time and has a high satisfaction rate in >90% of patients who underwent the procedure. In a recent systematic review and meta-analysis of randomised clinical trials, fundoplication has been shown to be a more effective therapy than proton pump inhibitor for treatment of GERD, without the significant risk of adverse events. However, before performing the surgery, it is extremely important to assess and select the patients who would benefit from the surgery to ensure better results.

MESALAZINE GRANULES FOR IBD, AN OLD DRUG IN NEW SPLENDOR

Wolfgang Kruis

University of Cologne, Germany

The history of 5-aminosalicylic acid (5-ASA) the ingredient of mesalazine (MES) covers a wide time period starting with studies in the 30ies of the last century up to today. Why is MES still among the most frequently prescribed drugs for IBD? Firstly, the mode of action encompasses a plethora of proven therapeutic activities such as antiinflammatory effects against leukotriens, oxygen radicals, immunologic proinflammatory factors and others. Current research results focus on interactions with pathogenic intestinal microbiota.

Pharmacology of MES has shifted from simple eudragit coated formulations to sophisticated constructions with multifunctional mechanisms such as dual-release granules, warranting targeted delivery of 5-ASA to the inflamed sites of the intestines.

Recent trials have solved the question of appropriate dosing.

Actual research has demonstrated the effectivity of 5-ASA on modern treatment endpoints such as mucosal healing and even disease clearance (symptom and mucosal as well as histologic remission).

Clinical effects of MES in IBD are explained by a long list of known study results which are actually still expanded by additional ongoing work. MES is not only a traditional but also a very up to date drug.

Keywords: IBD, Mesalazine, Disease Clearance

MOVING TOWARD REMISSION: LONG TERM TREATMENT AND REAL-WORLD EFFECTIVENESS OF USTEKINUMAB IN IBD

Malcolm Tan Teck Kiang

Singapore General Hospital, Singapore

Ustekinumab is a monoclonal antibody that targets interleukin-12/23, and is approved for the treatment of moderate to severe ulcerative colitis (UC) and Crohn's disease (CD). This review summarizes the long-term treatment and real-world effectiveness of ustekinumab in IBD.

Several studies have shown that ustekinumab is effective in inducing and maintaining remission in UC and CD. In a 12-month study, 45% of patients with UC achieved clinical remission with ustekinumab, and 33% of patients with CD achieved endoscopic remission. In a real-world study of patients with UC, 58.2% of patients had endoscopic improvement at month 12 with ustekinumab.

Ustekinumab is generally well-tolerated, with the most common adverse events being upper respiratory tract infections, headache, and rash. Serious adverse events are rare.

Overall, the data suggest that ustekinumab is an effective and safe treatment for IBD, with long-term effectiveness in real-world settings.

Keywords: Inflammatory Bowel Disease, Ustekinumab, Effectiveness

COMMON ERRORS IN THE DIAGNOSIS OF IBD AND HOW TO AVOID THEM

Siew-Chien Ng

The Chinese University of Hong Kong, Hong Kong

There is no single, gold standard diagnostic test for inflammatory bowel disease (IBD) and several other diseases can be misdiagnosed as IBD. There is a broad differential diagnosis including non-infectious etiologies such as autoimmune disorders, vasculidities, ischemia, diverticular disease, drugs, cancer, and radiation-induced disease. Colonic infections besides *Salmonella* include *Shigella*, *Clostridioides difficile* (*C. diff*), *Eschericia coli* (*E. coli*), *Campylobacter*, *Aeromonas* and the protozoan *Entamoeba histolytica*. Other infectious mimics include *Mycobacterium tuberculosis* (“the great mimic”) may coexist with IBD or mimic Crohn’s disease entirely. The diagnosis of IBD can be difficult to establish given its non-specific clinical symptoms and varying endoscopic and histologic findings. In this talk, I will discuss the clinical symptoms, pathologic features, and differential diagnosis of IBD. I will also focus on non-infectious and infectious mimics of IBD and discuss distinguishing features of each of these distinct disorders, using various live cases for demonstration.

Keywords: Infectious, IBD, diagnosis

MIMICS OF IBD HISTOLOGICAL PERSPECTIVES

Pavitratha Puspanathan

Hospital Pulau Pinang, Penang, Malaysia

It is common place to for bowel segment biopsies or resection specimens from patients suspected to have Chronic Inflammatory Bowel Disease (IBD) to be sent for histopathological assessment. Pathologist and clinicians must be aware of common histological mimics that can be encountered in these specimens in daily practise. The main differentials include infections and non-infectious causes. Common infections include tuberculosis, amoebiasis and fungal infections. Drug-induced colitis, Segmental Colitis associated with Diverticulosis (SCAD), ischaemic colitis and auto-immune conditions can be seen as non-infectious mimics of IBD. Clinical, endoscopic and histological correlation is crucial in diagnosis these conditions.

Keywords: Inflammatory bowel disease; Mimics; infections

MIMICS OF IBD CLINICAL PERSPECTIVES

Soo-Kyung Park

Kangbuk Samsung Hospital, School of Medicine, Sungkyunkwan University, Seoul, Korea

The diagnosis of inflammatory bowel disease (IBD) relies on a combination of clinical, radiological, endoscopic, and histopathological findings. However, there are several conditions that can mimic the clinical presentation of IBD, posing a diagnostic challenge to clinicians. This lecture provides an overview of the mimics of IBD from a clinical perspective and emphasizes the importance of accurate diagnosis. We discuss common mimics such as irritable bowel syndrome, infectious enteritis, Microscopic colitis, Behçet's disease, Intestinal tuberculosis and Drug-induced enteritis, highlighting their clinical features, diagnostic approaches, and potential pitfalls.

It is crucial to differentiate these conditions from IBD because their underlying causes, management approaches, and treatment strategies may vary significantly. A thorough evaluation by healthcare professionals, including medical history, physical examination, laboratory tests, endoscopic evaluation, and imaging studies, is necessary to establish an accurate diagnosis and provide appropriate care.

By enhancing the understanding of these IBD mimics and their distinguishing features, clinicians can improve diagnostic accuracy, reduce unnecessary investigations, and provide appropriate treatment strategies to patients with similar clinical presentations to IBD.

Keywords: Inflammatory bowel disease, clinical symptoms, diagnosis

IS IT TIME TO BID ADIEU TO SEROLOGY IN THE DIAGNOSIS OF IBD?

Juanda Leo Hartono

National University of Singapore, Singapore

Evaluation of serum antibodies in IBD was thought to provide value in clinical care. Anti-Saccharomyces cerevisiae antibody (ASCA) and atypical perinuclear antineutrophil cytoplasmic antibody (pANCA) were more prevalent in IBD but were not accurate enough on its own to diagnose IBD. Combining these two tests together was found to be of some utility in differentiating Ulcerative (UC) from Crohn's Disease (CD). The discovery of additional serologies have led to 'serology panel' by combining various circulating antibodies. Although this panel showed some improvement in accuracy, it is not enough to be routinely used in clinical practice.

Beyond diagnosing and phenotyping of disease, the use of serology had been evaluated for predicting disease course, disease relapse, post operative recurrence, and treatment response, as well as determining mucosal healing. In clinical practice, although the non-invasiveness nature of serology is attractive, the patient's available clinical, laboratory, endoscopy, radiology, and histology information is usually adequate in clinical decision making for the majority of patients. Combination of serology with other factors (clinical, endoscopy, genetics, biomarkers, etc) as part of scoring system may improve its utility in clinical practice.

Keywords: Serology, biomarker, Inflammatory Bowel Disease

GUT MICROBIOTA IN HEALTH: EARLY LIFE & AGEING

Emad El-Omar

St George Hospital, Sydney, Australia

The gut microbiota is a critical biomass with profound effects human health. Loss of microbial diversity and dysbiosis are characteristic of many diseases and these associations are fast being mechanistically confirmed and validated. Dysbiosis represents an abnormal state that predisposes to a variety of diseases by maximizing the harmful effect of pathobionts and the loss of beneficial effects of symbionts. The consequences of this dysbiosis include disruption of mucosal barrier function (hyperpermeability), translocation of micro-organisms and their products and initiation of a state of low-grade chronic inflammation. Seminal microbiome papers have been published touching on many aspects of human health, including the microbiome of early life, the maternal microbiome as predictor of adverse pregnancy outcomes, and the transfer of the microbiome from mother to child. Such work will have a profound impact on our understanding of the origins of disease in humans and will translate into trials of preemptive manipulation of the microbiome to improve health outcomes. On the other end of the age spectrum, our understanding of the microbiome of healthy and unhealthy ageing is providing invaluable information on many cognitive, neurological and cardio-metabolic conditions. The next decade promises to be the decade of “microbiome medicine”. Be prepared!

Keywords: Microbiome; Inflammation; Dysbiosis

DIET & THE ENVIRONMENT

Michael Kamm

University of Melbourne, Australia

Factors shaping the gut microbiota include diet, other ingested substances, host genetic factors, geographical location, “cleanliness” when growing up, and travel.

Dietary influence on the gut microbiota starts with the maternal diet before birth, is of great importance in the first three or four years of life, but continues to be important throughout life.

Recent interest has focussed on additives that are part of ultra-processed food, including preservatives, emulsifiers, sweeteners, colourants, and anti-oxidants. General health, life expectancy, and the incidence of a range of diseases all correlate with the degree of consumption of ultra-processed foods. These foods cause disease by changing the microbiota, often towards a more inflammatory state, rather than through direct toxic chemical effects on the gut. Emulsifiers, in particular, have been shown to facilitate the growth of pathobiont pro-inflammatory organisms, and diminish the growth of protective anti-inflammatory organisms.

Other ingested substances also change the gut microbiota, although their role in disease pathogenesis is less clearly established. These include certain natural foods, yeasts, toothpaste (titanium dioxide nanoparticles), plastics (microparticles), medications and supplements.

Antibiotics also have a profound effect on the microbiota, with childhood consumption leading to an increased risk of a range of inflammatory disorders throughout life.

Keywords: Microbiota, food additives

MAKING SENSE OF METAGENOMICS

Howard Yim Chi Ho

The University of New South Wales, Australia

Metagenomics studies genetic materials extracted from microbial communities, or microbiota, residing within diverse ecosystems like the human gut. Over decades, the rapid advancements in DNA sequencing, the establishment of reference gene catalogues and bioinformatics enable the metagenome-wide association studies of various human diseases such as inflammatory bowel disease, hepatocellular carcinoma, neurodegenerative diseases, and colorectal cancer. This yields vast data, creating unique challenges and opportunities.

In this seminar, we will gain insight into the general methodologies employed in metagenomic analyses. Using several diseases as examples, we will delve into the establishment of associations between changes in microbiota profiles and disease outcomes. We will also discuss the technical challenges encountered while navigating the vast expanse of metagenomic data. We will further explore the validation process both in vivo and in vitro. The presentation will extend to elucidate how these studies have yielded the development of novel diagnostic markers, enhancing the precision and sensitivity of current diagnostic tools. Finally, we will discuss how these studies have identified beneficial microbes which can be developed into probiotics for preventing and treating these diseases. Taken together, this seminar will provide you with a step-by-step guidance to help you make sense of metagenomics.

Keywords: Microbiome; Diagnostics; Probiotics

MAKING SENSE OF METABOLOMICS

Chong Chun Wie

Monash University Malaysia, Selangor, Malaysia

The study of small molecule metabolites in a biological system, such as blood, urine and saliva is generally known as metabolomics. These metabolites are the end products of various cellular processes, and their composition and levels can provide valuable insights into an organism's physiological and biochemical status. The primary goal of metabolomics is to gain a deeper understanding of the metabolic pathways and networks that underlie various biological processes and to identify biomarkers that can serve as indicators of health, disease, or therapeutic response. Host metabolic profiles are highly related to the microbial composition in the gut. Combining microbiome data with metabolomics allows researchers to gain functional insights into the microbiome's role in various physiological processes. In this talk, I will discuss how the combination of microbiome and metabolome is helpful in understanding the interaction between biological components in maintaining overall system functionality.

Keywords: Microbiome, Metabolomics, Systems Biology

NAVIGATING THE COMPLEX TREATMENT ALGORITHM OF HCC

Cosmas Rinaldi A Lesmana

Dr. Cipto Mangunkusumo National General Hospital, Universitas Indonesia, Jakarta, Indonesia

Hepatocellular carcinoma (HCC) is still a major problem across the world. The big issue in clinical practice that, most of HCC patients come at the late stage.

In the HCC management, loco-regional therapy is considered as the main player to control the disease, however, the cancer cells behaviour is sometimes not easy to be predicted. The aetiology of liver disease, tumour size, presence of tumour thrombus, liver satellite nodules, and metastasis have made more difficult to decide the best treatment strategy or which is the best first approach of treatment should be started. Another issue in clinical practice is HCC patients with portal hypertension complications due to advance chronic liver disease or liver cirrhosis.

In the development of systemic therapy, there have been a failure to control the disease for prolonged survival. Combination treatment strategy has been considered as the best option to control the cancer cells behaviour, however, the side effects, quality of life, and the cost issue are still becoming a big barrier.

Currently, there are two options for systemic therapy, such as oral treatment (Lenvatinib), and immunotherapy. Based on newer recommendation, the up to 7 criteria has been considered as the best solution treatment.

SYMPOSIUM 4 - Hepatocellular Carcinoma (Liver Multidisciplinary-Themed Symposium)

REVOLUTIONIZING HCC SURVEILLANCE: THE ROLE OF INNOVATIVE BIOMARKERS IN EARLY DETECTION AND DIAGNOSIS

Tawesak Tawandee

Siriraj Hospital, Mahidol University, Bangkok, Thailand

Hepatocellular carcinoma (HCC) is the most common primary liver cancer in the Asia Pacific region, and it is among one of the most common cancers in this region. HCC usually presents late when the patients are symptomatic, where there are limited choices of treatment. As a result, 5-year survival was extremely low, about 10-20%. The only way to improve survival is surveillance of people who are at-risk of developing HCC and HCC is one of situations where we have well-defined at-risk population of patients. Current international guidelines of HCC surveillance include ultrasound with or without alpha-fetoprotein (AFP) but sensitivity to detect early HCC was 45-63% and require both blood test and radiologists that subject to variation and long wait time. New biomarkers such as PIVKA-II, AFP-L3 are being used more frequently which can be more practical for HCC surveillance. Use of PIVKA-II can pick up early-stage HCC to almost 80%, when combined with AFP, Age and gender called GAAD score, the sensitivity will increase to about 90% for all HCC etiologies. Implementation of these biomarkers and GAAD score can change the way of HCC surveillance.

SYMPOSIUM 4 - Hepatocellular Carcinoma (Liver Multidisciplinary-Themed Symposium)

LIVER TRANSPLANT IN HCC - DDLT VS LDLT SETTINGS. MSGH-MST JOINT SOCIETIES LECTURESHIP

Mark Dhinesh Muthiah

National University of Singapore, Singapore

Liver transplantation is a key therapeutic option for patients with hepatocellular carcinoma (HCC), offering a chance of cure and improved survival rates. Two primary sources of donor organs, deceased donors and living donors, present distinct approaches to liver transplant, each with its advantages and challenges. This talk seeks to provide a comparison between deceased donor grafts and living donor grafts for HCC, shedding light on the respective benefits, limitations, and implications for patient outcomes.

Keywords: Liver Transplant, Liver Cancer, Living Donor Liver Transplant

GUT MICROBIOME AND HEPATOCELLULAR CARCINOMA

Amany Zekry

St George Hospital, University of New South Wales, Australia

Hepatocellular carcinoma (HCC), a significant global health problem has recently been associated with the gut microbiota. Emerging research has highlighted the potential for gut-driven responses to modulate various immune pathways relevant to HCC initiation. The impact of specific bacterial strains or gut microbiota-related metabolites, such as bile acids and short-chain fatty acids, has garnered attention in both human and animal studies.

Insight into the mechanistic links between dysbiosis and inflammation is gradually unfolding. It is posited that during dysbiosis, an imbalance between commensal and pro-inflammatory bacteria may lead to an increase in bacterial ligands and enterotoxins, setting off an inflammatory cascade in the gut. This leads to heightened intestinal permeability, facilitating the movement of microbial components like lipopolysaccharide (LPS) from the gut to the liver. This process activates immune cells through toll-like receptor 4 (TLR4) and downstream nuclear factor kappa B (NF- κ B) pathways, culminating in the production of pro-inflammatory cytokines. This phenomenon is underscored by studies correlating elevated serum LPS levels with advancing liver damage and the development of HCC. Compounds and metabolites derived from the gut microbiota can access the liver via the portal circulation, influencing the tumour microenvironment. For example, perturbed bile acid metabolism, largely attributed to shifts in gut microbiota composition, engenders an immune-suppressive milieu, thus fostering tumour cell growth and survival. Similarly, short-chain fatty acids modulate immune responses intersecting tumour immune responses. These insights cast microbiome-related responses as potentially therapeutic, diagnostic, and prognostic entities capable of shaping the trajectory of HCC. The ongoing surge of research in this domain holds promise for unravelling the intricate tapestry of microbiome-HCC interactions, paving the way for a future of enhanced comprehension and clinical interventions.

SYMPOSIUM B - Gut Microbiota and GI Cancers

COLORECTAL CANCER

Joseph J Y Sung

Nanyang Technological University, Singapore

Besides genomic factors, recent studies have shown that lifestyle and environmental factors affects our gut microbiome contributed significantly to development of colorectal cancer. *Fusobacterium nucleatum*, genotoxic *E. coli* and Enterotoxigenic *Bacteroides fragilis* (ETBF) are among the microbial organisms found to be responsible for cellular proliferation, immune alteration and drive the development of GI cancers including colorectal cancer. These organisms are often found in the oral cavity and the causal relationship is still under investigation. Low fibre diet and obesity may change the gut microbiome increasing the risk of developing colorectal cancer. There are potentials of using microbiome biomarkers for the early detection of colorectal cancer enhancing the sensitivity of FIT. There are also studies showing that by manipulating gut microbiome, chemotherapy and immunotherapy effects can be enhanced.

SYMPOSIUM B - Gut Microbiota and GI Cancers

PANCREATIC CANCER

Christian Jobin

University of Florida, United States

Pancreatic ductal adenocarcinoma (PDAC) is the 3rd leading cause of cancer death in the United States and is predicted to overtake colorectal cancer as the 2nd leading cause as early as 2030. In this lecture, I will discuss the role of the intestinal bacteriome in the development of PDAC. I will present evidence that although the pancreas is populated by bacteria, the intestinal bacteriome is the major site modulating PDAC development. I will show that the bacteriome mediates anti-tumor natural killer (NK) cell function in PDAC. The PDAC xenografts of both Rag1^{-/-} and C57Bl/6 mice, whose intestinal microbiota were depleted with broad-spectrum antibiotics (Abx) or born in germ-free (GF) conditions, were smaller and had increased intratumoral NK cells. Antibody-mediated depletion of NK cells in vivo abrogated this phenotype. Furthermore, treatment of NK cells in vitro with cell-free supernatant from stool isolated from the microbiota-depleted or germ-free mice demonstrated activation of anti-tumor NK cell phenotypes, including IFN- γ production and migration/invasion. A screen of immunoregulatory bacteria identified *Enterococcus Hirae* as an inducer of NK cell antitumor activity. Wild-type mice colonized with *Enterococcus Hirae* showed reduced tumor growth and increased tumor-infiltrated IFN- γ + NK cells compared to control mice gavaged with media. These data suggest that the intestinal bacteriome can modulate NK cell anti-tumor efficacy and thus could serve as a therapeutic target.

LECTURE 2: DIAGNOSIS AND TREATMENT OF *Helicobacter pylori* INFECTION - UPDATES ON THE LATEST MALAYSIAN CONSENSUS REPORT

Alex Leow Hwong Ruey

Pantai Hospital Kuala Lumpur, Kuala Lumpur, Malaysia

Helicobacter pylori accounts for 90% of duodenal ulcers and 70-90% of gastric ulcers. Many misconceptions regarding the appropriate diagnostic method and treatment strategies still exist in the Malaysian clinical practice. Under the initiative of the steering committee, an expert panel consisting of nine key opinion leaders in the field of gastroenterology convened to develop a set of consensus statements that are relevant to the Malaysian healthcare practice. The panel members reviewed the current evidence on the management of *H. pylori* infection, focusing on the best practices that are relevant to the Malaysian population based on clinical experience and published clinical evidence. Using the modified Delphi method, the panel achieved consensus in three areas of *H. pylori* infection management: indications for testing, diagnosis, and treatment. The panel proposed a set of 19 consensus statements, which were synthesized via two rounds of blinded voting and group discussions. The recommendations provided are relevant to the Malaysian population and can be used as a guide by physicians across various healthcare settings to facilitate appropriate diagnostic testing and treatment of *H. pylori* infection.

Keywords: diagnosis, *Helicobacter pylori* infection, Malaysian consensus

Goh KL, et. al. *JGH Open*. 2023 Mar 27;7(4):261-271

DEFINITION, WHO AND HOW SHOULD ONE BE TESTED?

Lee Yeong Yeh

Universiti Sains Malaysia, Kubang Kerian, Kelantan, Malaysia

Disorders of esophageal-gastric junction (EGJ) outflow, including achalasia and EGJ outflow obstruction, are motility disorders characterized by inadequate relaxation of lower esophageal sphincter (LES) with or without impaired esophageal peristalsis. A Malaysian joint societies (MSGH and MUGIS) taskforce has developed a consensus on disorders of EGJ outflow based on the latest evidence, while taking into consideration the relevance of local and regional context and resources. For my lecture, I will present the methodology that underlie the consensus. Definition, diagnostic investigations, the aims of treatment outcome, non-surgical or surgical treatment options, management of treatment failure or relapse and the management of complications are the primary aims of this consensus. After series of meetings and extensive review of literatures, 21 statements were established. The Delphi method was used in the consensus voting process. In addition, for my lecture, I will cover statements 1 to 4 that include the definition, who should be tested, and what are the tests.

Keywords: Disorders of EGJ outflow, definition, diagnosis

WHAT ARE THE DIAGNOSTIC TESTS AND TREATMENT OUTCOMES?

Chuah Kee Huat

Universiti Malaya Medical Centre, Kuala Lumpur, Malaysia

Phenotyping of achalasia cardia with high resolution manometry is useful for prognosis and management. Evidence from several systematic reviews and meta-analyses have indicated that type II achalasia had better outcomes, regardless of treatment modality. On the other hand, type III achalasia has a higher incidence of treatment failure, whilst requiring a more extensive myotomy. In addition, POEM (which has the advantage of extending the myotomy) was found to be more effective than pneumatic dilation and Heller Myotomy in treating achalasia type III.

EGJ outflow obstruction is a manometric diagnosis characterized by LES obstruction with intact peristalsis, maybe primary or secondary, and may have a more benign course than achalasia cardia.

Inconclusive diagnosis of disorder of EGJ outflow by manometry may require provocative tests ranging from multiple rapid swallows, rapid drink challenge, solid test swallows and solid test meals. Additional investigations, including timed barium esophagogram and endoFLIP have been demonstrated to be useful.

The primary aims of treatment are symptom-relief, to improve quality of life and minimizing complications, e.g. malnutrition, aspiration pneumonia, chronic food retention, esophagitis, with a subsequent risk of metaplasia and carcinoma transformation of the esophagus.

WHAT ARE THE NON-SURGICAL AND SURGICAL OPTIONS?

Hans Alexander Mahendran

Hospital Sultanah Aminah Johor Bahru, Johor, Malaysia

Achalasia is a failure of the distal oesophageal sphincter to relax and associated with eventual loss of peristalsis of the oesophagus. Endoscopic intervention is a feasible intervention for alleviating symptoms however, surgical intervention may be necessary for long-term improvement. Symptomatic relief has always been the measure of success in the management of achalasia, however nutritional outcomes are now being used to monitor outcomes of intervention especially among younger patients who are expected to endure this disease for longer durations. The identification of the ideal intervention and when surgical intervention may be superior to less invasive measures is the main concern. Younger patients may be better candidates for surgical intervention as they have better long-term nutritional outcomes enabling them to have better quality of life and avoid developing malnutrition that would negatively impact their lives.

WHAT OTHER CONSIDERATIONS? POST-TREATMENT COMPLICATIONS, RELAPSE OR REFRACTORY, AND CANCER SURVEILLANCE

Ho Shiaw Hooi

Universiti Malaya Medical Centre, Kuala Lumpur, Malaysia

Gastro-oesophageal reflux disease remains the most common and troublesome complications of myotomy procedures due to the disruption of the anti-reflux barrier following the procedure. Recent meta-analysis revealed that up to 8.5-19.0%, 13.0-29.4% and 30.0-47.4% of patients were found to have symptomatic reflux, oesophagitis on endoscopy and abnormal pH exposure respectively after POEM. Other late complications include stricture, bleeding, Barrett's oesophagus and Barrett's neoplasia were relatively rare. PPI remains the mainstay of treatment for GERD following myotomy procedure. In refractory GERD, anti-reflux procedure or surgery can be considered either in the form of endoscopic or laparoscopic fundoplication. Patients with achalasia are at risk of oesophageal neoplasia. Study indicated an absolute risk increase (cases per 100,000 patients per year) of 308.1 for oesophageal squamous cell neoplasia and 18.03 for oesophageal adenocarcinoma in untreated achalasia patients. In treated patients, case series indicated risk of Barrett's and Barrett's neoplasia. Hence, both untreated and treated achalasia patients need to be followed up with endoscopic assessment.

Symptoms recurrence maybe experienced by those who underwent treatment. Timed barium oesophagogram and high-resolution manometry are effective investigational modalities to confirm recurrence. Both pneumatic dilation and repeat POEM can be used to treated achalasia patients with recurrence following treatment.

Keywords: GERD, Complications, Relapse

MANIPULATION OF GUT MICROBIOTA USING PROBIOTICS IN MANAGEMENT OF IRRITABLE BOWEL SYNDROME

Uday Chand Ghoshal

Sanjay Gandhi Postgraduate Institute of Medical Sciences, Lucknow, India

Recently, several studies suggested that altered quantity and quality in gut microbiota, called dysbiosis, are important in the pathogenesis of irritable bowel syndrome (IBS). It is therefore worthwhile to evaluate whether therapeutic manipulation of the gut microbiota using probiotics would be effective and safe in management of these patients. Several studies showed that probiotics are effective in manipulation of altered gut microbiota and in improving the global IBS symptoms. Probiotics reduce visceral hypersensitivity, improve colonic transit time, enhance the intestinal epithelial barrier, modulate immune response via production anti-inflammatory and regulatory cytokines, and thus, inhibit the inflammation. Several meta-analyses have confirmed the efficacy of probiotics in management of IBS. Hence, it can be concluded that probiotics are useful in treatment of IBS, particularly diarrhoea predominant subtypes, and most studies showed that abdominal pain, bloating and flatulence are the symptoms, which were relieved most.

MANIPULATION OF THE GUT MICROBIOTA: PREBIOTICS AND FIBRE

Gerald Holtmann

University of Queensland, Brisbane, Australia

The manipulation of gut microbiota by prebiotics and dietary fibre has gained considerable interest in recent years due to the impact of the gut microbiome on human health. Prebiotics, as defined by Gibson and Roberfroid (1995), are selectively fermented ingredients that result in specific changes in the composition and/or activity of the gastrointestinal microbiota. The consumption of prebiotics stimulates the growth and activity of specific beneficial bacteria such as Bifidobacteria and Lactobacilli. On the other hand, there has been interest in the role of dietary fibre for gut health. Fibre can be classified into two main types: soluble and insoluble. Soluble fibre, found in foods like oats, legumes, and fruits, forms a gel-like substance in the gut, promoting the growth of beneficial bacteria and leading to increased production of short-chain fatty acids (SCFAs), which provide energy for colonocytes. In contrast, insoluble fibre add bulk to the stool and helps regulate bowel movements thus preventing constipation. While prebiotics are believed to selectively promote the growth of beneficial gut bacteria, fibre contributes to overall gut function by supporting regular bowel movements and providing substrates for fermentation.

Keywords: Gut Microbiota, Prebiotics, Fibre

REFERENCE

Gibson GR, Roberfroid MB. Dietary modulation of the human colonic microbiota: introducing the concept of prebiotics. *J Nutr.* 1995 Jun;**125**(6):1401-12

SYMPOSIUM C - Manipulation of Gut Microbiota

FAECAL TRANSPLANTATION

Jonathan Lee Wei Jie

National University of Singapore, Singapore

Fecal Microbiota Transplantation (FMT) is a procedure to administer a solution of fecal matter from healthy donors into another individual. Following a pivotal research publication in 2013 on its effectiveness in *C. Difficile* infective colitis, its use has been widely accepted as a treatment option in *C. Difficile* infection. Its effectiveness is explained by the restoration of normal gut flora.

Since then, the range of FMT applications extended rapidly and broadly not only in *C Difficile* infections, but for gastrointestinal disorders, as well as for extra-gastrointestinal diseases. This talk will highlight (1) the processes for ensuring quality control with FMT preparation, such that FMT a safe therapeutic method with few adverse effects, (2) the emerging indications for FMT therapy, and (3) the potential for personalized FMT for different patients and conditions according to varied hosts and diseases.

Keywords: Fecal microbiota transplant, Microbiome, Gut flora

SYMPOSIUM C - Manipulation of Gut Microbiota

OTHER NOVEL APPROACHES

David Ong Eng Hui

Mount Elizabeth Orchard Medical Centre, Singapore

The concept of “bugs as drugs” is an appealing one as an alternative to big Pharma and is gaining interest in the clinical and scientific field.

The modification of the gut microbiome to serve therapeutic purposes for various diseases will be discussed in the talk. FMT is the usual way to introduce a healthy ecosystem into the gut to treat disease but other innovations and ways to improve the gut microbiome will be discussed.

ANCHORING HOLISTIC MANAGEMENT OF FATTY LIVER IN ASIAN CONTEXT

George Boon-Bee Goh

Singapore General Hospital, Singapore

Metabolic dysfunction associated fatty liver disease (MAFLD) is an increasingly common liver condition, with pooled global prevalence estimated at 30%. Asia is no exception, with similar prevalence reported. MAFLD is a complex multi-system disease, which needs a holistic approach where care needs extend beyond the liver, and the broader context of cardiometabolic disease needs to be considered in a multi-disciplinary approach, with different stakeholders involved to improve patient outcomes. Instituting lifestyle modification, optimizing metabolic comorbidities while assessing risk of severe MAFLD are equally important. Liver directed therapies for MAFLD remains to be clarified as there are currently no universally approved pharmacological therapies available. Adjunct supplements or nutraceuticals such as omega 3 fatty acids and Silymarin may be helpful and may be commonly used in the care of patients with MAFLD. In this session, we will explore the evidence, efficacy and limitations of their use within the context of real-world management of MAFLD.

CLOSING THE IMMUNISATION GAP TOWARDS A HEPATITIS-FREE NATION

Tan Soek Siam

Selayang Hospital, Selangor, Malaysia

The WHO estimates that over 100 million Hepatitis A virus (HAV) infections occur annually worldwide with an overall mortality rate of 0.1-5.4%. There is evidence that HAV infection is more severe with increasing age. More importantly HAV infection in people living with chronic liver diseases (CLD) may result in more serious outcomes like fulminant hepatitis, acute-on-chronic liver failure and even death.

While hepatitis B virus (HBV) infection has a high global burden with around 300 million people suffering from chronic HBV infection. HBV is one of the component viral hepatitis to be eliminated as a public health threat by 2030, a goal set by the WHO. The targets to realize this goal involve a reduction in new infections by 90% and deaths by 65% by that time. Unfortunately to date there is still no curative treatment for HBV which is a cancer causing virus, hence prevention by vaccination is a vital tool in achieving elimination. According to the WHO position paper on Hepatitis B vaccine: "A comprehensive approach to eliminating HBV transmission must address prevention of infections acquired perinatally and during childhood, as well as prevention of infections acquired by adolescents and adults."

The Malaysia Society of Infectious Disease and Chemotherapy guideline for adult immunisation recommended vaccination for: travelers to high endemicity area, patients with CLD, haemophiliacs, men who have sex with men, injection drug users and those with risk of occupation exposure.

For specific subpopulations who are also in our care, eg for people living with inflammatory bowel diseases (IBD) or CLD, regional guidelines recommended Hepatitis A and Hepatitis B vaccination.

The efficacy and safety of combination HAV/HBV vaccine is proven and it also confers long-term protection up to 20 years.

Keywords: Vaccine, Hepatitis B , Hepatitis A

SYMPOSIUM 6 - Metabolic-Associated Fatty Liver Disease

FROM NAFLD TO MAFLD

Krzysztof Tomasiewicz

Medical University of Lublin, Poland

The suggestions about the revising nomenclature of fatty liver disease have been considered for many years. In 2020 the consensus of experts recommended the term NAFLD should be changed to metabolic-associated fatty liver disease (MAFLD). In June 2023 the most recent AASLD statement has been published, with new name - metabolic dysfunction-associated steatotic liver disease (MASLD). MASLD encompasses patients who have hepatic steatosis and have cardiometabolic risk factors. It is similar to previous MAFLD definition. There is also new category, termed MetALD, to describe those with MASLD who consume greater amounts of alcohol. Term NASH has been replaced by Metabolic dysfunction-associated steatohepatitis (MASH). In the near future one may expect patients sub-phenotyping based on genetics and epigenetics.

Metabolic health that is a base for MAFLD could be a consequence of comorbidities, ie. type 2 diabetes and obesity or metabolic abnormalities that may be identified even in lean patients. The prognosis of liver steatosis and fibrosis progression and risk of liver cancer is a main challenge for hepatologist. But in many MAFLD patients one may expect the increased cardiovascular risk and a number of diseases development including chronic kidney disease, sarcopenia, inflammatory bowel disease, extrahepatic cancers etc. Further investigations are still required.

Keywords: NAFLD, MAFLD, steatohepatitis

THE PATIENT WITH MAFLD AND HIGH LIVER STIFFNESS MEASUREMENT: WHAT NEXT?

Chan Wah Kheong

Universiti Malaya, Kuala Lumpur, Malaysia

Metabolic dysfunction-associated fatty liver disease is prevalent in the general population. A small yet significant proportion of patients have more severe liver disease. A simple and clear assessment and referral pathway is essential to optimize resources in the face of this burgeoning public health threat, so that patients with more severe liver disease can be referred for specialist care, while patients with less severe liver disease can remain in primary care, where they are best managed. Current guidelines recommend initial assessment with simple fibrosis test (e.g., fibrosis-4 index) followed by a second test (e.g., liver stiffness measurement) for selected patients. The concept of compensated advanced chronic liver disease (cACLD) reflects the continuum of severe fibrosis and cirrhosis in patients with ongoing chronic liver disease and aims to stratify patients according to the risk of clinically significant portal hypertension (CSPH) and decompensation. Treatment with non-selective beta-blocker (NSBB e.g., carvedilol) should be considered for prevention of decompensation in patients with CSPH. Patients with compensated cirrhosis who are on NSBB for prevention of decompensation do not need a screening endoscopy since endoscopy will not change management. Surveillance for hepatocellular carcinoma should be considered in patients with cACLD.

Keywords: metabolic dysfunction-associated fatty liver disease (MAFLD); compensated advanced chronic liver disease (cACLD); clinically significant portal hypertension (CSPH)

A PRACTICAL APPROACH TO LIFESTYLE MODIFICATION AND CARDIOVASCULAR DISEASE RISK REDUCTION FOR MAFLD

George Boon-Bee Goh

Singapore General Hospital, Singapore

Metabolic dysfunction associated fatty liver disease (MAFLD) is a leading cause of chronic liver disease worldwide with considerable clinical burden. It is closely related to established cardiometabolic risk factors such as obesity, type 2 Diabetes Mellitus and atherogenic dyslipidemia. As such, MAFLD is also closely associated with cardiovascular disease, with cardiovascular disease acknowledged as a leading cause of morbidity and mortality in patients with MAFLD. In the absence of approved pharmacological therapies currently, lifestyle modification remains the cornerstone of treatment in MAFLD. This entails dietary measures, enhancement of physical activity, and a focus towards weight loss/control. In general, weight reduction of between 5 to 10% have been shown to be beneficial in MAFLD management. Additionally, restriction or elimination of alcohol consumption and smoking cessation are also important. In this session, we will discuss the details of these lifestyle recommendations, providing a practical approach to carrying out these measures effectively.

EMERGING NOVEL THERAPIES FOR STEATOHEPATITIS

Phunchai Charatcharoenwitthaya

Siriraj Hospital, Mahidol University, Bangkok, Thailand

Insulin resistance plays a significant role in the development and progression of non-alcoholic fatty liver disease (NAFLD) to non-alcoholic steatohepatitis (NASH) and cirrhosis. Current therapeutic options for NASH primarily focus on improving steatosis, inflammation, and fibrosis. However, an ideal drug therapy for NASH should also address glucose metabolism, lipid regulation, insulin resistance, and obesity. Novel drugs targeting specific pathophysiological pathways associated with NASH have been developed. These include antioxidants, farnesoid X receptor (FXR) agonists, peroxisome proliferator-activated receptor (PPAR) agonists, glucagon-like peptide-1 (GLP-1) agonists, sodium-glucose cotransporter-2 inhibitors (SGLT-2i), fibroblast growth factor (FGF) analogues, thyroid hormone receptor β (THR- β) agonists, and fatty acid synthase inhibitors (FASNi). Given the heterogeneity of NASH, combination therapy is likely to be more effective in treating patients with NASH compared to monotherapy alone. Several trials are currently underway in this field. Since no specific treatment has been approved for NASH, further research is necessary to identify patient subgroups that may benefit the most from this therapeutic approach. Additionally, the development and validation of non-invasive predictive biomarkers that reliably predict histological and clinical responses are needed. These biomarkers would enable continuous monitoring of NASH patients undergoing therapies.

Keywords: Non-alcoholic steatohepatitis, insulin resistance, therapeutic agents

IS THERE A ROLE FOR “-BIOTICS” IN MAFLD?

Amany Zekry

St George Hospital, University of New South Wales, Australia

Metabolic-Associated Fatty Liver Disease (MaFLD) is a global health concern, presenting a complex interplay between metabolic dysfunction, hepatic lipid accumulation, and environmental and genetic factors. The gut microbiome has gained substantial interest for its role in modulating host metabolism and immune responses. Dysbiosis of the gut microbiome has been linked to MaFLD through alterations in bile acid metabolism, lipogenesis, and inflammation. Microbial-derived metabolites, such as short-chain fatty acids, secondary bile acids, and lipopolysaccharides, influence hepatic lipid homeostasis and insulin sensitivity, exacerbating MaFLD. Consequently, innovative strategies targeting enteric flora modulation, have garnered attention as potential preventative/adjunctive therapeutic options for MaFLD. These strategies encompass a spectrum of interventions, ranging from probiotics, and prebiotics to synbiotics, fecal microbiota transplantation (FMT), and the engineering of bacteria with tailored functionalities. Recent data suggest promising outcomes, revealing the potential of gut-based interventions to restore gut permeability, alleviate hepatic steatosis, and ameliorate lipid profiles in MaFLD patients. The imperative for robust and comprehensive studies remains clear to discern optimal therapeutic approaches, the strategic timing of interventions throughout the course of liver disease, and suitable tools to discern the most effective interventions and their outcomes. Until then, lifestyle modifications, healthy dietary habits, and exercise remain the foremost treatment approach for early-stage MaFLD. The evolution of microbiome-focused interventions in MaFLD management holds promise for reshaping therapeutic paradigms, emphasising the necessity of continued research in this field.

Keywords: Biome, MAFLD, Therapeutics

THE MICROBIOTA-GUT-BRAIN AXIS AS AN EXPERIENCE-DEPENDENT MODULATOR OF BRAIN FUNCTION AND DYSFUNCTION

Anthony Hannan

University of Melbourne, Australia

We have discovered altered brain-body interactions, including the first evidence of gut dysbiosis (dysregulated microbiota) in Huntington's disease (HD), and a preclinical model of schizophrenia. We have found correlations between microbial metagenomics and blood metabolomics at an early stage of pathogenesis in HD mice, suggesting a mechanism whereby gut dysbiosis can modulate brain function and dysfunction. This preclinical discovery was followed up with our clinical collaborators, demonstrating that gut microbiota are altered in a cohort of gene-positive presymptomatic and symptomatic subjects, relative to matched controls. Similarly, the gut microbiome changes we found in a genetic mouse model of schizophrenia have parallels with gut dysbiosis recently reported in clinical studies. Further studies demonstrate differential effects of environmental enrichment and exercise on gut microbiota of HD and wild-type mice, correlated with therapeutic impacts of these interventions. Recently, we have found that fecal microbiota transplant from wild-type mice into HD mice ameliorates cognitive deficits modeling dementia in HD. Ongoing studies are exploring the gut microbiome as a therapeutic target and the possibility that specific therapeutic interventions may modulate brain function via microbiota-gut-brain interactions. These, and other, preclinical discoveries may inform the development of new clinical approaches, including enviromimetics and their subclass, exercise mimetics.

NEURODEVELOPMENTAL DISORDERS

Sven Pettersson

National Neuroscience Institute, Singapore

Biological Ageing (BA) reflects organ decline and is always associated with the risk to contract a disease. Additionally, gut microbes are vital in regulating mammalian physiology and organ function and, therefore, essential to BA. It is empirically observed that organ decline is variable between individuals in part linked to the microbe composition. In line with the “Holobiont” hypothesis, any age-related change in organ function will be sensed by gut microbes who reciprocate by alteration in composition and/or secretion molecules to avoid impairment in metabolic homeostasis. In my presentation, I will use microbe regulation of tryptophan metabolism to illustrate how evolutionarily selected host-microbe-enriched pathways, communicate with host organ function and either reduce or accelerate the ageing process. I will pay special attention to the gut-microbe-brain axis.

Keywords: Ageing, gut microbiome, metabolites

MOOD AND DEPRESSIVE DISORDERS

Felice Jacka

Deakin University, Australia

Alfred Deakin Professor Jacka OAM has pioneered the new field of Nutritional Psychiatry by leading the development of a robust body of evidence regarding the influence of lifestyle behaviours, particularly diet, on mental and brain health. In this presentation, she will provide an up-to-date, critical assessment of the evidence regarding the role of diet quality in depression, anxiety, and brain health across age groups and countries. She will cover the new understanding of the mechanistic pathways linking diet to mental health with a particular focus on the microbiota-gut-brain axis. Finally, she will discuss the evidence for diet as a key clinical strategy for improving mental and brain health, outline the new research and translation activities underway in this field, and address the research, clinical and policy imperatives for translating the evidence into improvements to individual and population health. There is enormous potential for both clinical and public health interventions focused on nutrition for the prevention and treatment of mental, neurodevelopmental, and neurodegenerative disorders, including new possibilities for precision medicine.

Keywords: Diet; Nutrition; Psychiatry

GUT MICROBIOTA AND METABOLIC DISORDERS

Chun-Ying Wu

National Yang Ming Chiao Tung University, Taiwan

Metabolic syndrome has become a worldwide pandemic disease burden. In the past decades, metabolic syndrome has increased 5-10 times in nearly all countries, which cannot be explained by human genetic changing speed. Diet, sedentary life, and environmental factors have been suggested to be risk factors. All these potential risk factors now can be explained by gut microbiota dysbiosis.

In recent years, many animal experiments and clinical research have demonstrated the essential roles of gut microbiota in metabolic syndrome via many mechanisms, such as the efficacy of energy harvest, appetite control, hormone regulation, inflammation signaling, etc. Gut microbiota dysbiosis is the description of the imbalance status of gut microbiota, either the compositions or the functions. Dysbiosis not only leads to the development of metabolic syndrome but is also related to treatment responses.

Several gut microbiota intervention strategies have been suggested to treat dysbiosis, such as probiotics, prebiotics, post-biotics, lifestyle intervention, drugs, fecal microbiota transplantation, and live therapeutic products, etc. These gut microbiota intervention measures have been tried in animal experiments and clinical trials with promising results. Intervening gut microbiota has become a very actively studied solution to preventing or treating metabolic syndrome.

Keywords: Gut microbiota, metabolic syndrome, intervention

USE OF ARTIFICIAL INTELLIGENCE IN COLORECTAL CANCER SCREENING

Joseph J Y Sung

Nanyang Technological University, Singapore

Artificial intelligence has been shown to improve adenoma detection rate by 30% and reduce missing advanced neoplasm in the colon. This improvement is irrespective of FIT test results, polyp size, location and experience of endoscopist and even quality of bowel preparation. Furthermore, AI characterization of the polyps can also obviate removal of polyps from the colon saving cost and time for colonoscopy. There are also evidence to suggest that AI assisted polypectomy can reduce bleeding and complications of the procedure. So far, the evidence is convincing but gastroenterologist/endoscopist trust and acceptance of the procedures have room for improvement. It has been shown that while majority of gastroenterologist accept that AI can improve polyp detection and characterization, using AI to assist polypectomy have not been widely trusted as a safe procedure.

COLORECTAL CANCER SCREENING: ROLE OF ENDOSCOPY TRAINING AND CREDENTIALING

Benedict Devereaux

University of Queensland, Royal Brisbane and Women's Hospital, Australia

High quality colonoscopy is essential for accurate and safe detection of pre-malignant and malignant colonic lesions and diagnosis and management of non-neoplastic pathologies. Colonoscopy training has traditionally been co-ordinated at an individual endoscopy unit level. It is essential to critically appraise colonoscopy training and monitor subsequent performance to ensure high standards are enduring.

In determining the optimal governance programs lessons can be drawn from other jurisdictions. In Australia, all colonoscopists must fulfill the quality indicators determined by the Conjoint Committee for Recognition of Training in Gastrointestinal Endoscopy (CCRTGE) so as to undertake unsupervised practice. Over the past decade, there has been increased focus on the quality of colonoscopy in Australia. As a result, the Gastroenterological Society of Australia, established the Colonoscopy Recertification Program in 2017. In February 2023, this committee evolved to the Recertification in Colonoscopy Conjoint Committee, overseen by GESA, The Royal Australasian College of Surgeons and the Royal Australasian College of Physicians. Incorporating surgeons into this formal oversight committee was essential as colonoscopists, irrespective of specialty should attain and maintain the same high standard of colonoscopy practice; "We are not Physicians or Surgeons, we are all colonoscopists". Most recently, in order to ensure consistency in colonoscopy training, a new Conjoint Endoscopy Training Think Tank has been established to define a colonoscopy curriculum and syllabus.

Keywords: Colonoscopy, credentialing, recertification

CRC SCREENING: CHALLENGES AND COST-ECONOMIC IMPLICATIONS

Hyun-Soo Kim

Yonsei University Wonju College of Medicine, Wonju, Korea

I would like to introduce the interim results of a pilot study being conducted to introduce primary colonoscopy screening in Korea. As another hot issue, the results of a domestic big data study on the effectiveness of colonoscopy screening on the suppression of colorectal cancer among people in their 40s and over 75 years of age, which are highly controversial regarding initiation and stopping age of CRC screening will be introduced. Moreover, due to COVID-19 related congestion and delay of cancer screening resulted in the decreases both participation rate and consequent cancer detection date compared to pre-COVID 19. In particular, as the age increases, the detection rate of colorectal cancer tends to decrease, which is concerned that it will become a serious socioeconomic burden in the future. In a viewpoint of cost-effectiveness, CRC screening emerges as highly cost-effective in multiple models across a wide range of assumptions. Because of complexities with the wide variety of models, modeling approaches, and regional inputs, however, evidence on cost-effectiveness analyzes of colorectal cancer screening in Asia, specific cost-effectiveness estimates, comparisons between strategies, and willingness to pay to achieve a given health outcome is very lacking. In the lecture, current strategies, particularly FIT and colonoscopy and future direction for cost-economics will be addressed.

Keywords: Colorectal cancer screening, colonoscopy, cost-effectiveness

MANAGING FUNCTIONAL DISORDERS AFTER RECTAL CANCER SURGERY

Luqman Mazlan

Pantai Hospital Kuala Lumpur, Kuala Lumpur, Malaysia

Improvements in operative techniques for rectal cancer surgery and innovations in surgical devices such as the use of robots, advanced laparoscopic equipment and surgical staplers result in increasingly higher rates of primary anastomoses. The primary aim is to preserve as much sphincter muscle as possible and avoiding a permanent stoma. These developments, however, are a double edge sword because surgeons are then faced with trying to find a balance between achieving optimal functional outcome while not compromising on oncological margins.

Sphincter damage, reservoir dysfunction and dysmotility due to pelvic nerve denervation are among the few theories behind the pathophysiology of the Low Anterior Resection Syndrome (LARS) which is increasingly common with sphincter saving surgeries. These symptoms are a challenge to treat and have been proven to significantly affect the quality of life of patients. Treatment modalities include pelvic floor exercises, biofeedback therapy, trans-anal irrigation and sacral nerve stimulation. The lecture will highlight the latest literature on LARS and management options as well as the evidence behind the newer techniques currently available to evaluate and preserve sphincter and rectal reservoir function without compromising on cancer margins.

Keywords: Colorectal, surgery, functional

CLINICAL APPLICATION AND PERSONALISATION OF THE GUT MICROBIOME

Siew-Chien Ng

The Chinese University of Hong Kong, Hong Kong

The gut microbiota, regarded as “the second genome” of human, is responsible for a large number of key physiological responses in the host, including the regulation of host immunity, prevention of pathogen infection, synthesis and metabolism of critical molecules. Altered gut microbiome is linked to many human diseases ranging from cancer, metabolic disease, inflammatory bowel disease, mental illnesses and COVID-19. Systemic characterisation of the human faecal microbiome provides the opportunity to develop non-invasive approaches in the diagnosis of major human diseases, such as early colon cancer detection, diagnosis of childhood disease like autism, and metabolic conditions, for personalised therapies. Fecal microbiota transplantation has revolutionized the treatment of recurrent *Clostridium diffidioides* infections and are increasingly being tested in multiple different diseases. Understanding the underlying mechanisms of FMT can improve success for more precise selection of donors. More importantly, recent research highlighted that modulation of the gut microbiome could also play an indispensable role during anti-cancer therapy. In this talk, I will discuss the potential application of microbiome-based diagnostics and therapeutics using several examples. and the future of precision microbiome medicine.

Keywords: Microbiome, precision, fecal bacteria diagnostics

SYMPOSIUM E - Gut Microbiota-Translating Research into Practice

START-UP EXPERIENCE 1: WHAT I LEARN FROM MY JOURNEY WITH AMILI?

Jeremy Lim

National University of Singapore, Singapore

A/Prof Jeremy Lim will share about AMILI's genesis and the journey over the last 4 years, identifying lessons learnt that might be relevant for academics and clinicians looking into entrepreneurship and supporting entrepreneurs as advisors. He will discuss commercial realities and scientific opportunities and balancing the often contradictory forces.

SYMPOSIUM E - Gut Microbiota-Translating Research into Practice

START-UP EXPERIENCE 2: WHAT I LEARN FROM MY JOURNEY WITH AGTC GENOMICS?

Leong Chee Onn

AGTC Genomics, Kuala Lumpur, Malaysia

This presentation narrates the remarkable journey of AGTC Genomics, a shining example of the transition from an academic research setting to a thriving technology startup. It discusses how AGTC Genomics, originally rooted in an academic context, adapted its strategies and ideologies to establish its footing in the competitive entrepreneurial environment of the tech startup scene. The story of AGTC Genomics is unique in its ability to maintain the rigor and depth of scientific inquiry that characterized its academic origins while embracing the speed, adaptability, and customer-centric mindset required for success in the technology industry. The transformation of AGTC Genomics signifies the synergy of two seemingly different worlds: academia, known for its meticulous investigation and comprehensive research; and the technology startup ecosystem, valued for its rapid pace, constant evolution, and focus on disruptive innovation. This paper details how AGTC Genomics managed to converge these two realms, effectively leveraging academic prowess into commercial success. Through this case study, we aim to provide valuable insights for academic entities considering a similar transition, emphasizing the strategic planning, organizational restructuring, and cultural shifts required to thrive in a tech-oriented entrepreneurial space. By delving into the unique challenges and opportunities encountered by AGTC Genomics, this paper presents a roadmap that other organizations can potentially follow when transitioning from an academic to a startup setting.

Keywords: Genomics, academia, entrepreneur

E-Poster Presentations

- ID 003** **NOMOGRAM TO PREDICT THE LONG-TERM OVERALL SURVIVAL OF EARLY-STAGE HEPATOCELLULAR CARCINOMA AFTER RADIOFREQUENCY ABLATION**
Kwong-Ming Kee, Yuan-Hung Kuo, Tzu-Hsin Huang, Yi-Hao Yen, Sheng-Nan Lu, Jing-Houng Wang, Chao-Hung Hung, Chien-Hung Chen and Ming-Chao Tsai
Division of Hepato-Gastroenterology, Department of Internal Medicine, Kaohsiung Chang Gung Memorial Hospital and Chang Gung University College of Medicine, Taiwan
- ID 042** **PREVALENCE OF TRANSIENT ELASTOGRAPHY-DIAGNOSED MAFLD AMONG STAFFS IN THE DEPARTMENT OF NURSING SERVICES: A CROSS-SECTIONAL, URBAN HOSPITAL-BASED STUDY**
Saranya S Kumaresan¹, Brandon Ling Zing Sing¹, Rosanne Suraya Asraff Andrew¹, Amy Tiong Mii¹, Norhayati Majid², Rohana Jaafar², Masrifah Zakaria², Eliza Nadia Abdul Latif³, Khairul Najmi Muhammad Nawawi¹
¹*Gastroenterology & Hepatology Unit, Department of Medicine, Faculty of Medicine, Universiti Kebangsaan Malaysia, Kuala Lumpur, Malaysia*
²*Department of Nursing Services, Hospital Canselor Tuanku Muhriz, Kuala Lumpur, Malaysia*
³*Endoscopy Service Centre, Hospital Canselor Tuanku Muhriz, Kuala Lumpur, Malaysia*
- ID 067** **EVIDENCE OF VACCINE ESCAPE HBV MUTANT AMONG PATIENTS WITH CHRONIC HEPATITIS B IN HOSPITAL SAINS MALAYSIA**
Bello Kizito Eneye^{1,2}, Nazri Mustaffa^{3,5}, Wong Mung Seong^{3,5}, Lee Yeong Yeh^{3,5}, Rafidah Hanim Shueb^{1,4,5}
¹*Department of Medical Microbiology and Parasitology, School of Medical Sciences, Universiti Sains Malaysia, Kubang Kerian, Kelantan, Malaysia*
²*Kogi State University (Prince Abubakar Audu University) Anyigba, Kogi State, Nigeria*
³*Department of Medicine, School of Medical Sciences, Universiti Sains Malaysia, Kubang Kerian, Kelantan, Malaysia*
⁴*Institute for Research in Molecular Medicine, Universiti Sains Malaysia, Kubang Kerian, Kelantan, Malaysia*
⁵*Hospital Universiti Sains Malaysia, Kubang Kerian, Kelantan, Malaysia*
- ID 068** **A REPORT ON THE EMERGENCE OF HEPATITIS B RECOMBINANT GENOTYPES AMONG PATIENTS WITH CHRONIC HEPATITIS B INFECTION IN HOSPITAL UNIVERSITI SAINS MALAYSIA**
Bello Kizito Eneye^{1,2}, Nazri Mustaffa^{3,5}, Wong Mung Seong^{3,5}, Lee Yeong Yeh^{3,5}, Rafidah Hanim Shueb^{1,4,5}
¹*Department of Medical Microbiology and Parasitology, School of Medical Sciences, Universiti Sains Malaysia, Kubang Kerian, Kelantan, Malaysia*
²*Kogi State University (Prince Abubakar Audu University) Anyigba, Kogi State, Nigeria*
³*Department of Medicine, School of Medical Sciences, Universiti Sains Malaysia, Kubang Kerian, Kelantan, Malaysia*
⁴*Institute for Research in Molecular Medicine, Universiti Sains Malaysia, Kubang Kerian, Kelantan, Malaysia*
⁵*Hospital Universiti Sains Malaysia, Kubang Kerian, Kelantan, Malaysia*

E-Poster Presentations

- ID 069 AN EVALUATION OF EXPOSURE TO MICROPLASTICS AND NANOPLASTICS IN GASTROINTESTINAL TRACT ON GUT HEALTH: A SYSTEMATIC REVIEW**
Yi Huan Tan¹, Lai Ti Gew¹, Raja Affendi Raja Ali^{1,2}
¹Department of Biological Sciences, School of Medical and Life Sciences, Sunway University, Selangor, Malaysia
²Gut Research Group, Faculty of Medicine, Universiti Kebangsaan Malaysia, Kuala Lumpur, Malaysia
- ID 072 ENDOSCOPIC THERAPY WITH HIGH CONCENTRATION DEXTROSE: A COMEBACK WITH A NEW TWIST**
Shahreedhan Shahrani¹, Bo Shen², Ida Normiha Hilmi^{1,3}
¹Department of Internal Medicine, Universiti Malaya Medical Centre, Kuala Lumpur, Malaysia
²Center for Inflammatory Bowel Diseases, University Irving Medical Center/NewYork-Presbyterian/Columbia, New York, NY, USA
³Faculty of Medicine, Universiti Malaya, Kuala Lumpur, Malaysia
- ID 075 PHARYNGEAL AND UPPER ESOPHAGEAL SPHINCTER METRICS: NORMATIVE VALUES FOR THE MALAYSIAN POPULATION, COMPARISON BETWEEN 5ML AND 15ML BOLUS CHALLENGES AND CORRELATION WITH SWALLOWING RISK INDEX**
Naveen R^{1,4}, Siti Norhasliza¹, Azliani¹, Nashrulhaq Tagiling^{1,2}, T A Iskandar^{1,2}, Chua KH³, Lee YY^{1,2}
¹GI Function and Motility Unit, Hospital Universiti Sains Malaysia, Kubang Kerian, Kelantan, Malaysia
²School of Medical Sciences, Universiti Sains Malaysia, Kubang Kerian, Kelantan, Malaysia
³Faculty of Medicine, Universiti Malaya, Kuala Lumpur, Malaysia
⁴Gastroenterology Unit, Department of Internal Medicine, Hospital Sultanah Bahiyah, Alor Setar, Kedah, Malaysia
- ID 086 AN UNUSUAL CASE OF ACHALASIA CARDIA MIMIC: WHY CANT I CUT IT TROUGH?**
Nik Muhamad Affendi Nik Arsyad^{1,2}, Shiaw-Hooi Ho², Peng-Choong Lau^{3,4}, Sanjiv Mahadeva²
¹Department of Medicine, International Islamic University Malaysia, Kuantan, Pahang, Malaysia
²Division of Gastroenterology, Department of Medicine, Faculty of Medicine, Universiti Malaya, Kuala Lumpur, Malaysia
³Department of Surgery, Faculty of Medicine, Universiti Malaya, Kuala Lumpur, Malaysia
⁴Pantai Hospital Kuala Lumpur, Kuala Lumpur, Malaysia

NOMOGRAM TO PREDICT THE LONG-TERM OVERALL SURVIVAL OF EARLY-STAGE HEPATOCELLULAR CARCINOMA AFTER RADIOFREQUENCY ABLATION

Kwong-Ming Kee, Yuan-Hung Kuo, Tzu-Hsin Huang, Yi-Hao Yen, Sheng-Nan Lu, Jing-Houng Wang, Chao-Hung Hung, Chien-Hung Chen and Ming-Chao Tsai

Division of Hepato-Gastroenterology, Department of Internal Medicine, Kaohsiung Chang Gung Memorial Hospital and Chang Gung University College of Medicine, Taiwan

OBJECTIVES: Our objective was to develop a predictive nomogram that could estimate the long-term survival of patients with very early/early-stage hepatocellular carcinoma (HCC) undergoing radiofrequency ablation (RFA).

METHODOLOGY: For this retrospective study, we enrolled 950 patients who initially received curative RFA for HCC at Barcelona Clinic Liver Cancer (BCLC) stages 0 and A between 2002 and 2016. Factors predicting poor survival after RFA were investigated through a Cox proportional hazard model. The nomogram was constructed using the investigated variables influencing overall survival (OS).

RESULTS: After a median follow-up time of 6.25 years, 400 patients had died, and 17 patients had received liver transplantation. The 1-,3-,5-,7-, and 10-year OS rates were 94.5%, 73.5%, 57.9%, 45.7%, and 35.8%, respectively. Multivariate analysis showed that age greater than 65 years, albumin-bilirubin (ALBI) grades 2 and 3, AST-to-platelet ratio index (APRI) greater than 1, tumor size larger than 3 cm, diabetes mellitus, end-stage renal disease, and tumor number greater than 1 were significantly associated with poor OS. The nomogram was constructed using these seven variables. The validation results showed a good concordance index of 0.683. When comparing discriminative ability to tumor, node, and metastasis (TNM), BCLC, and Cancer of the Liver Italian Program (CLIP) staging systems, our nomogram had the highest C-index for predicting mortality.

CONCLUSIONS: We have developed a straightforward nomogram that allows for the prediction of long-term overall survival after RFA in early-stage HCC patients. This individualized tool holds significant potential for application in clinical practice, as it can enhance patient-physician communication and facilitate informed decision-making regarding curative treatment options for early-stage HCC patients. By providing personalized prognostic information, the nomogram empowers healthcare professionals to optimize treatment strategies and improve patient outcomes in this specific population.

PREVALENCE OF TRANSIENT ELASTOGRAPHY-DIAGNOSED MAFLD AMONG STAFFS IN THE DEPARTMENT OF NURSING SERVICES: A CROSS-SECTIONAL, URBAN HOSPITAL-BASED STUDY

Saranya S Kumaresan¹, Brandon Ling Zing Sing¹, Rosanne Suraya Asraff Andrew¹, Amy Tiong Mii¹, Norhayati Majid², Rohana Jaafar², Masrifah Zakaria², Eliza Nadia Abdul Latif³,
Khairul Najmi Muhammad Nawawi¹

¹Gastroenterology & Hepatology Unit, Department of Medicine, Faculty of Medicine, Universiti Kebangsaan Malaysia, Kuala Lumpur, Malaysia

²Department of Nursing Services, Hospital Canselor Tuanku Muhriz, Kuala Lumpur, Malaysia

³Endoscopy Service Centre, Hospital Canselor Tuanku Muhriz, Kuala Lumpur, Malaysia

BACKGROUND/OBJECTIVES: Prevalence of metabolic dysfunction-associated fatty liver disease (MAFLD) in Malaysia is expected to rise. Apart from metabolic diseases, irregular meal timing and lack of exercise surely play a role in the development of fatty liver. We aim to determine the prevalence of MAFLD among the staffs in the Department of Nursing Services in Hospital Canselor Tuanku Muhriz, UKM.

METHODOLOGY: MAFLD is defined according to the MSGH consensus statement 2022 and the presence of fatty liver was determined by transient elastography (TE) with a controlled attenuated parameter (CAP) cut-off value of ≥ 263 dB/m. International Physical Activity Questionnaire (IPAQ) was used to assess the physical activity level.

RESULTS: Out of 153 participants who underwent the screening, 53 (34.6%) individuals had TE-diagnosed fatty liver: nurses, 42/108 (38.9%); *pembantu perawatan kesihatan*, 6/33 (18.2%) and medical assistant, 5/12 (41.7%). All individual with fatty liver fulfilled the diagnostic criteria for MAFLD. The mean TE's values were as follow: MAFLD; CAP: 304.3 dB/m, E: 6.1 kPa and control; CAP: 218.1 dB/m, E: 5.1 kPa.

MAFLD group had significantly worse anthropometric parameters as compared to the control group; BMI; 30.9kg/m² (± 5.4) vs 26.7kg/m² (± 4.4), $p < 0.001$, waist circumference; 95.5cm (± 9.7) vs 85.5cm (± 10.2), $p < 0.001$, total body fat; 40.8kg vs 38.9kg, p -value=0.001, and visceral fat; 10.6 (± 4.1) vs 3.7 (± 3.0), $p < 0.001$. There were no significant different of prevalence of metabolic diseases between the two groups; diabetes mellitus type 2 ($p = 0.133$), hypertension ($p = 0.555$) and dyslipidemia ($p = 0.382$).

Although not statistically significant, MALFD group was slightly less active (1097.6 vs 1549.2, p -value=0.369) and adopted more sedentary lifestyle (9.8% vs 3.4%, $p = 0.126$). The mean values for the biochemical blood test for MAFLD group are as follow: fasting glucose 5.3mmol/L, total cholesterol 5.7 mmol/L, triglyceride 1.2 mmol/L, ALT 27.6U/L, and GGT 43.9U/L.

CONCLUSION: There was a modest prevalence of MAFLD (34.6%) among the Department of Nursing Service staff. Healthcare workers should be encouraged to adopt a healthier lifestyle, despite their understandably busy and hectic clinical duties.

EVIDENCE OF VACCINE ESCAPE HBV MUTANT AMONG PATIENTS WITH CHRONIC HEPATITIS B IN HOSPITAL SAINS MALAYSIA

Bello Kizito Eneye^{1,2}, Nazri Mustafa^{3,5}, Wong Mung Seong^{3,5}, Lee Yeong Yeh^{3,5}, Rafidah Hanim Shueb^{1,4,5}

¹Department of Medical Microbiology and Parasitology, School of Medical Sciences, Universiti Sains Malaysia, Kubang Kerian, Kelantan, Malaysia

²Kogi State University (Prince Abubakar Audu University) Anyigba, Kogi State, Nigeria

³Department of Medicine, School of Medical Sciences, Universiti Sains Malaysia, Kubang Kerian, Kelantan, Malaysia

⁴Institute for Research in Molecular Medicine, Universiti Sains Malaysia, Kubang Kerian, Kelantan, Malaysia

⁵Hospital Universiti Sains Malaysia, Kubang Kerian, Kelantan, Malaysia

INTRODUCTION: Chronic Hepatitis B virus (HBV) infection in Malaysia is still a public health concern despite the introduction of HBV vaccination for neonates in 1989. Despite the potency and safety of current small-HBs antigen HBV vaccines, the emergence of vaccine-escape mutations (VEMs) has been reported in Asia.

OBJECTIVE: To investigate the prevalence of VEMs among patients with chronic HBV infection at our centre, a tertiary referral hospital on the East Coast of Peninsular Malaysia.

METHODS: Blood samples were collected from one hundred and sixty-nine patients with chronic HBV infection. DNA was extracted from sera using a Machery Nagel DNA extraction kit, subjected to nested PCR using published primers, and then sequenced. The sequences were subjected to VEMs nucleotide modification at fourteen nucleotide positions related to VEMs (116, 118, 120, 126, 129, 130, 131, 133, 134, 141, 142, 143, 144 and 145).

RESULTS: A total of five (5) out of 166 subjects had VEMs, accounting for a 3.01% prevalence rate. Sex and age were significant towards acquiring VEMs within the study population ($P > 0.05$), with slightly more males (3) than females. VEMs occurred mainly in those aged 40-50 years old (4 subjects).

DISCUSSION AND CONCLUSION: These findings highlight the risk of VEMs in our cohort of patients, which may reflect similar issues at a national level or even globally. This further underlines the need for future vaccine technologies to address these issues.

A REPORT ON THE EMERGENCE OF HEPATITIS B RECOMBINANT GENOTYPES AMONG PATIENTS WITH CHRONIC HEPATITIS B INFECTION IN HOSPITAL UNIVERSITI SAINS MALAYSIA

Bello Kizito Eneye^{1,2}, **Nazri Mustafa**^{3,5}, **Wong Mung Seong**^{3,5}, **Lee Yeong Yeh**^{3,5}, **Rafidah Hanim Shueb**^{1,4,5}

¹Department of Medical Microbiology and Parasitology, School of Medical Sciences, Universiti Sains Malaysia, Kubang Kerian, Kelantan, Malaysia

²Kogi State University (Prince Abubakar Audu University) Anyigba, Kogi State, Nigeria

³Department of Medicine, School of Medical Sciences, Universiti Sains Malaysia, Kubang Kerian, Kelantan, Malaysia

⁴Institute for Research in Molecular Medicine, Universiti Sains Malaysia, Kubang Kerian, Kelantan, Malaysia

⁵Hospital Universiti Sains Malaysia, Kubang Kerian, Kelantan, Malaysia

INTRODUCTION: Hepatitis B virus (HBV) has evolved since its discovery and is still of significant medical concern to physicians and healthcare givers. The emergence of recombinant HBV genotypes has been reported in Europe, America, and Asia. However, the prevalence of recombinant HBV genotypes in Malaysia has not been reported yet.

OBJECTIVE: To investigate the prevalence of recombinant HBV genotypes among patients with chronic HBV infection at our centre, a tertiary referral hospital on the East Coast of Peninsular Malaysia.

Methods: A cohort of 226 patients who had chronic HBV infection were tested for recombinant genotypes using standard genotyping protocols and tools. HBV DNA was extracted from the sera of subjects and then analysed using nested PCR using published primers. The amplicons were sequenced following standard protocols and then genotyped. These HBV genotypes were then examined for recombinant genotypes. Recombinant genotypes were identified using Simplot analysis and NCBI genotyping tools.

RESULTS: Evidence of genotypic recombination was found in 7/226 subjects (3.1%). Two unique recombinant genotypes were detected; genotypes B/C (n=5: 71.4%) and B/D (n=2: 28.6%). Several demographic characteristics were associated with acquiring recombinant genes such as having multiple sexual partners, ethnicity, and occupation. Malays had the highest prevalence of recombinant genotypes (n=5: 71.4%). Those who identified themselves as civil servants (n=4: 57.1%) had the highest estimates of recombinant HBV.

DISCUSSION AND CONCLUSION: These results add to our understanding of the diversity of HBV genotypes and the incidence of recombinant genotypes. Identifying demographic variables linked to the development of recombinant genes offers helpful information for targeted preventative methods and public health interventions. The emergence of HBV recombinant genotypes is a strong indicator of HBV genomic evolution which highlights concerns regarding current therapeutic options.

AN EVALUATION OF EXPOSURE TO MICROPLASTICS AND NANOPLASTICS IN GASTROINTESTINAL TRACT ON GUT HEALTH: A SYSTEMATIC REVIEW

Yi Huan Tan¹, Lai Ti Gew¹, Raja Affendi Raja Ali^{1,2}

¹Department of Biological Sciences, School of Medical and Life Sciences, Sunway University, Selangor, Malaysia

²Gut Research Group, Faculty of Medicine, Universiti Kebangsaan Malaysia, Kuala Lumpur, Malaysia

INTRODUCTION: Gastrointestinal tract (GIT)-related diseases are highly prevalent worldwide. Little is known on how microplastics (MPs) and nanoplastics (NPs) are detected and influence various GIT diseases via ingestion of food sources and the associated plastics packaging. Therefore, we aimed to review and evaluate the presence of MPs and NPs in human GIT, and their potential impacts on gut health.

METHODOLOGY: Literature search was performed using Scopus and PubMed from 2004 to June 2023. Only peer-reviewed primary research published in English were retrieved. The eligible studies must use human subjects and/or in vitro cell lines focusing on the detection of MPs and NPs in GIT and its impact on gut health.

RESULTS: A total of 1101 articles were initially evaluated and 54 out of 1101 were included for review. 13 studies reported the presence of MPs and NPs in human GIT, namely colon and liver as well as in the stool. Polypropylene (PP), polycarbonate (PC), high density polyethylene (HDPE), polyethylene terephthalate (PET), and polystyrene (PS) are of the most common types of plastics polymers being detected within GIT. Two studies have identified a higher concentration of MPs and NPs in GIT disease patients as compared to healthy individuals. Another 4 studies also revealed that MPs and NPs significantly induced perturbations in the gut microbiome, potentially leading to GIT diseases. In vitro cell line data that simulated GIT system revealed 37 studies involving MPs and NPs which cause significant effects on cell viability, membrane integrity, apoptosis, oxidative stress, inflammatory response, and genotoxic DNA damage.

CONCLUSION: There is emerging data that indicates microplastics and nanoplastics can be detected in the GIT and have significant adverse effects on our gut health. Clinicians need to be aware of this new concern, which also calls for more collaborative basic, applied, and cross-disciplinary research.

ENDOSCOPIC THERAPY WITH HIGH CONCENTRATION DEXTROSE: A COMEBACK WITH A NEW TWIST

Shahreedhan Shahrani¹, Bo Shen², Ida Normiha Hilmi^{1,3}

¹Department of Internal Medicine, Universiti Malaya Medical Centre, Kuala Lumpur, Malaysia

²Center for Inflammatory Bowel Diseases, University Irving Medical Center/NewYork-Presbyterian/Columbia, New York, NY, USA

³Faculty of Medicine, Universiti Malaya, Kuala Lumpur, Malaysia

OBJECTIVE: Brisk rectal bleeding can be an initial presentation of colorectal cancer. Commonly used endoscopic treatment modalities for primary or metastatic gastrointestinal (GI) tumors, including thermal, mechanical, and injection therapy, suffer from a high risk of recurrent bleeding. Diffuse non-variceal, non-arterial bleeding, albeit common, can be an endoscopic challenge. Intra-lesional injection of high-concentration dextrose has been used in managing variceal bleeding in the past. There have been limited reports of its use in managing other causes of diffuse GI bleeding. We report a case of high-concentration dextrose used as a form of endoscopic intervention for diffuse tumoral bleeding.

RESULT: We report a case of a 61-year-old gentleman, who presented with a background history of altered bowel habits and an acute history of per rectal bleeding. He was hemodynamically stable; however, hemoglobin (Hb) showed a reduction of 3g/L 12.7g/L to 9.9g/L. A colonoscopy was performed, which revealed a fungating, circumferential, friable, and bleeding mass 10cm from the anal verge extending for approximately 10cm. There was diffuse, active oozing of blood from the lesion, even prior to multiple biopsies being taken for histopathological examination (HPE). A decision was made to use dextrose 50% (D50%) to spray on the diffuse mucosal bleeding site after biopsy specimens were taken. A through-the-scope spray catheter (Olympus, tubing length 1650mm, minimum channel size 2.8mm) was used to spray 12ml of D50%. Complete hemostasis was achieved. The patient remained hemodynamically stable throughout the procedure and during the acute observation period. HPE result of the tumor biopsies was reported as moderately differentiated adenocarcinoma. There was no further drop in Hb levels or further episodes of acute bleeding until his semi-emergency surgery for tumor resection was performed 8 weeks later.

CONCLUSION: Endoscopic therapy with high concentration dextrose may be considered as an alternative method for managing diffuse non-variceal, non-arterial bleeding.

PHARYNGEAL AND UPPER ESOPHAGEAL SPHINCTER METRICS: NORMATIVE VALUES FOR THE MALAYSIAN POPULATION, COMPARISON BETWEEN 5ML AND 15ML BOLUS CHALLENGES AND CORRELATION WITH SWALLOWING RISK INDEX

Naveen R^{1,4}, Siti Norhasliza¹, Azliani¹, Nashrulhaq Tagiling^{1,2}, T A Iskandar^{1,2}, Chua K H³, Lee Y Y^{1,2}

¹GI Function and Motility Unit, Hospital Universiti Sains Malaysia, Kubang Kerian, Kelantan, Malaysia

²School of Medical Sciences, Universiti Sains Malaysia, Kubang Kerian, Kelantan, Malaysia

³Faculty of Medicine, Universiti Malaya, Kuala Lumpur, Malaysia

⁴Gastroenterology Unit, Department of Internal Medicine, Hospital Sultanah Bahiyah, Alor Setar, Kedah, Malaysia

BACKGROUND: There is limited normative data of pharyngeal and upper esophageal sphincter (UES) metrics in different population. Likewise, it is unclear the effects on metrics using bolus challenges of 5ml and 15ml. Current study aimed to determine normative data for the Malaysian population, comparing metrics for 5ml and 15ml, and to correlate with the established swallowing risk index (SRI).¹

METHODS: This was a retrospective study involving patients who underwent high resolution impedance esophageal manometry (36 pressure and 8 impedance channels; Laborie, Netherlands) for indication of GERD. Water boluses were given for 5ml and 15ml, 3 swallows each. Metrics derived included velo-meso-pharynx (DCIa, Ia, Aa), hypopharynx (DCIb, Ib, Ab), velo-meso-hypopharynx complex (DCIc) and UES (resting pressure, I, A, IRP 0.2s, IRP 0.8s). For SRI, the metrics were Peak Pressure, IBP, BPT, and DCL. Normative values were reported as mean, 5th and 95th percentile. Comparison between 5ml and 15ml was made using paired t-test, and association with SRI was determined using multiple regression analysis (including age, sex and BMI; reported as hazard ratio or HR, 95% CI). All significance was p<0.05.

RESULTS: Of 80 screened patients, 50 patients from 5ml and 30 patients from 15ml bolus were eventually analysed (mean age 44.2 years, females 72% and obese 16%). The normative values for all metrics is shown (Table 1).

Impedance and admittance metrics for velo-mesopharynx (Ia, Aa) and hypopharynx (Ib, Ab) were significantly higher with 15ml vs. 5ml, but UES (I, A) were lower with 15ml vs 5ml (all P<0.001). In addition, UES IRP 0.2s was significantly lower with 15ml vs. 5ml (p=0.046). For SRI metrics, BPT and DCL were significantly lower with 15ml vs. 5ml (both p<0.02). With regression analysis, metrics significantly associated with SRI included the following: DCIa 15ml (HR 0.01, 95% CI 0.001-0.015; p=0.023), DCIb 15ml (HR 0.01, 95% CI 0.001-0.024, p=0.05), IRP 0.8s 15ml (HR 0.05, 95% CI 0.01-0.08, p=0.07) and female sex (HR 1.9, 95% CI 0.4-3.4, p=0.015).

CONCLUSION: Normative values of pharyngeal, UES and SRI for the Malaysian population are determined. Metrics for impedance, admittance and IRP 0.2s are different between 5ml and 15ml. Values of DCIs of velo-meso-pharynx and hypopharynx and IRP 0.8s derived from 15 ml bolus are predictive of SRI.

REFERENCE

1. Omari T et al. A Method to Objectively Assess Swallow Function in Adults with Suspected Aspiration. *GASTROENTEROLOGY* 2011;**140**:1454-1463

Table 1: Normative Values for Pharyngeal and Upper Esophageal Sphincter Metrics, and Comparison of Metrics between 5ml and 15ml Boluses

	Metrics	Bolus size						p ²
		5mL (n=50)			15mL (n=30)			
		Reference interval ¹		Mean (SD)	Reference interval ¹		Mean (SD)	
		5 th percentile (90% CI)	95 th percentile (90% CI)		5 th percentile (90% CI)	95 th percentile (90% CI)		
Velo-mesopharynx (a)	DCIa	45.2 (29.0 – 82.0)	357.2 (311.0 – 405.0)	176.9 (83.5)	54.9 (51.0 – 76.7)	379.8 (362.7 – 388.0)	174.9 (90.7)	0.627
	Ia	236.7 (204.0 – 254.0)	350.4 (343.0 – 357.0)	289.6 (33.9)	186.7 (185.0 – 197.0)	334.4 (311.0 – 363.0)	249.7 (42.3)	<0.001*
	Aa	2.9 (2.8 – 3.0)	4.2 (4.0 – 4.9)	3.5 (0.4)	3.0 (2.8 – 3.4)	5.4 (5.3 – 5.4)	4.1 (0.6)	<0.001*
Hypo-pharynx (b)	DCIb	13.6 (13.0 – 28.1)	170.1 (157.4 – 193.0)	84.3 (44.3)	20.3 (17.0 – 32.9)	197.5 (188.7 – 198.0)	90.8 (50.7)	0.212
	Ib	227.7 (211.0 – 240.9)	343.0 (328.7 – 355.0)	273.9 (28.6)	177.7 (176.0 – 196.3)	322.0 (281.0 – 372.0)	226.9 (37.8)	<0.001*
	Ab	2.9 (2.9 – 3.3)	4.4 (4.3 – 4.7)	3.7 (0.4)	3.2 (2.7 – 3.8)	5.6 (5.5 – 5.7)	4.5 (0.6)	<0.001*
Velo-meso-hypopharynx complex (c)	DCIc	85.5 (43.0 – 138.0)	449.1 (428.4 – 505.0)	262.3 (107.1)	89.4 (80.0 – 171.0)	471.4 (430.2 – 500.0)	264.9 (98.3)	0.440
UES	Resting Pressure	17.1 (-2.0 – 25.0)	113.6 (99.9 – 146.0)	57.8 (31.1)	11.2 (-2.0 – 25.0)	136.7 (120.2 – 146.0)	57.1 (33.2)	1.000
	I	229.3 (211.0 – 242.4)	332.4 (325.0 – 337.0)	280.9 (30.6)	191.3 (188.0 – 203.0)	264.0 (264.0 – 264.0)	229.7 (22.1)	<0.001*
	A	3.0 (3.0 – 3.1)	4.4 (4.2 – 4.7)	3.6 (0.4)	3.8 (3.8 – 3.9)	5.2 (5.2 – 5.3)	4.4 (0.4)	<0.001*
	IRP 0.2s	-16.0 (-17.35 – 9.90)	11.00 (9.35 – 21.00)	-1.64 (7.96)	-15.9 (-17.00 – 13.45)	20.4 (15.45 – 27.0)	-2.00 (9.90)	0.046*
	IRP 0.8s	-8.45 (-9.00 – 0.00)	46.8 (37.70 – 58.00)	15.48 (14.67)	-11.25 (-14.0 – 1.35)	48.05 (46.95 – 64.0)	12.10 (16.10)	0.426
SRI	Peak Pressure	129.0 (105.0 – 159.9)	445.1 (396.8 – 463.0)	256.4 (87.8)	125.3 (100.0 – 175.3)	455.8 (449.7 – 475.0)	281.7 (93.9)	0.157
	IBP	1.00 (1.00 – 1.00)	22.00 (19.95 – 26.0)	6.48 (6.43)	1.00 (1.00 – 1.00)	20.6 (17.85 – 25.00)	5.07(5.91)	0.790
	BPT	0.60 (0.60 – 0.80)	1.40 (1.40 – 1.50)	1.00 (0.21)	0.70 (0.70 – 0.90)	1.54 (1.40 – 1.70)	1.13 (0.23)	0.018*
	DCL	0.26 (0.20 – 0.30)	0.745 (0.70 – 0.80)	0.48 (0.14)	0.16 (0.11 – 0.31)	0.85 (0.80 – 0.90)	0.58 (0.18)	0.010*
	SRI	0.16 (0.15 – 0.23)	4.83 (4.65 – 5.04)	1.77 (1.70)	0.14 (0.14 – 0.18)	4.48 (4.40 – 4.57)	1.42 (1.49)	0.832

¹90% confidence interval for the double-sided 95% percentile were estimated using bootstrap method (N=1000)

²Paired T-test (n=30)

Legends: DCI; distal contractile integral (mmHg.s.cm), I; impedance (Ω), A; admittance (miliSiemens [mS]), IRP; integrated relaxation pressure (mmHg), UES; upper esophageal sphincter, SRI; swallowing risk index, Peak pressure (mmHg), IBP; Intrabolus Pressure (mmHg), BPT; Bolus Presence Time (s), DCL; Distension Contraction Latency (s); CI; Confidence Interval, SD; Standard Deviation, DCIa; Distal Contractile Integral Velo-mesopharynx (mmHg.s.cm), Ia; Impedance Velo-mesopharynx (Ω), Aa; Admittance Velo-mesopharynx (mS), DCIb, Distal Contractile Integral Hypopharynx (mmHg.s.cm), Ib; Impedance Hypopharynx (Ω), Ab; Admittance Hypopharynx (mS), DCIc; Distal Contractile Integral Velo-meso-hypopharynx complex (mmHg.s.cm).

AN UNUSUAL CASE OF ACHALASIA CARDIA MIMIC: WHY CANT I CUT IT TROUGH?

Nik Muhamad Affendi Nik Arsyad^{1,2}, Shiaw-Hooi Ho², Peng-Choong Lau^{3,4}, Sanjiv Mahadeva²

¹Department of Medicine, International Islamic University Malaysia, Kuantan, Pahang, Malaysia

²Division of Gastroenterology, Department of Medicine, Faculty of Medicine, Universiti Malaya, Kuala Lumpur, Malaysia

³Department of Surgery, Faculty of Medicine, Universiti Malaya, Kuala Lumpur, Malaysia

⁴Pantai Hospital Kuala Lumpur, Kuala Lumpur, Malaysia

Per-oral endoscopic myotomy (POEM) has become the main modality for the treatment of achalasia which is a motility disorder characterised by failure of lower oesophageal sphincter relaxation and loss of oesophageal peristalsis. Herein we report a rare case of achalasia mimic that was diagnosed after a failed POEM procedure.

A 28-year-old lady was referred to our centre with a worsening dysphagia for 6-month. She had a history of dysphagia since she was 3 year-old. Oesophagogastroduodenoscopy showed smooth narrowing at distal oesophagus with no mucosa lesion seen. CT scan showed long segment circumferential thickening of the lower oesophagus without extrinsic compression. Oesophageal manometry showed type-3 achalasia changes (see figure 1).

During POEM procedure, GOJ was determined at 39cm distance from incisor. However, a tight narrowing was encountered at 37cm preventing further tunneling beyond that point. Myotomy-first approach was attempted at this narrowed region but was unsuccessful in loosening the tight narrowing. Nonetheless, myotomy was carried out from 30cm till the point of narrowing. Due to risk of mucosal injury, further procedure was abandoned. The patient was subsequently referred to an UGI surgeon for salvage laparoscopic Heller's myotomy. However, the surgery was unsuccessful and was complicated with a small iatrogenic perforation at distal oesophagus. Eventually, distal oesophagectomy was carried out and the patient made an uneventful recovery. A circumferential hard whitish tissue within the thickened oesophagus was seen at distal oesophagus during the surgery (see figure 2). Histology from the surgical specimen revealed the presence of ectopic cartilage plate and sero-mucinous glands.

This case highlighted the potential of misdiagnosis despite the current standard diagnostic modalities for achalasia cardia. However, ectopic oesophageal cartilage resulting in luminal narrowing in the distal oesophagus is a rare condition which mimics achalasia. EUS assessment may perhaps be helpful in detecting such cartilage tissue within the narrowed oesophagus.

Oral Presentations

- ID 002 GALAD SCORE PERFORMS BETTER IN HEPATOCELLULAR CARCINOMA SCREENING IN COMPARISON WITH ALPHA FETOPROTEIN: A SINGLE-CENTRE, CASE CONTROL STUDY IN MALAYSIA**
Wing Hang Woo¹, Khairul Najmi Muhammad Nawawi^{1,7}, Deborah Chia Hsin Chew^{1,7}, Zhiqin Wong², Azlanudin Azman³, Nur Yazmin Yaacob⁴, Munirah Md Mansor⁵, Raja Affendi Raja Ali^{1,6,7}
¹*Gastroenterology and Hepatology Unit, Department of Medicine, Faculty of Medicine, Universiti Kebangsaan Malaysia, Kuala Lumpur, Malaysia*
²*Pantai Hospital Kuala Lumpur, Kuala Lumpur, Malaysia*
³*Hepatobiliary Unit, Department of Surgery, Faculty of Medicine, Universiti Kebangsaan Malaysia, Kuala Lumpur, Malaysia*
⁴*Department of Radiology, Faculty of Medicine, Universiti Kebangsaan Malaysia, Kuala Lumpur, Malaysia*
⁵*Department of Pathology, Faculty of Medicine, Universiti Kebangsaan Malaysia, Kuala Lumpur, Malaysia.*
⁶*School of Medical and Life Sciences, Sunway University, Selangor, Malaysia*
⁷*GUT Research Group, Faculty of Medicine, Universiti Kebangsaan Malaysia, Kuala Lumpur, Malaysia*
- ID 030 DETERMINING THE EFFICIENCY OF ANTIFOAMING AGENT AND MUCOLYTIC AGENT IN IMPROVING THE VISIBILITY OF GASTRIC MUCOSA IN PATIENTS UNDERGOING OESOPHAGOGASTRODUODENOSCOPY (OGDS) IN SINGLE TERTIARY CENTRE**
Andi Amina Andi Radi¹, Khairul Najmi Muhammad Nawawi¹⁻³, Deborah Chew Chia Hsin¹⁻³, Azmawati Mohammed Nawi², Kok Wei Hao¹
¹*Gastroenterology and Hepatology Unit, Department of Medicine, Faculty of Medicine, Universiti Kebangsaan Malaysia, Kuala Lumpur, Malaysia*
²*Department of Community Health, Faculty of Medicine, Universiti Kebangsaan Malaysia, Kuala Lumpur, Malaysia*
³*GUT Research Group, Faculty of Medicine, Universiti Kebangsaan Malaysia, Kuala Lumpur, Malaysia*
- ID 046 EFFECT OF PROBIOTICS ON INTESTINAL PERMEABILITY AND INFLAMMATORY MARKERS IN PATIENTS WITH CIRRHOSIS REFERRED FOR LIVER TRANSPLANTATION - A RANDOMIZED DOUBLE-BLIND PLACEBO CONTROLLED TRIAL**
Gokulapriya Ramachandran¹, Biju Pottakkat¹, Pazanivel Mohan², Sarbhari Basu³, Balasubramanian V³
¹*Department of Surgical Gastroenterology, Jawaharlal Institute of Postgraduate Medical Education and Research, Dhanvantari Nagar, India*
²*Department of Medical Gastroenterology Jawaharlal Institute of Postgraduate Medical Education and Research, Dhanvantari Nagar, India*
³*Department of Biochemistry, Jawaharlal Institute of Postgraduate Medical Education and Research, Dhanvantari Nagar, India*

Oral Presentations

- ID 059** **MICROBIAL SIGNATURE IN EARLY-ONSET COLORECTAL CANCER IN ASSOCIATION WITH INCREASED SUGAR INTAKE AND MINIMALLY ACTIVE LIFESTYLE**
Siti Maryam Ahmad Kendong^{1,2}, Raja Affendi Raja Ali^{3,4}, Khairul Najmi Muhammad Nawawi^{4,5}, Hajar Fauzan Ahmad^{5,6}, Zairul Azman⁷, Tan Geok Chin⁸, Norfilza Mohd Mokhtar^{1,5}
¹*Department of Physiology, Faculty of Medicine, Universiti Kebangsaan Malaysia, Kuala Lumpur, Malaysia*
²*Department of Basic Medical Sciences, Faculty of Medicine and Health Sciences, Universiti Malaysia Sarawak, Sarawak, Malaysia*
³*School of Medical and Life Sciences, Sunway University, Selangor, Malaysia*
⁴*GUT Research Group, Faculty of Medicine, Universiti Kebangsaan Malaysia, Kuala Lumpur, Malaysia*
⁵*Gastroenterology Unit, Department of Medicine, Faculty of Medicine, Universiti Kebangsaan Malaysia, Kuala Lumpur, Malaysia*
⁶*Department of Industrial Biotechnology, Faculty of Industrial Sciences and Technology, Universiti Malaysia Pabang, Pabang, Malaysia*
⁷*Department of Surgery, Hospital Canselor Tuanku Mubriz, Kuala Lumpur, Malaysia*
⁸*Department of Pathology, Faculty of Medicine, Universiti Kebangsaan Malaysia, Kuala Lumpur, Malaysia*
- ID 060** **FODMAP MEAL CHALLENGE TEST: A NOVEL INVESTIGATION TO PREDICT RESPONSE TO LOW-FODMAP DIET IN PATIENTS WITH NON-CONSTIPATING IRRITABLE BOWEL SYNDROME**
Uday C Ghoshal¹, Uzma Mustafa¹, Subhra K Mukhopadhyay²
¹*Department of Gastroenterology, Sanjay Gandhi Postgraduate Institute of Medical Sciences, Burdwan, West Bengal, India*
²*Department of Microbiology, The University of Burdwan, Burdwan, West Bengal, India*
- ID 061** **MEASUREMENT OF FECAL SHORT CHAIN FATTY ACID PRODUCING BACTERIA AT 6 MONTHS POST VEDOLIZUMAB TREATMENT SERVES AS POTENTIAL POSITIVE PREDICTIVE BIOMARKER IN PATIENTS WITH INFLAMMATORY BOWEL DISEASE**
Low Wei Hong¹, Raja Affendi Raja Ali^{2,4}, Hajar Fauzan Ahmad^{3,4}, Norfilza M Mokhtar^{1,4}
¹*Department of Physiology, Faculty of Medicine, Universiti Kebangsaan Malaysia, Kuala Lumpur, Malaysia*
²*School of Medicine and Life Sciences, Sunway University, Selangor, Malaysia*
³*Faculty of Industrial Sciences and Technology, Universiti Malaysia Pabang, Pabang, Malaysia*
⁴*GUT Research Group, Faculty of Medicine, Universiti Kebangsaan Malaysia, Kuala Lumpur, Malaysia*

GALAD SCORE PERFORMS BETTER IN HEPATOCELLULAR CARCINOMA SCREENING IN COMPARISON WITH ALPHA FETOPROTEIN: A SINGLE-CENTRE, CASE CONTROL STUDY IN MALAYSIA

Wing Hang Woo¹, Khairul Najmi Muhammad Nawawi^{1,7}, Deborah Chia Hsin Chew^{1,7}, Zhiqin Wong², Azlanudin Azman³, Nur Yazmin Yaacob⁴, Munirah Md Mansor⁵, Raja Affendi Raja Ali^{1,6,7}

¹Gastroenterology and Hepatology Unit, Department of Medicine, Faculty of Medicine, Universiti Kebangsaan Malaysia, Kuala Lumpur, Malaysia

²Pantai Hospital Kuala Lumpur, Kuala Lumpur, Malaysia

³Hepatobiliary Unit, Department of Surgery, Faculty of Medicine, Universiti Kebangsaan Malaysia, Kuala Lumpur, Malaysia

⁴Department of Radiology, Faculty of Medicine, Universiti Kebangsaan Malaysia, Kuala Lumpur, Malaysia

⁵Department of Pathology, Faculty of Medicine, Universiti Kebangsaan Malaysia, Kuala Lumpur, Malaysia.

⁶School of Medical and Life Sciences, Sunway University, Selangor, Malaysia

⁷GUT Research Group, Faculty of Medicine, Universiti Kebangsaan Malaysia, Kuala Lumpur, Malaysia

BACKGROUND: Hepatocellular carcinoma (HCC) carries one of the highest cancer related mortality in Malaysia. The detection rate for early HCC remains low, despite biannual serum α -fetoprotein (AFP) and ultrasound liver. To overcome this inadequacy, GALAD score was developed which is a statistical model that incorporates AFP, lens culinaris agglutinin-reactive μ -fetoprotein (AFP-L3) and protein induced by vitamin K antagonist-II (PIVKA-II) along with the patient's gender and age to predict the probability of HCC. We aim to compare the performance of GALAD score with serum AFP, AFP-L3 and PIVKA-II in screening HCC.

METHODS: A single-center, case-control study enrolled 44 patients with HCC and 179 cirrhotic patients (as controls). The serum levels of AFP, AFP-L3 and PIVKA-II were measured using the μ TASWako i30 automated immunoanalyzer. Receiver operating characteristic curve (ROC) was used to compare the performance of GALAD score versus serum AFP, AFP-L3 and PIVKA-II.

RESULTS: Of 44 HCC [22(50%) HBV, 10(22.7%) MAFLD, 6(13.7%) HCV, 3(6.8%) had alcohol-related liver disease and others 3(6.8%)] and HCC tumor staging according to Barcelona Clinic Liver Cancer (BCLC) [7(16%) BCLC 0/A, 11(25%) BCLC B, 11(25%) BCLC C and 15(34%) BCLC D] were studied. The AUC of the GALAD score was 0.94 (95% confidence interval (CI):0.90–0.98, $p < 0.0001$) which was the highest compared to AFP (0.89), AFP-L3 (0.84) and PIVKA-II (0.88) for detection of HCC. The sensitivity and specificity in detecting any stage of HCC for GALAD score (84.1%/93.8%) at standard cut-off of -0.63 and (88.6%/92.2%) at its best cut-off value of -1.035 whereas AFP (79.5%/92.2%), AFP-L3 (59.1%/94.9%) and PIVKA-II (79.5%/84.9%). The sensitivity of GALAD score was 100% in early stage of HCC (BCLC 0/A).

CONCLUSION: The GALAD score outperformed AFP, AFP-L3 and PIVKA-II for HCC screening, especially in the early stage. Hence, it will facilitate early detection and eventually improve HCC patients' survival rate.

DETERMINING THE EFFICIENCY OF ANTIFOAMING AGENT AND MUCOLYTIC AGENT IN IMPROVING THE VISIBILITY OF GASTRIC MUCOSA IN PATIENTS UNDERGOING OESOPHAGOGASTRODUODENOSCOPY (OGDS) IN SINGLE TERTIARY CENTRE

Andi Amina Andi Radi¹, Khairul Najmi Muhammad Nawawi¹⁻³, Deborah Chew Chia Hsin¹⁻³, Azmawati Mohammed Nawi², Kok Wei Hao¹

¹Gastroenterology and Hepatology Unit, Department of Medicine, Faculty of Medicine, Universiti Kebangsaan Malaysia, Kuala Lumpur, Malaysia

²Department of Community Health, Faculty of Medicine, Universiti Kebangsaan Malaysia, Kuala Lumpur, Malaysia

³GUT Research Group, Faculty of Medicine, Universiti Kebangsaan Malaysia, Kuala Lumpur, Malaysia

OBJECTIVES: A comprehensive oesophagogastroduodenoscopy is limited when there is an accumulation of mucous and bubbles in the detection of early gastric cancer. This study was performed to determine the improvement of endoscopic visualization by using premedication agents.

METHODOLOGY: This randomized, double-blinded, placebo-controlled trial had three allocation arms: A: water (W, control), B: water + 100mg Simethicone(W+S1), and C: water + S1 + 600mg N-acetylcysteine (W+S1+NAC600). The 100mls of the solution was consumed 20 minutes before OGDS. A gastric total visibility score (TVS) was used to assess endoscopic visualization in four parts of the stomach as the primary outcome. Adequate visibility was defined as a total visibility score (TVS) of less than 7 points (AV). Secondary outcomes included procedure time, positive endoscopic findings and adverse effects.

RESULTS: 222 eligible patients were randomized. Each allocation arm had 74 patients (n=74). Dyspepsia with 55.9% of cases was the major indication for OGDS. Allocation arms B and C had a high frequency of AV (82.4% and 87.8% respectively, $p < 0.001$) and a median gastric TVS of [5(4-6), $p < 0.001$]. The Fleiss' multi-rater kappa for interobserver agreement showed slight agreement ($\kappa = 0.073$). Allocation arms B and C had the lowest incidence of simethicone flushing needed ($p < 0.001$). Allocation arm C had higher positive endoscopy results (90.5%) than A and B (58.1% and 82.4% respectively) with p -value < 0.001 yet no significant difference in procedure time. There were no documented significant side effects with the usage of premedication agents.

DISCUSSION AND CONCLUSION: In view of similar efficiency, we conclude that usage of simethicone alone as a premedication agent benefits in better endoscopic visualization. It should be considered as one of the recommendations for pre-OGDS preparation in Malaysia as it is more practical, cost-effective and readily available.

Keywords: Oesophagogastroduodenoscopy (OGDS), simethicone, N-acetylcysteine (NAC), gastric total visibility score (TVS)

EFFECT OF PROBIOTICS ON INTESTINAL PERMEABILITY AND INFLAMMATORY MARKERS IN PATIENTS WITH CIRRHOSIS REFERRED FOR LIVER TRANSPLANTATION - A RANDOMIZED DOUBLE-BLIND PLACEBO CONTROLLED TRIAL

Gokulapriya Ramachandran¹, Biju Pottakkat¹, Pazanivel Mohan², Sarbhari Basu³, Balasubramaniyan V³

¹Department of Surgical Gastroenterology, Jawaharlal Institute of Postgraduate Medical Education and Research, Dhanvantari Nagar, India

²Department of Medical Gastroenterology Jawaharlal Institute of Postgraduate Medical Education and Research, Dhanvantari Nagar, India

³Department of Biochemistry, Jawaharlal Institute of Postgraduate Medical Education and Research, Dhanvantari Nagar, India

BACKGROUND: Gut dysbiosis and bacterial translocation are significantly associated with the pathogenesis of cirrhosis and its complications. Microbiota-targeted therapy like probiotics may remodel intestinal microbial communities and restores barrier function and immunomodulation thus decreasing complications in cirrhotic patients.

AIM: We aimed to study the effect of 6 weeks oral supplementation of probiotics (VSL#3) on gut permeability and inflammatory markers in patients with cirrhosis referred for liver transplantation.

METHODS: A randomized, placebo-controlled, double-blind study was conducted among 215 patients with cirrhosis referred for liver transplantation between July 2021 - October 2022. Patients were screened for cirrhosis and were randomized into two groups to receive either probiotics (VSL#3) or placebo, twice a day for 6 weeks. Each arm had 107 patients and baseline characteristics were noted. Gut permeability and inflammatory markers in serum samples were assessed before and after the intervention.

RESULTS: In cirrhotic patients, the levels of intestinal permeability markers Zonula occludin -1 (ZO-1) was reduced significantly ($p < 0.01$) but occludin levels was insignificantly decreased ($p = 0.49$) following probiotics treatment compared to placebo. Moreover, zonulin concentration was insignificantly elevated both in placebo and probiotic groups. Inflammatory marker such as hs-CRP and IL-1beta were significantly decreased ($p < 0.5$ and $p < 0.01$, respectively) following VSL#3 supplementation whereas decreased TNF alpha in probiotic group was not statistically significant ($p = 0.071$). Child Turcotte Pugh score improved significantly compared to pre therapy (8.04 ± 0.196 vs 7.30 ± 0.24 ; $p < 0.0001$), and MELD score remained the same before and after the intervention (7.98 ± 0.213 vs 7.97 ± 0.27 ; $p = < 0.867$). No adverse events was observed due to probiotic intake.

CONCLUSIONS: Probiotic VSL#3 supplementation is safe and well tolerated in patients with cirrhosis. By decreasing the levels of intestinal permeability markers and inflammatory markers, probiotics may help to reduce inflammation which may further decrease the complications in patients with cirrhosis.

MICROBIAL SIGNATURE IN EARLY-ONSET COLORECTAL CANCER IN ASSOCIATION WITH INCREASED SUGAR INTAKE AND MINIMALLY ACTIVE LIFESTYLE

Siti Maryam Ahmad Kendong^{1,2}, Raja Affendi Raja Ali^{3,4}, Khairul Najmi Muhammad Nawawi^{4,5}, Hajar Fauzan Ahmad^{5,6}, Zairul Azman⁷, Tan Geok Chin⁸, Norfilza Mohd Mokhtar^{1,5}

¹Department of Physiology, Faculty of Medicine, Universiti Kebangsaan Malaysia, Kuala Lumpur, Malaysia

²Department of Basic Medical Sciences, Faculty of Medicine and Health Sciences, Universiti Malaysia Sarawak, Sarawak, Malaysia

³School of Medical and Life Sciences, Sunway University, Selangor, Malaysia

⁴GUT Research Group, Faculty of Medicine, Universiti Kebangsaan Malaysia, Kuala Lumpur, Malaysia

⁵Gastroenterology Unit, Department of Medicine, Faculty of Medicine, Universiti Kebangsaan Malaysia, Kuala Lumpur, Malaysia

⁶Department of Industrial Biotechnology, Faculty of Industrial Sciences and Technology, Universiti Malaysia Pahang, Pahang, Malaysia

⁷Department of Surgery, Hospital Canselor Tuanku Muhriz, Kuala Lumpur, Malaysia

⁸Department of Pathology, Faculty of Medicine, Universiti Kebangsaan Malaysia, Kuala Lumpur Malaysia

Colorectal cancer is commonest cancer among men in Malaysia and the incidence of early-onset colorectal cancer cases (EOCRC) (≤ 50 years old) has risen steadily in Malaysia. Most EOCRC cases were diagnosed at an advanced stage with unique molecular features. However, the cause of the increase in EOCRC and the relationship with specific microbial signature and lifestyle is unknown.

OBJECTIVE: This study aimed to investigate microbial composition, dietary intake and physical activity in EOCRC patients.

METHODOLOGY: Tissue samples from patients with EOCRC, late-onset colorectal cancer (LOCRC), control:) were collected for DNA extraction and subjected for 16S sequencing. Archived EOCRC samples were analysed using immunohistochemical (IHC) screening of Lynch-associated genes. The patients' dietary records were evaluated using Nutritionist Pro, while physical activity data was analysed with the International Physical Activity Questionnaire (IPAQ) analysis.

RESULTS: A total of 80 tissues from 76.5% Malay, 20.2% Chinese and 3.3% Indian patients with (EOCRC: n=20, late-onset colorectal cancer (LOCRC): n=11, control: n=18) were studied. Alpha and beta diversity analysis revealed significant microbial difference ($p < 0.05$) in EOCRC and LOCRC as compared to controls. LEfSe analysis identified *Parvimonas micra* and *Fillifactor alocis* as core gut microbiota in EOCRC. According to IHC findings, only 2.5% of patients have Lynch syndrome. Dietary intake analysis revealed that the EOCRC group consumed significantly high sugar intake as compared to

controls ($p < 0.05$). According to IPAQ analysis, the majority of both EOCRC and LOCRC patients were only minimally active (53.83% and 38.46% respectively) compared to the controls.

DISCUSSION AND CONCLUSION: In Malaysia, *Parvimonas micra* and *Fillifactor alocis* are two oral pathobionts that were highly abundant and serve as unique microbial signature in EOCRC. They are strongly associated with high-sugar diet and sedentary lifestyle among patients with EOCRC.

FODMAP MEAL CHALLENGE TEST: A NOVEL INVESTIGATION TO PREDICT RESPONSE TO LOW-FODMAP DIET IN PATIENTS WITH NON-CONSTIPATING IRRITABLE BOWEL SYNDROME

Uday C Ghoshal¹, Uzma Mustafa¹, Subhra K Mukhopadhyay²

¹Department of Gastroenterology, Sanjay Gandhi Postgraduate Institute of Medical Sciences, Burdwan, West Bengal, India

²Department of Microbiology, The University of Burdwan, Burdwan, West Bengal, India

BACKGROUND: Though a low-FODMAP diet improves 50% irritable bowel syndrome (IBS) patients, regional dietary variations, vegetarianism, and long-term nutritional consequences challenge its implementation. We aimed developing a FODMAP-meal challenge test (FMCT). We prospectively studied whether, (i) high- than low-FODMAP foods produce more breath H₂ among IBS patients than controls, (ii) post-meal symptoms relate to breath H₂, and (iii) novel FMCT predicts response to low-FODMAP diet?

METHODS: 40 Rome III IBS and 20 healthy controls underwent an eight-hour H₂ breath test following a low- (rice, brinjal, corn, and banana [450 Kcal]) and a high-FODMAP meal (wheat, kidney bean, pulse, and curd [450 Kcal]). Breath H₂ (every 15-minutes) and symptoms following low- and high-FODMAP meals were recorded. IBS-symptom severity scores were recorded every month for 3-months on low-FODMAP diet.

RESULTS: 40 Rome III IBS (19 Rome IV-positive) were comparable to 20 controls in age and gender. IBS patients (n=39 excluding one H₂ non-producer) and controls produced more breath H₂ after high- (greater in IBS) than low-FODMAP meal. Post-meal symptoms were commoner in IBS (4/40 [10%] and 27/40 [67.5%] IBS with low- and high-FODMAP, respectively [p<0.00001]; none in healthy). IBS patients developing post-high-FODMAP meal symptoms produced greater H₂ (18 PPM [IQR 10.5 to 23] vs. 6 [0 to 7.2]; p<0.001). A positive FMCT (breath H₂ ≥ 10 PPM above basal with symptoms following high-FODMAP food) had sensitivity, specificity, and diagnostic accuracy of 78.6%, 66.6%, and 75.6%, respectively to predict low-FODMAP diet response.

CONCLUSIONS: The novel FMCT predicts response to a low-FODMAP diet in IBS.

MEASUREMENT OF FECAL SHORT CHAIN FATTY ACID PRODUCING BACTERIA AT 6 MONTHS POST VEDOLIZUMAB TREATMENT SERVES AS POTENTIAL POSITIVE PREDICTIVE BIOMARKER IN PATIENTS WITH INFLAMMATORY BOWEL DISEASE

Low Wei Hong¹, Raja Affendi Raja Ali^{2,4}, Hajar Fauzan Ahmad^{3,4}, Norfilza M Mokhtar^{1,4}

¹Department of Physiology, Faculty of Medicine, Universiti Kebangsaan Malaysia, Kuala Lumpur, Malaysia

²School of Medicine and Life Sciences, Sunway University, Selangor, Malaysia

³Faculty of Industrial Sciences and Technology, Universiti Malaysia Pahang, Pahang, Malaysia

⁴GUT Research Group, Faculty of Medicine, Universiti Kebangsaan Malaysia, Kuala Lumpur, Malaysia

OBJECTIVES: Little is known about the association between gut dysbiosis, fecal short-chain fatty acid (fSCFA), dietary intake and vedolizumab (VDZ) therapy response in patients with inflammatory bowel disease (IBD).

METHODOLOGY: A prospective cohort study of IBD patients receiving VDZ at week 0 and week 24 was conducted with healthy controls. Stool samples were collected for 16S rRNA amplicon sequencing and gas chromatography mass spectrometry for gut microbiota profiling and metabolites. Macronutrients were analyzed using Nutritionist Pro based on a 2-week dietary record. Clinical response post VDZ therapy were measured using Harvey-Bradshaw Index (HBI) for Crohn's disease (CD) and Ulcerative Colitis Disease Activity Index (UCDAI) for ulcerative colitis (UC) patients. Correlation analysis between microbiome, dietary and fSCFA was performed using R studio.

RESULTS: A total of 31 IBD patients (pre-VDZ therapy; CD = 16, UC =15: post-VDZ therapy; CD= 7, UC = 3) and 20 controls were studied. IBD patients had significantly higher fat and lower carbohydrate intakes than controls ($p<0.001$). Alpha and beta diversity revealed distinct microbial profiles in IBD patients as compared to controls ($p<0.001$). Linear discriminant analysis effect size identified higher abundance of the *Bacteroides* phylum in IBD as compared to controls ($p<0.001$). *Acidaminococcus Intestini* was dominated in pre-VDZ as compared to post-VDZ patients. VDZ responders had significantly higher abundance of fSCFA-producing bacteria; *Bifidobacterium Kashiwanohense* and genus *Blautia_A*. Among VDZ responders, a positive correlation was observed between *Parasutterella Excrementihominis* and fSCFA propionate but negatively correlation with carbohydrate, fiber, and fat intakes.

DISCUSSION AND CONCLUSION: IBD patients who have responded with VDZ have a high abundance of fSCFA-producing bacteria; *Bifidobacterium Kashiwanohense*, genus *Blautia_A* and *Parasutterella Excrementihominis* that are positively correlated with propionate. This finding could potentially serve as positive predictors of responsiveness to VDZ therapy in IBD patients. However, further research with a sizable sample size is required.

Keywords: Inflammatory Bowel Disease, Vedolizumab, Gut Microbiota, SCFA, Macronutrients

Poster Presentations

- ID 004** **AZATHIOPRINE INDUCED ALOPECIA TOTALIS: A RARE ADVERSE EVENT, AS AN EARLY CLINICAL MARKER OF MYELOTOXICITY**
Ruben Skantha, Rasnaizam Rasdi, Azlida Che Aun, Choong Yeong Sooi
Hospital Tengku Ampuan Afzan, Pabang, Malaysia
- ID 005** **DEMOGRAPHICS STUDY AND PREDICTORS OF HOSPITALISATION AMONG LIVER CIRRHOSIS PATIENTS IN HOSPITAL SULTANAH NORA ISMAIL**
Amin Mohamed, Rajendran Jeevakanthi, Kien Ting Liu, Murugesu Kalaivani, Sadli Salwa, Nazri Hafiz Muhammad
¹*Gastroenterology Clinic, Hospital Sultanah Nora Ismail, Batu Pabat, Johor, Malaysia*
²*National Heart Association of Malaysia, Kuala Lumpur, Malaysia*
- ID 006** **UNREVEALING THE ROLE OF SIX VEGFA POLYMORPHISMS ON THE SUSCEPTIBILITY OF HEPATOCELLULAR CARCINOMA (HCC) AND RECURRENCE: AN UPDATED SYSTEMATIC REVIEW AND META ANALYSIS OF 11 STUDIES**
Dwijo Anargha Sindhughosa, I Ketut Mariadi
Division of Gastroenterology and Hepatology, Internal Medicine Department, Faculty of Medicine, Udayana University/Prof. Dr. I.G.N.G. Ngoerah Hospital, Denpasar, Bali, Indonesia
- ID 007** **BENIGN RECURRENT INTRAHEPATIC CHOLESTASIS (BRIC): A CASE REPORT IN MALAYSIA**
Thomas Koshy, Ahmad Syahidan Yusoff, Ravin Ponnisamy, Nurul Atiah, Syuhada Dan binti Adnan
Gastroenterology & Hepatology Unit, Sultanah Nur Zahirah Hospital, Terengganu, Malaysia
- ID 008** **RECOGNITION OF ASYMPTOMATIC EARLY-STAGE HEPATIC WILSON DISEASE WITH LIMITED RESOURCES-BLESSING IN DISGUISE IN THE COVID ERA**
S Y Ngeoh, W C Liew, S L Lee, M S Firdaus
Hospital Sultanah Aminah, Johor, Malaysia
- ID 009** **CASE OF LATE-ONSET HEPATITIS B FLARE POST RITUXIMAB**
S Y Ngeoh, W C Liew, S L Lee, M S Firdaus
Hospital Sultanah Aminah, Johor, Malaysia
- ID 010** **3 CONCURRENT TUMOURS IN A PATIENT WITH NAFLD CIRRHOSIS**
T M Yeo, Norhaniza Bahar, Nik Razima Wan Ibrahim, Rosaida Hj Mohd Said
Hospital Sultan Idris Shah Serdang, Selangor, Malaysia
- ID 011** **CASE REPORT: UNCOMMON ASSOCIATION BETWEEN HEPATITIS C VIRUS (HCV) AND GUILLAIN-BARRE SYNDROME (GBS) - EXPLORING THE POTENTIAL AS AN EXTRAHEPATIC MANIFESTATION**
Kay-Keng Tan, Tse-Hui Chow
Gastroenterology Unit, Medical Department, Hospital Raja Permaisuri Bainun Ipoh, Perak, Malaysia

Poster Presentations

- ID 012 ATYPICAL PRESENTATION OF AUTOIMMUNE PANCREATITIS**
Ying Zhuang Ng¹, Yuan Ye Beh¹, Mohamad Fadli Abd Rahman¹, Kuang Kiat Kiew²
¹*Hospital Pulau Pinang, Penang, Malaysia*
²*Hospital Sultanah Bahiyah, Kedah, Malaysia*
- ID 013 A RARE CHOLESTATIC MANIFESTATION OF HEPATIC SINUSOIDAL T CELL LYMPHOMA**
S C Khoo, S D Adnan
Hospital Sultanah Nur Zahirah, Terengganu, Malaysia
- ID 014 TREATMENT OUTCOME OF TENOFOVIR DISOPROXIL FUMARATE (TDF) AMONG CHRONIC HEPATITIS B PATIENTS: A RETROSPECTIVE REVIEW IN HOSPITAL SULTANAH NUR ZAHIRAH (HSNZ)**
Ahmad Syahidan Yusoff, Abdul Wafiy, Syuhada Dan
Hospital Sultanah Nur Zahirah, Terengganu, Malaysia
- ID 015 CHOLANGIOSCOPY-GUIDED LITHOTRIPSY OF A BILE DUCT STONE THROUGH A PERCUTANEOUS T-TUBE TRACT**
Prakash Narayanan, K C Tan, T S Lee
Hepatology Department, Hospital Selayang, Selangor, Malaysia
- ID 016 SUBOPTIMAL RESPONSE TO TENOFOVIR ALAFENAMIDE (TAF) IN 2 CHRONIC HBV PATIENTS: A CASE REPORT**
Noor Aliza Abd Mutalib¹, Leong Chee Loon²
¹*Gastroenterology Unit, Medical Department, Hospital Kuala Lumpur, Kuala Lumpur, Malaysia*
²*Infectious Disease Unit, Medical Department, Hospital Kuala Lumpur, Kuala Lumpur, Malaysia*
- ID 017 CLINICAL AUDIT OF ENDOSCOPIC RETROGRADE CHOLANGIOPANCREATOGRAPHY (ERCP) IN HOSPITAL KUALA LUMPUR**
Soo Man Jun, Lalitha Shanmugam, Rinosyah Palaniappan, Daniel Ching, Noor Aliza Mutalib
Department of Internal Medicine, Hospital Kuala Lumpur, Kuala Lumpur, Malaysia
- ID 018 DIAGNOSTIC DILEMMA: AN UNUSUAL CASE OF TREATED TUBERCULOSIS OF THE GUT TURNED OUT TO BE CROHN'S DISEASE WITH GYNAECOLOGICAL INVOLVEMENT**
Sheng Tian Ong, Yuan Ye Beh, Ian Xiang Yuan Ch'ng, Ying Zhuang Ng, Mohamad Fadli bin Abd Rahman
Department of Gastroenterology and Hepatology, Hospital Pulau Pinang, Penang, Malaysia

Poster Presentations

- ID 019** **STEPS TO DELIVERING A COMPREHENSIVE GASTROENTEROLOGY AND HEPATOLOGY SERVICE IN A NEW HOSPITAL: A SINGLE CENTRE EXPERIENCE**
M Y Yap¹, Vince¹, S Y Lau^{1,2}
¹*Hospital Sultan Abdul Aziz Shah, Selangor, Malaysia*
²*University Putra Malaysia, Selangor, Malaysia*
- ID 020** **A REAL-WORLD EVIDENCE (RWE) STUDY TO EVALUATE THE EFFECTIVENESS OF PROTON PUMP INHIBITORS (PPIS) OMEPRAZOLE AND PANTOPRAZOLE FOR SYMPTOMATIC RELIEF OF GASTRO-ESOPHAGEAL REFLUX DISEASE (GERD) / ACID PEPTIC DISEASE (APD)**
Priti Panchal¹, Sandip Rungta², Debasis Basu³, Shivaji Rao⁴, Anish Kolly⁵, Ritwik Banerjee⁶, Krishna C V⁶, Rahul Rathod⁶, Bhavesh P Kotak⁶, Gauri Dhanaki⁶
¹*Thunga Hospital, Mumbai, Maharashtra, India*
²*AMRI Hospital, Kolkata, West Bengal, India*
³*Apollo Multispecialty Hospital, Kolkata, West Bengal, India*
⁴*Apollo Hospital, Bangalore, Karnataka, India*
⁵*Jaya Bhushan Hospital, Hyderabad, Telangana, India*
⁶*Dr Reddy's Laboratories Ltd, Hyderabad, India*
- ID 021** **A PIONEERING CASE OF ENDOSCOPIC ASSISTED HIGH RESOLUTION ANOSCOPY FOR DETECTION OF DYSPLASTIC LESIONS IN ANAL EPITHELIUM - UNVEILING THE GASTROENTEROLOGIST'S PERCEPTIVE**
Ruben Skantha, Ahmad Faizal Rakawi, Dzawani Muhammad, Rasnaizam Rasdi, Azlida Che Aun, Choong Yeong Sooi
Hospital Tengku Ampuan Afzan, Pahang, Malaysia
- ID 023** **PREVALENCE OF COLORECTAL NEOPLASIA IN PATIENTS WITH CHRONIC KIDNEY DISEASE UNDERGOING COLORECTAL CANCER SCREENING: A SINGLE CENTRE EXPERIENCE IN MALAYSIA**
Mohd Hasnul Helmi Zulkifli¹, Thevaraajan Jayaraman¹, Muhammad Iqbal Abdul Hafidz², Muhammad Ilham Abdul Hafidz¹, Rafiz Abdul Rani¹, Mohd Shahril Ahmad Saman³, Chandromouli Annamalai¹
¹*Gastroenterology Unit, Department of Internal Medicine, Faculty of Medicine, Universiti Teknologi Mara, Selangor, Malaysia*
²*Nephrology Unit, Department of Internal Medicine, Faculty of Medicine, Universiti Teknologi Mara, Selangor, Malaysia*
³*Department of Public Health Medicine, Faculty of Medicine, Universiti Teknologi Mara, Selangor, Malaysia*
- ID 024** **REBLEEDING RISK IN UPPER GASTROINTESTINAL BLEEDING: A SINGLE CENTER STUDY**
G H Chan, P Nagaratnam, M F Limun, N A Bakar
Hospital Raja Perempuan Zainab II, Kubang Kerian, Kelantan, Malaysia
- ID 025** **AN AUDIT OF REFERRAL FOR ANEMIA WITHOUT APPARENT GI BLEEDING IN A TERTIARY PUBLIC HOSPITAL**
CY Wong, L T Gew, P B C Philip, A M Noor Aliza
Hospital Kuala Lumpur, Kuala Lumpur, Malaysia

Poster Presentations

- ID 027 A CASE OF POST-COLONOSCOPY COLORECTAL CANCER: THE IMPORTANCE OF QUALITY COLONOSCOPY**
A Muhamad¹, MYYap¹, SY Lau^{1,2}
¹Hospital Sultan Abdul Aziz Shah, Selangor, Malaysia
²University Putra Malaysia, Selangor, Malaysia
- ID 028 A RARE CASE OF ACUTE LIVER FAILURE IN SEVERE DENGUE**
Jeshwina J, Jasvinee S, W Abdullah W Z A, Shahril N S
Hospital Putrajaya, Wilayah Persekutuan Putrajaya, Malaysia
- ID 029 COMPARATIVE ANALYSIS OF SENSITIVITY AND SPECIFICITY OF ULTRASOUND FINDINGS OF DILATED INTRAHEPATIC DUCT IN DIAGNOSING CHOLEDOCHOLITHIASIS: A COMPARISON WITH ENDOSCOPIC ULTRASOUND**
K G Lew, L T Gew
Hospital Kuala Lumpur, Kuala Lumpur, Malaysia
- ID 031 INITIAL SUCCESS EXPERIENCE IN EUS INTERVENTION AS SALVAGE THERAPY FOR ACUTE GASTRIC VARICEAL BLEEDING: A SINGLE CENTER EXPERIENCE**
Cha Chee Tan, Lai Teck Gew, Chung Yeow Wong, Philip Pang, Noor Aliza Binti Abd Mutalib
Hospital Kuala Lumpur, Kuala Lumpur, Malaysia
- ID 032 PRECUT VS CONVENTIONAL SPHINCTEROTOMY: AN AUDIT ON BLEEDING COMPLICATION AND RATE OF SUCCESS ON BILE DUCT CANNULATION IN HOSPITAL KUALA LUMPUR**
Cha Chee Tan, Lai Teck Gew, Chee Men Lu, Ken Guan Lew, Chung Yeow Wong, Philip Pang, Noor Aliza Binti Abd Mutalib
Hospital Kuala Lumpur, Kuala Lumpur, Malaysia
- ID 034 THE PREVALENCE OF CLOSTRIDIUM DIFFICILE INFECTION IN THE TERTIARY CARE CENTER IN SARAWAK**
Nurul Husna Baharudin, Victoria Kok Shinq Ling, Alisa Hanum Binti Arba'eni @ Arbaen
Gastroenterology Unit, Department of Internal Medicine, Sarawak General Hospital, Kuching, Sarawak, Malaysia
- ID 035 RECURRENT HEPATIC HYDROTHORAX, A DISEASE ENTITY THAT LACKS IT'S MUCH NEEDED RECOGNITION AND MANAGEMENT STRATEGIES**
R Thivaganesh, W A Wan Zaharatul Ashikin
Hospital Putrajaya, Wilayah Persekutuan Putrajaya, Malaysia

Poster Presentations

- ID 036** **PANCREATIC PSEUDOCYST DRAINAGE WITH HOT-AXIOS STENT IN ASYMPTOMATIC PREGNANT LADY: OUR EDGY EXPERIENCE**
Mohd Noor Nashriq Umar Othman¹, Kok Wei Hao¹, Ngiu Chai Soon², Azlanudin Azman³, Ani Amelia Zainuddin⁴, Yazmin Yaacob⁵, Khairul Najmi Muhammad Nawawi¹
¹Gastroenterology Unit, Department of Medicine, Faculty of Medicine, Universiti Kebangsaan Malaysia, Kuala Lumpur, Malaysia
²Gastroenterology Unit, Cardiac Vascular Sentral Kuala Lumpur, Kuala Lumpur, Malaysia
³Hepatopancreatobiliary Surgery, Department of Surgery, Faculty of Medicine, Universiti Kebangsaan Malaysia, Kuala Lumpur, Malaysia
⁴Department of Obstetrics and Gynecology, Faculty of Medicine, Universiti Kebangsaan Malaysia, Kuala Lumpur, Malaysia
⁵Department of Radiology, Faculty of Medicine, Universiti Kebangsaan Malaysia, Kuala Lumpur, Malaysia
- ID 037** **THE PREVALENCE OF HELICOBACTER PYLORI INFECTION IN MULTIRACIAL COMMUNITY AT HOSPITAL SULTANAH AMINAH, JOHOR BAHRU**
S Y Ngeoh, W C Liew, S L Lee, M S Firdaus
Hospital Sultanah Aminah, Johor Bahru, Johor, Malaysia
- ID 038** **MANAGEMENT OF HEPATIC SARCOIDOSIS: A SYSTEMATIC REVIEW**
Ram Prasad Sinnanaidu¹, Vikneshwaran Chandra Kumar², Ranita Hisham Shunmugam³, Sanjiv Mahadeva¹
¹Gastroenterology Unit, Medical Department, Universiti Malaya Medical Centre, Kuala Lumpur, Malaysia
²Medical Department, Hospital Tuanku Ja'afar Seremban, Negeri Sembilan, Malaysia
³Universiti Malaya Library, Universiti Malaya, Kuala Lumpur, Malaysia
- ID 039** **A CASE SERIES OF EARLY ENDOSCOPIC THERAPY FOR UPPER GASTROINTESTINAL BLEEDING IN DENGUE FEVER**
Tian Ming Yeo, Noor Purdah Abdul Kadir, Nik Razima Wan Ibrahim, Norhaniza Bahar, Ee Keng Lim, Rosaida Hj Mohd Said
Hospital Sultan Idris Shah Serdang, Selangor, Malaysia
- ID 040** **FINDING OF RELOOK/SECOND GASTROSCOPE WITHIN 1 WEEK AFTER THE FIRST HEMOSTASIS IN PATIENT WITH NON-VARICEAL UGIB: A RETROSPECTIVE REVIEW**
CY Wong, L T Gew, P B C Philip, A M Noor Aliza
Hospital Kuala Lumpur, Kuala Lumpur, Malaysia
- ID 041** **TRAINING MODELS FOR ADVANCED ENDOSCOPIC PROCEDURES IN A MULTI RACIAL SETTING**
P Nagaratnam^{1,2}, Hari Suthan¹, Gew L T¹
¹Hospital Kuala Lumpur, Kuala Lumpur, Malaysia
²Hospital Raja Perempuan Zainab II, Kelantan, Malaysia

Poster Presentations

- ID 044 BACTERIOLOGICAL ANALYSIS AND ANTIBIOTIC SENSITIVITY PATTERN OF ENDOSCOPIC RETROGRADE CHOLANGIO-PANCREATOGRAPHY OBTAINED BILE CULTURES**
C Vikneshwaran Chandra Kumar¹, Ee Hong Siow¹, Nor Zanariah Zainol Abidin², Sattian Kollanthavelu¹
¹Gastroenterology and Hepatology Unit, Department of Medicine, Hospital Tuanku Ja'afar, Seremban, Negeri Sembilan, Malaysia
²Microbiology Unit, Department of Pathology, Hospital Tuanku Ja'afar, Seremban, Negeri Sembilan, Malaysia
- ID 045 MICRO RNAs 21 AND 221 ARE NEGATIVELY CORRELATED WITH HEPATIC AND INTESTINAL TIGHT JUNCTION INTEGRITY IN THE PATHOGENESIS OF EXPERIMENTAL HEPATOCARCINOGENESIS**
Balasubramaniyan Vairappan, Victor Mukherjee, Amit Kumar Ram
Liver Diseases Research Lab, Department of Biochemistry, Jawaharlal Institute of Postgraduate Medical Education and Research, Puducherry, India
- ID 047 ACUTE EPSTEIN-BARR VIRUS (EBV) INFECTION CAUSING SEVERE HEPATITIS IN AN IMMUNOCOMPETENT PATIENT: A CASE REPORT AND REVIEW**
Ian Xiang Yuan Ch'ng, Yuan Ye Beh, Sheng Tian Ong, Ying Zhuang Ng, Mohamad Fadli bin Abd Rahman
Department of Gastroenterology and Hepatology, Hospital Pulau Pinang, Penang, Malaysia
- ID 048 CASE REPORT ON PATIENT WITH ACUTE FATTY LIVER IN PREGNANCY WITH NEWLY DIAGNOSED AIH**
Balakrishnan Asha Gayatheri, Zalwani M S
Department of Gastroenterology and Hepatology, Hospital Sultanah Bahiya, Kedah, Malaysia
- ID 050 DILI VS AIH: A CLINICAL CHALLENGE**
Noor Purdah¹, Nik Razima Wan Ibrahim¹, Norhaniza Bahar¹, Ee Keng Lim, Muhamad Yusuf², Mohd Isnisyam Saaya²
¹Gastroenterology Unit, Hospital Sultan Idris Shah, Selangor, Malaysia
²Department of Pathology, Hospital Selayang, Selangor, Malaysia
- ID 051 IMPROVING GUT DYSBIOSIS IN SPINAL CORD INJURY BY USING MULTI-STRAIN PROBIOTICS: AN ANIMAL MODEL EXPERIMENT**
M N Azmi², Y Yaacob², M Danniya¹, R A Raja Affendi^{3,4}, P Azim¹
¹Department of Neurosciences, Universiti Sains Malaysia, Kubang Kerian, Kelantan, Malaysia
²Biomechanics Laboratory, School of Mechanical Engineering, Universiti Teknologi MARA, Selangor, Malaysia
³School of Medical and Life Sciences, Sunway University, Selangor, Malaysia
⁴Gut Research Group, Faculty of Medicine, Universiti Kebangsaan Malaysia, Kuala Lumpur, Malaysia

Poster Presentations

- ID 052** **PREVALENCE OF CHRONIC KIDNEY DISEASE IN HEPATITIS C PATIENTS AND THEIR OUTCOMES WITH DIRECT ACTING ANTIVIRAL (DAA) THERAPY IN HOSPITAL TENGGU AMPUAN AFZAN**
M F Arifin¹, K A Jaafar¹, M A Md Jalil¹, A Che'Aun²
¹*International Islamic University Malaysia, Kuantan, Pahang, Malaysia*
²*Hospital Tengku Ampuan Afzan, Kuantan, Pahang, Malaysia*
- ID 053** **ECHINOCOCCOSIS, A DISEASE ENTITY THAT IS EXTREMELY RARE YET RELENTLESSLY INTERESTING**
R Thivaganesh, Wan Zaharatul Ashikin
Hospital Putrajaya, Wilayah Persekutuan Putrajaya, Malaysia
- ID 054** **FROM GUT TO BLOOD: DECODING IRON DEFICIENCY ANEMIA IN GASTROINTESTINAL TRACT**
Y Z Tay, P Nagaratnam, M F Limun, G H Chan, N A Bakar
Hospital Raja Perempuan Zainab II, Kelantan, Malaysia
- ID 055** **ATYPICAL MANIFESTATION OF A LARGE POLYP IN A YOUNG PATIENT WITH IRRITABLE BOWEL SYNDROME**
Y C Tang¹, Naim Syahidah Zulkafli², Zalwani Zainuddin¹
¹*Gastroenterology Unit, Internal Medicine Department, Hospital Sultanah Bahiyah, Alor Setar, Kedah, Malaysia*
²*Pathology Department, Hospital Sultanah Bahiyah, Alor Setar, Kedah, Malaysia*
- ID 056** **ANTI-HBS LEVEL PATTERN AMONG CHRONIC HEMODIALYSIS PATIENTS IN A PUBLIC HOSPITAL SETTING**
K A Jaafar¹, A Z Shukor²
¹*International Islamic University of Malaysia, Kuantan, Pahang, Malaysia*
²*Hospital Kemaman, Kemaman, Terengganu, Malaysia*
- ID 057** **REBLEEDING RISK IN UPPER GASTROINTESTINAL BLEEDING: A SINGLE CENTRE STUDY**
G H Chan, P Nagaratnam, Y Z Tay, M F Limun, N A Bakar
Hospital Raja Perempuan Zainab II, Kota Bharu, Kelantan, Malaysia
- ID 058** **EFFECTS OF SHORT-TERM ANTIBIOTIC USAGE ON GUT MICROBIOME: INSIGHTS FROM A COHORT STUDY IN YOUNG CHILDREN**
Bavdekar A¹, Kawade A², Veligandla K C³, Joshi D K³, Neha³, Rathod R³, Kotak Bhavesh³
¹*KEM Hospital, Pune, India*
²*Shirdi Sai Baba Rural Hospital, Pune, India*
³*Dr Reddys Laboratories Ltd, Hyderabad, India*

Poster Presentations

- ID 062** **EXPLORING INTESTINAL BARRIER DYSFUNCTION IN INFLAMMATORY BOWEL DISEASE PATIENTS WITH TREATED VEDOLIZUMAB: IMPLICATIONS FOR THERAPEUTIC RESPONSE**
Nurul Aqilah Shahabudin¹, Raja Affendi Raja Ali^{2,3}, Norfilza Mohd Mokhtar^{1,2}
¹Department of Physiology, Faculty of Medicine, Universiti Kebangsaan Malaysia, Kuala Lumpur, Malaysia
²GUT Research Group, Faculty of Medicine, Universiti Kebangsaan Malaysia, Kuala Lumpur, Malaysia
³School of Medical and Life Sciences, Sunway University, Selangor, Malaysia
- ID 063** **RISK OF HEPATOCELLULAR CARCINOMA AMONG CHRONIC HEPATITIS C WITH CIRRHOSIS AFTER ACHIEVED SVR12: A RETROSPECTIVE REVIEW IN HOSPITAL SULTANAH NUR ZAHIRAH (HSNZ)**
Ahmad Syahidan Yusoff
Hospital Sultanah Nur Zahirah, Kuala Terengganu, Terengganu, Malaysia
- ID 064** **PERCUTANEOUS TRANSLUMINAL ANGIOPLASTY (PTA) IN A PATIENT WITH BUDD-CHIARI SYNDROME AFTER LIVER TRANSPLANT: A CASE REPORT**
Shih Mun Yong¹, Su Wen Chuah¹, Shazatul Ezanni Binti Shamsudin², James Emmanuel¹, Raman Muthukaruppan¹
¹Department of Gastroenterology and Hepatology, Queen Elizabeth Hospital, Kota Kinabalu, Sabah, Malaysia
²Department of Radiology, Queen Elizabeth Hospital, Kota Kinabalu, Sabah, Malaysia
- ID 065** **TREATMENT OF FUNCTIONAL DYSPEPSIA BASED ON SUBTYPE COMPARED TO EMPIRICAL PROTON PUMP INHIBITOR: AN INTERIM ANALYSIS OF A RANDOMIZED CONTROLLED TRIAL**
Qing Yuan Loo¹, Kee Huat Chuah¹, Wen Xuan Hian¹, Xin Hui Khoo¹, Muhamad Ammar Furqan bin Zulkifly¹, Sarala Panirsheelum², Nurhidayah binti Mohammad Jubri², Vicraman Natarajan², Hooi Min Lim³, C Vikneshwaran Chandra Kumar¹, Stanley Khoo¹, Sanjiv Mahadeva¹
¹Gastroenterology and Hepatology Unit, Department of Medicine, Faculty of Medicine, Universiti Malaya, Kuala Lumpur, Malaysia
²Staff & Student Health Unit, Universiti Malaya Medical Centre, Kuala Lumpur, Malaysia
³Department of Primary Care Medicine, Faculty of Medicine, Universiti Malaya, Kuala Lumpur, Malaysia
- ID 066** **IMPACT OF POSITIVE GLUCOSE, LACTOSE AND FRUCTOSE HYDROGEN BREATH TESTS ON SYMPTOMS AND QUALITY OF LIFE IN IRRITABLE BOWEL SYNDROME**
Qing Yuan Loo¹, Kee Huat Chuah¹, Wen Xuan Hian¹, Xin Hui Khoo¹, Yeong Yeh Lee², Sanjiv Mahadeva¹
¹Division of Gastroenterology, Department of Medicine, Faculty of Medicine, Universiti Malaya, Kuala Lumpur, Malaysia
²School of Medical Sciences, Universiti Sains Malaysia, Kubang Kerian, Kelantan, Malaysia
- ID 070** **ENDOSCOPIC EVALUATION IN ADULTS WITH SUSPECTED GASTROINTESTINAL (GI) BLEEDING: A 9-YEAR RETROSPECTIVE, SINGLE-CENTRE REVIEW**
Shahreedhan binti Shahrani¹, Sandeep Singh Gill², Ng Xin Tong², Looi Kah Hee², Nurul Safirah Binti Norhisham², Chee Sher Weyne², Khoo Xin Hui², Imran Zainal Abidin^{1,2}, Sanjiv Mahadeva^{1,2}
¹Department of Internal Medicine, Universiti Malaya Medical Centre, Kuala Lumpur, Malaysia
²Faculty of Medicine, Universiti Malaya, Kuala Lumpur, Malaysia

Poster Presentations

- ID 071 GASTROINTESTINAL (GI) BLEEDING WITH ANTI-THROMBOTIC USE: A LARGE MALAYSIAN COHORT STUDY**
Shahreedhan binti Shahrani¹, Sandeep Singh Gill², Ng Xin Tong², Looi Kah Hee², Nurul Safirah Binti Norhisham², Chee Sher Weyne², Khoo Xin Hui², Imran Zainal Abidin^{1,2}, Sanjiv Mahadeva^{1,2}
¹*Department of Internal Medicine, Universiti Malaya Medical Centre, Kuala Lumpur, Malaysia*
²*Faculty of Medicine, Universiti Malaya, Kuala Lumpur, Malaysia*
- ID 073 MOLECULAR EPIDEMIOLOGY AND SPATIAL DISTRIBUTION OF HEPATITIS B VIRUS GENOTYPES, SUBGENOTYPES AND SEROTYPES AMONG PATIENTS FROM A MALAYSIAN TERTIARY MEDICAL CENTRE**
Bello Kizito Eneye^{1,2}, Wong Mung Seong^{3,5}, Lee Yeong Yeh^{3,5}, Rafidah Hanim Shueb^{1,4,5}, Nazri Mustafa^{3,5}
¹*Department of Medical Microbiology and Parasitology, School of Medical Sciences, Universiti Sains Malaysia, Kubang Kerian, Kelantan, Malaysia*
²*Kogi State University (Prince Abubakar Audu University) Anyigba, Kogi State, Nigeria*
³*Department of Medicine, School of Medical Sciences, Universiti Sains Malaysia, Kubang Kerian, Kelantan, Malaysia*
⁴*Institute for Research in Molecular Medicine, Universiti Sains Malaysia, Kubang Kerian, Kelantan, Malaysia*
⁵*Hospital Universiti Sains Malaysia, Kubang Kerian, Kelantan, Malaysia*
- ID 074 THE LINK BETWEEN THE OPPORTUNISTIC GUT FUNGAL PATHOGENS WITH COLORECTAL ADENOCARCINOMA**
Aisyah Yunus¹, Norfilza Mohd Mokhtar^{2,3}, Raja Affendi Raja Ali^{3,4}, Siti Maryam Ahmad Kendong², Hajar Fauzan Ahmad^{1,3}
¹*Faculty of Industrial Sciences and Technology, Universiti Malaysia Pahang, Pahang, Malaysia*
²*Department of Physiology, Faculty of Medicine, Universiti Kebangsaan Malaysia, Kuala Lumpur, Malaysia*
³*Gut Research Group, Faculty of Medicine, Universiti Kebangsaan Malaysia, Kuala Lumpur, Malaysia*
⁴*School of Medical and Life Sciences, Sunway University, Selangor, Malaysia*
- ID 076 CASE REPORT: METHEMOGLOBINEMIA IN PARACETAMOL OVERDOSE - A RARE OCCURENCE**
Naveen R, Zalwani Zainuddin, Kuang Kiat Kiew
Gastroenterology Unit, Department of Internal Medicine, Hospital Sultanah Bahiyah, Alor Star, Kedah, Malaysia
- ID 078 CD20-NEGATIVE DIFFUSE LARGE B-CELL LYMPHOMA OF THE COLON: EXPOSING THE GREAT MIMICKER WITH IHC**
Subita Sugantal¹, James Emmanuel¹, Lily Wong Lee Lee², Raman Muthukaruppan¹
¹*Gastroenterology Unit, Department of Medicine, Queen Elizabeth Hospital, Kota Kinabalu, Sabah, Malaysia*
²*Hematology Unit, Department of Medicine, Queen Elizabeth Hospital, Kota Kinabalu, Sabah, Malaysia*
- ID 079 AN UNUSUAL COMPLICATION OF METAL STENTING IN A LIVER TRANSPLANT RECIPIENT WITH ANASTOMOTIC STRICTURE: A CASE REPORT**
C F Liew, James Emmanuel, R Puthashanan, Raman Muthukaruppan Chettiar
Queen Elizabeth Hospital, Kota Kinabalu, Sabah, Malaysia

Poster Presentations

- ID 080** **PIECEMEAL COLD SNARE EMR TO A LARGE NON-GRANULAR LATERALLY SPREADING DUODENAL TUMOUR**
Keng Hoong Chiam, Shih Mun Yong
Pantai Hospital, Penang, Malaysia
- ID 081** **LIVER INJURY IN PREGNANT PATIENTS WITH POSITIVE COVID-19: ITS CLINICAL FEATURES AND OUTCOMES**
Y P Tan, Joyce Yap, Adawiyah, Mathurubini Nair, Daleen Leong, Ezma, K K Sia
Gastroenterology unit Medical department, Ampang Hospital, Selangor, Malaysia
- ID 082** **UTILITY OF COLONOSCOPY IN DIAGNOSING ACUTE GASTROINTESTINAL GRAFT VERSUS HOST DISEASE**
Y P Tan¹, T G Wong²
¹Gastroenterology & Hepatology Unit, Ampang Hospital, Selangor, Malaysia
²Haematology Department, Ampang Hospital, Selangor, Malaysia
- ID 083** **INNOVATION IN PATIENT-CENTRIC INFLAMMATORY BOWEL DISEASE (IBD) CARE IN MALAYSIA: EARLY EXPERIENCE ANALYSIS OF THE IBD PAL MOBILE APP FOR REMOTE DISEASE MONITORING**
Choong Yeong Sooi¹, Ida Normiha Hilmi², Khairul Najmi Muhammad Nawawi³, Sherene Swee Yin Lim⁵, Ruben Skantha¹, Rasnaizam Rasdi¹, Azlida Che' Aun¹, Xin Hui Khoo², Lorraine Angal², Mei Hui Wee⁴, Alex Hwong Ruey Leow⁴
¹Department of Gastroenterology, Hospital Tengku Ampuan Afzan, Kuantan, Pahang, Malaysia
²Division of Gastroenterology and Hepatology, Department of Medicine, Faculty of Medicine, Universiti Malaya, Kuala Lumpur, Malaysia
³Gastroenterology Unit, Department of Medicine, Faculty of Medicine Universiti Kebangsaan Malaysia, Kuala Lumpur, Malaysia
⁴Pantai Hospital Kuala Lumpur, Kuala Lumpur, Malaysia
⁵Medical Affairs, Ferring Malaysia, Selangor, Malaysia
- ID 084** **HEPATIC HYDROTHORAX: SINGLE CENTRE'S EXPERIENCE IN MALAYSIA ON THE UTILITY OF OCTREOTIDE - A CASE SERIES**
C Vikneshwaran Chandra Kumar, Ruben Skantha, Shahreedhan Shahrani, Nik Arsyad Nik Muhammad Affendi, Thevaraajan Jayaraman, Kee Huat Chuah, Stanley Khoo, Ruveena Bhavani Rajaram, Sanjiv Mahadeva
Gastroenterology and Hepatology Unit, Department of Medicine, Universiti Malaya Medical Centre, Kuala Lumpur, Malaysia
- ID 085** **G-POEM FOR REFRACTORY GASTROPARESIS: CASE SERIES**
Chong Chearn Lee¹, Shiaw-Hooi Ho², Sanjiv Mahadeva²
¹Gastroenterology and Hepatology Unit, Department of Medicine, Hospital Canselor Tuanku Muhriz, Kuala Lumpur, Malaysia
²Gastroenterology and Hepatology Unit, Department of Medicine, Universiti Malaya Medical Centre, Kuala Lumpur, Malaysia

Poster Presentations

- ID 087** **LONG TERM EFFICACY AND PERSISTENCE OF BIOLOGICS THERAPY IN CROHN DISEASE IN MULTIRACIAL ASIAN COUNTRY: A REAL WORLD EXPERIENCE**
Nik Arsyad bin Nik Muhamad Affendi^{1,2}, Xin Hui Khoo¹, Alex Hwong-Ruey Leow^{1,3}, Ida Normiha Hilmi¹
¹Division of Gastroenterology and Hepatology, Department of Medicine, Faculty of Medicine, Universiti Malaya, Kuala Lumpur, Malaysia
²Division of Gastroenterology and Hepatology, Department of Medicine, Faculty of Medicine, International Islamic University Malaysia, Kuala Lumpur, Malaysia
³Pantai Hospital Kuala Lumpur, Kuala Lumpur, Malaysia
- ID 089** **G-POEM FOR REFRACTORY GASTROPARESIS: CASE SERIES OF TREATMENT OUTCOME**
Chong Chearn Lee^{1,2}, Shiaw-Hooi Ho², Sanjiv Mahadeva²
¹Gastroenterology and Hepatology Unit, Department of Medicine, Hospital Canselor Tuanku Mubriz, Kuala Lumpur, Malaysia
²Gastroenterology and Hepatology Unit, Department of Medicine, Universiti Malaya Medical Centre, Kuala Lumpur, Malaysia
- ID 090** **LYMPHOEPITHELIAL SQUAMOUS CELL CARCINOMA OF THE OESOPHAGUS: A CASE REPORT**
Marco Luciano Medina^{1,2}, Man Kein Seong³, Ho Shiaw Hooi²
¹University of the East Ramon Magsaysay Memorial Medical Center, Quezon City, Philippines
²Department of Medicine, Faculty of Medicine, Universiti Malaya, Kuala Lumpur, Malaysia
³Department of Pathology, Faculty of Medicine, Universiti Malaya, Kuala Lumpur, Malaysia
- ID 091** **FACTORS ASSOCIATE WITH HIGH ADENOMA DETECTION RATE: A TERTIARY CENTRE EXPERIENCE**
Mohd Badrul Hisyam bin Hashim¹, Nik Arsyad bin Nik Muhamad Affendi^{1,2}, Ho Shiaw Hooi¹
¹Division of Gastroenterology and Hepatology, Department of Medicine, Faculty of Medicine, Universiti Malaya, Kuala Lumpur, Malaysia
²Division of Gastroenterology and Hepatology, Department of Medicine, Faculty of Medicine, International Islamic University Malaysia, Kuala Lumpur, Malaysia
- ID 092** **EFFICACY AND SAFETY OF DIRECT ACTING ANTIVIRAL THERAPY IN PATIENTS WITH CHRONIC HEPATITIS C VIRUS INFECTION: A SINGLE-CENTER EXPERIENCE**
Lu Chee Men, James Emmanuel, R Puthashanan, Raman Muthukaruppan Chettiar
Queen Elizabeth Hospital, Kota Kinabalu, Sabah, Malaysia
- ID 093** **EUS-GUIDED LUNG MASS BIOPSY IN PATIENTS WITH LUNG CARCINOMA: A CASE SERIES**
K K Ng, J Emmanuel, R Puthashanan, R Muthukaruppan
Hospital Queen Elizabeth, Kota Kinabalu, Sabah, Malaysia

Poster Presentations

- ID 094** **CHOLANGIOSCOPY-GUIDED HOLMIUM LASER LITHOTRIPSY AS A RESCUE TREATMENT FOR AN IMPACTED TRAPEZOID BASKET IN THE BILE DUCT: A CASE REPORT**
K K Ng, J Emmanuel, R Puthashanan, R Muthukaruppan
Queen Elizabeth Hospital, Kota Kinabalu, Sabah, Malaysia
- ID 095** **A RARE CASE REPORT: GALLBLADDER MALIGNANCY IN AN ADULT WITH DOWN SYNDROME**
N Azis, J Emmanuel, R Puthashanan, R Muthukaruppan
Queen Elizabeth Hospital, Kota Kinabalu, Sabah, Malaysia
- ID 096** **CHOLANGIOSCOPY-GUIDED HOLMIUM LASER LITHOTRIPSY FOR LARGE BILE DUCT STONES - CASE SERIES**
N Azis, J Emmanuel, R Puthashanan, R Muthukaruppan
Queen Elizabeth Hospital, Kota Kinabalu, Sabah, Malaysia
- ID 097** **CERVICAL OESOPHAGEAL HAEMANGIOMA - A RARE CASE OF UPPER GASTROINTESTINAL BLEED**
C C Cheah, James Emmanuel, R Puthashanan, Raman, Muthukaruppan Chettiar
Queen Elizabeth Hospital, Kota Kinabalu, Sabah, Malaysia
- ID 098** **INCREASING INCIDENCE OF IBD IN MALAYSIA WITH REVERSAL OF ULCERATIVE COLITIS TO CROHN'S DISEASE RATIO: FOLLOW UP FROM THE KINTA VALLEY STUDY**
Khoo Xin-Hui¹, Tan Phei Oon², Andrew Chua Seng Boon^{3,4,6}, Harjinder Singh⁴, Ng Thean Heng⁴, Wong Choon Heng⁵, Kong Wai Hong⁵, Raja Affendi Raja Ali⁷, Ida Normiha Hilmi¹
¹*Division of Gastroenterology, Department of Medicine, Universiti Malaya, Kuala Lumpur, Malaysia*
²*Division of Gastroenterology, Department of Medicine, Hospital Raja Permaisuri Bainun, Ipoh, Perak, Malaysia*
³*Division of Gastroenterology, Ipoh Gastro Centre, Ipoh, Perak, Malaysia*
⁴*Division of Gastroenterology, Pantai Hospital Ipoh, Ipoh, Perak, Malaysia*
⁵*Division of Gastroenterology, KPJ Specialist Centre, Ipoh, Perak, Malaysia*
⁶*Division of Gastroenterology, Fatimah Hospital, Ipoh, Perak, Malaysia*
⁷*Division of Gastroenterology, Department of Medicine, Universiti Kebangsaan Malaysia, Kuala Lumpur, Malaysia*
- ID 099** **ENDOSCOPIC RETROGRADE CHOLANGIOPANCREATICOGRAPHY (ERCP) USING A GASTROSCOPE**
Kokulabalan Mariappen, James Emmanuel, Puthashanan Rajamanickam, Raman Muthukaruppan Chettiar
Queen Elizabeth Hospital, Kota Kinabalu, Sabah, Malaysia

AZATHIOPRINE INDUCED ALOPECIA TOTALIS: A RARE ADVERSE EVENT, AS AN EARLY CLINICAL MARKER OF MYELOTOKSICITY

Ruben Skantha, Rasnaizam Rasdi, Azlida Che Aun, Choong Yeong Sooi

Hospital Tengku Ampuan Afzan, Pahang, Malaysia

Azathioprine is an effective drug used in the treatment of inflammatory bowel disease. Myelosuppression is a common side effect, however severe pancytopenia and alopecia are rare. We report an interesting case of azathioprine induced alopecia as a relevant clinical marker of severe myelosuppression.

A 41-year-old lady presented with alternating diarrhea and constipation associated with bloody stools. Routine tests showed she was anemic with thrombocytosis. She underwent a colonoscopy which showed panproctocolitis, suggestive of ulcerative colitis and this was confirmed histologically. She was initiated on steroids with a weekly tapering dose, and mesalazine. After a month, we started her on Azathioprine as a steroid sparer, and increased the dose the following month. She had gained weight, bowel output improved and no blood per stools.

Two months after initiating Azathioprine, she began to report excessive hair loss which progressed to almost complete loss of scalp hair. She subsequently admitted to ward with pancytopenia, alopecia totalis, and retinal and subconjunctival hemorrhages. Her Azathioprine and mesalazine were withheld and received multidisciplinary treatment. Full blood picture confirmed severe pancytopenia with no malignant cells and bone marrow showed slightly lower cellularity than normal. After 1 month of therapy with hematopoietic agents and withdrawal of azathioprine, her cell counts improved. TPMT and NUDT15 testing was not done due to costs.

In several case reports, alopecia was reported 2 weeks prior to the onset of myelosuppression, and myelosuppression occurred about 20 days later. Another case reported alopecia and myelosuppression occurring simultaneously. In all these cases, the patients eventually recovered.

In conclusion, this case emphasizes the significance of a basic clinical indicator like alopecia, which can serve as an early warning sign for severe myelosuppression in individuals undergoing azathioprine treatment. TPMT/NUDT15 testing when available should be performed to identify TPMT and NUDT15 mutations, hence avoiding azathioprine use completely.

DEMOGRAPHICS STUDY AND PREDICTORS OF HOSPITALISATION AMONG LIVER CIRRHOSIS PATIENTS IN HOSPITAL SULTANAH NORA ISMAIL

Amin Mohamed, Rajendran Jeevakanthi, Kien Ting Liu, Murugesu Kalaivani, Sadli Salwa,
Nazri Hafiz Muhammad

¹Gastroenterology Clinic, Hospital Sultanah Nora Ismail, Batu Pahat, Johor, Malaysia

²National Heart Association of Malaysia, Kuala Lumpur, Malaysia

OBJECTIVES:

1. To identify the prevalence and demographics data among liver cirrhosis of gastroenterology clinic in hospital Sultanah Nora Ismail.
2. To predict on the factors that influence hospitalisation among liver cirrhosis patients.

METHODOLOGY: Liver cirrhosis patients attending the Gastroenterology Clinic of hospital Batu Pahat, Malaysia from 1st July 2022 to 1st June 2023 were tabulated. Clinic records was used for data collection. Pearson Chi Square, Fisher's exact test, Simple and multiple logistic regression were statistical analysis method used in this study.

RESULTS: A total of 151 adult patients were diagnosed with liver cirrhosis including 78 males (51.7%) and 73 females (48.3%), with mean age of 55-years-old. Most patients were Malay (56.3%) and followed by Chinese (38.4%). They were non smokers and non alcoholic. Comorbidities of DM, HPT, Dyslipidemia, IHD and CKD were analysed as well. The most likely causes were chronic hepatitis B (N=70, 46.4%), chronic hepatitis C (N= 34, 22.5%), Metabolic associated fatty liver disorder (N=23, 15.2%), Autoimmune (N=14, 9.3%), Primary Biliary Cirrhosis (N=5, 3.3%), Alcohol (N=3, 2.0%), and co-infections (N=2, 1.3%). Age, LDL, Creatinine and BMI have been found to be statistically significant for the hospitalisation when t-test was performed. Subsequently, simple and multiple logistic regression was performed and it was found that a person with an increase of 1mmol/L in creatinine has 1% higher odds to be warded (95% CI: 1.00, 1.02, p=0.009) when adjusted for BMI.

CONCLUSION: Hepatitis B viral infection remains the most common cause of cirrhosis among liver cirrhosis patients. Consideration need to given on liver cirrhosis patients who are elderly, obese and having CKD.

UNREVEALING THE ROLE OF SIX VEGFA POLYMORPHISMS ON THE SUSCEPTIBILITY OF HEPATOCELLULAR CARCINOMA (HCC) AND RECURRENCE: AN UPDATED SYSTEMATIC REVIEW AND META ANALYSIS OF 11 STUDIES

Dwijo Anargha Sindhughosa, I Ketut Mariadi

Division of Gastroenterology and Hepatology, Internal Medicine Department, Faculty of Medicine, Udayana University/Prof. Dr. I.G.N.G. Ngurah Hospital, Denpasar, Bali, Indonesia

OBJECTIVE: Evaluating the role of vascular endothelial growth factor A (VEGFA) polymorphisms toward susceptibility of hepatocellular carcinoma (HCC) and recurrence after its management.

METHODOLOGY: The study population were patients with HCC. VEGF gene polymorphism studied were VEGFA rs2010963 (-634G>C), rs3025039 (+936C>T), rs833061, rs699947 (-2578C>A), rs1570360 (-1154 G/A), and rs10434 (-1612 G/A). We analyze the wildtype, heterozygote, and mutant genotype. The primary outcome was the susceptibility of HCC, while the secondary outcome was the recurrence of HCC after treatment of either liver transplantation or resection. Random effect model was used for the analysis.

RESULTS: The total of 11 studies included. The mutant genotype for VEGFA rs2010963 (-634G>C) polymorphism had pooled OR of 1.13 (0.89-1.44), VEGFA rs2010963 (-634G>C) had pooled OR of 1.13 (0.89-1.44), rs3025039 (+936C>T) had pooled OR of 0.55 (0.21-1.45), rs833061 had pooled OR of 0.54 (0.2-1.47), rs699947 (-2578C>A) had pooled OR of 0.96 (0.56-1.67), rs1570360 (-1154 G/A) had pooled OR of 0.78 (0.2-3.03), and rs10434 (-1612 G/A) had pooled OR of 1.24 (0.78-2). The heterozygote and wildtype genotype showed no significant association with susceptibility of HCC ($p > 0.05$), similar to mutant genotype. As for recurrence after treatment (liver transplantation/resection), we investigated three polymorphisms; rs2010963 (-634G>C), rs3025039 (+936C>T), and rs699947 (-2578C>A). All showed no significant association with recurrence after either transplantation or resection ($p > 0.05$).

DISCUSSION: The nature of HCC is tightly related to tumor-induced angiogenesis. The main factor that leads to the development of HCC is increase in angiogenic factors. VEGFA is angiogenic factors mainly involved in angiogenesis and vascular remodeling. Several studies already showed various result in VEGF gene polymorphism and the association with HCC and recurrence.

CONCLUSION: VEGFA polymorphisms have no association with susceptibility of HCC and recurrence of HCC after treatment. Further study in diverse population and analyzing gene interactions are warranted.

BENIGN RECURRENT INTRAHEPATIC CHOLESTASIS (BRIC): A CASE REPORT IN MALAYSIA

Thomas Koshy, Ahmad Syahidan Yusoff, Ravin Ponnisamy, Nurul Atiah, Syuhada Dan binti Adnan
Gastroenterology & Hepatology Unit, Sultanah Nur Zahirah Hospital, Terengganu, Malaysia

CASE REPORT: We report a case of a 33-year-old adult male patient with BRIC who presented with recurrent cholestatic jaundice and pruritis with intervening symptom free period for the last 3 years. Diagnosis was made by his classical clinical presentation and liver biopsy showing intrahepatic cholestasis and negative screen for all other possible etiologies. He was started on Ursodeoxycholic acid 500mg bd. He was advised to take low fat diet. His pruritis resolved first and subsequently bilirubin returned to baseline after 2 months of treatment. Patient was followed for 6 months and has not developed fresh episode of jaundice and pruritis.

DISCUSSION: Benign recurrent intrahepatic cholestasis is a rare genetic disorder characterized by intermittent episodes of jaundice and pruritis. It is a benign disease with no progression to end stage liver disease. There is completely asymptomatic phase in between attacks which can last for months to years. Serum gamma-glutamyl transpeptidase (GGT), aspartate aminotransferase (AST), and alanine aminotransferase (ALT) are either normal or mildly elevated. A diagnostic criterion for BRIC has been proposed by Luketic and Shiffman which includes: (a) at least 2 episodes of jaundice with asymptomatic interval of month to years; (b) laboratory investigations suggestive of intrahepatic cholestasis; (c) cholestasis induced severe pruritis; (d) cholangiography showing normal intra and extrahepatic bile ducts; (e) liver histology suggesting centrilobular cholestasis; (f) absence of other causes of cholestasis. Our patient fulfilled all these criteria. There is no definite treatment for BRIC and medications are used during episodes to alleviate symptoms.

CONCLUSION: BRIC is a self-limiting disease and does not cause chronic liver disease. Knowledge of this entity is essential as early recognition can prevent performance of expensive diagnostic investigations and patient can be counseled regarding the benign nature of the disease.

RECOGNITION OF ASYMPTOMATIC EARLY-STAGE HEPATIC WILSON DISEASE WITH LIMITED RESOURCES-BLESSING IN DISGUISE IN THE COVID ERA

S Y Ngeoh, W C Liew, S L Lee, M S Firdaus

Hospital Sultanah Aminah, Johor, Malaysia

OBJECTIVE: Wilson's disease is a rare genetic disorder with a varied clinical presentation, which makes diagnosis challenging.

CASE REPORT: A 19-year-old gentleman had persistent hypertransaminasemia following a previous COVID-19 infection in mid-2021. He was non-alcoholic with normal BMI, and denied using traditional medications or supplements. Hepatitis B and C screening, autoimmune markers, and abdominal ultrasound yielded normal results. Copper metabolism assessment showed low ceruloplasmin with a slightly elevated 2x ULN (upper limit of normal) of 24-hour urine copper (2.25 umol/24 hours). Slit-lamp examination did not reveal Kayser-Fleischer rings. The patient had no neurological symptoms or relevant family history. Genetic analysis was not performed due to financial constraints. Liver biopsy indicated mild steatohepatitis with moderate portal inflammation, but the specific stain was unavailable. Given the equivocal of Leipzig score of 3 or 4, a Penicillamine challenge test was conducted, resulting in a notable surged in urine copper to 5x ULN (17.88 umol/24 hours). Therefore, Wilson's disease was confirmed with a Leipzig score of 4. The patient was started on oral chelator D-Penicillamine.

RESULT: The transaminitis showed gradual improvement with the treatment.

DISCUSSION: The case highlights the challenges in diagnosing Wilson's disease, which lacks a definitive diagnostic test. Diagnosis relies on a combination of clinical presentation, family history, laboratory tests, imaging, and eye assessment. In some cases, liver biopsy may be necessary. The Penicillamine challenge test played a crucial role in aiding the diagnosis in this case.

CONCLUSION: Wilson's disease should be considered in patients with unexplained liver abnormalities, even in the absence of neurological symptoms or Kayser-Fleischer rings. This patient presents with asymptomatic early-stage liver disease, and adherence to treatment is expected to improve liver function. Early diagnosis and treatment are vital in preventing disease progression and complications in Wilson's disease.

CASE OF LATE-ONSET HEPATITIS B FLARE POST RITUXIMAB

S Y Ngeoh, W C Liew, S L Lee, M S Firdaus

Hospital Sultanah Aminah, Johor, Malaysia

OBJECTIVE: Hepatitis B flare post-rituximab can be a serious and potentially life-threatening complication. When combined with chemotherapy, the overall HBV reactivation rate during rituximab treatment has been reported to be 20%- 55%, with a lower rate of 3% in HBsAg-negative patients.

CASE REPORT: A 68-year-old male was diagnosed with stage IV grade I follicular lymphoma in 2019. He was scheduled for rituximab-based chemotherapy. Prior to treatment, hepatitis serology was performed, which showed negative results for hepatitis B surface antigen (HBsAg) and anti-HCV. However, anti-HBc testing was not performed. Chemotherapy was initiated in August 2019, consisting of 4 cycles of Bendamustine/Rituximab, followed by 2 cycles of R-CHOP, and finally 12 cycles of rituximab maintenance until January 2022. Liver function tests remained normal throughout the treatment period. In early May 2023, the patient presented with symptoms of jaundice, lethargy, and severe transaminitis. Repeated testing confirmed positive results for HBsAg, indicating reactivation of Hepatitis B, with a high viral load (HBV DNA 4013339 IU/ml).

RESULT: Antiviral treatment was promptly initiated, and the patient responded well with subsequent improvement in liver function tests.

DISCUSSION: This patient experienced a late-onset hepatitis B flare after completing 16 months of chemotherapy. This case emphasizes the importance of properly assessing hepatitis B status by testing for HBsAg, HBcAb, and HBsAb before initiating rituximab-based chemotherapy. If a patient is HBsAg negative and HBcAb positive, indicating prior exposure to the hepatitis B virus and the presence of occult HBV infection, antiviral prophylaxis should be administered before starting rituximab-based chemotherapy.

CONCLUSION: Anti-CD20 therapies deplete B cells, increasing the risk of occult HBV reactivation. High-risk patients should receive 12-16 months of antiviral prophylaxis after stopping anti-CD20 therapy.^{2,3} This prolonged prophylaxis ensures adequate protection during B-cell recovery after treatment cessation.

3 CONCURRENT TUMOURS IN A PATIENT WITH NAFLD CIRRHOSIS

T M Yeo, Norhaniza Bahar, Nik Razima Wan Ibrahim, Rosaida Hj Mohd Said

Hospital Sultan Idris Shah Serdang, Selangor, Malaysia

INTRODUCTION: Hepatocellular carcinoma (HCC) is a complication of non-alcoholic fatty liver disease (NAFLD). An association has been found between obesity and various other malignancies such as colon, pancreatic and ovarian cancer, likely due to the resulting low grade inflammatory state. Here we report a case of an obese patient with NAFLD who had HCC and concurrent ovarian and pleural tumours.

CASE REPORT: A 66 year old lady under our Hepatology clinic follow-up for Child-Pugh A liver cirrhosis secondary to NAFLD, complained of fatigue for the past 6 months. She had a history of esophageal variceal bleeding a year earlier. Surveillance ultrasound showed a right liver lobe heterogenous mass as well as a right adnexal solid mass. Subsequently a 4-phase CECT liver and abdomen showed a segment VI/V liver lesion measuring 5.6x6.3 cm with early enhancement on arterial phase and washout on portovenous and delayed phases with central necrosis, which is typical of HCC. It also showed a right adnexal solid mass measuring 6.6x4.5 cm with cystic & necrotic components suggestive of an ovarian tumour, and another pleural based mass adjacent to the right lower lobe. AFP and Ca-125 levels were normal (4.57 ng/ml and 13.57 IU/ml respectively). HBs Ag and anti-HCV were non-reactive. Laparoscopic segment VI resection was performed by Hepatobiliary team, while imaging guided biopsy of pleural mass was planned by Respiratory team. Histopathology of the liver mass confirms HCC. Gynae oncology team is planning imaging surveillance of the adnexal tumour.

DISCUSSION AND CONCLUSION: Our case shows that it is possible for obese patients with NAFLD to have multiple concurrent tumours. Clinicians should watch out for symptoms and signs of malignancy at various sites in patients with obesity and NAFLD. Liver tumours in NAFLD patients with another primary tumour can be either metastatic or primary.

CASE REPORT: UNCOMMON ASSOCIATION BETWEEN HEPATITIS C VIRUS (HCV) AND GUILLAIN-BARRE SYNDROME (GBS) - EXPLORING THE POTENTIAL AS AN EXTRAHEPATIC MANIFESTATION

Kay-Keng Tan, Tse-Hui Chow

Gastroenterology Unit, Medical Department, Hospital Raja Permaisuri Bainun Ipoh, Perak, Malaysia

INTRODUCTION: We present a case report of a manifestation of Guillain-Barre syndrome (GBS) in conjunction with chronic hepatitis C infection. It is worth noting that the correlation between GBS and hepatitis C virus (HCV) infection has been seldom documented in existing literature.

CASE PRESENTATION: A 59 years old gentleman who has underlying diabetes mellitus and hypertension presented with progressive bilateral lower limb numbness and weakness for 4 days. He was admitted to the ward and NCS done showed mixed sensory motor demyelinating neuropathy (AMSAN). Case was seen by neuromedical team and treated as Guillain Barre Syndrome. He was started IVIG 0.4g/kg for 5 days and responded well to IVIG. In the ward noted patient has elevated liver enzyme, investigation was done and showed anti-HCV antibodies positive. HCV RNA viral load revealed 3258983 iu/ml and HCV genotype showed 1a type. He was started DAA treatment (sofosbuvir+daclatasvir) for total 12 weeks and Follow-up appointments were scheduled for the patient in the gastroenterology clinic.

DISCUSSION: Our case study highlights a severe case of Guillain-Barre Syndrome (GBS) that was associated with hepatitis C virus (HCV) infection. The electromyography (EMG) results classified the GBS subtype as Acute Motor-Sensory Axonal Neuropathy (AMSAN), which correlated with the clinical presentation. We emphasize the importance of screening for HCV infection in high-risk patients to prevent the silent progression of chronic hepatitis C and its potentially severe extra-hepatic manifestations.

Keywords: Chronic hepatitis C, Hepatitis C virus, Guillain-Barre syndrome, Extra-hepatic manifestations

ATYPICAL PRESENTATION OF AUTOIMMUNE PANCREATITIS

Ying Zhuang Ng¹, Yuan Ye Beh¹, Mohamad Fadli Abd Rahman¹, Kuang Kiat Kiew²

¹Hospital Pulau Pinang, Penang, Malaysia

²Hospital Sultanah Bahiyah, Kedah, Malaysia

Autoimmune pancreatitis (AIP) is an uncommon but well-established form of pancreatic inflammation. Unlike other pancreatic disease, it typically has a dramatic response to glucocorticoid therapy.

In this case report, we describe a 51-year-old woman who presented with epigastric fullness and generalised pruritus persisting for three months. Additionally, she experienced bilateral lacrimal and parotid glands swelling for the past one month. Initial liver function tests revealed mixed hepatocellular and cholestatic picture. Her viral hepatitis screening was negative but antinuclear antibody (ANA) was positive and serum IgG level was elevated (2470 mg/dL). However, her serum IgG4 level was within normal limit (25.2 mg/dL). Her ultrasound abdomen revealed bulky pancreas suggestive of pancreatitis. Subsequent Magnetic resonance cholangiopancreatography showed diffuse enlargement of the pancreas leading to upstream dilatation of biliary system. Endoscopic ultrasound showed diffuse hypoechoic enlargement of the pancreas from head to tail, with multiple hyperechoic foci and strands. The pancreatic duct appeared irregularly dilated. The common bile duct was grossly dilated with abrupt tapering towards the pancreatic head. Two occasions of fine needle biopsies were done using 19G FNB needle, noted fibrous replacement and mild inflammation of the pancreas and was negative for malignancy. The patient was started on oral Prednisolone at a dose of 0.6mg/kg daily, gradually tapered down. She had significant clinical improvement after the treatment with reduced epigastric fullness, generalised itchiness and resolution of lacrimal and parotid glands swelling. Additionally, her liver function tests also showed significant improvement.

Differential diagnosis for her case includes Sjogren's syndrome with sclerosing pancreatitis and less likely pancreatic malignancy. However, considering the marked clinical and biochemical improvement, and unclassified variant of AIP was considered the most probable diagnosis.

In conclusion, the diagnosis and management of AIP remains challenging and necessitates the correlation of clinical, serological, radiological, histological and treatment response to glucocorticoid therapy.

A RARE CHOLESTATIC MANIFESTATION OF HEPATIC SINUSOIDAL T CELL LYMPHOMA

S C Khoo, S D Adnan

Hospital Sultanah Nur Zahirah, Terengganu, Malaysia

OBJECTIVE: To highlight the significance of diagnosing the rare diagnosis of Hepatic T Cell Lymphoma in cholestatic liver manifestation.

RESULTS: A 31 year-old female, with underlying Alpha Thalassaemia carrier, Evan's syndrome (steroid dependent) and history of splenectomy, presented with 4 months of lethargy, reduced effort tolerance, jaundice and early satiety. She had no family history of liver disease/ malignancy. On examination, there was hepatomegaly. Her investigations are as tabulated below.

Haematology was consulted, and treated her for Autoimmune Cholangitis, with methylprednisolone, but eventually not responding. She was proceeded with transjugular liver biopsy, which showed dense irregularly distributed sinusoidal infiltrate of atypical lymphoid cells, mainly within the sinusoids. The atypical lymphoid cells are positive for CD3, TIA-1 and CD56, with high Ki-67 index. Final Diagnosis: Sinusoidal T-cell Lymphoma. Despite starting on Chemotherapy (CHOP regime), patient subsequently developed severe sepsis and passed on.

DISCUSSION AND CONCLUSION: Hepatic T cell Lymphoma is a rare disease entity, which is usually diagnosed only via liver biopsy. The spleen histopathology might have added value in diagnosing the lymphoma earlier if it was sent for histopathological examination during the splenectomy in the past. Also, the thrombocytopenia due to her Evan's syndrome complicated the liver biopsy, making it feasible only with transjugular method. The lymphadenopathy noted on imagings did not seem significant ultrasonographically, thus was not biopsied. That was to be balanced with the risk of bleeding due to her thrombocytopenia as well.

Table 1: Blood results with trends

		UDCA started ↓	Methylpred ↓		Pre- chemo ↓	Post- chemo ↓	
	9/5	19/6	29/6	1/9	25/9	11/10	19/10
Hb	14.8	14	12.7	14.9	12	10.1	8.9
TWC	13	12	10	7.8	7.9	2.2	38
Platelet	33	92	164	37	15	64	76
ALT	21	27	38	78	102	35	34
AST	39	46	35	41	71	59	166
T bili	120	610	313	616	576	604	406
Direct bili	54	427	165	417	406	421	306
Indirect bili	66	183	148	199	170	183	100
ALP	240	150	96	178	210	179	187
Albumin	32	32		37	28	27	20
CRP	5.1	5.9				54	64
LDH	404	414		323			

Table 2: Aetiology work-up

Tests	Results
TSH	1.6
AFP	1.4
Coomb's	Direct positive; indirect negative
ANA, ASMA/ AMA/LKM	Negative
HepB/HepC/ HIV, RPR	Non-reactive
FBP	No Haemolysis
Retic Count	1.3
IgG4	0.35
Specific liver Ab	Negative

Table 3: Imagings

Imagings	Main Findings
US HBS	Hepatomegaly, shotty para-aortic LN
CT HBS	Cholelithiasis, enlarged para-aortic LN
MRCP	Hepatomegaly, no cholangitis/lesion.
EUS	Peripancreatic LN. CBD/PD normal.

TREATMENT OUTCOME OF TENOFOVIR DISOPROXIL FUMARATE (TDF) AMONG CHRONIC HEPATITIS B PATIENTS: A RETROSPECTIVE REVIEW IN HOSPITAL SULTANAH NUR ZAHIRAH (HSNZ)

Ahmad Syahidan Yusoff, Abdul Wafiy, Syuhada Dan
Hospital Sultanah Nur Zahirah, Terengganu, Malaysia

INTRODUCTION: Tenofovir disoproxil fumarate (TDF) is preferred as oral first-line therapy in chronic hepatitis B patients. Its safety and efficacy have been confirmed in multiple clinical trials. However, no reports have been published on the experience with TDF among Southeast Asian populations, specifically east coast Malaysia.

OBJECTIVES: The objectives of the study are to determine the proportion of chronic hepatitis B patients achieving complete virological suppression after being treated with TDF at 12 months and 24 months of therapy in Hospital Sultanah Nur Zahirah and to identify factors associated with the virological suppression.

MATERIALS AND METHODS: This was a retrospective cohort study using secondary data, which involved chronic hepatitis B patients treated with Tenofovir Disoproxil Fumarate (TDF) for at least 3 months, between 1st January 2017 and 31st December 2022. The proportion of chronic hepatitis B patients who achieved complete virological response (CVR) at the end of 12 and 24 months of therapy was evaluated. Additionally, the association of complete virological response with clinico-demographic factors, clinical outcome (liver cirrhosis-related complications, development of hepatocellular carcinoma), biochemical response, and survival status was also analysed.

RESULTS: 215 patients who fulfilled the inclusion criteria were identified. 62.8% (135 out of 215) patients achieved complete virological response at 12 months of TDF therapy, and 185 (86.1%) patients achieved complete virological response at the end of 24 months of TDF therapy. Analysis using multiple logistic regression showed the presence of HBeAg antigen as the only factor associated significantly with complete virological suppression. (OR= 8.246, 95% CI: 2.093 - 32.487, p-value = 0.003). Using chi-square tests, the association of complete virological suppression at 24 months of TDF therapy was shown to be statistically significant (p-value < 0.001) with the reduction of liver cirrhosis complications, namely variceal bleeding, ascites, spontaneous bacterial peritonitis, hepatic encephalopathy, and the incidence of hepatocellular carcinoma. Normalisation of ALT level was shown to be significantly associated with complete virological suppression at 12 months and 24 months of TDF therapy.

CONCLUSION: Our experience from this study shows that TDF is an effective therapy for chronic hepatitis B patients in our population. Induction of long-term suppression of HBV DNA should be the primary endpoint of treating chronic Hepatitis B patients as this is significantly associated with favourable clinical outcomes, preventing further disease progression and development of hepatocellular carcinoma, thus improving overall survival.

CHOLANGIOSCOPY-GUIDED LITHOTRIPSY OF A BILE DUCT STONE THROUGH A PERCUTANEOUS T-TUBE TRACT

Prakash Narayanan, K C Tan, T S Lee

Hepatology Department, Hospital Selayang, Selangor, Malaysia

OBJECTIVE: Cholelithiasis is prevalent all over the world. The management of common bile duct (CBD) stones in a patient with altered surgical anatomy can be challenging. The clinical management of complex choledocholithiasis, particularly the removal of any stones that may remain following choledochectomy especially in patient with altered anatomy, is controversial, nevertheless. We wish to present a case study of cholangioscopy-guided laser lithotripsy of a bile duct stone through a percutaneous T-tube tract in a patient with altered anatomy.

RESULT / CASE PRESENTATION: 62 years old Indian gentleman with underlying gastric carcinoma diagnosed 2008 and total gastrectomy with a Roux-en-Y reconstruction presented with right hypochondriac pain. CT abdomen shows gall bladder empyema with dilated common bile duct and distal common bile duct (CBD) soft stone and proceeded with emergency open cholecystectomy, on table cholangiogram and CBD exploration. Intraoperative findings show grossly distended gallbladder empyema and one stone impacted in the distal CBD unable to remove despite multiple attempts. Case was referred to our centre for cholangioscopy-guided laser lithotripsy of a bile duct stone through a percutaneous T-tube tract. Cholangioscopy was inserted into CBD through T Tube tract.

Distal CBD stone noted measuring around 1cm preceded with laser lithotripsy and stone fragmented. Fragmented stones drained down to small bowel.

DISCUSSION: Classically, in both open and laparoscopic CBD exploration, the T-tube is inserted to prevent bile stasis, decompression of the biliary tree, and lower the risk of bile leakage. Most recent studies restrict the indication for T-tube insertion to cholangitis, prevention of slender bile duct stenosis, or for patients with steadily impacted stones, to facilitate future stone extraction. Last indication was applied to our case due to altered anatomy and to facilitate future stone extraction.

CONCLUSION: Cholangioscopy-guided laser lithotripsy of a bile duct stone through a percutaneous T-tube tract is a safe and effective intervention to remove residual choledocholithiasis.

SUBOPTIMAL RESPONSE TO TENOFOVIR ALAFENAMIDE (TAF) IN 2 CHRONIC HBV PATIENTS: A CASE REPORT

Noor Aliza Abd Mutalib¹, Leong Chee Loon²

¹Gastroenterology Unit, Medical Department, Hospital Kuala Lumpur, Kuala Lumpur, Malaysia

²Infectious Disease Unit, Medical Department, Hospital Kuala Lumpur, Kuala Lumpur, Malaysia

In Malaysia, approximately 1.17% or 238,971 Malaysian adults aged 20 or older had chronic HBV infection. International guidelines recommend tenofovir(TDF), entecavir(ETV) and TAF , a new prodrug of TDV for the first-line treatment of HBV infection because of their efficacy and high barrier to resistance. To date, there have been no reported cases of HBV that is clinically resistant to TAF or TDF. Based on existing evidence, TDF/TAF resistance is likely to depend on the selection of suites of mutations (most commonly including L180M, A181V/T, M204I/V and/or N236T). Herein, we reported 2 cases of HBV with suboptimal response to TAF.

A 63 years old man who was diagnosed with HBeAg negative, anti-HBe positive CHB in 1999. He was started on TDF in 2015 and achieved virological suppression until 2020. He developed virological breakthrough with persistent high HBV DNA. His compliance was assessed with inquiring by the attending physician at each visit and medication possession ratio (MPR) by attending pharmacist. HBV resistance testing was performed and showed no genotypic mutations associated with tenofovir resistance (L180M, A181V/T, M204I/V, N236T and A194T) were detected. His HBV DNA was 770000 iu/ml in 2022 before changed to TAF in early 2022. He failed to achieve viral suppression with HBV DNA of 103,100 iu/ml in 2023.

A 26 year-old man is diagnosed with HIV/HBV (HBeAg positive and anti-HBe negative) coinfection in 2019. He was started on TAF/Emtricitabine and bactegrevir. His baseline HBV DNA is 31,700,000 iu/ml, HIV RNA of 67200 copies/ml and CD4 of 286 cells/ml. His HBV DNA improved to 42 iu/ml after a year of treatment. However, his HBV DNA rebounds with latest of 9,160,000 iu/ml in May 2023. He complied with medicatio as evidenced by well suppressed of HIV RNA and marked improvement of CD4 of > 600 cells/ml. His ALT remains normal throughout the treatment.

In summary, TDF/TAF therapy has been extremely successful treatment with no confirmatory resistance up to today, these cases indicated that probable cause of TAF non-response remains obscure and the number of cases remains limited.

CLINICAL AUDIT OF ENDOSCOPIC RETROGRADE CHOLANGIOPANCREATOGRAPHY (ERCP) IN HOSPITAL KUALA LUMPUR

Soo Man Jun, Lalitha Shanmugam, Rinosyah Palaniappan, Daniel Ching, Noor Aliza Mutalib

Department of Internal Medicine, Hospital Kuala Lumpur, Kuala Lumpur, Malaysia

BACKGROUND: Despite its efficacy in diagnosis and therapeutic procedures in hepatobiliary diseases, ERCP (Endoscopic Retrograde Cholangiopancreatography) carries substantial risks and data regarding its safety remains scarce. This study is aimed to evaluate the performance of ERCP in a Hospital Kuala Lumpur as a tertiary hospital in Malaysia.

MATERIALS AND METHODS: All ERCPs done from 1 Jan 2023 to 30 April 2023 done by gastroenterology unit in Hospital Kuala Lumpur (HKL) was retrospectively collected and reviewed. Data includes patients' information, indication, pathology and complications of ERCP were obtained from Malaysia Gastrointestinal Registry (MGIR) database and electronic medical record respectively. Data was subsequently recorded and analyzed in excel worksheet.

RESULTS: 171 ERCPs were performed within 4 months study period. Median age of this study population was 59 (25.5) years old. Majority are Malay (60.2%) gentleman (59.7%). The three major indication of ERCP in this study population are bile duct stone (56.5%), obstructive jaundice (19.7%) and ascending cholangitis (10.7%). Most of the patients had choledocholithiasis (71.1%) and suppurative cholangitis (10.4%). 3% of the study populations had malignant pathology (n=5). The complication rate of our study was 11.1%. Of these, most of them had bleeding (68.4%). Only 10.5% of them had perforation. 21% in our study had failed cannulation. 20.5% of the study population had PD cannulation. Among all cases of bile duct stone, 49.6% achieved complete clearance.

CONCLUSION: Our study showed that the most identified pathology is biliary trees stone and most of the procedures are mainly therapeutic to relieve the obstruction. Overall complication rate is low and half of the biliary stone achieved stone clearance.

DIAGNOSTIC DILEMMA: AN UNUSUAL CASE OF TREATED TUBERCULOSIS OF THE GUT TURNED OUT TO BE CROHN'S DISEASE WITH GYNAECOLOGICAL INVOLVEMENT

Sheng Tian Ong, Yuan Ye Beh, Ian Xiang Yuan Ch'ng, Ying Zhuang Ng, Mohamad Fadli bin Abd Rahman

Department of Gastroenterology and Hepatology, Hospital Pulau Pinang, Penang, Malaysia

INTRODUCTION: Crohn's Disease (CD) and Tuberculosis (TB) of the gut pose notable diagnostic difficulties due to mimicry in features, especially in TB endemic areas. Both diseases can affect gynaecological organs. Such involvement in CD is often difficult/late to diagnose, and have various presentations: enteric fistula, granulomatous salpingo-oophoritis, abscesses, destructive perineal disease.

CASE PRESENTATION: A 23-year-old lady presented with anaemia, diarrhoea, secondary amenorrhoea and abdominal tenderness. The diarrhoea started 8 years ago with bloody/mucous discharge. She was initially treated as TB gut (first colonoscopy showed colonic ulcers; biopsy report was unavailable; stool examination was positive for acid-fast bacilli). Despite completing 9 months of anti-TB, her symptoms never resolved, and were complicated with perianal abscess. Re-workup revealed raised inflammatory markers; fecal calprotectin 582mg/kg. CECT abdomen/pelvis showed extensive colonic wall thickening with bilateral enlarged ovaries and focal collections at pouch of Douglas, left psoas muscle, and retroperitoneal regions. Colonoscopy revealed circumferential ulcers at rectum, sigmoid and descending colon. Histopathological examination showed severe discontinuous mucosal abnormalities suggestive of CD: basal plasmacytosis, severe ulceration with crypt abscesses, non-caseating micro-granulomas. TB PCR, Acid-fast bacilli, cytomegalovirus and dysplasia were negative. She was treated with antibiotics for pelvic inflammatory disease and was started on steroids and azathioprine and is now planned for biologics.

Discussion: This case illustrates many overlapping features of TB and CD. It could be that it was not TB from the beginning (stool acid-fast bacilli has low sensitivity ranging 37%-52% and data were mostly from HIV positive patients). Now, she also had gynaecological complications apart from active flare of CD. Gynaecological presentations may precede intestinal symptoms and delay the diagnosis. Mechanism include: fistulization causing abscesses, 'metastatic deposits' forming separately from diseased bowels, or as a result of suffering from chronic disease.

CONCLUSION: Clinicians should anticipate gynaecological complications in CD and reconsider diagnosis if symptoms unresolving post anti-TB.

STEPS TO DELIVERING A COMPREHENSIVE GASTROENTEROLOGY AND HEPATOLOGY SERVICE IN A NEW HOSPITAL: A SINGLE CENTRE EXPERIENCE

M Y Yap¹, Vince¹, S Y Lau^{1,2}

¹Hospital Sultan Abdul Aziz Shah, Selangor, Malaysia

²University Putra Malaysia, Selangor, Malaysia

OBJECTIVES: Gastroenterologists specialize in caring for patients with gastrointestinal, liver and pancreato-biliary disorders. Gastroenterology is a highly investigational specialty, utilizing laboratory tests, imaging, and endoscopy for diagnosis. This study aimed to identify common cases seen in gastroenterology and hepatology clinic and outline essential services for optimal care provision in a newly established hospital.

METHODOLOGY: A retrospective analysis was performed on outpatient data extracted from hospital electronic medical records. All patients were included since the inception of our clinic on 3rd of January 2022 to 31st December 2022.

RESULTS: 173 patients were reviewed, 146 (84%) were new referrals. The cases primarily involved gastrointestinal tract 103 (59.5%), liver 51 (29.5%), pancreatobiliary 9 (5.2%), and dual pathology 10 (5.8%). 170 underwent laboratory, imaging, and/or endoscopic investigations; 45 (26%) of these utilized all three modalities for diagnosis. In terms of management, 136 (78.6%) required medications, 7 (4.1%) were referred to specialized professionals, 16 (9.2%) needed both referral and medications, and 14 (8.1%) were managed conservatively. It is worth noting that 66 (38.2%) of all patients faced challenges during their care, including 26 (39.4%) patients who experienced unavailability of diagnostic tests and 16 (24.2%) patients who required referrals to other centers. Patient compliance measured by attendance at diagnostic tests and follow-up appointments was good at 76.3%, but 5 patients had financial factors contributing to poor compliance.

DISCUSSIONS: Gastroenterology involves a wide range of disorders and relies on various diagnostic and therapeutic techniques. Access to the tests, medications, and specialized services is crucial for comprehensive care. Limited availability of these resources, especially for financially burdened patients, can compromise patient compliance.

CONCLUSION: This study provides insight to the common conditions and service utility in an outpatient setting. It serves as a foundation for developing protocols to ensure optimal care delivery in gastroenterology and hepatology.

A REAL-WORLD EVIDENCE (RWE) STUDY TO EVALUATE THE EFFECTIVENESS OF PROTON PUMP INHIBITORS (PPIS) OMEPRAZOLE AND PANTOPRAZOLE FOR SYMPTOMATIC RELIEF OF GASTRO-ESOPHAGEAL REFLUX DISEASE (GERD) / ACID PEPTIC DISEASE (APD)

Priti Panchal¹, Sandip Rungta², Debasis Basu³, Shivaji Rao⁴, Anish Kolly⁵, Ritwik Banerjee⁶, Krishna C V⁶,
Rahul Rathod⁶, Bhavesh P Kotak⁶, Gauri Dhanaki⁶

¹Thunga Hospital, Mumbai, Maharashtra, India

²AMRI Hospital, Kolkata, West Bengal, India

³Apollo Multispecialty Hospital, Kolkata, West Bengal, India

⁴Apollo Hospital, Bangalore, Karnataka, India

⁵Jaya Bhushan Hospital, Hyderabad, Telengana, India

⁶Dr Reddy's Laboratories Ltd, Hyderabad, India

OBJECTIVE: Gastro-Esophageal Reflux Disease (GERD) manifests as symptoms caused due to mucosal damage induced by reflux of gastric contents into esophagus. Proton Pump Inhibitors (PPIs), the main stay of therapy, are considered to have comparable efficacies and safety profiles. However, there is a dearth of documented data on clinical practices and outcomes; therefore, this study aims to evaluate real-world evidence (RWE) on the effectiveness and safety of omeprazole and pantoprazole in adult patients not treated for GERD within 2 weeks preceding treatment initiation with these PPIs.

METHODOLOGY: The study involves data extraction from 600 anonymized Electronic Medical Records (EMRs) procured from >15 physicians in India. Patients treated for at least 4 weeks with the PPIs are included. The primary objective is to determine the proportion of responders (patients with symptomatic relief of heartburn, regurgitation, epigastric pain, nausea, vomiting, bloating).

RESULTS: Amongst 150 patients included in interim analysis, 54 (36%) were treated with omeprazole (20mg), 48 (32%) with pantoprazole (40mg), 41 (27%) with omeprazole (40mg), and 7 (5%) with pantoprazole (80mg). The primary endpoint is comparison of responders between the two groups. At 2 weeks post treatment initiation, significantly more patients achieved relief in all symptoms when treated with omeprazole(20mg) compared to pantoprazole (40mg). Improvement in heartburn at 2 & 4 weeks is [86% (O) vs 46% (P) (p<0.001) & 92% (O) vs 73% (P) (p=0.005)]. Improvement in regurgitation at 2 & 4 weeks is [65% (O) vs 47% (P) (p=0.042) & 98% (O) vs 80% (P) (p=0.001)]. Improvement in epigastric pain at 2 & 4 weeks is [79% (O) vs 58% (P) (p=0.015) & 90% (O) vs 76% (P) (p=0.028)].

DISCUSSION & CONCLUSION: No adverse events were observed. Results reveal that omeprazole (20mg) is more effective in faster relief (at 2 weeks) of GERD/APD symptoms and is comparable to/more effective than pantoprazole (40mg) at 4 weeks depending on specific symptoms.

A PIONEERING CASE OF ENDOSCOPIC ASSISTED HIGH RESOLUTION ANOSCOPY FOR DETECTION OF DYSPLASTIC LESIONS IN ANAL EPITHELIUM - UNVEILING THE GASTROENTEROLOGIST'S PERCEPTIVE

Ruben Skantha, Ahmad Faizal Rakawi, Dzawani Muhamad, Rasnaizam Rasdi, Azlida Che Aun, Choong Yeong Sooi

Hospital Tengku Ampuan Afzan, Pahang, Malaysia

OBJECTIVE: Anal cancer is on the rise amongst HIV infected men, which are largely linked to HPV infection. Endoscopic assisted high resolution anoscopy (eHRA), is a diagnostic procedure that can be used for early detection of anal cancer; however, it is somewhat an unfamiliar territory for most gastroenterologists.

METHODOLOGY: eHRAs were performed on high-risk individuals using Olympus PCF190 and Q180 colonoscope, via Evis Exera III systems. The anal transformation zone was observed without staining, followed by acetic acid and Lugol's Iodine application to the mucosa, using an intrascope catheter. Areas of acetowhitening or lack of Lugol's staining were identified, biopsied, and reported using the Bethesda System for cervical pathology, as no standard system for anal intraepithelial lesions exists.

RESULTS: Over a 6-month period, 4 eHRAs were performed at our centre in which 3 patients had biopsy proven high grade squamous intraepithelial lesions (HSIL) while another with low grade squamous intraepithelial lesion (LSIL); and all had HPV infection. 1 patient with HSIL had a repeat procedure and lesions were treated with argon plasma coagulation. He tolerated the procedure well and showed no suspicious lesions during a repeat anoscopy 1 month later.

DISCUSSION: In a previous study, HSIL progression to overt cancer was shown to be 60% lower in those who had HSIL treatment. Although not all cases of anal cancer can be prevented with HSIL treatment, the high rate of anal cancer amongst high-risk groups emphasizes the need for effective HSIL treatment approaches and its' close follow up following treatment.

CONCLUSION: eHRA can increase the yield of detecting HSILs in high-risk populations and overcomes the gastroenterologist's limitation due to lack of experience using a microscope.

PREVALENCE OF COLORECTAL NEOPLASIA IN PATIENTS WITH CHRONIC KIDNEY DISEASE UNDERGOING COLORECTAL CANCER SCREENING: A SINGLE CENTRE EXPERIENCE IN MALAYSIA

Mohd Hasnul Helmi Zulkifli¹, Thevaraajan Jayaraman¹, Muhammad Iqbal Abdul Hafidz²,
Muhammad Ilham Abdul Hafidz¹, Rafiz Abdul Rani¹, Mohd Shahril Ahmad Saman³,
Chandromouli Annamalai¹

¹Gastroenterology Unit, Department of Internal Medicine, Faculty of Medicine, Universiti Teknologi Mara, Selangor, Malaysia

²Nephrology Unit, Department of Internal Medicine, Faculty of Medicine, Universiti Teknologi Mara, Selangor, Malaysia

³Department of Public Health Medicine, Faculty of Medicine, Universiti Teknologi Mara, Selangor, Malaysia

BACKGROUND: Chronic kidney disease (CKD) is an independent risk factor for colorectal neoplasia and carcinoma. We aimed to determine the prevalence of colorectal neoplasia and examine its associated factors in patients with CKD attending the nephrology clinic.

METHOD: This is a cross sectional single centre study conducted in a university hospital in Malaysia. The inclusion criteria were patients with CKD stages 3-5, age \geq 50 years attending the nephrology clinic from December 2021-May 2022. The exclusion criteria were history of colorectal cancer, inflammatory bowel disease and first degree relative with CRC. Recruited patients were screened with faecal immunochemical test (FIT) and were scheduled for colonoscopy if the FIT was positive. Presence of colorectal neoplasia and their characteristics were recorded based on endoscopic and histologic evaluation.

RESULTS: Out of 168 patients who fulfilled the inclusion criteria, the FIT positive rate was 34.5% (n=58). Nine patients who were FIT positive did not undergo colonoscopy, resulting in a final sample size of 159 patients. The median (IQR) age were 66 (62-71) years. There was a male gender preponderance (66%) and most of the patients were of Malay ethnicity (93.7%). The CKD stage distribution were 45.3% (n=72) CKD 3; 34% (n=54) CKD 4; 8.8% (n=14) CKD 5 not on dialysis; and 11.9% (n=19) were on dialysis. Among those who underwent colonoscopy, the polyp detection rate was 69.4% (n=34) and the adenoma detection rate was 57.2% (n=28). There was one case of colorectal cancer. The prevalence of colorectal neoplasia in our cohort of CKD patients was 18.2%. In multivariate analysis, usage of oral anticoagulant was significantly associated with colorectal neoplasia (OR 10.24, 95% CI [1.78-58.97]) (p-value 0.009).

CONCLUSION: The prevalence of colorectal neoplasia in patients with CKD was 18.2%. Usage of oral anticoagulant was a significant risk factor for colorectal neoplasia.

REBLEEDING RISK IN UPPER GASTROINTESTINAL BLEEDING: A SINGLE CENTER STUDY

G H Chan, P Nagaratnam, M F Limun, N A Bakar

Hospital Raja Perempuan Zainab II, Kubang Kerian, Kelantan, Malaysia

OBJECTIVE: The aim of this study was to identify risk factors for rebleeding after endoscopic hemostasis in patients presented with upper gastrointestinal bleeding (UGIB).

METHODOLOGY: A retrospective analysis was performed on patients with UGIB underwent therapeutic endoscopic hemostasis by Gastroenterology department HRPZII from 1st June 2022 to 31st May 2023. Oesophagogastroduodenoscopy (OGDS) reports retrieved from Malaysian Gastrointestinal Registry and reviewed. Total of 129 cases identified, of which 17 cases had rebleeding (within 30 days) and underwent repeated therapeutic endoscopic intervention. Data was analyzed using IBM SPSS Statistics.

RESULTS: A total of 129 patients were studied, of which 65.1% (n=84) were male. Mean age was 61.8±12.4. 30-days rebleeding after initial endoscopic hemostasis occur in 17 patients (13.2%). Out of 17 patients who rebled, significant comorbidities include hypertension (n=12), diabetes mellitus (n=9), chronic kidney disease (n=5) and chronic liver disease (n=3). Among variables compared, gender, age group and timing of index endoscopy (whether done within office hours) did not have significant association with rebleeding. The rate of rebleeding was higher among nonvariceal UGIB compared to variceal UGIB (p=0.043). Among cases of nonvariceal UGIB (n=86), Forrest Ia lesion had higher risk of rebleeding compared to other lesions (p=0.046).

CONCLUSION: Despite successful endoscopic hemostasis, Forrest Ia lesion was associated with higher risk of 30-days rebleeding, and might therefore be considered to be observed more closely in high dependency ward.

AN AUDIT OF REFERRAL FOR ANEMIA WITHOUT APPARENT GI BLEEDING IN A TERTIARY PUBLIC HOSPITAL

C Y Wong, L T Gew, P B C Philip, A M Noor Aliza

Hospital Kuala Lumpur, Kuala Lumpur, Malaysia

OBJECTIVE: Anemia is a common cause for inpatient referral for endoscopy investigation for gastrointestinal (GI) blood loss. There was clear guideline on timing of endoscopy investigation and intervention for overt GI bleeding and clear-cut-low-ferritin anaemia. Nonetheless, there was lack of clear indicator for endoscopy investigation for anaemia without apparent GI bleeding, especially when it was done during acute illness. We carried out an audit in a Hospital Kuala Lumpur (HKL) to determine the yield of endoscope and determine how this could change our practice for inpatient scope for this group of patients.

METHODOLOGY: 130 patients that had undergone endoscope for anaemia without GI bleeding from July 2022 to April 2023 in HKL was included. Patient characteristics, indication of referral, blood parameter of the patients, factor potentially affecting hemoglobin level during admission and the endoscope findings were collected.

RESULTS: Total of 168 scopes was carried out. 50.1%, 38.5%, 3.1% and 1.5% of patient was found to have potential bleeding lesion, no bleeding lesion, stigmata of recent bleed and lesion require endotherapy respectively. 4 out of 5 patients with endoscopic diagnosis of tumor were found to have low ferritin of <50ng/ml. Out of the 130 patients, there were only 1 patient has clear indication for in-patient endotherapy for Forrest IIb peptic ulcer disease.

DISCUSSION AND CONCLUSION: Current audit show 1.5 % of the patient benefitted from in-patient endoscopy intervention for anaemia without GI bleeding. Majority of the patient could be managing as early-out-patient endoscopy service. Ferritin <50 seemed to be the best indicator for in-patient endoscopy investigation as it may alter the in-patient management significantly with diagnosis of colon cancer. Further better-designed study needs to verify this finding and to find effective indicator to triage the endoscopy investigation for the in-patient referral for anaemia without apparent GI bleeding.

A CASE OF POST-COLONOSCOPY COLORECTAL CANCER: THE IMPORTANCE OF QUALITY COLONOSCOPY

A Muhamad¹, M Y Yap¹, S Y Lau^{1,2}

¹Hospital Sultan Abdul Aziz Shah, Selangor, Malaysia

²University Putra Malaysia, Selangor, Malaysia

BACKGROUND: Colonoscopy is an effective screening and diagnostic tool when performed well. Post-colonoscopy colorectal cancer (PCCRC), defined as a cancer found after a negative colonoscopy performed within the past 3 to 5 years is deemed preventable in 80% of cases. We report a case of a near-obstructing rectosigmoid tumour found after a negative colonoscopy thirteen months prior.

CASE REPORT: A 66-year-old man was seen for investigation of left sided abdominal pain, chronic constipation, haematochezia and 10kg unintentional weight loss over 2 years. He had a gastroscopy and colonoscopy performed a year ago for similar symptoms. Blood tests were unremarkable including a normal haemoglobin of 13.4g/dL. A CT thorax, abdomen and pelvis showed abnormal thickening of the distal sigmoid colon. We performed a colonoscopy which showed a near-obstructing rectosigmoid adenocarcinoma confirmed on biopsies. The documentation on his index colonoscopy report was sparse with no information about adequacy of bowel preparation or sedation used despite them being in the reporting template. There was no photo-documentation available.

DISCUSSION: Colorectal cancer (CRC) remains prevalent in Malaysia, contributing to 13% of all new cancer cases in 2020. CRC typically follows an adenoma-carcinoma sequence, hence screening and removal of adenomas by colonoscopy serve the most effective means of preventing CRC. A 10-year follow-up study showed an 18% risk reduction in CRC through screening and surveillance colonoscopies. International guidelines now recommend extending surveillance to 10 years for individuals whose index colonoscopy showed no or low risk findings. This is provided that the index colonoscopy was done with high quality. Adequate bowel preparation, scope withdrawal time of 6 minutes or more, high caecal intubation and adenoma detection rates for endoscopists, and good polypectomy technique are important factors for quality colonoscopy.

CONCLUSION: This case emphasizes the importance of quality colonoscopy and clear documentation, both written and visual.

A RARE CASE OF ACUTE LIVER FAILURE IN SEVERE DENGUE

Jeshwina J, Jasvinee S, W Abdullah W Z A, Shahril N S
Hospital Putrajaya, Wilayah Persekutuan Putrajaya, Malaysia

INTRODUCTION: Acute liver failure (ALF) in dengue fever is rare and carries extremely poor prognosis with severe hepatic involvement commonly occurs at second week of illness.

OBJECTIVE: To illustrate a rare case of acute liver failure associated with dengue fever.

CASE SUMMARY: A 59 years old woman with underlying hypertension on Amlodipine 5 mg daily presented at day 3 with fever, vomiting and epigastric pain. She denied taking any traditional medications. On examination she was alert, orientated with blood pressure 135/58mmHg, heart rate 98 beats per minute, afebrile with oxygen saturation 97% under room air. She was jaundiced but did not have hepatosplenomegaly, ascites or stigmata of chronic liver disease. Her lungs were clear. Blood investigations showed aspartate transaminase (AST) 6989 iu/l, alanine transaminase (ALT) 2939iu/l, alkaline phosphate (ALP) 149 iu/l, international normalised ratio (INR) 2.6 with metabolic acidosis [pH 7.22, bicarbonate 15 mmol/l and lactate 6.3mmol/l]. NS-1 antigen was positive at day 2 of illness. Hepatitis serology was non-reactive. She was commenced on N-acetyl cysteine (NAC) according to the ALF regime [100mg/kg/day = 7000mg]. Subsequently, 24 hours later she developed grade III hepatic encephalopathy with highest peak of liver enzymes [AST 12045 iu/l and ALT 3836iu/l]. She completed 5 days regime of NAC and showed clinical improvement in conscious level with normalization of liver enzymes and was discharged home on day 14.

DISCUSSION: This case demonstrates the rare presentation of ALF in dengue fever, presenting in the first week of illness. NAC had shown to improve survival in early (grade I or II) liver failure stage with its role in reducing oxidative stress, increasing blood flow to the liver and its direct antiviral activity.

CONCLUSION: NAC may have a role in acute liver failure associated with Grade III hepatic encephalopathy in severe dengue.

COMPARATIVE ANALYSIS OF SENSITIVITY AND SPECIFICITY OF ULTRASOUND FINDINGS OF DILATED INTRAHEPATIC DUCT IN DIAGNOSING CHOLEDOCHOLITHIASIS: A COMPARISON WITH ENDOSCOPIC ULTRASOUND

K G Lew, L T Gew

Hospital Kuala Lumpur, Kuala Lumpur, Malaysia

BACKGROUND: Cholelithiasis, the presence of gallstones in the common bile duct (CBD), requires prompt diagnosis for proper management. Ultrasound is commonly used to detect dilated intrahepatic duct (DIHD), a suggestive finding of cholelithiasis. However, the accuracy of DIHD on ultrasound compared to endoscopic ultrasound (EUS) has not been extensively evaluated. We aimed to assess the diagnostic performance of DIHD on ultrasound in comparison to EUS, considering various patient characteristics and laboratory parameters.

METHODS: We conducted a retrospective analysis of medical records for patients with suspected cholelithiasis from January 2023 to June 2023. Patients who underwent both ultrasound and EUS were included. Baseline characteristics (age, sex) and laboratory parameters (TW, CRP, ALP, ALT, AST) were recorded. Sensitivity, specificity, positive predictive value (PPV), negative predictive value (NPV), and accuracy were calculated for DIHD on ultrasound using EUS as the reference standard.

RESULTS: A total of 32 patients met the inclusion criteria. DIHD on ultrasound had a sensitivity of 50% and specificity of 100% for diagnosing cholelithiasis. The PPV was 100% and NPV was 22.22%. Overall accuracy was 56.25%. Subgroup analysis showed that age and sex did not significantly affect the diagnostic performance of DIHD on ultrasound. However, elevated TW, CRP, ALT, AST, and ALP levels were associated with an increased likelihood of cholelithiasis.

CONCLUSION: DIHD on ultrasound is a highly specific but low sensitive finding for diagnosing cholelithiasis compared to EUS. Age and sex did not significantly influence diagnostic accuracy. Elevated TW, CRP, ALT, AST, and ALP levels were associated with a higher likelihood of cholelithiasis. These findings can assist clinicians in deciding when to use ultrasound and EUS in the diagnostic workup of suspected cholelithiasis patients.

INITIAL SUCCESS EXPERIENCE IN EUS INTERVENTION AS SALVAGE THERAPY FOR ACUTE GASTRIC VARICEAL BLEEDING: A SINGLE CENTER EXPERIENCE

Cha Chee Tan, Lai Teck Gew, Chung Yeow Wong, Philip Pang, Noor Aliza Binti Abd Mutalib

Hospital Kuala Lumpur, Kuala Lumpur, Malaysia

INTRODUCTION: Acute gastric varices bleeding (AGVB) commonly treated with cyanoacrylate injection or endoscopic variceal ligation. It is an effective treatment with success rate of 93.9%. TIPPS, plug/balloon assisted retrograde transhepatic occlusion (P/BARTO) and surgical shunt the options after failed conventional therapy. EUS-guided variceal intervention for gastric varices had emerged as an effective modality for AGVB.

PATIENT AND METHODS: There were 35 patient with acute gastric varices presented in in January 2022 to March 2023 in Kuala Lumpur General Hospital. All cases were treated with conventional endoscopically cyanoacrylate injection into gastric varices. However 2 of the cases was failed to stop bleeding and rescued by EUS guided therapy. First patient was a 42-year-old lady with cryptogenic liver cirrhosis whom had GOV-2 with life-threatening bleeding despite of endoscopic cyanoacrylate injection. Hemostasis was achieved with EUS-guided 1.5 cc glue injection at the small feeding varices proximal to the initial glue injection site. Similarly, the second patient was a 48-year-old man whom was diagnosed with alcoholic liver cirrhosis. presented with persistent bleeding after endoscopic glue injection of GOV-1. EUS-guided coiling was performed to the feeding vessels proximal to the site of glue injection and hemostasis was achieved endoscopically and sonographically (absent of flow after the coiling).

DISCUSSION: EUS-guided varices intervention has advantage of localizing and injecting targeted varix with sonographic image. This is important especially after the first initial attempt for cyanoacrylate injection endoscopically as further unsuccessful trial of endoscopic injection of glue may ended up submucosally or at the non-feeding vessels, which in turn subject the patient for further invasive therapy with increased morbidity and cost. Moreover, the procedure can be done in same setting when the equipment and expertise are readily available. More research is needed to define the role of EUS-intervention for gastric varices bleeding in acute setting.

PRECUT VS CONVENTIONAL SPHINCTEROTOMY: AN AUDIT ON BLEEDING COMPLICATION AND RATE OF SUCCESS ON BILE DUCT CANNULATION IN HOSPITAL KUALA LUMPUR

**Cha Chee Tan, Lai Teck Gew, Chee Men Lu, Ken Guan Lew, Chung Yeow Wong, Philip Pang,
Noor Aliza Binti Abd Mutalib**

Hospital Kuala Lumpur, Kuala Lumpur, Malaysia

INTRODUCTION: Precut sphincterotomy is a technique to assist bile duct cannulation after failed conventional method. Recently, American Society of Gastrointestinal Endoscopy suggested that pre-cut fistulotomy may be a safer approach as compared to conventional precut sphincterotomy. We have audited the rate of selective bile duct cannulation and compared the bleeding complication among the three methods of biliary access.

METHODOLOGY: We retrospectively analyse data from 1st April 2021 to 31st April 2023. Only ERCP with native papillae were included. The rate of successful cannulation and complication of both methods were measured.

RESULTS: 608 cases were included in this study. Among them, 579 patients were diagnosed with choledocholithiasis, and 29 patients were diagnosed with malignancy. The successful cannulation rate was 95.2%. Sphincterotomy was performed in 541 patients and the rest was cannulated/stented without sphincterotomy for various reason. 455, 80, and 6 patients had undergone conventional sphincterotomy, conventional precut sphincterotomy and pre-cut fistulostomy respectively. Immediate bleeding rate of conventional sphincterotomy was 14.51% while conventional precut sphincterotomy was 15.0%. 6 precut fistulostomy had no bleeding.

DISCUSSION: In this audit, it appears to us that the risk of bleeding of conventional precut sphincterotomy was similar to conventional sphincterotomy. Fistulotomy seemed to be a safer approach in terms of bleeding, but larger number of the procedure needed to conclude this.

THE PREVALENCE OF CLOSTRIDIUM DIFFICILE INFECTION IN THE TERTIARY CARE CENTER IN SARAWAK

Nurul Husna Baharudin, Victoria Kok Shinq Ling, Alisa Hanum Binti Arba'eni @ Arbaen

Gastroenterology Unit, Department of Internal Medicine, Sarawak General Hospital, Kuching, Sarawak, Malaysia

OBJECTIVE: To determine the prevalence, risk factors, clinical outcome, and 30 days readmission rate of patients with adult clostridium difficile infection (CDI) in patients admitted to Sarawak General Hospital from January 2022 until June 2023.

METHODS: This is a retrospective cross-sectional study. We reviewed the test result of patients who underwent stool testing for clostridium difficile antigen and toxin and identified patients who tested positive. Reviewing the patient's medical record, the demographic details and clinical information were obtained. The risk factors, clinical outcome, and 30 days readmission rate were identified and analyzed.

RESULTS: From January 2022 until June 2023, 967 adult patients underwent stool testing for clostridium antigen and toxin. We reviewed the test result and a total of 34 tested positive (antigen + toxin positive). This study found that the overall prevalence of adult CDI is 3.52 %. Out of the reviewed data, 70% were male and 30% were female. 26% of them age >65 years old, and 90% have previous antibiotic exposure. 64% of the patients have underlying cardiac disease and chronic kidney disease, which are risk factors for CDI. We also found that 81% of the patients were discharged home, with 30 days readmission rate are 6%, however, it is not due to a gastrointestinal-related problem. The study found that 95% of our patients were given proton pump inhibitors (PPI) as GI prophylaxis.

CONCLUSION: The prevalence of adult CDI in a tertiary center in Sarawak is 3.52%, similar to the neighboring state's local prevalence. The majority of them have previous antibiotic exposure and co-morbidities of cardiac disease and chronic kidney disease, which have been established as risk factors for developing CDI. The role of PPI as an independent risk factor for CDI needs further study in the future.

RECURRENT HEPATIC HYDROTHORAX, A DISEASE ENTITY THAT LACKS IT'S MUCH NEEDED RECOGNITION AND MANAGEMENT STRATEGIES

R Thivaganesh, W A Wan Zaharatul Ashikin

Hospital Putrajaya, Wilayah Persekutuan Putrajaya, Malaysia

Recurrent hepatic hydrothorax, as uncommon as it sounds, poses a real challenge to the treating physicians. It typically presents as a transudative pleural effusion, most commonly in the setting of chronic liver disease and clinically significant portal hypertension. Appropriate diagnostic measures including the cause of decompensation must be sought. Patient's care will be directed by a hepatologist. Here, we present a case of recurrent hepatic hydrothorax and the management strategies.

CASE REPORT: We present a 69year old gentleman with decompensated liver cirrhosis secondary to MAFLD (Child Pugh B-8) with clinically significant portal hypertension, previous history of decompensated with variceal bleeding, hepatic encephalopathy and ascites.

This time around presented intially with pleural effusion and gross ascites. Management with repeated pleural ascites tap, no continuous drainage done. Pleural fluid investigation were transudative, likely hepatic hydrothorax. All other workups including hepatitis, autoimmune, malignancy and infective causes were ruled out. Patient was on dietary salt restriction as well diuretics, adjusted accordingly to achieve desired therapeutic effect

DISCUSSION: Hepatic hydrothorax refers to the presence of pleural effusion in a patient with liver cirrhosis in the absence of other causes. It occurs in 5-15% of patients with cirrhosis. The management strategies are similar to ascites which includes dietary sodium restriction, diuretic and symptomatic pleural drainage. Placement of chest tubes may lead to massive protein and electrolyte depletion, infection, renal failure and bleeding, except in spontaneous bacterial empyema and refractory hydrothorax. Refractory hydrothorax is associated with increased mortality rate. Available treatment options are repeated thoracentesis, pleurodesis, TIPS, liver transplanation, thoracoscopic repair of diaphragmatic defects. However these managements strategies have their own complications and risk. More data is needed to further facilitate the management strategies.

PANCREATIC PSEUDOCYST DRAINAGE WITH HOT-AXIOS STENT IN ASYMPTOMATIC PREGNANT LADY: OUR EDGY EXPERIENCE

Mohd Noor Nashriq Umar Othman¹, Kok Wei Hao¹, Ngiu Chai Soon², Azlanudin Azman³, Ani Amelia Zainuddin⁴, Yazmin Yaacob⁵, Khairul Najmi Muhammad Nawawi¹

¹Gastroenterology Unit, Department of Medicine, Faculty of Medicine, Universiti Kebangsaan Malaysia, Kuala Lumpur, Malaysia

²Gastroenterology Unit, Cardiac Vascular Sentral Kuala Lumpur, Kuala Lumpur, Malaysia

³Hepatopancreatobiliary Surgery, Department of Surgery, Faculty of Medicine, Universiti Kebangsaan Malaysia, Kuala Lumpur, Malaysia


⁴Department of Obstetrics and Gynecology, Faculty of Medicine, Universiti Kebangsaan Malaysia, Kuala Lumpur, Malaysia

⁵Department of Radiology, Faculty of Medicine, Universiti Kebangsaan Malaysia, Kuala Lumpur, Malaysia

A pancreatic pseudocyst is a collection of enzymatic fluid that is encased and protected by a well-constructed inflammatory wall that is surrounded by fibrous tissue. Pancreatic pseudocysts complicate 5% of cases of pancreatitis or fewer than 1 in 60,000 deliveries. However, the treatment of this sporadic condition is not standardized.

In this scenario, we reported a case of asymptomatic 24 years old lady at 15 weeks of gestation with incidental finding of pancreatic pseudocyst during antenatal scan, which was later confirmed by ultrasound (USG) abdomen and magnetic resonance imaging (MRI) abdomen noted a sizeable cystic mass (7.9 x 12.9 x 11.9) cm between the spleen and kidney, suggestive of pancreatic pseudocyst. Multidiscipline team (MDT) meeting between the between gastroenterologist, hepatobiliary surgeon, obstetrician, and radiologist regarding the benefit and risk of intervention versus without intervention and risk of enlarging cyst towards delivery was done. Subsequently, at 20 weeks of gestation, the patient underwent successful endoscopic ultrasound guided cystogastrostomy and drainage of pancreatic pseudocyst under general anesthesia (GA) with insertion of a lumen-apposing metal stent (LAMS) hot AXIOS 10 mm (length) x 15mm (diameter). Prior the EUS procedure, she was given progesterone injection by the obstetrician team as prophylaxis against premature contractions.

Day one post procedure, she developed fever with abdomen pain and antibiotic was escalated from Ceftriaxone to Tazobactam & Metronidazole. Patient was transferred and monitored in intensive care unit. Abdomen x-ray was done, showed stent still in position and no air under diaphragm. Repeated OGDS was performed under GA noted stent was in situ with no bleeding or necrotic material. IV antibiotic were continued for a week and subsequently patient was discharged. Follow-up 2 months post stent insertion at 28 weeks of gestation, a repeated imaging show resolved pseudocyst and LAMS stent was removed. Prior 1 month of the expected date of delivery, repeated USG showed remained resolved pseudocyst. Another follow-up 3 month post-partum with USG, showed no evidence of pseudocyst and she was discharged back to the primary care.



In conclusion, pancreatic pseudocyst during pregnancy seem to follow the same natural course as they do in non-pregnant patients, and most commonly linked to alcoholic pancreatitis. Concern for increased risk of rupture during pregnancy or during vaginal birth exists despite the fact that the patient was asymptomatic and no risk factors contributing to pancreatitis. Given the fact that majority of cases are treated conservatively, MDT meeting with multiple discipline team is important to explained the risk and benefit to patient regarding antepartum treatment options such as percutaneous or endoscopic drainage. If the situation managed carefully, a favorable conclusion can be attained for the health of both fetus and the mother.

THE PREVALENCE OF HELICOBACTER PYLORI INFECTION IN MULTI-RACIAL COMMUNITY AT HOSPITAL SULTANAH AMINAH, JOHOR BAHRU

S Y Ngeoh, W C Liew, S L Lee, M S Firdaus

Hospital Sultanah Aminah, Johor Bahru, Johor, Malaysia

OBJECTIVE: The main objective of this retrospective study is to determine the prevalence of *H. pylori* infection in patients who underwent endoscopy with Rapid Urease Test (RUT). This study aims to identify the demographic characteristics of *H. pylori* infection in our population and assess the associated gastrointestinal characteristics.

METHOD: This retrospective single-center study population included all patients who underwent esophagogastroduodenoscopy (OGDS) with rapid urease test at our center between May 2021 and May 2023. Baseline demographic and clinical characteristics were collected using the electronic medical record system. Data analysis was conducted using SPSS, with Person's Chi-Square Test employed as the analytical technique.

RESULT: A total of 3,976 patients were included in this study, with a mean age of 55 years old (± 16). The prevalence of *H. pylori* infection was 12.4% (493/3,976) in the overall population. Among different races, Indian had the highest infection rate (20.9%, 124/593), followed by others (20.1%, 35/174), Chinese (11.0%, 141/1280), and Malay (10.0%, 193/1929). The prevalence of *H. pylori* infection varied significantly between racial groups ($P < 0.001$). In terms of age, the highest infection rates were observed among individuals aged less than 30 years old, while infection rates exhibit higher in male (13.1%, 257/1965). However, the association between age group and gender with *H. pylori* infection were not significant ($P > 0.05$). *H. pylori* infection was significantly associated with dyspepsia as an indication for OGDS ($P < 0.001$). The study also found significant associations between *H. pylori* infection and gastritis, gastric ulcer and gastric tumor ($P < 0.05$).

DISCUSSION AND CONCLUSION: The overall prevalence of *H. pylori* infection in Hospital Sultanah Aminah Johor Bahru is low 12.4%. *H. pylori* infection prevalence rates vary among ethnic groups in Malaysia, being highest in Indians followed by Chinese and lowest in Malays and this finding coherent with some other local studies.

Association between *H. pylori* infection and Demographic factors

Demographic factors	n (%)			P value
	Overall (n= 3976)	RUT positive (n=493)	RUT negative (n=3483)	
Age Categories				
<30 years old	373 (9.3)	53 (14.2)	320 (85.8)	0.291 ^a
30-49 years old	1087 (27.3)	147 (13.5)	940 (86.5)	
50-69 years old	1766 (44.4)	207 (11.7)	1559 (88.3)	
≥70 years old	750 (18.9)	86 (11.5)	664 (88.5)	
Gender				
Male	1965 (49.4)	257 (13.1)	1708 (86.9)	0.199 ^a
Female	2011 (50.6)	236 (11.7)	1775 (88.3)	
Ethnicity				
Malay	1929 (48.5)	193 (10.0)	1736 (90.0)	<0.001 ^a
Chinese	1280 (32.2)	141 (11.0)	1139 (89.0)	
Indian	593 (14.9)	124 (20.9)	469 (79.1)	
Others	174 (4.4)	35 (20.1)	139 (79.9)	

RUT, Rapid Urease Test

^aPerson's Chi-Square Test

Association between *H. pylori* infection and Gastrointestinal Characteristics

Indications For OGDS	n (%)	RUT positive	RUT negative	P value
		n (%)	n (%)	
Dyspepsia	1570	233 (47.3)	1337 (38.4)	<0.001 ^a
Persistent vomiting	42	3 (0.6)	39 (1.1)	0.299 ^a
GERD like symptoms	241	38 (7.7)	203 (5.8)	0.102 ^a
Dysphagia/Odynophagia	131	12 (2.6)	118 (3.4)	0.382 ^a
OGDS findings				
Esophagitis	511	74 (15)	437 (12.7)	0.126 ^a
Esophageal ulcer	47	6 (1.2)	41 (1.2)	0.939 ^a
Gastritis	2634	395 (80.1)	2239 (64.3)	<0.001 ^a
Gastric ulcer	297	60 (12.2)	237 (6.8)	<0.001 ^a
Gastric tumor	33	8 (1.6)	25 (0.7)	0.038 ^a

RUT, Rapid Urease Test; OGDS, esophagus duodenoscopy procedure

^aPerson's Chi-Square Test

MANAGEMENT OF HEPATIC SARCOIDOSIS: A SYSTEMATIC REVIEW

Ram Prasad Sinnanaidu¹, Vikneshwaran Chandra Kumar², Ranita Hisham Shunmugam³,
Sanjiv Mahadeva¹

¹Gastroenterology Unit, Medical Department, Universiti Malaya Medical Centre, Kuala Lumpur, Malaysia

²Medical Department, Hospital Tuanku Ja'afar Seremban, Negeri Sembilan, Malaysia

³Universiti Malaya Library, Universiti Malaya, Kuala Lumpur, Malaysia

OBJECTIVE: Hepatic sarcoidosis is an uncommon clinical condition in which clear recommendations are lacking in its treatment. We aimed to review systematically the literature on hepatic sarcoidosis treated by corticosteroids and/or immunosuppressive agents in order to propose treatment algorithm which may provide useful guidance to clinicians managing this challenging condition.

METHODS: Using MEDLINE, PubMed, CINAHL, Cochrane, and Google Scholar databases, we found original articles on corticosteroid and/or immunosuppressive therapies for hepatic sarcoidosis from inception to 31 July 2022. We used 'Hepatic Sarcoidosis' and 'Corticosteroid' as keyword in our searches. We base our methods on Prisma statement and checklist.

RESULTS: Out of 612 references that been retrieved from the data bases, 38 published study were finalized. This includes total of 272 patients. Out of this, 186 patients were started on corticosteroids as first line treatment. Ursodeoxycholic acid (UDCA) has been used as another option for first line, given to 40 patients as monotherapy or as a combination with corticosteroids. Second line therapy which includes azathioprine (AZA), methotrexate (MTX), mycophenolate mofetil (MMF) and cyclophosphamide have shown mix treatment response with AZA and MTX given most promising profile as steroid sparing agent. Anti TNF only used in very limited studies with limited information provided.

CONCLUSION: Corticosteroid is first line treatment for hepatic sarcoidosis. UDCA is a potential alternative used in hepatic sarcoidosis either single agent or add on therapy with promising outcomes. Conventional immunosuppressive therapy as steroid sparing agents shown good outcomes despite some adverse effect been reported. Anti TNF usage was scarcely reported with only 2 studies highlighted the benefits. Overall, due to heterogeneity of study design with rarity of disease, we unable to make clear recommendations.

Keywords: Hepatic sarcoidosis; Corticosteroids; Liver; Infliximab

A CASE SERIES OF EARLY ENDOSCOPIC THERAPY FOR UPPER GASTROINTESTINAL BLEEDING IN DENGUE FEVER

Tian Ming Yeo, Noor Purdah Abdul Kadir, Nik Razima Wan Ibrahim, Norhaniza Bahar, Ee Keng Lim,
Rosaida Hj Mohd Said

Hospital Sultan Idris Shah Serdang, Selangor, Malaysia

INTRODUCTION: Dengue fever is a vector-borne illness endemic in tropical areas worldwide, which is estimated to cause 36,000 deaths annually. Severe dengue can manifest as overt bleeding, of which gastrointestinal (GI) bleeding is among the commonest sites. Here we present a case series of upper GI bleeds in dengue fever treated endoscopically.

CASE REPORTS: Patient 1 presented at day 5 of illness. Upon presentation, he was in compensated shock with hyperlactatemia. He then passed out melena with Hb drop of 2 g/dL. Urgent endoscopy showed haemorrhagic pangastritis, multiple Forrest 2b ulcers in antrum, and diffuse Forrest 2c ulcers in duodenum. Haemostatic powder was applied.

Patient 2 presented at day 4 of illness. He was haemodynamically stable but had melenic stools. Early endoscopy showed Forrest 2a ulcer at prepyloric and diffuse Forrest 2c ulcers in duodenum. Hemoclip was applied to prepyloric ulcer followed by haemostatic powder.

Patient 3 presented at day 5 of illness. He was haemodynamically stable, but had melena and anemia (Hb 10.4g/dL). Early endoscopy showed Forrest 1b ulcer at incisura, and multiple Forrest 3 ulcers at antrum and duodenum. Hemoclip was applied to the incisura ulcer after 0.01% Adrenaline injection.

Patient 4 presented at day 5 of illness. He was haemodynamically stable but had melena and Hb drop of 2g/dL. Urgent endoscopy showed severe reflux esophagitis with an esophageal tear and antral erosive gastritis. Hemoclip was applied to the tear followed by haemostatic powder. All patients also received packed cell transfusions.

CONCLUSION: All 4 patients remained stable with no further episodes of bleeding. This showed that early endoscopic intervention (within 12 hours) presented adverse outcomes from GI bleeding in dengue fever. Endoclips were effective in focal bleeding while haemostatic powder was effective in diffuse bleeding.

FINDING OF RELOOK/SECOND GASTROSCOPE WITHIN 1 WEEK AFTER THE FIRST HEMOSTASIS IN PATIENT WITH NON-VARICEAL UGIB: A RETROSPECTIVE REVIEW

C Y Wong, L T Gew, P B C Philip, A M Noor Aliza

Hospital Kuala Lumpur, Kuala Lumpur, Malaysia

OBJECTIVE: Generally, most guidelines suggest against routine second-look upper gastrointestinal (GI) endoscopy after index endoscopy therapy for Upper GI bleeding (UGIB). This practice should only be applied to selected patients, especially those with a high-grade lesion that was deemed inadequately treated, or as a safety measure before early initiation of antiplatelet or anticoagulant therapy. We conducted a retrospective review of patients who underwent repeated endoscopy within a week to determine the value of this practice.

METHODOLOGY: We extracted all patients who underwent endoscopic hemostasis for UGIB caused by peptic ulcer disease, specifically those with an initial high-grade lesion (F1, F2a, F2b) in the index gastroscopy. Second-endoscopy was performed one week after the index gastroscopy to reevaluate the previous bleeding lesion. This data was collected from January 2018 to April 2023 at Hospital Kuala Lumpur. The Forrest classification was used for risk stratification of non-variceal UGIB, dividing it into high grade lesions (F1, F2a, F2b) and low-grade lesions (F2c, F3).

RESULT: 102 patients were recruited for this study. Of the patients who underwent the reevaluation endoscopy, 76 patients (74.6 %) were found to have downgraded to a low-grade lesion, while 26 patients (25.4 %) still showed high grade lesions on the second gastroscopy. Out of those 26 patients, 22 required additional endotherapy to achieve hemostasis.

DISCUSSION AND CONCLUSION: When relook endoscopy was planned by the endoscopist, it proved to be of great value as a high proportion of patients still had had-grade lesions, and a significant number of them required further endoscopic treatment. Further assessment of this patient group and the development of objective criteria for second-look endoscopy should be carried out in a larger population with a better-designed study methodology.

TRAINING MODELS FOR ADVANCED ENDOSCOPIC PROCEDURES IN A MULTI RACIAL SETTING

P Nagaratnam^{1,2}, Hari Suthan¹, Gew L T¹

¹Hospital Kuala Lumpur, Kuala Lumpur, Malaysia

²Hospital Raja Perempuan Zainab II, Kelantan, Malaysia

INTRODUCTION: In training novice endoscopists for advanced endoscopy procedures, in vivo and ex vivo animal models, mainly porcine models or specialized and expensive training models are usually used. In a multi racial country where porcine models are not suitable due to religious practices, we explored alternative, cheap, but effective training techniques.

METHODOLOGY AND OUTCOME:

1. Advanced Luminal Endoscopic Procedure

An ex vivo model was created with goat's intestine for a training practice session.

The goat's intestine cost RM38 to obtain.

This was then washed and laid open. Hemorrhoid banding gun was used to band the mucosa to create lesions mimicking polyps. Subsequently, the intestine was fixed on a curved cardboard and placed in an enclosed clear box with an open end for scope insertion.

The trainee endoscopists then used a colonoscope to identify the 'lesions', raise them with methylene blue and perform resections for practice Endoscopic Mucosal Resection Techniques.

This was done successfully by all the trainees during the session.

2. Endoscopic Ultrasound Guided Fine Needle Biopsies

We initially attempted this using goat's stomach, but was not successful as the penetration for the ultrasound was poor.

We then made an ultrasound phantom using edible jelly mixture.

1L of water was boiled with agar mixture (RM 10) and then poured into a large plastic container. Grapes (RM10) were placed within the agar mixture at various levels and this was then placed in the refrigerator until it cooled down and solidified.

The container was then placed in an enclosed clear box with an open end for scope insertion.

Trainee endoscopists practised using the endoscopic ultrasound to identify the grapes which mimicked lymph nodes endosonographically. 22G Needles were used to practice fine needle biopsy techniques. Samples of cores of grapes were obtained successfully during the session.

CONCLUSION: These two techniques described above are not only feasible, but are cheap and easily reproduced and religiously sensitive models for training junior endoscopists who are starting their journey in advanced endoscopy.

BACTERIOLOGICAL ANALYSIS AND ANTIBIOTIC SENSITIVITY PATTERN OF ENDOSCOPIC RETROGRADE CHOLANGIO-PANCREATOGRAPHY-OBTAINED BILE CULTURES

C Vikneshwaran Chandra Kumar¹, Ee Hong Siow¹, Nor Zanariah Zainol Abidin², Sattian Kollanthavelu¹

¹Gastroenterology and Hepatology Unit, Department of Medicine, Hospital Tuanku Ja'afar, Seremban, Negeri Sembilan, Malaysia

²Microbiology Unit, Department of Pathology, Hospital Tuanku Ja'afar, Seremban, Negeri Sembilan, Malaysia

OBJECTIVE: Patients diagnosed with ascending cholangitis will require early initiation of empirical antibiotics followed by adequate biliary draining. Bacteriological analyses were performed on endoscopic retrograde cholangio-pancreatography (ERCP)-obtained bile cultures in patients undergoing ERCP for suspected biliary infection.

METHODOLOGY: In this retrospective, single-centre study, we reviewed medical records of all patients who underwent ERCP from June 2021 till April 2023 for ascending cholangitis and had ERCP-obtained bile cultures.

RESULTS: Nine-eight patients (40% male, mean age 53.5 ± 18.5 years, range 28-89 years) had recorded ERCP-obtained bile culture taken for suspected ascending cholangitis. Aetiology of the biliary obstruction in almost ninety percent (n=88) of the patients were benign biliary disease [79/88 had choledocholithiasis] and malignant disease was seen in ten patients. The bile culture was positive for bacterial growth in 54 out of 98 (55.1%) patients, and fourteen (26%) of these patients had polymicrobial growth. From the total seventy organisms isolated, the most frequently encountered organisms were Gram-negative bacteria (n=66/70; 94.3%), including *Klebsiella pneumoniae* [25.7% (18/70)], *Escherichia coli* [21.4% (15/70)], *Pseudomonas aeruginosa* [11.4% (8/70)], and *Citrobacter freundii* [12.9% (9/70)]. Amikacin and Piperacillin-Tazobactam had 95.5% susceptibility followed by Meropenem, Cefipime, Ciprofloxacin and Ceftazidime which showed 80-90% susceptibility against Gram-negative organisms. Highest resistances were noted in Ampicillin, Cefazolin and Cefuroxime (susceptibility less than 50%).

CONCLUSION: ERCP-obtained bile cultures give valuable information on more accurate selection of empirical antibiotics in the local setting.

MICRO RNAs 21 AND 221 ARE NEGATIVELY CORRELATED WITH HEPATIC AND INTESTINAL TIGHT JUNCTION INTEGRITY IN THE PATHOGENESIS OF EXPERIMENTAL HEPATOCARCINOGENESIS

Balasubramanian Vairappan, Victor Mukherjee, Amit Kumar Ram

Liver Diseases Research Lab, Department of Biochemistry, Jawaharlal Institute of Postgraduate Medical Education and Research, Puducherry, India

BACKGROUND: The gut-liver axis has attracted more attention in recent years. Our recent study sowed a key role of the gut microbiome in liver cancer. MicroRNAs are becoming increasingly popular in cancer research and are dysregulated in cancer, acting as oncogenes or tumor suppressors. We aimed to elucidate the role of nimbolide (limonoid) in regulating specific microRNAs (21, 145, and 221) and hepatic and intestinal tight junction integrity in an experimental HCC.

METHODS: Diethyl nitrosamine and N-nitrosomorpholine induced HCC mice were administered Nimbolide (6mg/kg b.wt.), a tetranotriterpenoid from the neem tree orally for four weeks following induction of HCC at 28 weeks.

RESULTS: We found significantly increased expressions of miR21a-5p (30-fold) and 221-3p (10-fold) in HCC. Treatment with Nimbolide to HCC mice significantly decreased the miRs 21a-5p and 221-3p expressions. However, miR145 did not alter between groups. Moreover, hepatic and intestinal tight junction-associated proteins like claudin-2, zonula occludens (ZO)-1 associated nucleic acid-binding protein (ZONAB) and occludin were significantly decreased whilst significantly increased hepatic and intestinal expression of claudin-1 was noted in HCC. The epithelial-mesenchymal transition (EMT) marker E-cadherin expression was decreased along with increased CDK4, PCNA, Bcl-xL, and N-cadherin protein expressions in HCC mice. Nimbolide treatment to HCC mice positively regulated the above indices.

CONCLUSION: Our novel data suggested that Nimbolide supplementation to HCC mice improved miRs 21a-5p & 221-3p expressions and associated diminished tight junction integrity in the gut-liver axis thereby decreasing the severity in HCC mice.

ACUTE EPSTEIN-BARR VIRUS (EBV) INFECTION CAUSING SEVERE HEPATITIS IN AN IMMUNOCOMPETENT PATIENT: A CASE REPORT AND REVIEW

Ian Xiang Yuan Ch'ng, Yuan Ye Beh, Sheng Tian Ong, Ying Zhuang Ng, Mohamad Fadli bin Abd Rahman

Department of Gastroenterology and Hepatology, Hospital Pulau Pinang, Penang, Malaysia

INTRODUCTION: Epstein Barr virus (EBV) is a ubiquitous gammaherpesvirus. Although treatment is supportive, its infection can range from asymptomatic to the development of lymphoproliferative and neuroimmunological diseases. EBV frequently affects the liver but is mostly subclinical/self-limiting.

CASE REPORT: A 32-year-old gentleman with no known medical illness was admitted due to unresolved fever for 2 weeks associated with lethargy, epigastric discomfort, nausea and sore throat. He denied recent travel or supplement/traditional medicine intake. On examination, his GCS was full, with generalized lymphadenopathy and mild hepatosplenomegaly. His liver function was grossly deranged: alanine aminotransferase (ALT) 1064U/L, alkaline phosphatase (ALP) 372U/L, aspartate transaminase (AST) 519U/L with normal bilirubin level and coagulation profile. His lowest albumin was 29g/L. He also has thrombocytopenia (121×10^3 uL) and lymphocytosis (11.5×10^3 /uL). Viral screening (HIV, CMV, Hep A,B,C), leptospirosis, dengue, acetaminophen level, malaria blood film, connective tissue screening were all negative. Despite treating with intravenous ceftriaxone and hydration, his ALT worsened to 1324U/L and he became more lethargic and required IV N-acetylcysteine (NAC) infusion. Anti-EBV viral capsid antigen (VCA-IgM) was sent and came back positive. He was given supportive treatment and close monitoring. Fortunately, his symptoms and hepatitis improved over days and was discharged well after a week.

DISCUSSION: This case fulfilled Hoagland criteria (specific for infectious mononucleosis - an EBV associated disease). Compared to heterophile antibodies, VCA-IgM is more sensitive and specific. 75% of patients exhibit 2-3-fold increase in ALT. Transaminitis usually resolves in 2-3 weeks, however complications like cholestasis, chronic hepatitis, and liver failure have been reported. Role of NAC is unknown in the treatment of EBV related hepatitis due to absence of clinical trials, although animal studies did show potential.

CONCLUSION: EBV should be considered as a potential cause of acute hepatitis. Low index of suspicion is required and future research should fill gaps with regards to its treatment.

CASE REPORT ON PATIENT WITH ACUTE FATTY LIVER IN PREGNANCY WITH NEWLY DIAGNOSED AIH

Balakrishnan Asha Gayatheri, Zalwani M S

Department of Gastroenterology and Hepatology, Hospital Sultanah Bahiya, Kedah, Malaysia

Acute fatty liver of pregnancy (AFLP) is a rare and potentially fatal condition characterized by microvesicular steatosis and liver failure. Diagnosis is usually based on the Swansea criteria in conjunction with serologic and biochemical testing although liver biopsy can be performed under certain circumstances. Treatment involves early diagnosis, prompt fetal delivery, and intensive supportive care with recovery expected over the ensuing days to weeks.

CASE REPORT: 36-year-old gravida 5 para 4 patient at 36 weeks gestation, presented to an outside hospital with a 3 days of epigastric pain, nausea and yellowish discoloration. She had WHO class I obesity (BMI 31.1 kg/m²) but was otherwise healthy. Initial laboratory tests showed a white blood cell count (WBC) 10 k/ μ L, hemoglobin (Hgb) 12 g/dL, platelets (PLT) 215 k/ μ L, normal blood smear, aspartate aminotransferase (AST) 443 IU/L, alanine aminotransferase (ALT) 570 IU/L, alkaline phosphatase (ALP) 431 IU/L, and total bilirubin (TB) 190/dL. International normalized ratio (INR) 4.77. Abdominal ultrasound showed hepatic steatosis. An emergency lower segment cesarean section (LSCS) was performed. Four days later, she was in grade 3 Hepatic encephalopathy and she was intubated for cerebral protection. Laboratory testing revealed WBC 17 k/ μ L, Hgb 9.1 g/dL, PLT 59 k/ μ L, AST 84 IU/L, ALT 115 IU/L, ALP 205 IU/L, TB 263 mg/dL, albumin 25 mg/dL, serum creatinine 118 mg/dL, and international normalized ratio (INR) 3.2 mg/dL. A CT brain performed was normal. A CTPA was done to exclude pulmonary embolism. She was referred to our facility due to her hepatic decompensation. Preeclampsia and HELLP were considered, but unlikely based on absence of hypertension, appropriate platelet count, and normal peripheral smear. She was diagnosed as Acute Fatty liver in pregnancy (AFLP) fulfilled Swansea criteria with acute liver failure. She was supported for 3 weeks in Intensive care unit. She was extubated after 3 weeks with full GCS recovery. Laboratory testing revealed WBC 11.2 k/ μ L, Hgb 9.3 g/dL, PLT 73 k/ μ L, AST 65 IU/L, ALT 30 IU/L, ALP 104 IU/L, TB 225.9 mg/dL, albumin 20 mg/dL, serum creatinine 86 mg/dL, and international normalized ratio (INR) 1.44 mg/dL. Another bout of Hospital acquired illness impeded her recovery. Laboratory testing prior to discharge revealed WBC 10.1 k/ μ L, Hgb 9.1 g/dL, PLT 73 k/ μ L, AST 210 IU/L, ALT 140 IU/L, ALP 104 IU/L, TB 303 mg/dL, albumin 21 mg/dL, serum creatinine 51 mg/dL, and international normalized ratio (INR) 1.2 mg/dL. She was seen in the clinic 2 weeks post discharge. At that visit, she was well with mild jaundice. Laboratory testing revealed WBC 10.1 k/ μ L, Hgb 10.1 g/dL, PLT 156 k/ μ L, AST 127 IU/L, ALT 124 IU/L, ALP 82 IU/L, TB 82 mg/dL, albumin 33 mg/dL. IgG was 33. A liver biopsy was performed. In view of persistent hyperbilirubinemia and transaminitis and raised immunoglobulin G, she was diagnosed as autoimmune hepatitis. Oral steroids were started after the liver biopsy.

Liver biopsy revealed interface hepatitis and swollen hepatocytes steatosis which is microvesicular. She biochemical parameters significantly improved after steroid initiation. Laboratory testing revealed PLT 265 k/ μ L, AST 55 IU/L, TB 16 mg/dL, albumin 33 mg/dL.

DILI VS AIH: A CLINICAL CHALLENGE

Noor Purdah¹, Nik Razima Wan Ibrahim¹, Norhaniza Bahar¹, Ee Keng Lim, Muhamad Yusuf¹,
Mohd Isnisyam Saaya²

¹Gastroenterology Unit, Hospital Sultan Idris Shah, Selangor, Malaysia

²Department of Pathology, Hospital Selayang, Selangor, Malaysia

BACKGROUND: Drug induced Liver Injury (DILI) is defined by presence of some degree of liver injury, commonly detected by elevated liver enzymes, caused by drugs, herbal and dietary supplement. Where else, Autoimmune Hepatitis (AIH) is a complex immune-mediated liver disease that is diagnosed histologically by interface hepatitis and high serum levels of alanine aminotransferase (ALT), aspartate aminotransferase (AST) and immunoglobulin G (IgG) with the presence of autoantibodies. A frequent clinical challenge is represented by the differential diagnosis between DILI and AIH, especially when AIH is seronegative, or level of serum IgG are normal.

CASE PRESENTATION: This is a case report 42-year-old Malay lady who presented to our centre with the complaint of dark colour urine for 1 month. It was associated with pale stool, lethargy, legs itchiness, epigastric pain and nauseated. She also had jaundice a week prior to presentation and reduce appetite with significant loss of weight 2 kg in a month. She has no past medical illness, but she had history of longstanding taking slimming pills and herbal supplement for more than a year. Clinically she was alert, jaundice, no encephalopathy, and abdomen soft non tender with no organomegaly or ascites. Blood parameter showed ALT 382, AST 482, IgG 20 (Ref:7-16g/dl), Antinuclear antibody (ANA) positive but other liver specific antibodies were negative. Ultrasound abdomen showed starry sky appearance and histologically in liver biopsy presence of periportal interface hepatitis involving more than 50% of portal tracts. With those findings it supports the diagnosis of AIH and DILI excluded. She was treated with oral prednisone and azathioprine. She showed dramatically improvement with the treatment and to date her liver function was normalised.

CONCLUSION: DILI can manifest with autoimmune characteristics and drugs could represent the trigger of AIH. Histology could be a great value in this cases and marked decrease in serum transaminases after corticosteroid therapy has been recently proposed as *ex juvantibus* tool to discriminate DILI from AIH.

Keywords: Inflammation, Drugs-induce liver injury, Autoimmune Hepatitis

IMPROVING GUT DYSBIOSIS IN SPINAL CORD INJURY BY USING MULTI-STRAIN PROBIOTICS: AN ANIMAL MODEL EXPERIMENT

M N Azmi², Y Yaacob², M Danniya¹, R A Raja Affendi^{3,4}, P Azim¹

¹Department of Neurosciences, Universiti Sains Malaysia, Kubang Kerian, Kelantan, Malaysia

²Biomechanics Laboratory, School of Mechanical Engineering, Universiti Teknologi MARA, Selangor, Malaysia

³School of Medical and Life Sciences, Sunway University, Selangor, Malaysia

⁴Gut Research Group, Faculty of Medicine, Universiti Kebangsaan Malaysia, Kuala Lumpur, Malaysia

INTRODUCTION: Spinal cord injury (SCI) is known to affect gut dysbiosis that leads to gut dysfunction. However, the mechanism following SCI, related to gut dysbiosis is unknown. The study aims to develop a stable and reliable SCI with gut dysbiotic animal model for potential application of multi-strain probiotic treatment regimens post SCI.

METHODOLOGY: Female Wistar rats were randomly assigned to 4 groups: control, control with antibiotics, SCI with antibiotics, and SCI with antibiotics and probiotics. Gut dysbiosis was induced by administering antibiotics via drinking water after a standard contusion injury using New York University Impactor. Hexbio, a multi-strain probiotic containing lactobacillus and bifidobacterium enriched with acid lactic producing bacteria, was orally administered daily for 6 days at a dose of 3g of 1×10^9 CFU/kg. Vital organs were cultured in nutrient agar to confirm bacteria translocation and gut dysbiosis following SCI. Locomotor recovery and gait analysis were performed at day 7, 14, 21, and 28 post-probiotic treatment. Fecal samples were collected at similar time point for 16s rRNA sequencing in all 4 groups.

RESULTS: A total of 24 rats were studied. Following SCI, there were a clear evidence of bacterial translocation except in control group. Number of bacterial colonies growth significantly increased compared to control, in all selected organs ($p < 0.05$). The locomotor recovery and gait analysis were significantly improved in probiotic treating group at day 14 ($p < 0.04$) and day 28 ($p < 0.05$). The bacterial diversity also shown significant changes between probiotic treated group; injured group ($P < 0.05$), control with antibiotic group ($p < 0.01$) but not significant with control group ($p > 0.05$).

DISCUSSIONS/CONCLUSIONS: Following SCI, application of multi-strain probiotic, Hexbio appeared to improve gut dysbiosis along with behaviour analysis and demonstrated early recruitment of endogenous stem cells for repair activity. Hence, there is a potential clinical use of Hexbio post SCI and it requires further translational study.

PREVALENCE OF CHRONIC KIDNEY DISEASE IN HEPATITIS C PATIENTS AND THEIR OUTCOMES WITH DIRECT ACTING ANTIVIRAL (DAA) THERAPY IN HOSPITAL TENGGU AMPUAN AFZAN

M F Arifin¹, K A Jaafar¹, M A Md Jalil¹, A Che' Aun²

¹International Islamic University Malaysia, Kuantan, Pahang, Malaysia

²Hospital Tengku Ampuan Afzan, Kuantan, Pahang, Malaysia

INTRODUCTION: Hepatitis C virus (HCV) is a global health burden. HCV infection is independently associated with chronic kidney disease (CKD)¹. The prevalence of CKD in HCV varies globally from 10.36-11.2% (US)^{2,3} and 5.43-7.6% (Taiwan)^{4,5}.

OBJECTIVE: This study aims to determine the prevalence of CKD among HCV patients who are being treated at Hospital Tengku Ampuan Afzan (HTAA), and the outcome of DAA therapy in chronic HCV with CKD, as well as their effect on patients' renal function.

METHOD: This was a retrospective cross-sectional study at a single treatment center, HTAA, from January 2018 to October 2022. Data collected includes eGFR pre and post DAA treatment, sustained virologic response at 12 weeks (SVR 12) and other comorbidities.

RESULTS: A total of 150 out of 230 patients screened were enrolled for data collection. All 150 patients were treated with generic Sofosbuvir and Daclatasvir. In our cohort, the prevalence of CKD in chronic HCV was 29%. Among them, 50% are CKD stage 1, 32% CKD stage 2, 12% CKD stage 3a, and 6% CKD stage 3b. 45.3% of patients showed significant improvement in eGFR, and the majority of the population, 53.3% were experiencing insignificant changes in eGFR. Only 1.3% (n=2) patients showed worsening of eGFR. All the patients achieved SVR12, claiming 100% response rate.

DISCUSSION: The prevalence of CKD in HCV was higher in our cohort at 29%. However, this could be due to study limitations from a single center experience. This study echoed some other studies that prove clearing HCV infection reduces mortality and complications such as CKD6.

CONCLUSION: The prevalence of CKD in HCV was high (29%). Achieving SVR12 significantly improved renal function (45%). Generic DAA showed promising SVR12 rates in our cohort.

ECHINOCOCCOSIS, A DISEASE ENTITY THAT IS EXTREMELY RARE YET RELENTLESSLY INTERESTING

R Thivaganesh, Wan Zaharatul Ashikin

Hospital Putrajaya, Wilayah Persekutuan Putrajaya, Malaysia

Hydatid cyst, as rare as it is in Malaysia, is often a diagnostic dilemma.

This is a case of incidental discovery of hydatid cyst in a gentleman and the diagnostic workup that has been done.

This case is meant to bring more awareness to include this uncommon differential diagnosis despite not being endemic in Malaysia

CASE REPORT: We hereby present a 59 year old gentleman, with known medical illness and is a chronic smoker and regular alcohol consumer. Has a strong family history of gastrointestinal malignancy and a routine medical check up revealed persistently elevated AFP.

MRI liver showed multiple rim enhancing lesions and complex cystic lesions with non functioning left adrenal adenoma.

Repeated CT imaging showed multiple liver lesions with intralesional smaller calcifications dots that is highly suggestive.

Otherwise he is asymptomatic and well and pending serology. Liver enzymes is within normal limits.

DISCUSSION: Echinococcosis, a multisystem disease, more commonly involving lungs and liver, is spread by oral enteral route and contamination from farm animals.

It is distinct by its asymptomatic incubation and long latent periods. Symptoms are caused by mass effect and other complications such as rupture, secondary bacterial infection.

The diagnosis is straightforward with a constellation of clinical, serology and suggestive radiological findings, however it requires a very high index of suspicion.

Other causes such as polycystic liver disease, abscess, infective, malignancy cause needs to be ruled out as well.

The treatment is with antiparasitic agents and surgical intervention which includes resection and percutaneous aspiration. Relapses are not uncommon.

CONCLUSION: Echinococcosis requires a multidisciplinary approach. Risk versus benefit is a key deciding factor in management. Further strategies and required to prevent relapses.

FROM GUT TO BLOOD: DECODING IRON DEFICIENCY ANEMIA IN GASTROINTESTINAL TRACT

Y Z Tay, P Nagaratnam, M F Limun, G H Chan, N A Bakar

Hospital Raja Perempuan Zainab II, Kelantan, Malaysia

OBJECTIVE: This retrospective single center study was done to look at the outcome of patients who had endoscopies done for iron deficiency anaemia (IDA).

METHODOLOGY: Data of patients who had upper GI endoscopy and colonoscopy under gastroenterology's unit in Hospital Raja Perempuan Zainab, Kota Bharu from the Malaysia Gastrointestinal Registry (MGIR) from January 2019 to June 2023 (54 months) was extracted. Data of patients who had their endoscopy done due to iron deficiency anaemia were then further analyzed.

RESULTS: A total of 63 patients had both OGDS and colonoscopy done for iron deficiency anaemia. Mean age was 58. Among them, 52% (n = 33) were male, and 48% (n =30) were female. The most prevalent of endoscopic cause of iron deficiency anemia were identified as follows: hemorrhoids accounted for 25% (n=16) of cases, followed by colonic polyps at 21% (n=13), and peptic ulcer disease at 19% (n=12).

Other causes included lower gastrointestinal malignancy constituted 6%(n=4) of cases, followed by solitary rectal ulcer syndrome (SRUS) and angiodysplasia at 3% each (n=2), and NSAID-induced and Dieulafoy lesion at 1.5% each (n=1). We could not find 10 patients (15.8%) with endoscopic findings, they were given follow up with iron supplement and planned for capsule endoscopy.

CONCLUSION: This study reiterated the importance of performing endoscopy in patient with iron deficiency anaemia with no overt GI bleeding or GI's symptoms as a majority had significant findings.

ATYPICAL MANIFESTATION OF A LARGE POLYP IN A YOUNG PATIENT WITH IRRITABLE BOWEL SYNDROME

Y C Tang¹, Naim Syahidah Zulkafli², Zalwani Zainuddin¹

¹Gastroenterology Unit, Internal Medicine Department, Hospital Sultanah Bahiyah, Alor Setar, Kedah, Malaysia

²Pathology Department, Hospital Sultanah Bahiyah, Alor Setar, Kedah, Malaysia

Solitary rectal ulcer syndrome (SRUS) is an uncommon benign entity with protean clinical and endoscopic manifestations, including hyperemic mucosa, ulceration, and broad based polyp.

We illustrate our clinical encounter with a young gentleman with long standing irritable bowel syndrome having new complain of intermittent sensation of mass prolapsing out of anal canal with per rectal bleeding. Colonoscopy reveals a large pedunculated polyp with ulcerated surface, subsequently removed with hot snare polypectomy. The histopathologic finding is consistent with SRUS.

This case highlights the importance of clinical assessment and correlation in interpreting endoscopic and histopathologic findings, and SRUS should be considered as differential diagnosis for large pedunculated polyp.

ANTI-HBS LEVEL PATTERN AMONG CHRONIC HEMODIALYSIS PATIENTS IN A PUBLIC HOSPITAL SETTING

K A Jaafar¹, A Z Shukor²

¹International Islamic University of Malaysia, Kuantan, Pahang, Malaysia

²Hospital Kemaman, Kemaman, Terengganu, Malaysia

Background: Persistent uraemia in chronic haemodialysis patients is known to impair their immune system making them more susceptible than the general population to get Hepatitis B Virus (HBV) infection. A complete course of HBV immunisation can provide adequate protection as long as the anti-HBs antibody level produced is more than 100mIU/ml.

OBJECTIVE: The goal of this study is to identify the variables that may contribute to a poor response to immunisation, which is indicated by an anti-HBs antibody level below 100 mIU/ml.

METHOD: 55 chronic haemodialysis patients from Hospital Tengku Ampuan Afzan (HTAA), Kuantan were recruited into this study. The mean age of participants was 42.2 years old (SD±2.8) ranging from 18 to 82 years old. Anti-HBs antibody level was measured 3 months post-HBV immunisation.

RESULTS: 81.8% (N=46) of the participants were good responders while the remaining 18.2% (N=9) were poor responders. Statistical analyses were done using IBM SPSS version 26.0. Initial univariate analysis showed significant relationship between Chinese ethnicity (N=9, p=0.016), uncontrolled diabetes (N=12, p=0.045) and anaemia (N=43, p=0.019) among poor responders. Logistical regression analysis showed uncontrolled diabetes as the only variable with statistically significant negative impact towards immunisation response (p=0.031).

CONCLUSION: This preliminary study involving patients from a single public haemodialysis centre showed uncontrolled diabetes as a strong predictor for poor response towards HBV immunisation among chronic haemodialysis patients.

REBLEEDING RISK IN UPPER GASTROINTESTINAL BLEEDING: A SINGLE CENTRE STUDY

G H Chan, P Nagaratnam, Y Z Tay, M F Limun, N A Bakar
Hospital Raja Perempuan Zainab II, Kota Bharu, Kelantan, Malaysia

OBJECTIVE: The aim of this study was to identify risk factors for rebleeding after endoscopic hemostasis in patients presented with upper gastrointestinal bleeding (UGIB).

METHODOLOGY: A retrospective analysis was performed on patients with UGIB underwent therapeutic endoscopic hemostasis by Gastroenterology department HRPZII from 1st June 2022 to 31st May 2023. Oesophagogastroduodenoscopy (OGDS) reports retrieved from Malaysian Gastrointestinal Registry and reviewed. Total of 129 cases identified, of which 17 cases had rebleeding (within 30 days) and underwent repeated therapeutic endoscopic intervention. Data was analyzed using IBM SPSS Statistics.

RESULTS: A total of 129 patients were studied, of which 65.1% (n=84) were male. Mean age was 61.8+-12.4. 30-days rebleeding after initial endoscopic hemostasis occur in 17 patients (13.2%). Out of 17 patients who rebled, significant comorbid include hypertension (n=12), diabetes mellitus (n=9), chronic kidney disease (n=5) and chronic liver disease (n=3). Among variables compared, gender, age group and timing of index endoscopy (whether done within office hours) did not have significant association with rebleeding. The rate of rebleeding was higher among nonvariceal UGIB compared to variceal UGIB (p=0.043). Among cases of nonvariceal UGIB (n=86), Forrest Ia lesion had higher risk of rebleeding compared to other lesions (p=0.046).

CONCLUSION: Despite successful endoscopic hemostasis, Forrest Ia lesion was associated with higher risk of 30-days rebleeding, and might therefore be considered to be observed more closely in high dependency ward.

EFFECTS OF SHORT-TERM ANTIBIOTIC USAGE ON GUT MICROBIOME: INSIGHTS FROM A COHORT STUDY IN YOUNG CHILDREN

Bavdekar A¹, Kawade A², Veligandla K C³, Joshi D K³, Neha³, Rathod R³, Kotak Bhavesh³

¹KEM Hospital, Pune, India

²Shirdi Sai Baba Rural Hospital, Pune, India

³Dr Reddys Laboratories Ltd, Hyderabad, India

INTRODUCTION: Antibiotics despite being lifesaving medications have a profound negative impact on the delicate balance of the gut microbiome. They produce collateral damage and have implications on the overall health and well-being of individuals particularly in early childhood.

OBJECTIVE: This study was aimed to assess the impact of short-term antibiotic usage on the gut microbiome dynamics in young children.

METHODOLOGY: This multi-centric cohort study was conducted across 02 sites in Pune, India. It included 54 participants aged 3-5 years, divided into two groups: the first group received oral or intravenous antibiotics, while the second group included healthy participants without antibiotic treatment. Stool samples were collected from all participants on day 0 and day 5 (+/- 1 day) of the study and analysed using 16SrRNA gene sequencing.

RESULTS: Both groups experienced a mean relative increase in the abundance of the Firmicutes phylum, more pronounced in the healthy participants compared to those on antibiotic treatment. The Firmicutes/Bacteroidetes ratio (F/B ratio) was altered, suggesting a shift in the overall microbial composition of the gut. β -diversity indices in the antibiotic treated group were more heterogeneous on day 5 as compared to the other group. A significant ($p < 0.05$) high relative abundance of Enterobacteriaceae, Enterococcaceae and Lactobacillaceae was observed in the participants with antibiotic treatment over participants without antibiotic treatment. Furthermore, the relative abundance of Escherichia-Shigella, Enterococcus, Lactobacillus, Sellimonas, Ruminococcus torques group and Eggerthella was significantly higher ($p < 0.05$) in participants with antibiotic treatment.

DISCUSSION: Health Care Practitioners must consider damage to gut microbiome while prescribing antibiotics to children.

CONCLUSION: The study found that even short-term antibiotic usage in young children was associated with altered microbial abundance and diversity in the gut.

Keywords: short term antibiotic, gut microbiome, young children, F/B ratio, β -diversity indices, alteration

EXPLORING INTESTINAL BARRIER DYSFUNCTION IN INFLAMMATORY BOWEL DISEASE PATIENTS WITH TREATED VEDOLIZUMAB: IMPLICATIONS FOR THERAPEUTIC RESPONSE

Nurul Aqilah Shahabudin¹, Raja Affendi Raja Ali^{2,3}, Norfilza Mohd Mokhtar^{1,2}

¹Department of Physiology, Faculty of Medicine, Universiti Kebangsaan Malaysia, Kuala Lumpur, Malaysia

²GUT Research Group, Faculty of Medicine, Universiti Kebangsaan Malaysia, Kuala Lumpur, Malaysia

³School of Medical and Life Sciences, Sunway University, Selangor, Malaysia

OBJECTIVE: Vedolizumab (VDZ) is used for the treatment of moderate to severe inflammatory bowel disease (IBD), Crohn's Disease (CD) or ulcerative colitis (UC). However, up to 40% of patients demonstrate minimal therapeutic response. Various factors such as intestinal barrier dysfunction, dysregulated genes, and mucosal barrier defects, may affect the responsiveness of VDZ therapy. We aim to focus on the roles of intestinal barrier function in IBD patients pre and post VDZ therapy.

METHODOLOGY: RNA was extracted from 25 colonic biopsies of (UC=14, CD=11) pre-VDZ and 11 biopsies post-VDZ (n=8 responder and n=3 non-responder) IBD patients. Normal colorectal mucosa (n=10) was used as control. The cDNA was amplified by qPCR using QuantiNova SYBR Green PCR kit for intestinal barrier genes: mucin 1 (MUC1), claudin 8 (CLDN8), and occludin (OCLN). Ultrathin sections (80-90 nm) of VDZ responder and non-responder samples were cut by ultramicrotome and examined under transmission electron microscope (TEM) for the ultrastructural features on tight junction (TJ), gap junction (GJ), and desmosomes gap width.

RESULTS: In pre-VDZ therapy, intestinal barrier genes (MUC1 and OCLN) expression demonstrated significantly decreased among IBD patients while CLDN8 was significantly higher by 2.19-fold as compared to controls ($p < 0.05$).

VDZ responders demonstrated significantly upregulated of CLDN8 gene by 5.96-fold as compared to control ($p < 0.05$). However, VDZ non-responders demonstrated significantly downregulated of CLDN8 gene by 0.18-fold as compared to control ($p < 0.05$).

TJ and GJ gap widths were significantly wider in VDZ non-responders (674 nm and 692 nm, respectively) than in VDZ responders (331 nm and 397 nm, respectively) ($p < 0.05$). There was no significant difference in desmosome gap width between groups.

DISCUSSION AND CONCLUSION: Downregulation of intestinal barrier gene, CLDN8 along with wider tight and gap junctions (leaky gut) may be responsible for the non-responsiveness of VDZ therapy in IBD patients.

RISK OF HEPATOCELLULAR CARCINOMA AMONG CHRONIC HEPATITIS C WITH CIRRHOSIS AFTER ACHIEVED SVR12: A RETROSPECTIVE REVIEW IN HOSPITAL SULTANAH NUR ZAHIRAH (HSNZ)

Ahmad Syahidan Yusoff

Hospital Sultanah Nur Zahirah, Kuala Terengganu, Terengganu, Malaysia

BACKGROUND: Management of Hepatitis C virus (HCV) infection has been greatly evolved in the last few years. Currently, the newer treatment direct acting antivirals (DAAs) promise a higher rate of efficacy to compare to previous treatment, pegylated interferon. The goal of HCV treatment is to eradicate the virus and to avoid the progression of liver fibrosis and HCV-related disease. Sustained virologic response (SVR) is the most widely used efficacy endpoint in clinical studies of hepatitis C and represents the eradication of HCV from the body. This study was conducted to determine the associated factors among cirrhotic patients develop hepatocellular carcinoma after SVR12 within 2 years.

OBJECTIVE: The aim of the study was to determine the change in liver stiffness measurements after successful treatment with DAAs in chronic Hepatitis C with liver cirrhosis between 2018 till December 2022 by using APRI and FIB4 and determine the factors associated with changes in the status of liver fibrosis.

METHOD: Study design was retrospective cohort, and the study involved a total of 56 patients from Hospital Sultanah Nur Zahirah, Kuala Terengganu. It involved adults above 18 years old and had achieved SVR-12 with DAAs (Sofosbuvir + Daclatasvir) with or without Ribavirin regardless of treatment naïve or experience, presence of cirrhosis or virus genotype. They were evaluated using APRI scores > 1.5, FIB-4 scores > 2.67 and US Hepatobiliary at the baseline and SVR-12.

RESULTS: The changes in mean (SD) APRI score were 2.34 (3.04) at baseline to 1.67 (1.07) after SVR12, while the mean (SD) FIB-4 score was from 4.70 (4.03) at baseline to 2.89 (2.97) after SVR-12. The multiple regression analysis revealed that clinical data including platelet, AST and ALT were significant predictors of advanced fibrosis (P 0.05). Only 0.67 percent of patients developed HCC after achieving SVR within 2 years, thus the median survival time cannot be determined.

CONCLUSION: Our study has demonstrated a significant reduction in liver stiffness (based on APRI and FIB-4) after achieving SVR-12 among cirrhotic patients. Clinical data including platelet count and ALT and AST levels are significant independent predictors of liver fibrosis. After achieving SVRs, the risk of developing hepatocellular carcinoma is extremely low.

PERCUTANEOUS TRANSLUMINAL ANGIOPLASTY (PTA) IN A PATIENT WITH BUDD-CHIARI SYNDROME AFTER LIVER TRANSPLANT: A CASE REPORT

Shih Mun Yong¹, Su Wen Chuah¹, Shazatul Ezanni Binti Shamsudin², James Emmanuel¹, Raman Muthukaruppan¹

¹Department of Gastroenterology and Hepatology, Queen Elizabeth Hospital, Kota Kinabalu, Sabah, Malaysia

²Department of Radiology, Queen Elizabeth Hospital, Kota Kinabalu, Sabah, Malaysia

INTRODUCTION: Inferior vena cava (IVC) occlusion due to liver transplantation is relatively uncommon with an estimated incidence of 1-6%, usually occurs in the early phase post liver transplant. The subsequent rise in hepatic sinusoidal pressure can lead to portal hypertension, renal failure, graft failure and ultimately death, depending on the level of occlusion.

CASE DESCRIPTION: Here is a case of a 64-year-old gentleman who underwent a living donor liver transplant 8 years ago. He presented with right hypochondrium pain, ascites and bilateral lower limbs oedema for 6 months. The diagnosis of (IVC) obstruction was detected via venous doppler and this was confirmed using computed tomography (CT) venogram. Fluoroscope imaging showed IVC stenosis at the level of hepatic vein tributaries. Balloon dilatation was performed, post intervention venogram showed stenotic segment has been improved. However the occlusion relapsed a month later with worsening ascites and a repeat balloon venoplasty was done. The symptoms improved post second venoplasty.

DISCUSSION: Percutaneous transluminal angioplasties (PTA), either via transjugular or transhepatic method, can help to restore anastomotic patency. However, it is limited by the risk of restenosis which necessitates repeat angioplasty. An alternative is to place a stent at the site of caval stenosis, which technical success rate of 88-100% and clinical success rate of 86% in post-liver transplant patients. The patency rate is 96.7% with duplex ultrasonography for IVC stents at mean follow-up of 58 months. In refractory cases, surgical portosystemic shunt placement and liver transplantation have been described in literature, however, there was insufficient consensus regarding this clinical practise.

TREATMENT OF FUNCTIONAL DYSPEPSIA BASED ON SUBTYPE COMPARED TO EMPIRICAL PROTON PUMP INHIBITOR: AN INTERIM ANALYSIS OF A RANDOMIZED CONTROLLED TRIAL

Qing Yuan Loo¹, Kee Huat Chuah¹, Wen Xuan Hian¹, Xin Hui Khoo¹, Muhamad Ammar Furqan bin Zulkifly¹, Sarala Panirsheelum², Nurhidayah binti Mohammad Jubri², Vicraman Natarajan², Hooi Min Lim³, C Vikneshwaran Chandra Kumar¹, Stanley Khoo¹, Sanjiv Mahadeva¹

¹Gastroenterology and Hepatology Unit, Department of Medicine, Faculty of Medicine, Universiti Malaya, Kuala Lumpur, Malaysia

²Staff & Student Health Unit, Universiti Malaya Medical Centre, Kuala Lumpur, Malaysia

³Department of Primary Care Medicine, Faculty of Medicine, Universiti Malaya, Kuala Lumpur, Malaysia

OBJECTIVE: Functional dyspepsia (FD) has a greater burden compared with other functional GI disorders in secondary care. This burden may be reduced by more effective management strategies. We aimed to compare the treatment efficacy of FD according to subtype (intervention), versus empirical proton pump inhibitor (PPI) (control).

METHODOLOGY: We performed a single-blind, randomized controlled trial of adults with FD (Rome IV criteria) in secondary care. In the intervention group, patients were categorized into Epigastric Pain Syndrome (EPS) (treatment-Esomeprazole); Postprandial Distress Syndrome (PDS) [treatment-prokinetic (Itopride)] and overlapped syndrome[treatment-Itopride, maintain, add, or switch to Esomeprazole at week 4]. The primary efficacy outcome is the assessment of global symptom improvement (using the seven-point Likert Scale) over 8 weeks. Secondary outcomes included assessment of the change in individual upper gastrointestinal symptoms (a total of 9 symptoms) and Quality of life [measured using the Short-Form Nepean Dyspepsia Index (SF-NDI)].

RESULTS: A total of 139 patients were recruited (Mean age=48; Male=46). Patients were randomly assigned to intervention group (n=68) or control group (Esomeprazole) (n=71). FD sub-types in both groups were similar: EPS (33.3% vs 66.7%), PDS (53.9% vs 46.1%), overlap (46.7% vs 53.3%); p=0.271. The percentage of patients achieving the primary efficacy outcome did not differ significantly between the groups (76.0% vs 78.7%, p=0.776). The improvement of individual symptoms in both groups were similar (all p>0.05). There was a significant improvement of SF-NDI after treatment in both groups [intervention group- median 30.0 (baseline) to 12.5 (week 8); control group- median 42.5 (baseline) to 12.5 (week 8); p<0.001]. However, there were no statistical significant difference in the degree of changes of SF-NDI between both groups. Analysis according to subtypes yielded similar results. There were no significant difference between groups in the number of adverse events.

CONCLUSION: Management strategies according to FD subtype or empirical PPI appears to be similarly effective and safe. Treatment with Itopride for patients with PDS or overlap syndrome is not inferior to PPI.

IMPACT OF POSITIVE GLUCOSE, LACTOSE AND FRUCTOSE HYDROGEN BREATH TESTS ON SYMPTOMS AND QUALITY OF LIFE IN IRRITABLE BOWEL SYNDROME

Qing Yuan Loo¹, Kee Huat Chuah¹, Wen Xuan Hian¹, Xin Hui Khoo¹, Yeong Yeh Lee², Sanjiv Mahadeva¹

¹Division of Gastroenterology, Department of Medicine, Faculty of Medicine, Universiti Malaya, Kuala Lumpur, Malaysia

²School of Medical Sciences, Universiti Sains Malaysia, Kubang Kerian, Kelantan, Malaysia

BACKGROUND: Small intestinal bacterial overgrowth (SIBO) has a significant negative impact on IBS patients. However, the impact of Lactose Malabsorption (LM) and Fructose Malabsorption (FM) among IBS patients is unknown.

METHODOLOGY: A prospective study of consecutive adults who had a positive hydrogen breath test (HBT) (either glucose- 75g, lactose- 25g and fructose -25g) in University Malaya Medical Centre and Hospital Universiti Sains Malaysia was conducted. A positive HBT is defined as a rise in hydrogen of ≥ 20 ppm or a rise in methane of ≥ 10 ppm from baseline. Patients who were tested negative for SIBO (negative glucose HBT) were offered to do lactose and/ or fructose HBT in order to diagnose LM or FM. Symptoms severity and health-related quality of life (HRQoL) of IBS patients with SIBO were compared with others (patients with LM +/- FM). The independent factors associated with severe IBS (i.e. IBS symptom severity score: IBS-SSS >300) were explored.

RESULTS: A total of 60 subjects were recruited (median age 51 years, female 65% and IBS-diarrhoea predominant 61%). The frequency of HBT positive were as follows: glucose 36.7%, lactose 36.7% and fructose 23.3%).

36.4% with SIBO, 9.1% with LM and 14.3% with FM had severe IBS. Severe IBS was associated with SIBO, compared with others (LM +/- FM) (36.4% vs 10.5%, $p=0.016$). The presence of SIBO was associated with poorer HRQOL (EQ-5D utility score 0.73 (0.69-0.78) vs 0.80 (0.73-0.85), $p=0.034$].

On multivariate analysis, only SIBO (OR 5.25, 95% CI 1.19 - 23.15, $p=0.028$) and depression (hospital anxiety depression scale >8) (OR 5.59, 95% CI 1.19 – 26.40, $p=0.030$) were independently associated with severe IBS.

DISCUSSION: The study on the impact of individual positive HBT (glucose, lactose and fructose) is novel. The findings of this study suggest that the screening for SIBO may be more important and should be prioritize over other HBT.

CONCLUSION: This study demonstrated that the negative impact (symptoms and HRQoL) of positive glucose HBT is significantly more than positive fructose and lactose HBT.

ENDOSCOPIC EVALUATION IN ADULTS WITH SUSPECTED GASTROINTESTINAL (GI) BLEEDING: A 9-YEAR RETROSPECTIVE, SINGLE-CENTRE REVIEW

Shahreedhan binti Shahrani¹, Sandeep Singh Gill², Ng Xin Tong², Looi Kah Hee², Nurul Safirah Binti Norhisham², Chee Sher Weyne², Khoo Xin Hui², Imran Zainal Abidin^{1,2}, Sanjiv Mahadeva^{1,2}

¹Department of Internal Medicine, Universiti Malaya Medical Centre, Kuala Lumpur, Malaysia

²Faculty of Medicine, Universiti Malaya, Kuala Lumpur, Malaysia

OBJECTIVE: Gastrointestinal bleeding (GIB) is one of the most common medical emergencies. Despite newer advances in medical therapy and intervention, it still carries a significant mortality rate.

This study aims to determine the endoscopy findings in patient who were referred for suspected GI bleeding; and to study its' possible associated risk factors.

METHODOLOGY: This was a retrospective audit in University Malaya Medical Centre (UMMC), a tertiary hospital in Kuala Lumpur, Malaysia with gastroenterology subspecialty expertise. All adult patients who were referred for suspected GI bleeding and underwent GI endoscopy (oesophagogastroduodenoscopy (OGDS) and colonoscopy) from 1st January 2013 to 31st December 2021 were included.

RESULTS: There were 5222 patients included in the study, of which they were predominantly male (55.6%), ethnic Chinese (49.1%) and had hypertension co-morbidity (59.9%). 6.5% of patients were on anticoagulants, whereas 23.2% of patients were on antiplatelets.

The most common endoscopic findings from OGDS were peptic ulcer disease (28.3%), varices (6.7%) and normal findings (45.3%). A third of patients who underwent colonoscopy had normal findings (33.7%). Presence of comorbidities such as hypertension, chronic kidney disease, ischaemic heart disease and atrial fibrillation; and antiplatelet use were found to be significant risk factors for GI bleeding ($p < 0.001$).

CONCLUSION: A large proportion of patients who were referred for suspected GI bleeding had normal endoscopy findings. Presence of co-morbidities and antiplatelet use were significant risk factors for GI bleeding.

GASTROINTESTINAL (GI) BLEEDING WITH ANTI-THROMBOTIC USE: A LARGE MALAYSIAN COHORT STUDY

Shahreedhan binti Shahrani¹, Sandeep Singh Gill², Ng Xin Tong², Looi Kah Hee², Nurul Safirah Binti Norhisham², Chee Sher Weyne², Khoo Xin Hui², Imran Zainal Abidin^{1,2}, Sanjiv Mahadeva^{1,2}

¹Department of Internal Medicine, Universiti Malaya Medical Centre, Kuala Lumpur, Malaysia

²Faculty of Medicine, Universiti Malaya, Kuala Lumpur, Malaysia

OBJECTIVE: The increasing prevalence of vascular diseases is subsequently leading to an increase of patients requiring long-term treatment with anti-thrombotics; be it antiplatelet agents or anticoagulants. There have been limited reports studying GI bleeding due to anti-thrombotic use in a diverse, large population, especially in South East Asia. This study aims to assess the relation of anti-thrombotics with GI bleeding; to describe its demographics, clinical characteristics and endoscopic outcomes.

METHODOLOGY: This study was a retrospective audit in University Malaya Medical Centre (UMMC). All patients who were referred for suspected GI bleeding and underwent GI endoscopy (oesophagogastroduodenoscopy (OGDS) and colonoscopy) from 1st January 2013 to 31st December 2021 were included. Patients were identified from manual endoscopy logbooks. Demographic and relevant information including endoscopic outcomes were charted via the hospital's electronic medical records (EMR) database, IPesakit.

RESULTS: There were 5222 patients referred for GI endoscopy due to suspected GI bleeding. Peptic ulcer was the main cause in the upper tract (28.3%) and hemorrhoids, in the lower tract (17.4%). 1548 patients (29.6%) were on anti-thrombotics; 337 patients (6.5%) were on anticoagulants and 1211 patients (23.2%) were on antiplatelets. The most common anticoagulant use that presented with GI bleeding were warfarin (33%), apixaban (28.9%) and dabigatran (18%). Antiplatelets that presented with GI bleeding were mainly aspirin (12.9%) and clopidogrel (3.8%). Use of warfarin, apixaban and rivaroxaban were significant risks for GI bleeding ($p < 0.001$). Age, presence of comorbidities such as hypertension, chronic kidney disease, ischaemic heart disease and atrial fibrillation; and aspirin use were also found to be significant risk factors for GI bleeding. ($p < 0.001$).

CONCLUSION: Significant risk factors for GI bleeding were age, comorbidities, antiplatelet use and usage of warfarin, apixaban and rivaroxaban.

MOLECULAR EPIDEMIOLOGY AND SPATIAL DISTRIBUTION OF HEPATITIS B VIRUS GENOTYPES, SUBGENOTYPES AND SEROTYPES AMONG PATIENTS FROM A MALAYSIAN TERTIARY MEDICAL CENTRE

Bello Kizito Eneve^{1,2}, Wong Mung Seong^{3,5}, Lee Yeong Yeh^{3,5}, Rafidah Hanim Shueb^{1,4,5}, Nazri Mustaffa^{3,5}

¹Department of Medical Microbiology and Parasitology, School of Medical Sciences, Universiti Sains Malaysia, Kubang Kerian, Kelantan, Malaysia

²Kogi State University (Prince Abubakar Audu University) Anyigba, Kogi State, Nigeria

³Department of Medicine, School of Medical Sciences, Universiti Sains Malaysia, Kubang Kerian, Kelantan, Malaysia

⁴Institute for Research in Molecular Medicine, Universiti Sains Malaysia, Kubang Kerian, Kelantan, Malaysia

⁵Hospital Universiti Sains Malaysia, Kubang Kerian, Kelantan, Malaysia

INTRODUCTION: It has been recognised that certain HBV genotypes, subgenotypes and serotypes are associated with more severe disease progression. At the same time, analysis of these HBV genotypes, subgenotypes and serotypes may also provide insight into population movements and origins of infection.

OBJECTIVES: To determine the distribution, and to obtain geographic insight into the spatial distribution, of HBV genotypes, subgenotypes and serotypes of patients with chronic HBV infection from the northeast state of Kelantan, Malaysia.

METHODOLOGY: Demographic information from one hundred and eighty subjects with chronic HBV infection from Hospital Universiti Sains Malaysia was obtained. HBV DNA was extracted from blood samples, amplified, and sequenced to determine HBV genotypes, subgenotypes and serotypes. The results were then mapped to epidemiologic data according to districts within the state of Kelantan.

RESULTS: There were three genotypes within the study population: Genotype B (168/180:93.3%), Genotype C (7/180:3.9%) and Genotype D (1/180:0.6%). Eight subgenotypic variants were observed in the study. Subgenotype B3 (53/168: 31.5%) was the most dominant. There were four serotypes of HBV within the study population: adr (7/180: 3.9%), ayw (13/180: 7.2%), adw (97/180: 53.9%), ayr (63/180: 35.0%). There was a significant genotypic difference according to sex and age at $P > 0.05$. Kota Bharu district had the highest distribution of HBV genotypes and subgenotypes, whilst Pasir Puteh and Machang districts had the lowest distribution of HBV genotype B.

DISCUSSION AND CONCLUSION: HBV Genotype B and C are associated with more severe disease outcomes. This study also reveals the molecular epidemiology and genomic diversity of HBV within the state of Kelantan, with a high burden of HBV genotypes in the state capital of Kota Bharu. These indicate a population movement towards the state capital, but at the same time there is a higher risk of hepatocellular carcinoma and chronic liver disease within this group.

THE LINK BETWEEN THE OPPORTUNISTIC GUT FUNGAL PATHOGENS WITH COLORECTAL ADENOCARCINOMA

Aisyah Yunus¹, Norfilza Mohd Mokhtar^{2,3}, Raja Affendi Raja Ali^{3,4}, Siti Maryam Ahmad Kendong², Hajar Fauzan Ahmad^{1,3}

¹Faculty of Industrial Sciences and Technology, Universiti Malaysia Pahang, Pahang, Malaysia

²Department of Physiology, Faculty of Medicine, Universiti Kebangsaan Malaysia, Kuala Lumpur, Malaysia

³Gut Research Group, Faculty of Medicine, Universiti Kebangsaan Malaysia, Kuala Lumpur, Malaysia

⁴School of Medical and Life Sciences, Sunway University, Selangor, Malaysia

OBJECTIVE(S): Colorectal cancer (CRC) is highly prevalent in Malaysia. Etiopathogenesis of CRC is complex involving gut mycobiome. To date, little is known about the composition and characteristics of the gut mycobiome among patients with CRC in Malaysia. We aimed to explore the presence of gut fungal pathogens in CRC patients.

METHODOLOGY: Biopsy samples were obtained from 61 individuals of 3 groups; 29 CRC (n=29), 19 polyps (pre-CRC) (n=19), and healthy controls (n=13). The gDNA was extracted for amplicon sequencing by targeting the ITS1 region and proceeded for diversities and biomarkers analyses using state-of-art bioinformatics approaches.

RESULTS: The analysis of 6,265,412 read-counts revealed 1,364 fungal ASV, with variable fungal species abundance across the groups. *Ascomycota* and *Basidiomycota* formed the highest phyla in all samples, with *Mucoromycota* (3.99%) and *Mortierellomycota* (18.76%) being significant among the control and pre-CRC groups, respectively. At the genera level, *Aspergillus* (13.63%), *Mortierella* (18.76%), and *Saitozyma* (22.83%) were abundant among the CRC, pre-CRC, and control groups, respectively. Alpha and beta-diversities analyses showed significant differences between the groups; Chao1 index (p -value = 0.004) and Bray-Curtis index (p -value = 0.05), respectively. Remarkably, machine learning analysis predicted that CRC patients were positively correlated with *Rhodotorula* and *Cutaneotrichosporon*.

DISCUSSION: Fungi are understudied but play significant roles as commensals or opportunistic pathogens that influence cancer patients' host immunity. Previous studies showed *Rhodotorula dairenensis* and *Cutaneotrichosporon curvatus* were associated with fungemia and cutaneous metastases among the CRC, respectively. Interestingly, we discovered a profusion of *Agaricomycetes* in CRC patients, which are connected to the patients' mushroom diet.

CONCLUSION(S): In Malaysia, a distinctive mycobiome profile is observed among CRC, pre-CRC, and healthy controls. Gut mycobiome signatures including *Rhodotorula dairenensis*, and *Mortierella echinula* may be involved in the CRC pathogenesis and its precursor polyp, and potentially serve as future non-invasive mycobiome markers for the detection of CRC.

CASE REPORT: METHEMOGLOBINEMIA IN PARACETAMOL OVERDOSE - A RARE OCCURENCE

Naveen R, Zalwani Zainuddin, Kuang Kiat Kiew

Gastroenterology Unit, Department of Internal Medicine, Hospital Sultanah Bahiyah, Alor Star, Kedah, Malaysia

INTRODUCTION

- Methemoglobinemia happens when the ferrous component in the haemoglobin molecule is oxidized, converting them from Fe²⁺ to Fe³⁺.
- Many conditions can lead to methemoglobinemia, among them include drugs and toxins.

CASE REPORT

- We share an interesting case of methemoglobinemia encountered in our patient with paracetamol overdose.
- Methemoglobinemia should be suspected in the event of haemolysis happening concurrently with paracetamol overdose.

CONCLUSION

- Awareness and high index of suspicion is crucial as certain cases can be life threatening.
- Though NAC (N-Acetylcysteine) is not the first line treatment, there has been numerous in vitro evidences indicating its methaemoglobin reducing capacity.
- Fortunately, in our patient, NAC treated both the PCM overdose and reduced the methaemoglobin.

CD20-NEGATIVE DIFFUSE LARGE B-CELL LYMPHOMA OF THE COLON: EXPOSING THE GREAT MIMICKER WITH IHC

Subita Sugantal¹, James Emmanuel¹, Lily Wong Lee Lee², Raman Muthukaruppan¹

¹Gastroenterology Unit, Department of Medicine, Queen Elizabeth Hospital, Kota Kinabalu, Sabah, Malaysia

²Hematology Unit, Department of Medicine, Queen Elizabeth Hospital, Kota Kinabalu, Sabah, Malaysia

INTRODUCTION: Diffuse Large B-Cell Lymphoma (DLBCL) is the most common subtype of non-Hodgkin's lymphoma (NHL) and it accounts for 30-40% of cases.¹ CD20-negative diffuse large B-cell lymphoma (DLBCL) are NHL subtypes that confer a poorer prognosis due to its atypical morphology, predilection for extranodal involvement, aggressive clinical course and resistance to chemotherapy.^{2,3} In addition, it poses a diagnostic challenge due to its rarity and highly variable clinical presentation. We report a case of primary CD20-negative DLBCL of the colon which responded to the standard CHOP (cyclophosphamide, doxorubicin, vincristine and prednisolone) based chemotherapy.

CASE REPORT: Our patient is a 45 year old gentleman with underlying Chronic Hepatitis B who presented with history of left hypochondrium pain for the past 1 year. There was associated weight loss of 10kg during that period with intermittent fever. On clinical assessment blood pressure was 106/68 mmhg and a pulse of 70/minute. Temperature was 38°C. Clinical examination was unremarkable. Blood parameters were notable for deranged Full blood count with white cell count of $24 \times 10^3/u/L$; hemoglobin 11 g/dl, platelet $175 \times 10^3/uL$ and an elevated C reactive protein of 214mg/L. Apart for hypoalbuminemia, his renal profile and liver function tests were unremarkable. Other work-up which included autoimmune profile, tumor markers, viral screening and tuberculosis workup were negative.

An ultrasound imaging of the abdomen revealed an ill defined splenic collection. He was commenced on a course of antibiotics for a total of 2 weeks in view of a presumptive diagnosis of splenic abscess. However a reassessment ultrasound abdomen did not reveal radiological improvement. Additional evaluation with CT imaging demonstrated intra-abdominal lymphadenopathy with focal circumferential thickening of the descending colon resulting in luminal narrowing (**Figure 1a and Figure 1b**). There was a heterogenous hyperdensity at the splenic hilum measuring 4x8x5cm in keeping with a necrotic node.

We proceeded with a colonoscopy that revealed circumferential segmental colitis at the descending colon in keeping with TB colitis. (**Figure 2a**). Narrow-band Imaging (NBI) assisted characterization of the lesion (**Figure 2b**) did not demonstrate malignant feature.

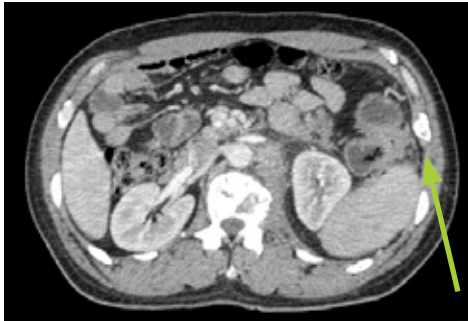

Figure 1a: Circumferential thickening of the descending colon resulting in luminal narrowing

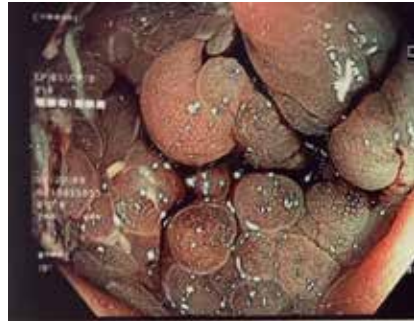

Figure 2b: Characterization with NBI did not demonstrate malignant features

The histopathological examination (HPE) of the descending colon which displayed atypical lymphoid cells was non-diagnostic. In view of a high index of suspicion of TB, a repeat colonoscopy and biopsy of the lesion was performed which revealed malignant lymphoid cells with immunoblastic appearance. An initial negative result for CD20 and CD3 markers as well as CD30 positivity had resulted in a preliminary misdiagnosis of ALK negative Anaplastic Large Cell Lymphoma. Further immunohistochemistry evaluation which revealed reactivity to primitive B-cell line markers ; CD79a and PAX5 with high ki67 proliferative index (>90%) (**Figure 3a and Figure 3b**) resulted in a revision of the diagnosis to CD20-negative Diffuse Large B-Cell Lymphoma of the colon.

He was subsequently referred to the hematology unit and was commenced on 1 cycle of Bendamustine due to its better tolerability profile followed by 5 cycles of CHOP chemotherapy (cyclophosphamide ,doxorubicin, vincristine and prednisolone). During clinic follow up patient had notable clinical improvement. Repeat CT imaging after completion of chemotherapy showed good treatment response evidenced by marked reduction of proximal descending colon thickening and regression in the size of the splenic node. (**Figure 4a and Figure 4b**) Reassessment colonoscopy showed endoscopic resolution of the previously seen area of segmental colitis with the presence of pseudopolyps.

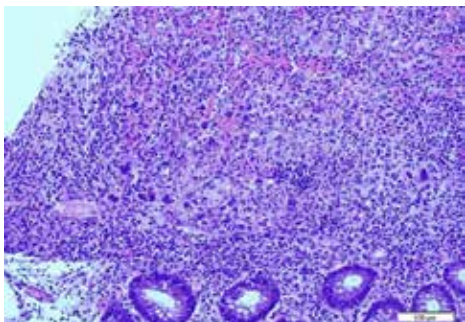


Figure 3a

- Individually dispersed malignant lymphoid cells with immunoblastic appearance within the lamina propria

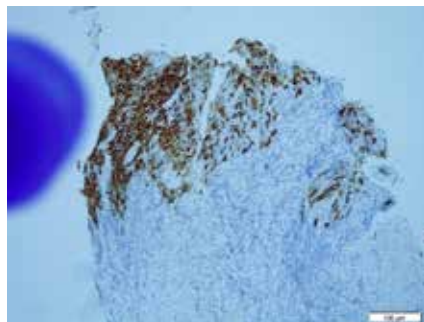


Figure 3b

- Malignant lymphoid cells exhibit the following immunoprofile: positive for leucocyte common antigen (LCA), CD79a, CD30 and paired box containing (PAX5) (strong nuclear expression) with high ki67 proliferative index (>90%)
- **Consistent with CD20-negative DIFFUSE LARGE B-CELL LYMPHOMA**

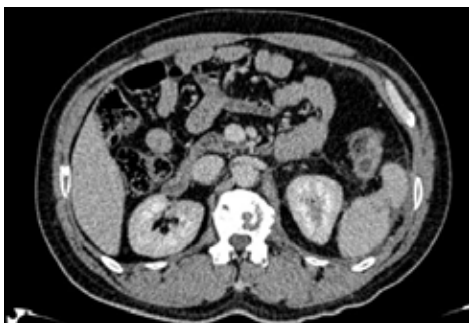
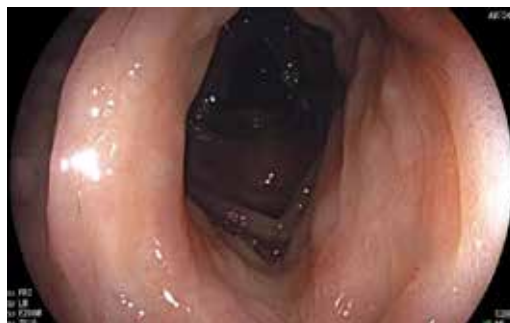
Figure 4a

Near complete resolution of the proximal descending colon thickening



Post chemotherapy reassessment colonoscopy revealed resolution

DISCUSSION: CD20-negative diffuse large B-cell lymphoma (DLBCL) are a rare group of lymphoproliferative disorders with a pronounced proclivity for extranodal involvement.²

The lack of an overarching histological classification, for DLBCL variants that do not express CD20, as illustrated in our case render these entities unclassifiable. Current recognised variants of CD20-negative DLBCL are *plasmablastic lymphoma*, primary effusion lymphomas, Anaplastic lymphoma kinase positive large B-cell lymphoma, and human immunodeficiency-virus associated plasmablastic lymphoma.⁴

In East Malaysia, a legitimate concern, owing to a disproportionately high prevalence is the diagnosis of intra-abdominal tuberculosis.⁵ The absence of malignant features on NBI (Narrow-band Imaging) during the index colonoscopy and the features on CT imaging had raised suspicion of TB. Nevertheless, the immunostaining which was positive for LCA markers confirmed that the cells were of lymphoid lineage. A preliminary misdiagnosis of ALK negative Anaplastic Large Cell Lymphoma did occur in our case owing to the initial negative result for CD20 and CD3 markers as well as CD30 positivity. However immunoreactivity to CD79a and PAX5 had assisted in elucidating the diagnosis. This highlights the importance of having an *extensive repertoire* of antibody panel in diagnostic immunohistochemistry.

In our patient the chemotherapy regime was initiated with Bendamustine followed by 5 cycles of CHOP. The patient's initial clinical presentation warranted the use of Bendamustine due to its better safety profile. He responded radiologically and endoscopically following treatment with the conventional CHOP based chemotherapy.

It is worth noting that in the event of a relapse in our patient, a targeted agent towards CD30, such as Brentuximab would be a prudent choice given the immunohistochemical expression of *the aforementioned antibody*.

CONCLUSION: To the best of our knowledge, this is the first reported case of a CD20-negative extranodal lymphoma involving the colon. Our patient had a favourable response to the CHOP based chemotherapy evidenced by radiological and endoscopic resolution of the disease.

AN UNUSUAL COMPLICATION OF METAL STENTING IN A LIVER TRANSPLANT RECIPIENT WITH ANASTOMOTIC STRICTURE: A CASE REPORT

C F Liew, James Emmanuel, R Puthashanan, Raman Muthukaruppan Chettiar

Queen Elizabeth Hospital, Kota Kinabalu, Sabah, Malaysia

INTRODUCTION: Biliary anastomotic stricture is a rare complication of liver transplant which can be treated with metal stenting. Stent migration has been reported in up to 6%-8% of patients. In majority of these patients, antegrade migration of the stent is inconsequential. However in rare occasions, the stent may get embedded in the duodenum leading to obstructive complications.

Case presentation: 64 year-old gentleman underwent liver transplant in 2016 following an acute liver failure secondary to Hepatitis B. He developed jaundice 3 months post surgery which was attributed to biliary anastomotic stricture. Percutaneous transhepatic biliary drainage followed by antegrade metal stenting was performed. In 2022, he was diagnosed with post liver transplant Budd-Chiari syndrome which necessitated an IVC venoplasty. CT imaging post venoplasty demonstrated a thickened pylorus. Oesophagogastroduodenoscopy (OGDS) revealed extensive phytobezoars in the stomach and pylorus was obstructed by the migrated stent. Coca-Cola was used to dissolve the phytobezoar. Repeated OGDS revealed lesser amount of phytobezoars in the stomach. Pyloric intubation was then successful using an ultraslim gastroscope. The first attempt of stent retrieval with rat tooth forceps was unsuccessful as there was resistance encountered on traction. Endoscopically the stent was seen to be embedded in the duodenal wall. Visualisation of the stent under fluoroscopy was unsuccessful likely due to the disintegration of the stent. Therefore a tandem was inserted into the proximal portion of the stent and contrast instillation was used to delineate the extent of the stent. The distal tip of the stent was located at D2. A rat tooth forceps was used to grasp the proximal flange of the stent, and with gentle manipulation, successfully removed under fluoroscopy and endoscopic visualization.

Discussion: Complications of stent migration include GI obstruction and intestinal perforation. Endoscopic retrieval of the stent in our case was technically challenging as it was partially embedded and due to the presence of phytobezoars.

PIECEMEAL COLD SNARE EMR TO A LARGE NON-GRANULAR LATERALLY SPREADING DUODENAL TUMOUR

Keng Hoong Chiam, Shih Mun Yong

Pantai Hospital, Penang, Malaysia

INTRODUCTION: Sporadic duodenal adenomas are mostly found incidentally during upper gastrointestinal endoscopy. The distribution of small bowel adenomas is predominantly at the ampulla and non-ampullary regions. Some adenomas may lead to occult bleeding and, rarely, luminal obstruction. Duodenal adenomas found at the major papilla may potentially occlude the common duct, resulting in various complications.

CASE DESCRIPTION: This is a 57-year-old gentleman who came in for an endoscopy for uninvestigated dyspepsia. Index endoscopy demonstrated multiple non-granular duodenal lateral spreading tumour (LST) at the second part of duodenum, with the most extensive lesion being 55-60 millimetres (mm), located in the D2/D3 junction. The biopsy demonstrated tubular adenoma low grade dysplasia with a foci high grade dysplasia. Lesions were removed on a separate occasion utilising the piecemeal cold snare endoscopic mucosal resection (EMR) technique.

LEARNING POINTS: Endoscopic resection in the duodenum is challenging due to its anatomical nature : Narrowed lumen, thinned wall, high density of complex blood vessel network and high concentration of digestive secretion such as pancreatic enzymes and bile that will precipitate bleeding.

Recent studies have shown that cold snare has lower morbidity than hot snare technique in treating SNADETs, with a lower rate of delayed bleeding and perforation, thus mitigating the need for defect closure.

To date, the only study on long term follow-up reported a low incidence of recurrence, and there was no association between recurrences with the type of resection technique.

LIVER INJURY IN PREGNANT PATIENTS WITH POSITIVE COVID-19: ITS CLINICAL FEATURES AND OUTCOMES

Y P Tan, Joyce Yap, Adawiyah, Mathurubini Nair, Daleen Leong, Ezma, K K Sia

Gastroenterology unit Medical department, Ampang Hospital, Selangor, Malaysia

COVID-19 stricken pregnant lady are susceptible to infection especially lung infection making them higher risk of ICU admission. We conducted a retrospective review of covid positive pregnant lady admitted to Hospital Ampang from 1 January 2021 till 31 December 2022. COVID 19 associated acute liver injury was defined as either alanine aminotransferase (ALT) >40U/L, aspartate aminotransferase (AST) >40U/L or total bilirubin (TBIL) >17.1 μ mol/L. We graded the inflammatory markers to correlate with severity of COVID 19, as per calculation from the full blood count at admission, CRP and neutrophil-lymphocyte ratio. We have analysed 81 subjects with laboratory proven COVID 19 and liver injury. In our cohort, 35.8% had category 5, 22.2% category 4 followed by 25.9% category 3, 13.6% category 2 and 2.5% category 1. Median period of amenorrhea was 32 weeks of third trimester, the earliest date was 6 weeks and highest POA was 39 weeks. There were 2 deaths (2.5%) in our cohort whom was COVID category 3 and 5 respectively, rest of 79 patients (97.5%) recovered uneventfully. The mean NLR and ALC were 5.14 and 1.7 respectively. Out of all subjects, 58% recovered without complications though 16 % suffered from moderate to severe organising pneumonia; 12.3% had bacteremia; 6.2% down with hospital acquired pneumonia and 4.9 % had pulmonary embolism. It is reported also myocardial infarction and pneumothorax occurred in 1.2% respectively. The severity of disease corresponding to the NLR of more than 3.75. The mean ALT level was 112unit/L with standard deviation of 27. The mean CRP was 32.97. In our study, the hepatocellular pattern acute liver injury in pregnant lady was common but majority recovered. NLR and AST correlated indirectly with poor outcome. Careful monitoring of transaminitis and intensive care is needed on its worsening.

UTILITY OF COLONOSCOPY IN DIAGNOSING ACUTE GASTROINTESTINAL GRAFT VERSUS HOST DISEASE

Y P Tan¹, T G Wong²

¹Gastroenterology & Hepatology Unit, Ampang Hospital, Selangor, Malaysia

²Haematology Department, Ampang Hospital, Selangor, Malaysia

INTRODUCTION: Acute graft versus host disease is the major complication of post allogenic hemopoietic stem cell transplantation. Recognition of aGVHD is crucial in reducing mortality and morbidity. The endoscopic biopsies provide important means to diagnose gut GVHD. We focus on getting clinical significance in endoscopic diagnosis from colonoscopy findings and biopsy results.

METHODOLOGY: We followed up 8 patients post allogenic stem cell transplantation between 24 weeks to 100 days after allo-SCT. All of them experience watery diarrhea with frequency of more than 6 times and abdominal pain. We analyzed all segmental biopsies (prophylactic platelet transfusion if level less than $50 \times 10^3/\mu\text{L}$) and all 8 patients were diagnosed with colorectal GVHD by the histologic evaluation.

RESULTS: The endoscopic features range from hyperemia, irregular shallow ulcers, to epitheliolysis. All the biopsy results correspond to typical histological features of GVHD with Lerner grade I to IV. Among 8 patients who underwent colonoscopy 3 showed hyperemic patches, 3 irregular shallow ulcers and 2 circumferential extensive ulcerations. Their age ranged from 23 to 51 years old with 4 post haploidentical allo-SCT (haplo-SCT), 3 Allogenic hematopoietic stem cell transplantation and 1 reduced intensity conditioning transplantation (allo-RIC). All received conditioning and aGVHD prophylaxis. 3 out of 8 had concomitant CMV disease. Only 1 patient demonstrated skin involvement, 1 the hepatic involvement and 1 both the hepatic and skin involvement. Whilst 4 patients had colorectal GVHD without skin and hepatic involvement.

DISCUSSION/CONCLUSION: Colonoscopy is invaluable in getting GVHD diagnosis and ruling out CMV, TB as well as infective colitis.

INNOVATION IN PATIENT-CENTRIC INFLAMMATORY BOWEL DISEASE (IBD) CARE IN MALAYSIA: EARLY EXPERIENCE ANALYSIS OF THE IBD PAL MOBILE APP FOR REMOTE DISEASE MONITORING

Choong Yeong Sooi¹, Ida Normiha Hilmi², Khairul Najmi Muhammad Nawawi³, Sherene Swee Yin Lim⁵, Ruben Skantha¹, Rasnaizam Rasdi¹, Azlida Che' Aun¹, Xin Hui Khoo², Lorainne Angal², Mei Hui Wee⁴, Alex Hwong Ruey Leow⁴

¹Department of Gastroenterology, Hospital Tengku Ampuan Afzan, Kuantan, Pahang, Malaysia

²Division of Gastroenterology and Hepatology, Department of Medicine, Faculty of Medicine, Universiti Malaya, Kuala Lumpur, Malaysia

³Gastroenterology Unit, Department of Medicine, Faculty of Medicine Universiti Kebangsaan Malaysia, Kuala Lumpur, Malaysia

⁴Pantai Hospital Kuala Lumpur, Kuala Lumpur, Malaysia

⁵Medical Affairs, Ferring Malaysia, Selangor, Malaysia

BACKGROUND: Telehealth has been shown to improve on patient engagement and revolutionized on healthcare delivery.

OBJECTIVE: The aim of this retrospective analysis was to assess the real-world usage and patient-reported outcomes (PRO) from the first Malaysian IBD mobile monitoring tool, MyIBD Pal application.

METHODS: This was a multicenter, observational study examining the early experience of integrating the IBD app in routine care. Patients were asked to assess their usage experience by using visual analogue scales (VAS).

RESULTS: Eighteen patients enrolled and activated the IBD app between 22/7/2022 to 3/4/2023 were included in this pilot analysis. The median age was 27 (range 16-66) years. There was no significant correlation between the age and frequency of use of symptoms diary based on SCCAI score ($r_s = 0.19439$, $p = 0.43956$). In the PRO analysis (total entries = 362), mild-moderate CD patients were significantly more likely to report having moderate-severe episodes compared to CD patients in remission (chi-square, $P < 0.0001$). There was no significant association between baseline UC severity, and the frequency of reported moderate-severe episodes among UC patients ($P = 0.1351$). 77.8% utilized the clinic appointment scheduler, while the scheduled medications feature was activated in 72.7% of the subjects. 83.3% rated the app as easy to use, with a mean VAS score of 4.1 (SD 0.64). However, the lowest rating was on the difficulty of remembering to use the app (mean VAS score 3.0, SD 1.0), while the highest rating was on feeling in better control of their health condition (mean VAS score 4.3, SD 0.5).

CONCLUSION: These findings support the feasibility of using the IBD Pal app to supplement standard of care among patients with IBD, enabling real-time notifications of PRO for early intervention in a real-world setting. We await more data to confirm our initial observation reported here.

Keywords: Mobile apps, Patient-Reported Outcomes; Telemedicine; Inflammatory Bowel Disease

HEPATIC HYDROTHORAX: SINGLE CENTRE'S EXPERIENCE IN MALAYSIA ON THE UTILITY OF OCTREOTIDE - A CASE SERIES

C Vikneshwaran Chandra Kumar, Ruben Skantha, Shahreedhan Shahrani, Nik Arsyad Nik Muhammad Affendi, Thevaraajan Jayaraman, Kee Huat Chuah, Stanley Khoo, Ruveena Bhavani Rajaram, Sanjiv Mahadeva

Gastroenterology and Hepatology Unit, Department of Medicine, Universiti Malaya Medical Centre, Kuala Lumpur, Malaysia

INTRODUCTION: Hepatic hydrothorax (HH) leads to significant morbidity and short-term mortality. Till date, transjugular intrahepatic portosystemic shunt (TIPS) and liver transplantation (LT) are the only definitive treatment for HH.

OBJECTIVE: To determine the efficacy of octreotide infusion for management of HH.

METHODOLOGY: Single-center retrospective case-series of decompensated liver cirrhosis patients with hepatic hydrothorax between March 2018 and March 2020. Apart from standard medical therapy, patients were subjected to pleural drainage and intravenous octreotide infusion over seven days (25mcg/hour day one, 50mcg/hour day two, 100 mcg/hour days three to seven). Resolution of HH was confirmed with repeat chest X-ray.

RESULTS: Median age of patients in this case series was 69 years old [interquartile range (IQR) 62-74]; three males and five females. The median Child-Pugh Score was 8 (IQR 7-10) and model for end-stage liver disease (MELD-Na) score was 19 (IQR 14-22). All patients had concurrent ascites requiring peritoneal drainage. Seven had significant right-sided pleural effusion, whereas one had left-sided pleural effusion. Portal-vein thrombosis present in one patient and two had hepatocellular carcinoma. Four patients achieved clinical resolution of HH with octreotide at the end of treatment, and at one-, three-, six- and twelve-months post-treatment. Chemical pleurodesis done for one patient and another required repeat infusion of octreotide within one month with subsequent clinical resolution of HH. The remaining four patients did not achieve clinical remission; two patients required repeated thoracentesis during follow-ups, one patient had indwelling pleural catheter placement, and another transferred out to another hepatology center.

CONCLUSION: Octreotide infusion in tandem with pleural drainage resulted in clinical resolution of HH in 50% of our patients and may be an alternative treatment for selected patients with HH when both TIPS and LT are non-viable.

G-POEM FOR REFRACTORY GASTROPARESIS: CASE SERIES

Chong Chearn Lee¹, Shiaw-Hooi Ho², Sanjiv Mahadeva²

¹Gastroenterology and Hepatology Unit, Department of Medicine, Hospital Canselor Tuanku Muhriz, Kuala Lumpur, Malaysia

²Gastroenterology and Hepatology Unit, Department of Medicine, Universiti Malaya Medical Centre, Kuala Lumpur, Malaysia

INTRODUCTION: Gastroparesis is a common gastrointestinal disorder with high prevalence globally and high disease burden. In the majority of case studies, diabetes and idiopathic constitute the commonest cause of gastroparesis. Gastrointestinal symptoms including nausea, vomiting and postprandial fullness as part of Gastroparesis Cardinal Symptom Index can be an objective tool for assessment of severity of gastroparesis. Gastroparesis is characterised by non-obstructive delayed gastric emptying which can be evaluated by scintigraphy and stable isotope breath test.

CASE SUMMARIES / RESULTS: Presented here are two interesting cases who underwent G-POEM for refractory gastroparesis.

Case 1 is a 64-year-old man with type 1 achalasia with refractory gastroparesis who underwent sequential POEM and G-POEM with improvement of clinical symptoms at 3 months.

Case 2 is an obese 39-year-old man with refractory gastroparesis secondary to uncontrolled type 2 diabetes mellitus who underwent G-POEM with improvement of clinical symptoms with normal gastric emptying at two years followup.

DISCUSSION: Management of gastroparesis includes dietary and lifestyle modification, pharmacological agents including prokinetics and antiemetics, botulinum toxin injection, or nutrition related therapeutic interventions such as nasoduodenal tube, percutaneous gastroduodenostomy or jejunostomy.

Gastric per oral endoscopic pyloromyotomy (G-POEM) is a promising treatment for refractory gastroparesis.

CONCLUSION: G-POEM is a safe procedure for refractory gastroparesis with significant short-term and mid-term improvement in overall symptoms. Further studies are required to identify candidates with best G-POEM treatment outcome.

Keywords: Gastroparesis, G-poem

LONG TERM EFFICACY AND PERSISTENCE OF BIOLOGICS THERAPY IN CROHN DISEASE IN MULTIRACIAL ASIAN COUNTRY: A REAL WORLD EXPERIENCE

Nik Arsyad bin Nik Muhamad Affendi^{1,2}, Xin Hui Khoo¹, Alex Hwong-Ruey Leow^{1,3}, Ida Normiha Hilmi¹

¹Division of Gastroenterology and Hepatology, Department of Medicine, Faculty of Medicine, Universiti Malaya, Kuala Lumpur, Malaysia

²Division of Gastroenterology and Hepatology, Department of Medicine, Faculty of Medicine, International Islamic University Malaysia, Kuala Lumpur, Malaysia

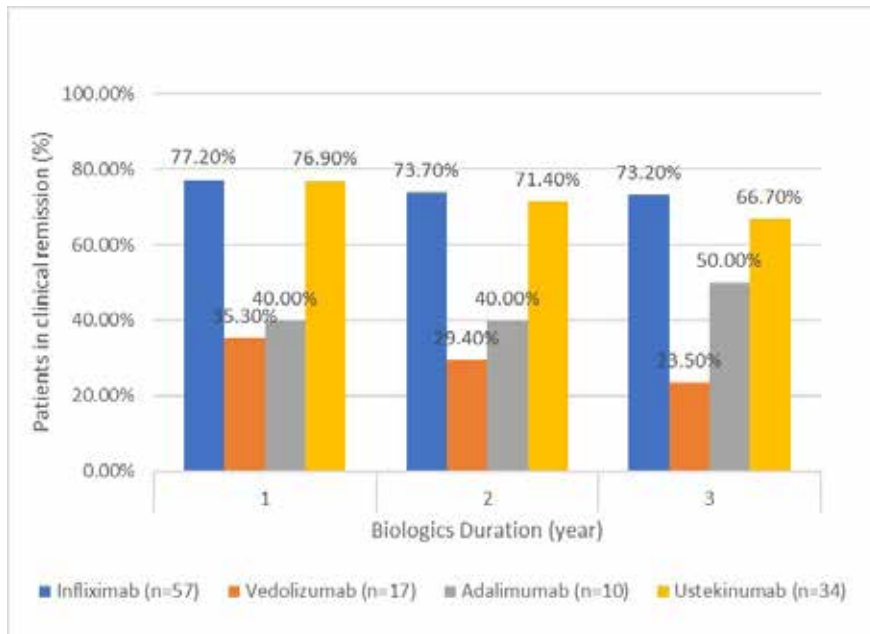
³Pantai Hospital Kuala Lumpur, Kuala Lumpur, Malaysia

INTRODUCTION: Biologic therapy is an effective treatment in moderate-to-severe Crohn disease (CD), however there is a lack of head-to-head randomised control trials to compare efficacy between available biologic therapy. We sought to determine efficacy and persistence of the currently available therapy in biologic naïve CD patients in our centre.

METHODOLOGY: A retrospective, single-centre study was conducted where we recruited all biologic naïve CD patients who were started on biologics therapy. Demographic and baseline clinical characteristic data was collected. Clinical remission and persistence up to 3 years after starting treatment were analysed.

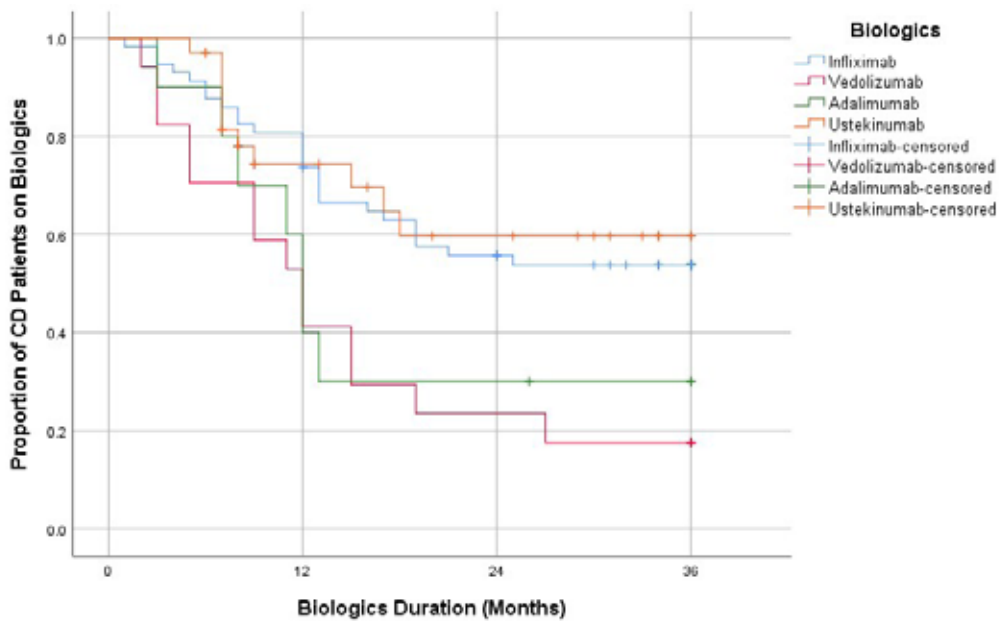
RESULT: A total of 118 patients were recruited into this study. Mean age was 30.6 ± 10.9 year old. 61% (n=72) were male and 39% (n=46) were female. Ethnicity, Indian 44.9% (n=53), Chinese 34.7% (n=41) and Malay 19.5% (n=23). Mean disease duration was 7.57 ± 5.1 years. Location of disease was as follows; 34.7% (n=41) ileal, 28.8% (n=34) colon, 32.2% (n=38) ileocolon and 4.2% (n=5) isolated upper GI. Majority had non-penetrating non-stricturing disease 70.3% (n=83) followed by 17.8% (n=21) stricturing disease and 11.9% (n=14) penetrating disease. 27.1% (n=32) had perianal disease. The median duration of biologic therapy was 26.5 ± 26.8 months. Clinical remission and persistence of biologic therapy are shown in figures 1 and 2 below.

CONCLUSION: In this study, infliximab and ustekinumab group have significantly higher efficacy and persistence as compared to adalimumab and vedolizumab although this data has to be interpreted with caution due to the unequal number of patients in each group and retrospective nature of study. A large prospective trial is required.



*Chi-square test, X2 showed significance difference between patients in remission and not in remission (1 year, $p=0.002$; 2 year, $p=0.003$, 3 year, $p=0.002$)

Figure 1: Percentage of patients in clinical remission with biologics treatment



Log rank test, $p=0.006$

Persistence rate of biologic treatment at 1,2,3 years of follow up in Crohns disease patients.

Biologics	1 Year	2 Year	3 Year
Infliximab	73.7%	55.7%	53.8%
Vedolizumab	41.2%	23.5%	17.6%
Adalimumab	40%	30%	30%
Ustekinumab	74.3%	59.7%	59.7%

Figure 2: Persistence of biologics

G-POEM FOR REFRACTORY GASTROPARESIS: CASE SERIES OF TREATMENT OUTCOME

Chong Chearn Lee^{1,2}, Shiaw-Hooi Ho², Sanjiv Mahadeva²

¹Gastroenterology and Hepatology Unit, Department of Medicine, Hospital Canselor Tuanku Muhriz, Kuala Lumpur, Malaysia

²Gastroenterology and Hepatology Unit, Department of Medicine, Universiti Malaya Medical Centre, Kuala Lumpur, Malaysia

INTRODUCTION: Gastroparesis is a common gastrointestinal disorder with high prevalence globally and high disease burden. In the majority of case studies, diabetic and idiopathic causes constitute the commonest cause of gastroparesis. Gastroparesis is characterised by non-obstructive delayed gastric emptying which can be evaluated by scintigraphy and stable isotope breath test. Gastric peroral endoscopic myotomy (G-POEM) was introduced in 2013 by Khashab et al as a novel endoscopic treatment for gastroparesis.

CASE SUMMARIES / RESULTS: Presented here are two interesting cases who underwent G-POEM for refractory gastroparesis.

Case 1 is a 64-year-old man with type 1 achalasia with refractory idiopathic gastroparesis who underwent sequential POEM and G-POEM with improvement of clinical symptoms at 3 months.

Case 2 is 39-year-old man with refractory gastroparesis secondary to uncontrolled type 2 diabetes mellitus who underwent G-POEM which resulted in tremendous symptoms resolution. However, he developed symptom recurrence at one-and-a-half-year after the G-POEM which necessitate symptom control with further prokinetic medications.

Discussion & Conclusion: G-POEM is a promising new treatment for refractory gastroparesis with good short and long-term efficacy especially for secondary and idiopathic gastroparesis. However, its long-term efficacy for diabetic gastroparesis remains a challenge. Studies revealed that most diabetic gastroparesis experienced symptom recurrence after a mean duration of 1 year after the procedure. Case 2 is a typical example of such cases which require multi-modality approaches after the G-POEM. Motility issues affecting the stomach in a diabetic gastroparesis tend to be more severe than other causes of gastroparesis. On top of poor pyloric relaxation, diabetic gastroparesis also experience poor fundal tone, antro-pyloric propulsion and duodenal motility.

Keywords: Gastroparesis, G-poem

LYMPHOEPITHELIAL SQUAMOUS CELL CARCINOMA OF THE OESOPHAGUS: A CASE REPORT

Marco Luciano Medina^{1,2}, **Man Kein Seong**³, **Ho Shiaw Hooi**²

¹University of the East Ramon Magsaysay Memorial Medical Center, Quezon City, Philippines

²Department of Medicine, Faculty of Medicine, Universiti Malaya, Kuala Lumpur, Malaysia

³Department of Pathology, Faculty of Medicine, Universiti Malaya, Kuala Lumpur, Malaysia

Lymphoepithelial carcinoma (LEC) is a rare histologic subtype of squamous cell carcinoma that commonly affects the nasopharynx, salivary glands, larynx and oral cavity but not in the gastrointestinal tract. It is morphologically similar to non-keratinizing nasopharyngeal carcinoma.

Herein, we report a case of LEC arising from the cervical oesophagus in a 42-year-old, Chinese female, presenting as chronic cough. Her initial investigations revealed a moderate-size squamous cell cancerous lesion in the proximal oesophagus which involved the muscularis propria layer but without regional or distant metastasis (pT2N0M0). She was offered oesophagectomy from this initial consultation which she declined.

She came to our institution for second opinion consultation. A repeat oesophagogastroduodenoscopy (OGDS) done here showed a large 2-3 cm Lugol's unstained lesion at the anterior aspect of the cervical oesophagus at the level of 18 to 21cm from incisor. Interestingly, it did not show the typical intrapapillary capillary loop (IPCL) features of squamous cell carcinoma on Narrow band imaging (NBI) examination. Radial EUS showed a 12.5 x 4.4 mm hypoechoic lesion arising from the second layer i.e. muscularis mucosa instead of the initial fourth layer i.e. muscularis propria. Diagnostic Endoscopic submucosal dissection (ESD) was performed without complication and en-bloc resection achieved. Final histopathologic examination revealed lymphoepithelial poorly differentiated squamous cell carcinoma. However, the ESD was deemed to be non-curative as the deep margin was involved despite clear lateral margin. She underwent and completed chemoradiation therapy thereafter. Follow-up OGDS & PET CT after 7 months revealed no tumor recurrence or metastasis.

The LEC of the oesophagus is extremely rare. This case report highlights the utility of ESD as a feasible alternative therapy for patient with T1b squamous cell cancer of the oesophagus who are unwilling to undergo invasive surgery.

FACTORS ASSOCIATE WITH HIGH ADENOMA DETECTION RATE: A TERTIARY CENTRE EXPERIENCE

Mohd Badrul Hisyam bin Hashim¹, Nik Arsyad bin Nik Muhamad Affendi^{1,2}, Ho Shiaw Hooi¹

¹Division of Gastroenterology and Hepatology, Department of Medicine, Faculty of Medicine, Universiti Malaya, Kuala Lumpur, Malaysia

²Division of Gastroenterology and Hepatology, Department of Medicine, Faculty of Medicine, International Islamic University Malaysia, Kuala Lumpur, Malaysia

INTRODUCTION: Colorectal cancer (CRC) is the leading cancer among men and the second leading cancer among women in Malaysia. Colonoscopy is a gold standard modality for screening of CRC because it allows complete examination of the colon for the detection of cancerous and pre-cancerous lesions. Adenoma detection rate (ADR) is considered as one of the key indicators of high-quality colonoscopy. We sought to determine ADR in our centre and factors that associate with high ADR.

METHODOLOGY: This was a retrospective analysis of consecutive colonoscopy performed in our centre over 1-year duration from January 2019 to December 2019. Overall, 1,761 adult patients aged 18-years-old and above who underwent colonoscopy for symptomatic examination, screening and surveillance were included. The data was collected from the endoscopy registry in Electronic Medical Record system. Baseline characteristic of the study population, ADR and endoscopist data were collected and analysed. All the data were compiled and analysed using SPSS 26.

RESULT: Baseline characteristic of study population is as shown in table 1. A total of 51 endoscopists performed 1,761 colonoscopy procedures during the study period (for indications as stated above). The overall ADR was 26.9%, 30.3% in men and 23.5% in women. Factors contributing to statistically higher adenoma detection were successful caecal intubation and procedure performed by the gastroenterology team. However positive FOBT and good quality of bowel preparation did not show statistical difference in terms of adenoma detection rate (table 2).

CONCLUSION: Overall ADR in our centre was comparable to the international recommended benchmark. Discrepancy shown in the adenoma detection rate between gastroenterology team and non-gastroenterology team mainly highlight different in training experience and approach of doing endoscopy. Combine endoscopy training involving both gastroenterology and surgeon maybe require to overcome this gap.

Table 1: Baseline characteristic

Characteristic	Total population (n=1,761)
Age (years)	Mean 62.24 +/- (SD 14.5)
Age above 50	1,464 (83.1%)
Age below 50	297 (16.9%)
Gender, n (%)	
Male	883 (50.1%)
Female	878 (49.9%)
Ethnicity, n (%)	
Chinese	991 (56.3%)
Malay	433 (24.6%)
Indian	280 (15.9%)
Others	57 (3.2%)
Subspecialty (Endoscopists) (n=51)	
Gastroenterology, n (%)	14 (27.5%)
Non – Gastroenterology, n (%)	37 (72.5%)
Subspecialty (cases), n (%)	
Gastroenterology	890 (50.5%)
Non – Gastroenterology	871 (49.5%)
Experience level (cases), n (%)	
Non-consultant	1,556 (88.4%)
Consultant	205 (11.6%)
Indication, n (%)	
Symptomatic	901 (51.2%)
Screening	681 (38.7%)
Surveillance	179 (10.2%)
FOBT (n= 317)	
Positive, n (%)	151 (47.6%)
Negative, n (%)	166 (52.4%)

Table 2: Factors associate with adenoma detection

Factors	Adenoma detection		P-value
	Yes	No	
Ceacal intubation (n=1192) No ceacal intubation (n=288)	361 (30.3 %) 37 (12.8%)	831 (69.7%) 251 (87.2%)	<0.001
Gastroenterologist (n=704) Non gastroenterologist (n=776)	236 (33.5%) 162 (20.9%)	468 (66.5%) 614 (79.1%)	<0.001
Adequate bowel preparation (n=1201) Inadequate bowel preparation (n=279)	320 (26.6%) 78 (28.0%)	881 (73.4%) 201 (72.0%)	0.654
Positive FOBT (n=134) Negative FOBT (n=148)	58 (43.3%) 49 (33.1%)	76 (56.7%) 99 (66.9%)	0.086

EFFICACY AND SAFETY OF DIRECT ACTING ANTIVIRAL THERAPY IN PATIENTS WITH CHRONIC HEPATITIS C VIRUS INFECTION: A SINGLE-CENTER EXPERIENCE

Lu Chee Men, James Emmanuel, R Puthashanan, Raman Muthukaruppan Chettiar
Queen Elizabeth Hospital, Kota Kinabalu, Sabah, Malaysia

BACKGROUND: It is estimated 58 million people have been infected with chronic hepatitis C globally, with about 1.5 million new infections occurring per year. In 2016, WHO proposed target to eliminating hepatitis C as a public health threat by 2030, targeting an 80% reduction in new chronic infections and a 65% reduction in mortality from 2015 levels. In line with this, Malaysia has introduced a DAA-based regimen consisting of Sofosbuvir and Daclatasvir to be used as the standard hepatitis C treatment in public hospitals since 2018. Here, we evaluate the efficacy and safety of DAAs for the treatment of chronic hepatitis C virus infection in Queen Elizabeth Hospital, Sabah.

METHOD: All HCV-infected adult patients who received DAA from 2018-2021 were included in this retrospective analysis.

RESULTS: A total of 185 patients were included. 140 were non-cirrhotic and 45 had liver cirrhosis. All patients were treatment naive. 180/185 (97.29%) patients achieved SVR12 with Sofosbuvir/Daclatasvir base regime, 136/140 (97.14%) in the non-cirrhotic group and 44/45 (97.77%) in the cirrhotic group respectively. There were 3/185 (1.62%) cases that failed to achieve SVR12 with the Sofosbuvir/Daclatasvir base regime. All 3 patients were genotype 3, of which 2/3 (66.67%) of the patients were non-cirrhotic and the other had compensated cirrhosis. All 3 were retreated with Sofosbuvir/Velpatasvir regime for 24 weeks; 2/3 (66.67%) of them achieved SVR12. There were 2/185 (1.08%) cases of treatment withdrawal due to intolerable side effects which were headache, nausea and facial swelling. However, there were no life-threatening adverse events that occurred.

CONCLUSION: Sofosbuvir/Daclatasvir base DAAs are highly effective, safe and generally well-tolerated as seen in our retrospective analysis.

EUS-GUIDED LUNG MASS BIOPSY IN PATIENTS WITH LUNG CARCINOMA: A CASE SERIES

K K Ng, J Emmanuel, R Puthashanan, R Muthukaruppan

Hospital Queen Elizabeth, Kota Kinabalu, Sabah, Malaysia

OBJECTIVE: Endoscopic Ultrasonography (EUS) is commonly used to diagnose and stage solid and cystic lesions of the abdomen but has been on rare occasions used to evaluate and sample lung lesions. We present a case series on EUS-guided core biopsies of intraparenchymal lung lesions in diagnosing lung carcinoma.

CASE 1: A 59-year-old man who presented with cough and hoarseness of voice for 4 months. CT thorax revealed a left upper lobe tumour. EUS showed a 28mm x 31mm hypoechoic left lung upper lobe mass which was encasing the left subclavian artery. There were no significant mediastinal or intrabdominal lymphadenopathy. EUS-FNB (Fine Needle Biopsy) of the lung mass was done using a 22G Acquire needle. HPE confirmed lung adenocarcinoma.

CASE 2: A 53-year-old man presented with cough, dyspnoea and dysphagia for 3 months. CT thorax revealed a large left hilar and mediastinal mass. EUS revealed a 76mm x 54mm mediastinal mass encasing both aorta and pulmonary trunk, resulting in luminal narrowing of the oesophagus. EUS-FNB of the mass performed with a 22G Acquire needle, confirmed small cell lung carcinoma.

CASE 3: A 48-year-old man complained of shortness of breath for 6 months. CT thorax showed a right lower lobe lung mass with an extension into the mediastinum. EUS revealed a 56mm x 23mm hypoechoic mediastinal mass, which was vascular on colour Doppler. EUS-FNB of the mass was done with a 22G Acquire needle. HPE confirmed small cell lung carcinoma.

DISCUSSION AND CONCLUSION: There were no immediate post procedural complication in all patients. EUS-guided FNB have shown to be safe with excellent diagnostic accuracy in the diagnosis of lung carcinoma in our series. However, larger multicenter studies with longer follow-up are needed in order to better assess its safety and clinical efficacy.

CHOLANGIOSCOPY-GUIDED HOLMIUM LASER LITHOTRIPSY AS A RESCUE TREATMENT FOR AN IMPACTED TRAPEZOID BASKET IN THE BILE DUCT: A CASE REPORT

K K Ng, J Emmanuel, R Puthashanan, R Muthukaruppan

Queen Elizabeth Hospital, Kota Kinabalu, Sabah, Malaysia

OBJECTIVE: We report a case of a 41-year-old lady who had a repeat ERCP intended for bile duct stone clearance, complicated with a fracture of the lithotripter traction wire during the procedure, which was successfully retrieved following Holmium Laser Lithotripsy.

RESULTS: Bile duct was cannulated using an extractor balloon and 0.035 jag wire. The CBD was noted to be dilated proximally (15mm in size) with a large distal CBD stone (10mm in size). Stone extraction was attempted using a Trapezoid Retrieval Basket, however it failed to crush the stone. Subsequently we were unable to release the stone from the lithotripter, therefore, we proceeded with the use of a Soehendra lithotripter which was further complicated with a fracture of the traction wire. Sphincteroplasty was performed up to 12mm in diameter, followed by SpyGlass cholangioscopy and laser lithotripsy. The entrapped pigment stone was successfully fragmented using laser lithotripsy. The remnant wire was then removed with the help of a rat tooth forceps. Subsequent cholangiogram showed multiple stone fragments in mid-CBD. Due to incomplete clearance of the residual stone fragments, stenting was performed with a 7Fr double pigtail plastic stent. No immediate complication was encountered. Subsequent ERCP done 3 months later achieved complete clearance.

DISCUSSION AND CONCLUSION: A trapped basket within the CBD complicated with a fracture of the traction wire during ERCP is conventionally treated with surgery. The procedure in our patient was technically challenging in view of the size and location of the entrapped stone which was at the distal CBD. SpyGlass cholangioscopy with laser lithotripsy had successfully negated the need for open surgery in this patient.

A RARE CASE REPORT: GALLBLADDER MALIGNANCY IN AN ADULT WITH DOWN SYNDROME

N Azis, J Emmanuel, R Puthashanan, R Muthukaruppan

Queen Elizabeth Hospital, Kota Kinabalu, Sabah, Malaysia

OBJECTIVE(S): Solid organ tumors are rare in adults with Down`s Syndrome. We report a rare case of Gallbladder malignancy in our patient with Down`s Syndrome.

METHODOLOGY (IF PERTINENT): Case report

RESULTS: A 35-year-old male with Down`s syndrome presented with fever, jaundice and right hypochondriac pain for 2 weeks duration. Contrast enhanced CT abdomen revealed an infiltrating gallbladder mass causing biliary obstruction with enlarged portal nodes.

EUS performed showed heterogenous gallbladder mass measuring 42mm x 56mm, displacing the portal vein and infiltrating the common bile duct. Fine-needle-biopsy of the mass confirmed high grade dysplasia. ERCP showed a Bismuth II stricture complicated with suppurative cholangitis. Biliary stenting of both systems performed using 7F plastic stents.

He was initially planned for cholecystectomy and hepatectomy, however intaroperatively the GB tumour had infiltrated into hepatic flexure, Gerota`s fascia, 1st part of duodenum and hepatoduodenal ligament. Therefore resection was abandoned. Gallbladder mass was biopsied and this confirmed adenocarcinoma.

DISCUSSION AND CONCLUSION(S): Most common neoplasms associated with Down`s Syndrome are lymphomas and leukaemias. Solid organ tumors are rare in adult Down`s Syndromes with the standardized incidence ratio (SIR) being 0.45 for solid organ tumor and 0.00 for gallbladder malignancy. Few proposed protective mechanisms for solid organ tumors in patients with Down`s Syndrome are over-expression of tumor suppressor gene, endogenous anti-angiogenetic regulators and protective effect of tumor stroma. This is due to the presence of extra chromosome 21 (Trisomy 21). In this case, the possible risk factor could be asymptomatic cholelithiasis as report has shown that children with Down`s Syndrome have higher prevalence of cholelithiasis (3.92%). However, further studies is needed to confirm this.

REFERENCES

1. Low risk of solid tumors in persons with Down syndrome

Henrik Hasle, MD, PhD1, Jan M. Friedman, MD, PhD2, Jørgen H. Olsen, MD, DMSc3 and Sonja A. Rasmussen, MD, MS4

2. Ten Reasons Why People With Down Syndrome are Protected From the Development of Most Solid Tumors - A Review

Marta Pilar Osuna-Marco1,2*, Mónica López-Barahona3, Blanca López-Ibor2 and Águeda Mercedes Tejera1*

1Biology of Ageing Group, Faculty of Experimental Sciences, Universidad Francisco de Vitoria, Madrid, Spain, 2Pediatric

3. Oncology and Hematology Unit, HM Hospitals, Madrid, Spain, 3Centro Estudios Biosanitarios, Madrid, Spain

CHOLANGIOSCOPY-GUIDED HOLMIUM LASER LITHOTRIPSY FOR LARGE BILE DUCT STONES - CASE SERIES

N Azis, J Emmanuel, R Puthashanan, R Muthukaruppan

Queen Elizabeth Hospital, Kota Kinabalu, Sabah, Malaysia

OBJECTIVE: Laser lithotripsy of bile duct stones widely accepted endoscopic treatment modality for giant, impacted or very hard stone. This study objective is to assess safety and efficacy of the procedure.

METHODOLOGY: We report 18 cases of cholangioscopy guided laser lithotripsy performed at our centre. All cases had undergone ERCP and failed stone extraction. The procedure was performed using SpyGlass Digital-Imaging System (D-SOC), Light trail laser fibre (Holmium 30W Thulium 80W) which delivers high-energy pulses of 1800mJ. 17 cases were conducted by 2 operators and 1 case conducted by a single operator.

RESULTS: Patient demographic data showed, the mean age is 51 with female preponderance (56%). 8 patients (44%) of the patients were from Bajau ethnicity and followed by Dusun 4 patients (22%). The commonest presenting complaint were right hypochondriac pain (94%) and jaundice (72%). 10 patients (47%) have no prior medical illness, 4 patients (22.2%) had hypertension and 2 (11%) had hyperlipidemia, chronic kidney disease and previous cholecystectomy respectively.

The mean duration of the procedure was 80 minutes. Mean Common Bile Duct (CBD) diameter was 14mm proximally and 8mm distally. One patient had ectatic CBD and one had distal CBD stricture. 64% of the patients had single stone. Mean stone size is 16mm x 18mm and predominantly located at Mid CBD level (50%). In 16 out of 18 cases, the stones were successfully fragmented in single session. All patients were stented to reduce risk of cholangitis and no complication were observed.

DISCUSSION AND CONCLUSION(S): From our study, laser lithotripsy is safe and effective procedures to treat large bile duct stones. It negates the need for operative procedures for such patients.

CERVICAL OESOPHAGEAL HAEMANGIOMA - A RARE CASE OF UPPER GASTROINTESTINAL BLEED

C C Cheah, James Emmanuel, R Puthashanan, Raman, Muthukaruppan Chettiar

Queen Elizabeth Hospital, Kota Kinabalu, Sabah, Malaysia

INTRODUCTION: Haemangioma of the oesophagus is a rare benign tumor with a prevalence of 3%. Common location of haemangioma is at the lower third of the oesophagus. Patients are usually asymptomatic but some may present either with obstructive or hemorrhagic symptoms. Diagnosis of haemangioma of the upper third of the oesophagus is uncommon. The modalities of treatment is by surgical resection but endoscopic modalities such as endoscopic mucosal resection (EMR) and potassium titanyl phosphate or yttrium aluminum garnet (KTP/YAG) laser therapy have been used.

CASE PRESENTATION: We report a case of a 72 year-old gentleman with underlying hypertension and severe aortic stenosis presented with symptomatic anemia secondary to upper GI bleed. Oesophagogastroduodenoscopy (OGDS) revealed small Forrest III ulcers at gastric antrum, erosive esophagitis grade A (Los Angeles Classification). In addition, we also noted a 2cm solitary reddish-blue mucosal lesion at 20cm from incisors with no evidence of active bleeding. Subsequent CT thorax performed demonstrated a lobulated mass (1.3 x 1.5 x 2.2cm in size) at the level of C7-T1 of the oesophagus with extension to the trachea. Bronchoscopy was then done with the findings of no mass or haemangioma infiltrating the trachea. In view of the advanced age and underlying severe aortic stenosis, he was deemed not fit for surgery. Thus, endoscopic sclerotherapy with injection of 8cc ethanol 96% and 2cc haemoblock was performed under general anaesthesia. Reassessment by Oesophagogastroduodenoscopy (OGDS) 2 days later revealed post sclerotherapy scar in keeping with successful sclerotherapy. Oesophagogastroduodenoscopy (OGDS) done 6 weeks later revealed a well healed scar with no evidence of recurrence.

DISCUSSION: Cervical haemangioma is a rare benign tumor of oesophagus that can be managed successfully by endoscopic sclerotherapy as demonstrated in our case. This modality is an alternative to surgery in selected patients.

INCREASING INCIDENCE OF IBD IN MALAYSIA WITH REVERSAL OF ULCERATIVE COLITIS TO CROHN'S DISEASE RATIO: FOLLOW UP FROM THE KINTA VALLEY STUDY

**Khoo Xin-Hui¹, Tan Phei Oon², Andrew Chua Seng Boon^{3,4,6}, Harjinder Singh⁴, Ng Thean Heng⁴,
Wong Choon Heng⁵, Kong Wai Hong⁵, Raja Affendi Raja Ali⁷, Ida Normiha Hilmi¹**

¹Division of Gastroenterology, Department of Medicine, Universiti Malaya, Kuala Lumpur, Malaysia

²Division of Gastroenterology, Department of Medicine, Hospital Raja Permaisuri Bainun, Ipoh, Perak, Malaysia

³Division of Gastroenterology, Ipoh Gastro Centre, Ipoh, Perak, Malaysia

⁴Division of Gastroenterology, Pantai Hospital Ipoh, Ipoh, Perak, Malaysia

⁵Division of Gastroenterology, KPJ Specialist Centre, Ipoh, Perak, Malaysia

⁶Division of Gastroenterology, Fatimah Hospital, Ipoh, Perak, Malaysia

⁷Division of Gastroenterology, Department of Medicine, Universiti Kebangsaan Malaysia, Kuala Lumpur, Malaysia

BACKGROUND: Inflammatory bowel disease (IBD) although uncommon, is increasing throughout Asia. We previously published a population-based study looking at the incidence of IBD in Malaysia using Kinta Valley as the sample population.

METHODS: Patients diagnosed with IBD from Jan 2022 to Jun 2023 were prospectively recruited from the five medical centers covering all of Kinta Valley. Demographics and clinical characteristics were obtained. Total number of the population as a whole and of each ethnic group were obtained from the Department of Statistics Malaysia to calculate the incidence rates which were then compared to our previously published study.

RESULTS: Fifteen new cases of IBD were diagnosed. The crude incidence rates of IBD, ulcerative colitis (UC), Crohn's disease (CD) and IBD unclassified (IBU-U) were 1.13, 0.45, 0.60, 0.07 per 100,000 persons respectively. The highest incidence was among the Indians, 3.63 compared with 0.49 and 1.24 per 100000 persons among the Malays and the Chinese, respectively. The UC: CD ratio was 0.75: 1. Mean age of diagnosis was 40.9 ± 21.8 years old and mean BMI was 21.8 ± 4.3 . Distribution of CD location were as follows; ileocolonic (50.0%), followed by ileal (25.0%) and colonic (25.0%). Majority of the CD cases were inflammatory (62.5%), followed by stricturing (37.5%). Half of the UC cases were proctitis (50.0%), followed by left-sided (25.0%) and extensive colitis (25.0%). Three patients had IBD-related surgery whereby two patient had surgery at diagnosis.

Compared to the previous study where the crude incidence rates of IBD, ulcerative colitis [UC], and Crohn's disease[CD] between 2011-2013 were 0.68, 0.46, and 0.20 per 100 000 persons, there is an almost 1.7 time increase in incidence from ten years ago. In addition, the incidence of UC:CD is now 0.75:1 compared to 2.3:1 from the previous study. The ethnic distribution and disease pattern remain relatively unchanged.

CONCLUSIONS: The incidence rate of IBD has increased significantly compared to 10 years ago with the incidence of CD now higher than that of UC. This is consistent with our previous findings as well as that of other studies throughout Asia.

Table 1: Demographics and clinical characteristics of IBD patients diagnosed from Jan 2022 to Jun 2023 in Kinta District (n=15)

		IBD	CD	UC	IBD-U	
AGE		40.9 ± 21.8	39.6 ± 20.1	43.5 ± 17.1	35	0.704
Gender	Male	11 (73.3%)	7 (87.5%)	4 (66.7%)	0 (0)	0.157
	Female	4 (26.7%)	1 (12.5%)	2 (33.3%)	1 (100.0%)	
ETHNIC	Malay	3 (15.4%)	2 (16.7%)	1 (16.7%)	0	0.645
	Chinese	6 (38.5%)	4 (50.0%)	2 (33.3%)	0	
	Indian	6 (46.2%)	2 (33.3%)	3 (50.0%)	1 (100.0%)	
BMI		21.8 ± 4.3	22.4 ± 5.0	22.6 ± 3.0	21.87	0.663
Crohns disease						
DISEASE LOCATION	L1 Terminal ileum		2 (25.0%)			
	L2 Colon		2 (25.0%)			
	L3 Ileocolon		4 (50.0%)			
	P Perianal		0			
DISEASE BEHAVIOUR	B1 Inflammatory		5 (62.5%)			
	B2 Stricturing		3 (37.5%)			
	B3 Penetrating		0			
ULCERATIVE COLITIS						
DISEASE LOCATION	E1 Proctitis			2 (50.0%)		
	E2 Left-sided colitis			1 (25.0%)		
	E3 Extensive colitis			1 (25.0%)		
IBD-RELATED SURGERY	Yes	3 (20.0%)	2 (25.0%)	1 (16.7%)	0	
	No	12 (80.0%)	6 (75.0%)	5 (83.3%)	1 (100.0%)	

REFERENCE

Ida Hilmi, Fauziah Jaya, Andrew Chua, Wong Choon Heng, Harjinder Singh, Khean-Lee Goh. A first study on the incidence and prevalence of IBD in Malaysia--results from the Kinta Valley IBD Epidemiology Study. *J Crohns Colitis* 2015;9:404-9

ENDOSCOPIC RETROGRADE CHOLANGIOPANCREATICOGRAPHY (ERCP) USING A GASTROSCOPE

Kokulabalan Mariappen, James Emmanuel, Puthashanan Rajamanickam,
Raman Muthukaruppan Chettiar

Queen Elizabeth Hospital, Kota Kinabalu, Sabah, Malaysia

INTRODUCTION: Endoscopic retrograde cholangiopancreatography (ERCP) is a procedure that combines the use of endoscopy and fluoroscopy to diagnose and to treat diseases pertaining to the biliary and pancreatic ducts. The conventional method uses the side viewing duodenoscope, however in certain instances a gastroscope may be needed.

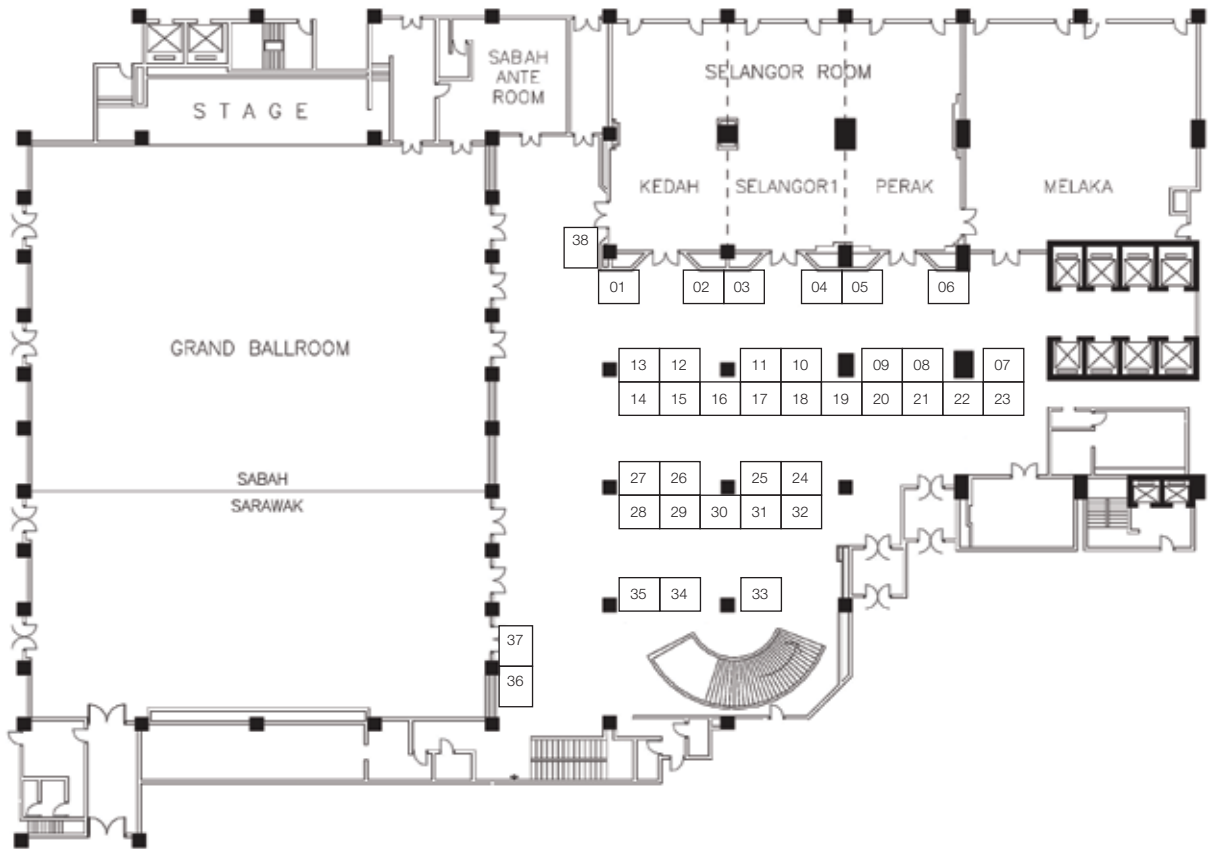
OBJECTIVE: Evaluate safety and efficacy of performing technically difficult ERCPs with gastroscope

METHODOLOGY: Retrospective analysis of 6 patients in whom gastroscope was utilized to perform ERCP from March 2022 till June 2023

RESULTS: A total of 7 ERCPs were performed in 6 patients using a gastroscope. This comprised 83% (n:5) males and 17% (n:1) female, with ages ranging from 47 to 69 years old (median age:61). The indications for ERCP were: ascending cholangitis secondary to choledocholithiasis (n:3,50%), obstructive jaundice secondary to malignant biliary stricture (n:2, 33%) and tuberculosis (TB) related biliary stricture (n:1,17%). Out of the 6 patients, 2 (33%) patients had altered anatomy (post Bilroth II surgery) which required gastroscope utilisation from the start. The remaining patients were switched to a gastroscope after failure to advance the duodenoscope into the duodenum. Technical success was 100% and clinical success was 6/7 (86%). There were no complications reported in our case series.

DISCUSSION: This case series highlights the safety and efficacy of gastroscope in performing ERCP in selected patients with technical difficulties and offers an alternative strategy to PTBD/surgery. However, a larger patient pool is needed to ascertain the efficacy and safety of this technique.

FLOOR PLAN



TRADE EXHIBITION

BOOTH NO	COMPANY	BOOTH NO	COMPANY
01	Mylan Sdn Bhd	18	SYS Healthcare Sdn Bhd
02 & 03	Abbott Sdn Bhd	19	Olympus Malaysia Sdn Bhd
04	Kotra Pharma (M) Sdn Bhd	20	Mansa Healthcare Sdn Bhd
05	First Pharma Sdn Bhd	21	Duopharma Marketing Sdn Bhd
06	Ferring Sdn Bhd	22	Eisai (Malaysia) Sdn Bhd
07	Biolife Sdn Bhd	23	Integrated Medical System Sdn Bhd
08	Yakult (Malaysia) Sdn Bhd	24 & 25	DCH Sdn Bhd
09	Amili Asia	26, 27, 28 & 29	Astrazeneca Sdn Bhd
10	Glaxosmith (M) Sdn Bhd	30	Boston Scientific (M) Sdn Bhd
11	Janssen Pharmaceutical	31	Infinity Medical Sdn Bhd
12	Hovid Sdn Bhd	32	WellMedic Healthcare Sdn Bhd
13 & 14	Pfizer (M) Sdn Bhd	33	EP Plus Group Sdn Bhd
15	United Italian Trading (M) Sdn Bhd	34 & 35	Servier Sdn Bhd
16	Medi-Life (M) Sdn Bhd	37	RB Health Sdn Bhd
17	Cellthron Malaysia Sdn Bhd	38	Sun Pharmacy Sdn Bhd

Hospitality Suite, Kedah Room	Takeda (M) Sdn Bhd
Hospitality Suite, Selangor Room	Medic Pro Healthcare Sdn Bhd
Hospitality Suite, Perlis Room	Integrated Medical System Sdn Bhd

ACKNOWLEDGEMENTS

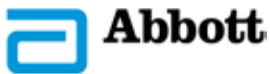The Organising Committee of the GUT 2023 incorporating 12th Asian Pacific Topic Conference 2023 on Gut Microbiota would like to express its appreciation to the following for their support and contributions:

DIAMOND SPONSOR



Astrazeneca Sdn Bhd

PLATINUM SPONSORS



Abbott Sdn Bhd



Pfizer (M) Sdn Bhd



Servier Sdn Bhd



Takeda (M) Sdn Bhd

GOLD SPONSORS



DCH Sdn Bhd



Ferring Sdn Bhd



First Pharma
Sdn Bhd



Glaxosmith (M)
Sdn Bhd



Janssen Pharmaceutical



Medic Pro Healthcare
Sdn Bhd



Mylan Sdn Bhd

ACKNOWLEDGEMENTS

SILVER SPONSORS

Amili Asia
Boston Scientific (M) Sdn Bhd
Celltrion Healthcare Malaysia Sdn Bhd
Duopharma Marketing Sdn Bhd
Eisai (Malaysia) Sdn Bhd
EP Plus Group Sdn Bhd
Hovid Pharmacy Sdn Bhd
Infinity Medical Sdn Bhd
Integrated Medical System Sdn Bhd
Kotra Pharma (M) Sdn Bhd
Mansa Healthcare Sdn Bhd
Medi-Life (M) Sdn Bhd
Mega Lifesciences Sdn Bhd (Bio life)
Olympus Malaysia Sdn Bhd
Ranbaxy (M) Sdn Bhd
RB (Health) Sdn Bhd
Roche (M) Sdn Bhd
Sun Pharma Company
SYS Healthcare Sdn Bhd
United Italian Trading (M) Sdn Bhd
WellMedic Healthcare Sdn Bhd
Yakult (Malaysia) Sdn Bhd